

Case Report and Review of Literature: Camrelizumab Combined with Fuzuloparib and Apatinib for Platinum-Resistant Recurrent Ovarian Cancer

Yawen Wu^{1,2}, Xiaoyan Zhang^{1,2}, Lian Li², Wen Yang², Zhifeng Yan², Chenglei Gu², Zhe Zhang², Jiahuan Zhou³, Lulu Liu³, Mingxia Ye², Yuanguang Meng²

¹School of Medicine, Nankai University, Tianjin, People's Republic of China; ²Department of Gynecology and Obstetrics, The First Medical Center of Chinese PLA General Hospital, Beijing, People's Republic of China; ³Department of Clinical Research & Development, Jiangsu Hengrui Pharmaceuticals Co., Ltd, Shanghai, People's Republic of China

Correspondence: Mingxia Ye; Yuanguang Meng, Email ymx298013@126.com; meng6512@vip.sina.com

Background: The mortality rate of ovarian cancer (OC) ranks first among female genital tract malignant tumors, which seriously threatens women's life and health. Because of its insidious onset and poor prognosis, it has become a thorny problem in the clinic, especially for patients with platinum-resistant recurrent ovarian cancer (PROC). In recent years, the medical treatment of OC has made gratifying results, bringing hope to the patients.

Case Description: A 54-year-old OC patient who has failed previous neoadjuvant chemotherapy, cytoreductive surgery, and postoperative chemotherapy was diagnosed with PROC. Then she received combination treatment of fuzuloparib (100mg PO BID), apatinib (250mg PO QD), and camrelizumab (200mg IV Q3W) for every 3-week cycle in a Phase II study for PROC patients. In the phase II study, her condition stabilized, responded well to treatment with a sharp decrease by 91.14% of target lesions and disappearances of non-target lesions, and continued to receive regular treatment with progression-free survival exceeding 15 months and no serious adverse events.

Conclusion: The present case proves PROC patients might have a sustained response to triplet combination with camrelizumab, combined with fuzuloparib and apatinib.

Keywords: recurrent ovarian cancer, platinum resistance, PARP inhibitors, immunotherapy, antiangiogenic agents

Introduction

The mortality rate of ovarian cancer (OC) is first among female genital tract malignant tumors.^{1,2} Because of its insidious onset and no specific clinical symptoms and signs, more than 70% of OC patients are diagnosed at an advanced stage and have a poor overall prognosis.³ Even if there is an opportunity to receive satisfactory cytoreductive surgery and adequate first-line chemotherapy at the initial treatment, 80% of patients with epithelial ovarian cancer will relapse at different time points, with a 5-year survival rate of 40%.^{3,4}

Based on the time from the end of the last platinum-based chemotherapy to disease progression, which is called platinum-free interval (PFI), patients with recurrent OC are divided into two categories. Those with PFI \geq 6 months are considered platinum-sensitive recurrence, and others with PFI $<$ 6 months are considered platinum resistance relapse. And almost all patients with platinum-sensitive relapse ultimately develop platinum resistance. The 2021 NCCN guidelines recommend that non-platinum single-agent chemotherapy or combined with targeted anti-angiogenesis drugs is the first choice for platinum-resistant relapsed patients.

Apatinib is an oral and highly potent tyrosine-kinase inhibitor targeting vascular endothelial growth factor receptor 2 (VEGFR-2).⁵ Efficacy and safety of apatinib in patients with platinum-resistant recurrent epithelial ovarian cancer (PROC) were shown in phase II clinical trials.⁶ Besides, apatinib combined with oral etoposide was proved to be

effective and safe among patients with platinum-resistant or platinum-refractory OC in Phase II, single-arm, prospective study.⁷ Fuzuloparib is the first original PARP inhibitor to be developed in China. It has received its first approval in China for the treatment of platinum-sensitive recurrent ovarian cancer in patients with germline BRCA mutation (gBRCAm) who have undergone second-line or above chemotherapy.⁸

The focus of tumor treatment is to prolong overall survival and the patient's quality of life as much as possible. The treatment of PROC is still a difficult problem in clinical practice and lacks effective therapeutic measures. In recent years, remarkable achievements have been made in the medical treatment of ovarian cancer, especially the new progress in PARP inhibitors, immunotherapy, and anti-angiogenic drugs.⁹ Herein, we firstly present a Chinese patient with germline BRCA1 mutated PROC who responded well to fuzuloparib in combination with camrelizumab and apatinib with a review of the literature.

Case Presentation

On October 16th, 2018, a 54-year-old married female patient, who was postmenopausal for 7 years and had 2 children, initially visited our hospital due to a pelvic mass accidentally found for 2 weeks. She underwent a resection of the left temporal skin basal cell carcinoma in September 2018, and her father died of brain metastases from lung cancer. Except for those, no other notable medical histories were present. Results of physical examinations were generally normal. Transvaginal ultrasound in our hospital showed a heterogeneous hypoechoic mass with a size of 11.9×9.3 × 9.0 cm in the pelvic cavity, and an ultrasound-guided needle biopsy of the mass was performed. The carbohydrate antigen 125 (CA125) is 517.3 U/mL. The patient was primarily diagnosed with ovarian cancer based on a pathological report of intrapelvic adenocarcinoma and results of immunohistochemistry. The results showed that ER(+), PMS2(+80%), MLH1 (+80%), MSH2(+90%), MSH6(+90%), PR(-), P16(+), WT-1(+), p53(+90%), Ki-67(+80%), HER-1(EGFR)(+), HER-2(1+), CDX-2(small focal+), Villin(-).

On admission, gynecological examination suggested that the pelvic range of motion was poor and closely related to the rectum, and the risk of rectal injury was greater, and there was ascites, it was difficult to achieve R0 in surgery. After adequate evaluation and discussion, the patient was given two-course neoadjuvant chemotherapy with paclitaxel and cisplatin (TP). The neoadjuvant treatment time was October 30, 2018, and November 29, 2018 respectively. On January 4, 2019, the patient underwent open abdominal cytoreductive surgery for ovarian cancer. Then she was diagnosed with stage IIIC moderately differentiated ovarian endometrioid adenocarcinoma based on postoperative pathology. The patient received satisfactory cytoreductive surgery and achieved R0. From January 13, 2019, to June 20, 2019, the patient was given six-course TP chemotherapy after surgery. Due to tumor recurrence suggested by imaging, bevacizumab, a monoclonal antibody targeting vascular endothelial growth factor, was combined since the 4th course of TP chemotherapy. At the end of treatment in June 2019, the ultrasound showed a hypoechoic nodule with a size of about 1.4 × 2.1 × 1.6 cm above the vagina. Follow-up regular reexaminations detected a slow growth of the vaginal hypoechoic nodule to 3.2 × 2.6 × 3.3 cm and new multiple small nodules in the pelvic cavity. In combination with biopsy pathology, it was considered to be tumor recurrence with metastasis, and the disease progressed. The patient was diagnosed with PROC and unable to be treated promptly due to coronavirus outbreak, no maintenance treatment and pelvic lesions persisted and progressed.

On August 9, 2020, the patient was enrolled in a phase II study for PROC patients (ChiCTR1900027114) and treated with combination treatment of fuzuloparib (100mg PO BID), apatinib (250mg PO QD), and camrelizumab (200mg IV Q3W) for every 3-week cycle. From August 9, 2020, to November 23, 2021, twenty-one cycles of therapy have been administered. CT scans revealed a partial response. At baseline, the diameter of target lesions at the vaginal stump and in front of rectum was 44 mm (Figure 1), and multiple lymph nodes below 8 mm in the internal iliac vessel region were observed for non-target lesions (Figure 2). After the 4th cycle of treatment, non-target lesions disappeared and did not recur (Figure 3). At the end of the 11th cycle, the diameter of target lesions reduced to 3.9 mm without significant change thereafter (Figure 4). Target lesions sharply decrease by 91.14%. No new lesions were found.

The incidence of grade 3 and above adverse reactions was 0. After the 4th cycle of treatment (November 5, 2020), grade 2 hypothyroidism gradually occurred. The main symptoms included serum-free T4 level gradually decreased to a minimum of 4.63 pmol/L, and serum thyroid-stimulating hormone level gradually increased to a maximum of 108.15 mU/L,

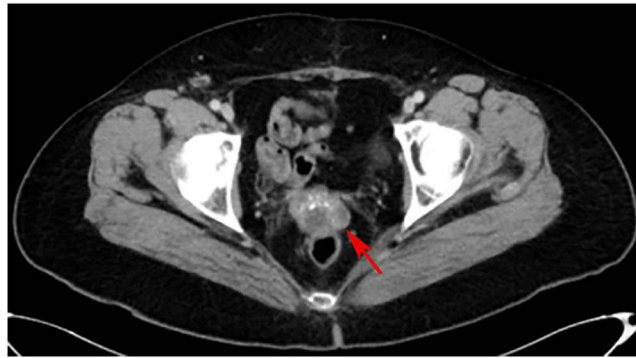


Figure 1 Target lesions at baseline. Target lesions at the vaginal stump and in front of rectum was 44 mm in longest diameter at baseline (red arrow).

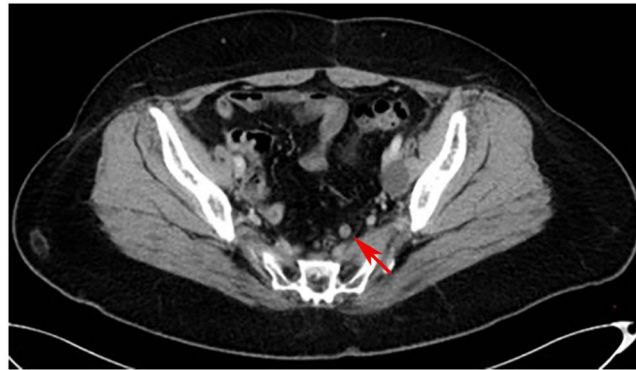


Figure 2 Non-target lesions at baseline. Multiple lymph nodes below 8 mm in the internal iliac vessel region were observed for non-target lesions at baseline (red arrow).

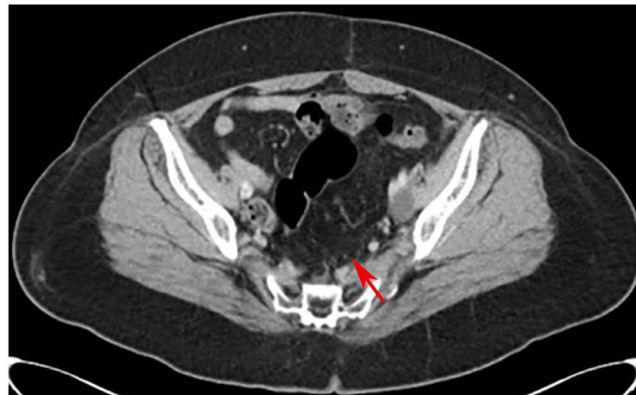


Figure 3 Non-target lesions at the end of the 4th cycle. Non-target lesions disappeared at the end of the 4th cycle of treatment and did not recur (red arrow).

accompanied by fatigue, weight gain, ECG ST-T changes, and other symptoms. The patient was given regular oral administration of levothyroxine sodium tablets (75ug QD) till now. Related symptoms were gradually relieved with good control. Reexamination of thyroid function was within the normal range. Another adverse reaction was a grade I red blood cell count decreased, which was fluctuating between $3.38 \times 10^{12}/L$ and $3.8 \times 10^{12}/L$. The patient had no subjective symptoms and did not require clinical intervention. The hemoglobin, white blood cell count, and neutrophil count were within the normal range. The above adverse reactions were considered related to anti-PD-1 antibody and PARP inhibitor drugs, rather than the new adverse reactions due to the triplet combination therapy.

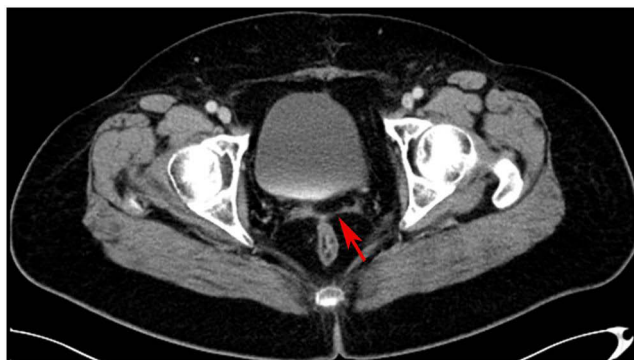

Figure 4 Target lesions at the end of the 11th cycle. Target lesions at the vaginal stump and in front of rectum reduced to 3.9 mm in longest diameter at the end of the 11th cycle (red arrow), which sharply decreased by 91.14%.

At baseline, the patient's CA125 level was 33.35 U/mL. After the 2nd cycle of treatment, CA125 level decreased to 4.78 U/mL, and was within the normal range on subsequent visits. Moreover, the patient underwent genetic testing and additional immunohistochemical tests during treatment of triplet combination. Genetic testing revealed BRCA1 (+), which was performed on September 22, 2021. Immunohistochemistry indicated PD-L1 (SP263), TC < 1%, CPS: 2, MLH1 (+>90%), MSH2 (+>90%), MSH6 (+>90%), and PMS2 (+>90%), which was performed on October 10, 2021.

The patient is still receiving triplet combination treatment with stable vital signs, significantly improved mental status, good appetite, and weight increased by 3 kg than before. Quality of life has been greatly improved, including significantly improved physical condition and mental and psychological status compared with those before participating in the clinical trial. The patient is self-sufficient in daily living with the eastern cooperative oncology group performance status (ECOG PS) of 2.

Discussion

Remarkable progress has been made in the treatment of ovarian cancer in recent years. However, most patients with advanced disease will develop tumor resistance to chemotherapy, particularly platinum resistance that ultimately results in fatality.¹⁰ Exploring an effective and well-tolerated treatment strategy for patients with platinum-resistant ovarian cancer (PROC) remains a challenge. Immune checkpoint inhibitors (ICI) have turned into a potent oncologic treatment for patients with different solid tumors. Unfortunately, the efficacy of ICI monotherapy in ovarian cancer is limited.^{11,12} To increase the proportion of patients who are likely to derive benefit, combination therapy was considered as a new opportunity for immunotherapy in ovarian cancer.

Herein, we describe a case of platinum-resistant recurrent ovarian cancer that showed a favorable response to camrelizumab, an anti-PD-1 antibody, combined with poly ADP-ribose polymerase inhibitor (PARPi) fuzuloparib and apatinib, an inhibitor of vascular endothelial growth factor receptor 2 (VEGFR-2). To the best of our knowledge, this is the first report that illustrates the efficacy and safety of the triplet combination in a Chinese patient with germline BRCA1 mutated PROC.

Poly ADP-ribose polymerase inhibitors targeting DNA repair (DDR) have greatly affected the ovarian cancer treatment, especially for patients with homologous recombination repair deficiency (HRD). Several PARP inhibitors have been developed and used in the clinical practice and clinical trials for ovarian cancer, such as olaparib, niraparib, fuzuloparib and pamiparib. In the CLIO trial (NCT02822157),¹³ olaparib monotherapy showed a favorable response rate (18%) compared with non-platinum chemotherapy (6%), regardless of the gBRCA status in PROC patients. However, the progression-free survival (PFS) was only 2.9 months for olaparib, compared with 3.4 months for chemotherapy, highlighting the need to develop alternative strategies.

Programmed death molecule-1 (PD-1) is a protein receptor expressed on the surface of T cells and is involved in the process of cell apoptosis. The humanized anti-PD1 monoclonal antibody can specifically bind to PD-1 and block the PD-1/PD-L1 signaling pathway to enhance T cell killing activity. A phase II study (KEYNOTE-100) of pembrolizumab in

patients with advanced ROC showed that the ORR rate was higher in the high PD-L1 expression group.¹¹ Treatment-related adverse reactions occurred in 73% of patients. Grade 3–5 adverse reactions occurred in 17% of subjects. Due to the low response rate, only a limited number of ovarian cancer patients will benefit from anti-PD-1 /PD-L1 monotherapy immune targeting.¹² Reasonable combination therapy can overcome the problems of low response rate and immune targeted therapy resistance.

PARPi has been found to enhance PD-L1 expression through several cellular pathways (eg, IFN γ , STNG pathway, GSK3B).^{14,15} At the same time, PARPi mediated DNA damage may enhance the anti-tumor immune response.¹⁶ D-1/PDL1 inhibitors are utilized to reduce the anti-tumor immune escape ability caused by PDL1 up-regulation, thereby improving the sensitivity of patients to PARPi. The TOPACIO trial (NCT02657889)¹⁷ showed that niraparib combined with anti-PD-1 pembrolizumab is tolerable, with an ORR of 18% and a disease control rate (DCR) of 65% in platinum-resistant or refractory recurrent ovarian cancer. Previous clinical trials of PARPi and anti-PD-L1 combination therapy for PROC did not show significant improvement in clinical efficacy.

Preclinical studies suggest that anti-angiogenics and PARPi have synergistic effect likely due to overlaps between the DDR pathways and angiogenesis, as the hypoxia induced by antiangiogenic treatment could repress homologous recombination repair, and PARP inhibition may ameliorate HIF1 α -mediated resistance to antiangiogenics.^{18–20} Multiple clinical studies have been performed to investigate the clinical activity of PARP inhibitors in combination with antiangiogenic agents (most targeting vascular endothelial growth factor (VEGF) signaling) for ovarian cancer. Olaparib plus bevacizumab has been approved for maintenance treatment of OC in homologous recombination deficiency (HRD)-positive tumors.²¹ The EVOLVE study assessed olaparib in combination with cediranib (a small molecule receptor tyrosine kinase inhibitor targeting VEGF receptor 1–3 and mast/stem cell growth factor receptor c-KIT) after progression on a PARPi. Among 34 heavily pretreated patients, objective responses were observed in 0 of 11 (0%) platinum-sensitive patients, and 2 of 10 (20%) platinum-resistant patients. Sixteen-week PFS rates were 55% and 50%, respectively.²²

Moreover, evidences suggest that angiogenic and immunogenic pathways exhibit extensive crosstalk.^{23–25} Angiogenic factors like VEGF could create an immunosuppressive environment by the release of inhibitory cytokines and the recruitment of immunosuppressive cell types.²⁶ Thus, the combined targeting of angiogenesis and immune checkpoints is deemed to facilitate a more robust immune response to therapy. Nevertheless, only a few of ongoing trials of dual inhibition of angiogenic and immune checkpoint pathways in PROC, with limited data thus far. In a single arm phase II trial (NCT02873962) of the combination of bevacizumab and the anti-PD-1 antibody nivolumab, the ORR across 38 women enrolled was 28.9%, and the ORR was 16.7% (3/18) in the platinum-resistant participants.²⁷

Considering that the combination of immunotherapy, PARPi and antiangiogenic agents may enhance the efficacy of each treatment, several clinical trials are under way to investigate the efficacy of triplet combination in the treatment of ovarian cancer. Notably, preliminary results of bevacizumab, olaparib, and durvalumab within the GINECO BOLD study showed promising results in patients with PROC: median PFS was 4.1 [3.5–5.9] months, median overall survival (mOS) was 18.8 [9.6 – NR] months, DCR at 3 months and 6-months were 70% and 30%, respectively.²⁸ In this case, our patient has sustained a response for more than 15 months, longer than the mPFS in the GINECO BOLD study.

In our case, the patient achieved considerable clinical response with a sharp decrease of 91.14% of the target lesions after receiving camrelizumab, combined with fuzuloparib and apatinib. As we know, BRCA1/2 deficient or HRD-positive tumor cells are more sensitive to PARPi,²⁹ the great benefit from the triplet combination therapy our patient has gained may largely lie in the functional loss of BRCA1, which contributes to the synthetic lethality induced by fuzuloparib. The limitation is that this is just one individual case. As mentioned above, recent studies suggest the existence of overlaps between PARP inhibition, anti-angiogenesis, and the PD-1/PD-L1 axis. The synergistic effect of this combined treatment on PROC warrants further investigation in a large sample.

In conclusion, our case suggests that the triplet combination with camrelizumab, combined with fuzuloparib and apatinib maybe a new option for PROC patient with manageable adverse reaction.

Ethics Approval and Consent for Publication

This study was approved by the Ethics Committee of Chinese PLA General Hospital. Written informed consent was obtained from the patient in accordance with the Declaration of Helsinki for the purpose of publication of the present case report and any relevant images.

Acknowledgments

The authors would like to thank our patient for allowing his case to be presented.

Disclosure

Authors Jiahuan Zhou and Lulu Liu are employed by Jiangsu Hengrui Pharmaceuticals Co., Ltd. The remaining authors declare that the research was conducted in the absence of any commercial or financial relationships that could be construed as a potential conflict of interest.

References

1. Gaona-Luviano P, Medina-Gaona LA, Magaña-Pérez K. Epidemiology of ovarian cancer. *Chin Clin Oncol*. 2020;9(4):47. doi:10.21037/cco-20-34
2. Momenimovahed Z, Tiznobaik A, Taheri S, Salehiniya H. Ovarian cancer in the world: epidemiology and risk factors. *Int J Womens Health*. 2019;11:287–299. doi:10.2147/IJWH.S197604
3. Huang L, Xu AM. MYND domain containing protein 3 in cancer. *Am J Transl Res*. 2017;9(1):1–14.
4. Ferlay J, Soerjomataram I, Dikshit R, et al. Cancer incidence and mortality worldwide: sources, methods and major patterns in GLOBOCAN 2012. *Int J Cancer*. 2015;136(5):E359–386.
5. Ding J, Chen X, Gao Z, et al. Metabolism and pharmacokinetics of novel selective vascular endothelial growth factor receptor-2 inhibitor apatinib in humans. *Drug Metab Dispos*. 2013;41(6):1195–1210.
6. Miao M, Deng G, Luo S, et al. A phase II study of apatinib in patients with recurrent epithelial ovarian cancer. *Gynecol Oncol*. 2018;148(2):286–290.
7. Lan CY, Wang Y, Xiong Y, et al. Apatinib combined with oral etoposide in patients with platinum-resistant or platinum-refractory ovarian cancer (AEROC): a Phase 2, single-arm, prospective study. *Lancet Oncol*. 2018;19(9):1239–1246.
8. Lee A. Fuzuloparib: first approval. *Drugs*. 2021;81(10):1221–1226.
9. Pignata S, Du Bois SCC, Harter P, Heitz F. Treatment of recurrent ovarian cancer. *Ann Oncol*. 2017;28(suppl_8):viii51–viii56.
10. Pujade-Lauraine E, Combe P. Recurrent ovarian cancer. *Ann Oncol*. 2016;27(Suppl 1):i63–i65. doi:10.1093/annonc/mdw079
11. Matulonis UA, Shapira-Frommer R, Santin AD, et al. Antitumor activity and safety of pembrolizumab in patients with advanced recurrent ovarian cancer: results from the phase II KEYNOTE-100 study. *Ann Oncol*. 2019;30(7):1080–1087. doi:10.1093/annonc/mdz135
12. Disis ML, Taylor MH, Kelly K, et al. Efficacy and safety of avelumab for patients with recurrent or refractory ovarian cancer: phase 1b results from the JAVELIN solid tumor trial. *JAMA Oncol*. 2019;5(3):393–401. doi:10.1001/jamaoncol.2018.6258
13. Vanderstichele A, Nieuwenhuysen EV, Han S, et al. Randomized phase II CLIO study on olaparib monotherapy versus chemotherapy in platinum-resistant ovarian cancer. *J Clin Oncol*. 2019;37(15_suppl):5507. doi:10.1200/JCO.2019.37.15_suppl.5507
14. Chabanon RM, Muirhead G, Krastev DB, et al. PARP inhibition enhances tumor cell–intrinsic immunity in ERCC1-deficient non–small cell lung cancer. *J Clin Invest*. 2019;129(3):1211–1228. doi:10.1172/JCI123319
15. Jiao S, Xia W, Yamaguchi H, et al. PARP inhibitor upregulates PD-L1 expression and enhances cancer-associated immunosuppression. *Clin Cancer Res*. 2017;23(14):3711–3720. doi:10.1158/1078-0432.CCR-16-3215
16. Ferrara N, Hillan KJ, Gerber H-P, Novotny W. Discovery and development of bevacizumab, an anti-VEGF antibody for treating cancer. *Nat Rev Drug Discov*. 2004;3(5):391–400. doi:10.1038/nrd1381
17. Konstantinopoulos PA, Waggoner S, Vidal GA, et al. Single-arm phases 1 and 2 trial of niraparib in combination with pembrolizumab in patients with recurrent platinum-resistant ovarian carcinoma. *JAMA Oncol*. 2019;5(8):1141–1149. doi:10.1001/jamaoncol.2019.1048
18. Monk BJ, Minion LE, Coleman RL. Anti-angiogenic agents in ovarian cancer: past, present, and future. *Ann Oncol*. 2016;27(Suppl 1):i33–i39. doi:10.1093/annonc/mdw093
19. Martinez-Romero R, Martinez-Lara E, Aguilar-Quesada R, Peralta A, Oliver FJ, Siles E. PARP-1 modulates deferoxamine-induced HIF-1 α accumulation through the regulation of nitric oxide and oxidative stress. *J Cell Biochem*. 2008;104(6):2248–2260. doi:10.1002/jcb.21781
20. Kaplan AR, Gueble SE, Liu Y, et al. Cediranib suppresses homology-directed DNA repair through down-regulation of BRCA1/2 and RAD51. *Sci Transl Med*. 2019;11:492.
21. Arora S, Balasubramaniam S, Zhang H, et al. FDA approval summary: olaparib monotherapy or in combination with bevacizumab for the maintenance treatment of patients with advanced ovarian cancer. *Oncologist*. 2021;26(1):e164–e172.
22. Lheureux S, Oaknin A, Garg S, et al. EVOLVE: a multicenter open-label single-arm clinical and translational phase ii trial of cediranib plus olaparib for ovarian cancer after PARP inhibition progression. *Clin Cancer Res*. 2020;26(16):4206–4215.
23. Schaaf MB, Garg AD, Agostinis P. Defining the role of the tumor vasculature in antitumor immunity and immunotherapy. *Cell Death Dis*. 2018;9(2):115.
24. Fukumura D, Kloepper J, Amoozgar Z, Duda DG, Jain RK. Enhancing cancer immunotherapy using antiangiogenics: opportunities and challenges. *Nat Rev Clin Oncol*. 2018;15(5):325–340.
25. Ramjiawan RR, Griffioen AW, Duda DG. Anti-angiogenesis for cancer revisited: is there a role for combinations with immunotherapy? *Angiogenesis*. 2017;20(2):185–204.

26. Voron T, Colussi O, Marcheteau E, et al. VEGF-A modulates expression of inhibitory checkpoints on CD8+ T cells in tumors. *J Exp Med*. 2015;212(2):139–148.
27. Liu JF, Herold C, Gray KP, et al. Assessment of combined nivolumab and bevacizumab in relapsed ovarian cancer: a phase 2 clinical trial. *JAMA Oncol*. 2019;5(12):1731–1738.
28. Freyer G, Floquet A, Tredan O, et al. 733P - Bevacizumab (Bev), olaparib (Ola) and durvalumab (Durva) in patients with recurrent advanced ovarian cancer (AOC): the GINECO BOLD study. *Annals Oncol*. 2021;32(suppl_5):S725–S772.
29. Li H, Liu ZY, Wu N, Chen YC, Cheng Q, Wang J. PARP inhibitor resistance: the underlying mechanisms and clinical implications. *Mol Cancer*. 2020;19(1):107.

OncoTargets and Therapy

Dovepress

Publish your work in this journal

OncoTargets and Therapy is an international, peer-reviewed, open access journal focusing on the pathological basis of all cancers, potential targets for therapy and treatment protocols employed to improve the management of cancer patients. The journal also focuses on the impact of management programs and new therapeutic agents and protocols on patient perspectives such as quality of life, adherence and satisfaction. The manuscript management system is completely online and includes a very quick and fair peer-review system, which is all easy to use. Visit <http://www.dovepress.com/testimonials.php> to read real quotes from published authors.

Submit your manuscript here: <https://www.dovepress.com/oncotargets-and-therapy-journal>