


CASE REPORT

Congenital dengue in neonate

Shailabh Gupta¹ | Vivek Choudhury¹ | Naveen Prakash Gupta¹ | Vishal Gupta² | Aakash Pandita³ ¹Neonatal Division, Department of Paediatrics, Max Super Specialty Hospital Patparganj, Delhi, India²John Radcliffe Hospital, Oxford, UK³Department of Neonatology SGPGI, Lucknow, India**Correspondence**Aakash Pandita, Consultant Neonatology, SGPGIMS, Lucknow, U.P, India.
Email: aakash.pandita@gmail.com**Abstract**

Congenital dengue should be considered as a cause of fever and rash in a neonate born to a mother especially in endemic areas.

KEYWORDS

Congenital Dengue, Neonatal rash, Neonatal sepsis, Thrombocytopenia

1 | INTRODUCTION

Dengue is an infectious disease caused by dengue virus and is transmitted classically by bite of female *Aedes aegypti* mosquito. The infection is endemic in India. In pregnant females, it can lead to premature labor.¹ Vertical transmission is known to occur which may cause increased perinatal mortality and morbidity.² Viremia persists for approximately 7 days and infected newborn may be asymptomatic or may show varied signs of infection. However, dengue fever has not been shown to cause any congenital abnormalities^{3,4} although dengue virus infection in early pregnancy during organogenesis may cause spontaneous abortion or neural tube alterations.⁵ Dengue is common in Asian countries namely India, Pakistan, and Sri Lanka. Dengue virus outbreaks have increased substantially over the past several decades in these countries. The cases increased to 180 000 in India in 2017, which is more than twice the average reported over the previous decade. Vertical transmission of dengue has been reported and should be considered in cases where illness in the mother occurs within 10 days before delivery. The affected neonates may become symptomatic up to 11 days (median 4 days) after birth. Pregnancy does not appear to increase the incidence or severity of dengue.⁶ In a prospective study of 2958 pregnant female, 2531 paired maternal-umbilical cord

blood samples were tested for dengue (Ig)M.⁷ Sixty-three women (prevalence of 2.5 percent) had a positive IgM serology. Only one (vertical transmission of 1.6 percent) of the paired umbilical cord samples was seropositive for dengue. All the maternal and fetal blood samples were negative for viral RNA by polymerase chain reaction. Breastfeeding has been proposed as a route of vertical transmission of dengue virus⁸ Figure 1.

2 | CASE

A late preterm (36 weeks) male, with birth weight 2.09 kg was born to a primigravida mother through vaginal delivery. Mother had history of high-grade fever 10 days prior to delivery, which responded well to antipyretics. Baby cried immediately after birth and was shifted to mother side. Sepsis work up was sent in view of history of fever in mother. Baby subsequently started with maculopapular rashes and thrombocytopenia (platelet counts 80 000/cumm) which worsened by day 3-30 000/cumm. Baby was started on iv antibiotics and referred on day 3 for further management.

On admission, baby was hemodynamically stable and blood, CSF, and urine cultures were sterile. NS-1 antigen was negative and dengue IgM was positive and IgG

This is an open access article under the terms of the Creative Commons Attribution-NonCommercial-NoDerivs License, which permits use and distribution in any medium, provided the original work is properly cited, the use is non-commercial and no modifications or adaptations are made.

© 2020 The Authors. *Clinical Case Reports* published by John Wiley & Sons Ltd.

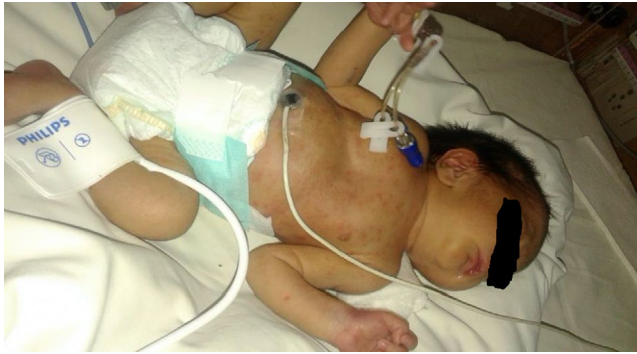

FIGURE 1 Neonate with maculopapular rash

TABLE 1 Investigations suggestive of dengue in mother and neonate

	Day of illness	NS-1 Ag	IgM	IgG
Mother	(Antepartum)	+	-	-
	Day 3			
	Day 8	-	+	-
	(Postpartum)	-	-	+
	Day 35			
Baby	Day 3	-	+	-
	Day 25	-		+

was negative initially (at day 3 of life). But at day 25 of life, dengue IgG came out positive. Dengue serology of mother was done which also came positive (IgM+, IgG+). (Table 1).

Patient was treated as a case of congenital dengue, platelet count improved over next 5-6 days and rash disappeared. Baby continued to remain hemodynamically stable and did not show any sign of hemorrhage or hypotension. Baby was discharged from hospital in a healthy condition.

3 | DISCUSSION

Presentation of congenital dengue is summarized in a systematic review by Pouliot SH et al; out of a total of 34 cases, 5 were reported to be asymptomatic and rest had symptoms such as fever, thrombocytopenia, hepatomegaly, hemorrhage, effusion, and rash. Average time between maternal fever and neonatal symptoms was 7 days (range 5-13 days).² Pregnant female can pass dengue virus to fetus if she develops fever from 10 days before delivery to 10 hours after delivery. Mode of delivery does not affect the rate of transmission.⁴ Common signs and symptoms include fever, thrombocytopenia as in general population, followed by elevated liver enzymes. Rarely, some cases may develop dengue shock syndrome with severe bleeding requiring platelet and red blood cell transfusions.²⁻⁷

It has been proposed that maternal age <20 years have high amount of circulating anti-dengue antibodies than those older than 20 years. Children with lower weight are at higher risk of severe dengue.⁶⁻¹⁰

Diagnosis can be confirmed by direct laboratory tests like dengue virus isolation, dengue virus nucleic acid detection, NS1 antigen detection, or with indirect relatively less specific tests by checking antibodies. Sensitivity of each test depends on the duration of illness and the timing of the test. Virus isolation and nucleic acid tests although are highly specific are costly and labor intensive. These tests are usually employed for early detection of virus in the first week of illness. Immunoglobulin (Ig)M can be detected as early as 4 days after the onset of illness. The diagnosis is however confirmed by IgM seroconversion between paired acute and convalescent phase (obtained 10-14 days after the acute phase) specimens. A fourfold or greater rise in antibody titer is diagnostic of acute dengue infection.⁵⁻¹⁰

4 | CONCLUSION

Vertical transmission of dengue virus occurs although rarely. Congenital dengue can occur when there is insufficient time for transfer of maternal protective antibodies to the fetus. Congenital dengue should be kept in differential diagnosis if a neonate presents with fever/rash/thrombocytopenia in dengue season. Serology and antigen should be done in both mother and baby which may help in diagnosis and management.

ACKNOWLEDGEMENTS

To our neonates who are our best teachers.

CONFLICT OF INTEREST

Nothing to declare.

AUTHOR CONTRIBUTIONS

SG, VC, NPG, VG, and AP: drafted this article. AP: did the critical appraisal of the manuscript. All authors accepted the final manuscript.

ETHICAL APPROVAL

Consent has been obtained from the parents.

DATA AVAILABILITY STATEMENT

All data are included in the case report.

ORCID

Aakash Pandita  <https://orcid.org/0000-0001-5890-0974>

REFERENCES

- Tein Dat T, Kotani T, Yamamoto E, Shibata K. Dengue fever during pregnancy. *Nagoya J Med Sci.* 2018;80:241-247.

2. Pouliot SH, Xiong X, Harville E, et al. Maternal dengue and pregnancy outcomes: a systematic review. *Obstet Gynecol Surv.* 2010;65(2):107-118. <https://doi.org/10.1097/OGX.0b013e3181cb8fbc>
3. Fernandez R, Rodriguez I, Borbonet E, Vazquez S, Guzman MG, Kasi G. Study of the relationship dengue-pregnancy in group of urban-mothers. *Pev Cubana Med Trop.* 1994;146:76-78.
4. Carles C, Peifter H, Talarmin A. Effect of dengue fever during pregnancy in French Guiana. *Clin Infect Dis.* 1999;28:637-640.
5. Thomas J, Thomas P, Reeba George C. Neonatal dengue case report. *Int J Contemp Pediatr.* 2017;4(6):2234-2236.
6. Carroll ID, Toovey S, Van Gompel A. Dengue fever and pregnancy - a review and comment. *Travel Med Infect Dis.* 2007;5:183.
7. Tan PC, Rajasingam G, Devi S, Omar SZ. Dengue infection in pregnancy: prevalence, vertical transmission, and pregnancy outcome. *Obstet Gynecol.* 2008;111:1111.
8. Barthel A, Gourinat AC, Cazorla C, et al. Breast milk as a possible route of vertical transmission of dengue virus? *Clin Infect Dis.* 2013;57:415.
9. Perret C, Chanthavanich P, Pengsaa K, et al. Dengue infection during pregnancy and transplacental antibody transfer in Thai mothers. *J Infect.* 2005;51:287-293.
10. Kerdpanich A, Watanaveeradej V, Samakoses R, et al. Perinatal dengue infection. *Southeast Asian J Trop Med Public Health.* 2001;32:488-493.

How to cite this article: Gupta S, Choudhury V, Gupta NP, Gupta V, Pandita A. Congenital dengue in neonate. *Clin Case Rep.* 2021;9:704–706. <https://doi.org/10.1002/ccr3.3627>