




Contents lists available at ScienceDirect

## International Journal of Surgery Case Reports

journal homepage: [www.casereports.com](http://www.casereports.com)

# Challenges and experiences in correcting scoliosis of a patient with Marfan Syndrome: A case report

Singkat Dohar Apul Lumban Tobing, Danar Lukman Akbar\*

Department of Orthopaedic & Traumatology, Cipto Mangunkusumo National Central Hospital and Faculty of Medicine, Universitas Indonesia, Jalan Diponegoro No. 71, Jakarta Pusat, Jakarta, 10430, Indonesia

## ARTICLE INFO

## Article history:

Received 22 May 2020

Received in revised form

13 September 2020

Accepted 22 September 2020

Available online 28 September 2020

## Keywords:

Marfan Syndrome  
Scoliosis correction  
Case report

## ABSTRACT

**INTRODUCTION:** Although common, it is not always easy to treat scoliosis in Marfan Syndrome. The distinguished anatomical components make it harder to treat the entity, albeit managing the whole patient. It is already widely known that the correction requires an immersive preoperative planning as well as a vast surgeon experience in order to preparedly face the possible that may happen intra operatively and post operatively.

**CASE PRESENTATION:** We present a case of patient with Marfan's syndrome presenting to our outpatient clinic with scoliosis deformity since 4 years ago. Patient also had cardiovascular problems. At the time of visitation, patient had a main thoracic Cobb Angle of 87.5° and lumbar Cobb Angle of 76.7°.

**RESULT:** We did a one-step surgical correction of scoliosis. We managed to acutely correct the scoliosis and maintain the correction by using a posterior stabilization. Afterwards patient was well conditioned and was discharged around 6 days later. The follow up was good, patient had no neurological deficits, and was able to walk without walker after 1 month.

**DISCUSSION:** Marfan Syndrome with scoliosis requires a good preoperative planning so that we may avoid unnecessary complications. It is still possible to do an acute correction for scoliosis that is severe and still maintain little to no complications rate.

© 2020 The Author(s). Published by Elsevier Ltd on behalf of IJS Publishing Group Ltd. This is an open access article under the CC BY-NC-ND license (<http://creativecommons.org/licenses/by-nc-nd/4.0/>).

## 1. Introduction

Marfan's syndrome is a systemic disorder of connective tissue caused by mutations in the extracellular matrix protein fibrillin 1. Manifestation of Marfan's syndrome include proximal aortic aneurysm, dislocation of the ocular lens, and musculoskeletal abnormality. The incidence of classic Marfan's syndrome is about 2–3 per 10,000 individuals. Arachnodactyly (overgrowth of the fingers) is generally a subjective finding. The combination of long fingers and loose joints leads to the characteristic Walker-Murdoch and the steinberg or thumb sign [1]. The other musculoskeletal abnormalities in Marfan's syndrome is scoliosis. It affects around 60% of Marfan's syndrome patients and there may be rapid progression during growth spurts, leading to marked deformity, pain, and restricted ventilatory condition [1].

Treatment of scoliosis in Marfan's syndrome patient include operative and nonoperative. In non-operative treatment, Milwaukee brace is indicated for patient with flexible progressive curves between 25 and 40 degrees that have no associated thoracic lordosis and lumbar kyphosis [2]. Cobb angle approximately 45 or more

and causes symptom and need surgical treatment. But indications vary widely according to the preference of the treating surgeon. Marfan's syndrome-associated scoliosis, has been reported satisfactory result by posterior instrumentation alone [3]. This case report had been reported in line with SCARE criteria [4].

## 2. Presentation of case

### 2.1. Patient information

We presented a 15 years old girl with curved back since 4 years before hospital admission. At first the curvature was not severe and patient did not seek medical attention. Four years later, the curve became worsened, and the patient sought medical attention. She complaint of shortness of breath, back pain and fatigue. Patient couldn't stand for a long period. No history of neurological deficit, defecation, and urinal problem was present.

### 2.2. Clinical findings

Patient had high stature and positive Steinberg and also Walker-murdoch signs. A curved back was present with right thoracic curve and left lumbar curve, with rib hump and no step off. There was no tenderness.

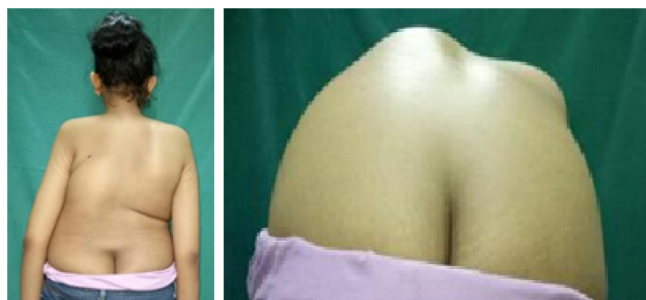
\* Corresponding author.

E-mail address: [danarla.orthopaedic@yahoo.com](mailto:danarla.orthopaedic@yahoo.com) (D.L. Akbar).

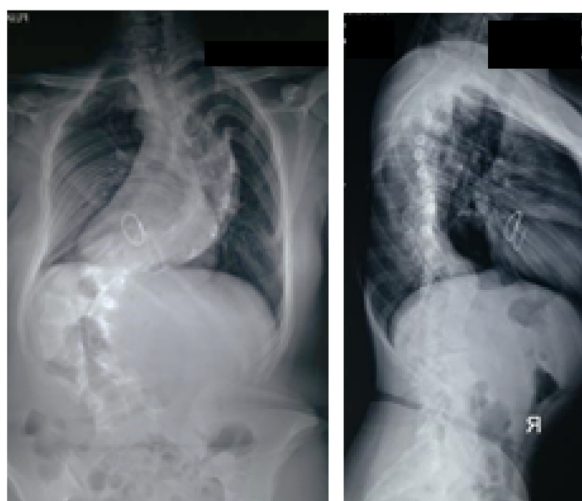
**Table 1**  
Preoperative Radiographic Findings.

	Cobb angle	UEV*	LEV*	Apex
Proximal thoracic	36.37°	Thoracal 1	Thoracal 4	Thoracal 3
Main thoracic	87.5°	Thoracal 4	Thoracal 11	Thoracal 7
Lumbal	76.7°	Thoracal 11	Lumbar 4	Lumbar 2
Risser	R4			

\* UEV: upper end vortex, LEV: lower end vortex.



**Fig. 1.** Clinical Manifestation of the Patient.



**Fig. 2.** Preoperative Radiographic Examination.

2.3. Timeline

Time	Symptom and Signs	Treatment
4 years before hospital admission	Curved back. No findings because patient did not seek medical attention	No treatment
1 month before hospital admission	Back pain, shortness of breath, fatigue, could not stand for long period, high stature, positive Steinberg and Walker-murdoch signs, curved back	One-step surgical correction of scoliosis and posterior stabilization

2.4. Diagnostic assessment

The forward flexion was 0–60°, extension was 0–25°, right lateral bending was 0–40° and left lateral bending was 0–40°. The standing height of the patient was 162 cm and the sitting height was 75.5 cm. The radiological parameter is shown on Table 1.

We diagnosed the patient to have neuromuscular scoliosis associated with Marfan's syndrome (Figs. 1 and 2).

**Table 2**  
Preoperative and postoperative comparison of Cobb's angle.

	Pre-operative	Post-operative	Difference
Proximal thoracic	36.37°	8.2°	28.17°
Main thoracic	87.5°	72°	15.5° (17.71%)
Lumbal	76.7°	110°	33.3°

**Table 3**  
Preoperative and postoperative comparison of clinical manifestation.

	Pre-operative	Post-operative
Standing Height	162 cm	170 cm
Sitting Height	75.5 cm	114 cm

2.5. Therapeutic intervention

Scoliosis correction and posterior stabilization was performed to the patient. Before the surgery, we consulted to the pediatrician for cardiopulmonary function. This was the step for perioperative preparation. The surgery was performed by the first author (SDALT). The surgical technique consists of 6 steps, as shown in Fig. 3. In the first step, the incision design was made. In the next step, after layer by layer incision, the whole spine was exposed and spinal deformity could be seen clearly. In the third step, the pedicle screws were inserted into thoracal 2, 3, 6, 7, 8, 11, 12 and lumbar 4 and lumbar 5. The pedicles were around 4.5–5.5 mm in diameter. Cross-link was inserted at the level of L2. Facetectomy and release of interspinous ligament was done to further free the vertebral body in the fourth step. In the fifth step, rod was placed afterwards. Translational and rotational correction was done. In the last step, final result exposed. Wound was closed layer by layer to the skin. A drain was applied.

Intraoperatively the blood loss was 1,600 cc, with additional transfusion of 400 cc of packed red cell and 200 cc of fresh frozen plasma. Intra-operative cell salvage was used for 200 cc autotransfusion.

2.6. Follow up and outcomes

After the surgery, the patient was evaluated for the hemodynamic condition in pediatric intensive care unit for 1 day. Three days post-operative, she was able to stand on both of her leg and walked with the help of assisted walking device. A month after the surgery, the patient was able to walk without assisted walking device and has no complaint of shortness of breath.

From the post-operative x-ray, we could see improvement of the Cobb's angle (Table 2). The Proximal thoracic Cobb's angle improved from 36.37° to 8.2° (28.17° of improvement). The main thoracic Cobb's angle was improved from 87.5° to 72° (17.71% improvement). (Fig. 4). The postoperative coronal balance is neutral, whereas the sagittal balance is positive (78.68 mm).

We could see the improvement also in the clinical condition. The patient's pre-operative standing height was 162 cm, corrected to 170 cm. Her sitting height was 75.5 cm, corrected to 114 cm (Fig. 5 and Table 3).

3. Discussion

The classic spinal deformities in Marfan's syndrome include increased vertebral scalloping, a higher prevalence of lumbosacral transitional vertebrae, lengthened process distance and a reduction in pedicle width and laminar thickness. The prevalence of Scoliosis in Marfan's syndrome is 63% [2]. Marfan's syndrome is a multisystem disease. The manifestations are seen in cardiovascular and musculoskeletal system. The patient complained shortness of breath, which probably manifested due to her scoliosis. After the

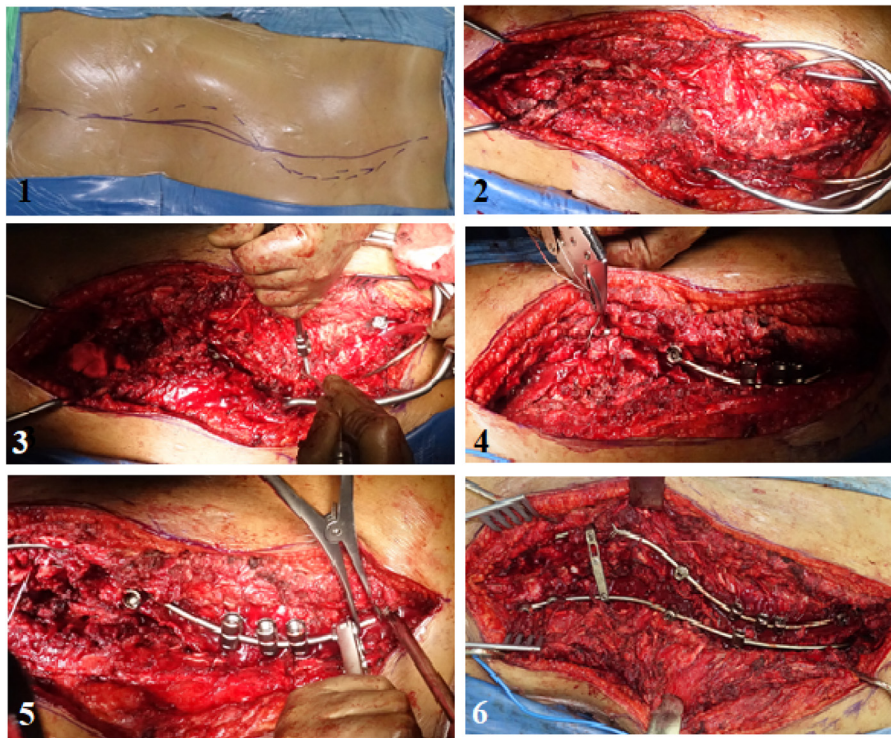


Fig. 3. Surgical Techniques.

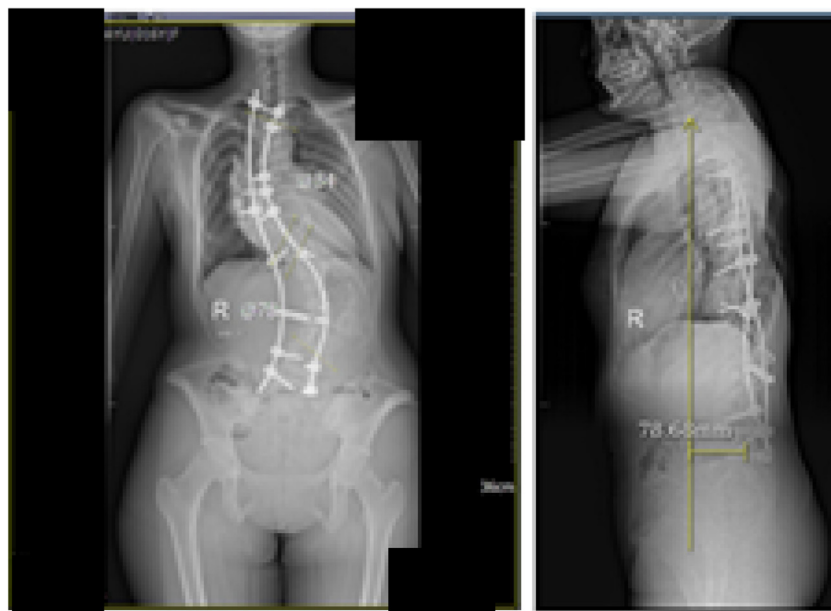


Fig. 4. Postoperative Radiographic Examination.

correction, the complaint gradually diminished. Few weeks after surgery, no more shortness of breath was observed. She could continue her daily activity as a student [5].

The curvature between 20° and 40° is recommended for the use Milwaukee brace. It needs observation every 3–4 months. If the progression occurs and the curve exceeds 40 degrees, it needs surgical treatment. Cardiopulmonary problem due to the progression of the curve, also needs surgical correction [6]. After the surgery thoracic curve achieved 72° (17.71%) correction. It is useful to aim the correction to get a clinically well-balanced spine rather than maximum intraoperative correction [5].

Idiopathic scoliosis is a three-dimensional deformity of the torso consisting of lateral curvature of the spine and vertebral rotation. Satisfactory treatment for AIS includes adequate restoration of the sagittal spinal alignment and vertebral rotation, and maximum correction in the coronal plane. The C7 plumb line is the most commonly used index of global balance. This parameter identified by measuring the position of a vertical line originating in the center of the C7 vertebral body with respect to the posterior superior corner of S1. This C7 plumb line was a stable, reliable index of sagittal balance, being maintained in narrow ranges for alignment of the spine over the pelvis and femoral heads [7]. The sagittal balance is

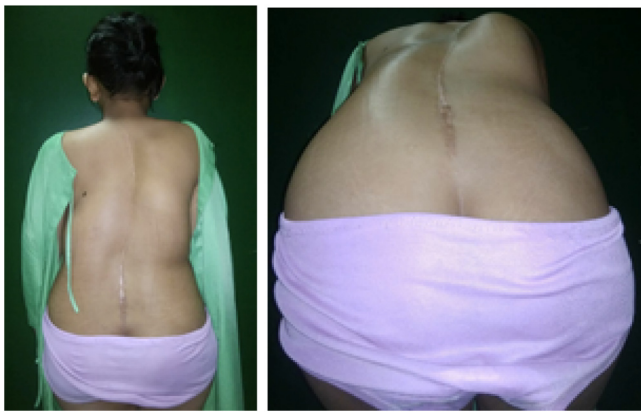


Fig. 5. Postoperative Clinical Manifestation.

assessed by the horizontal distance or misalignment of a vertical line passing from the center of C7 vertebral body to the posterolateral part of the S1 superior end plate. It was considered positive vs negative as it presented an anterior vs posterior deviation from the previously stipulated line. To assess coronal balance, a vertical line is drawn downwards from the midpoint of the C7 vertebral body. The horizontal distance between this plumb line and the midline of the sacrum or central sacral vertical line is measured and the position of this line is then named positive, neutral or negative, depending on the distance and direction from the midline [7]. The C7 was chosen as a reference point over T1 because of the visibility on lateral radiographs. The plumb line dropped from C7 vertebra (C7PL) is ideally located at the posterior edge of the sacral plateau, and this position is deemed very stable, while displacement in front or behind this point shows an unstable situation [8].

The goals of surgery in idiopathic scoliosis include maintaining a well balanced spine in coronal and sagittal planes, centering the fusion mass in the midline at the proximal and distal aspect and having the lowest instrumented vertebrae in an optimal coronal, sagittal, and axial orientation [9].

The spine is a complex structure balanced by multiple forces that implement structural changes in an attempt to compensate the sagittal and coronal vertical axis, so that the human being maintains as balanced a movement as possible. Sagittal balance can be maintained through three main compensatory mechanisms, which may occur in the spine, pelvis and/or lower limb areas, including reduction of TK/ hyperextension of adjacent segments, pelvis retroversion (increase of PT and rotation of the pelvis), knee flexion and ankle extension. Hyperextension of the adjacent segments is a common compensatory mechanism in retaining sagittal balance, as pelvis retroversion, knee flexion and ankle extension may occur secondary to hyperextension of the adjacent segments of these are too rigid to extend or reach their limits. The coronal balance does not correlate with the other spine variables, possibly due to the small discrepancy of results found in the main population with idiopathic scoliosis. The sagittal balance seems to be much more influenced by the upper spine, specifically by the cervical spine shape and by the first 5 thoracic vertebrae. Idiopathic scoliosis correlates with hypokyphosis and a decrease in cervical lordosis, two parameters with a significant and negative influence on sagittal balance, which consequently decreases its value in a population with adolescent idiopathic scoliosis. A research by Pinto et al. did not present a statistically significant correlation between the sagittal balance and the lumbar lordosis or spinopelvic parameters. This may be because there is no relationship at all between these variables [7].

Assessing global sagittal balance in patients with scoliosis is extremely important, especially before surgery, because it can help

avoid complications of imbalance, the progression of deformity, adjacent segment disease, and pseudarthrosis. A balanced posture is achieved when the spine and pelvis are aligned in a way that provides horizontal gaze with minimal energy output [8].

Global alignment (positive SVA) of less than 4 cm is an ideal alignment for reducing operative intervention procedures and postoperative pain and disability. SVA (sagittal vertical axis)-should be within 46 mm [10]. Sagittal balance is a parameter that is influenced by multiple factors. In fact, it is closely related to the cervical shape and the upper thoracic spine (from T1 to T5), which in turn, is in symbiosis with the severity of scoliotic curvature [7]. This is considered within the tolerable range for health-related quality of life outcomes. However, as patients age, they lean forward and tolerate slightly more positive sagittal alignment. Our study showed significant improvement in both clinical and radiological outcomes particularly Cobb angle of the patient, showing the surgery is successful. The final sagittal balance in this patient is measured as positive, with the value of more than normal (78.68 mm). however, as mentioned before, the sagittal balance is influenced by multiple factors and it is closely related to the severity of the scoliosis before correction takes place.

#### 4. Conclusion

Scoliosis in Marfan Syndrome is a common deformity. It can cause shortness of breath We present a Marfan's syndrome patient with spinal manifestation that was underwent surgical correction by posterior approach. The procedure is important to improve the physiological outcome for the patient. Our study showed significant improvement in both clinical and radiological outcomes particularly Cobb angle of the patient, showing the surgery is successful. The final sagittal balance in this patient is measured as positive, with the value of more than normal (78.68 mm). however, as mentioned before, the sagittal balance is influenced by multiple factors and it is closely related to the severity of the scoliosis before correction takes place.

#### Patient perspective

Patient understands about the goal of the treatment given.

#### Declaration of Competing Interest

The authors certify that They have NO affiliations with or involvement in any organization or entity with any financial interest or non-financial interest in the subject matter or materials discussed in this manuscript.

#### Funding

The authors received no financial support for the research, authorship, and/or publication of this article.

#### Ethical approval

The ethical approval was not required for this case report. It is not first in man.

#### Consent

Written informed consent was obtained from the patient for publication of this case report and accompanying images. A copy of the written consent is available for review by the Editor-in-Chief of this journal on request.

**Author contribution**

Singkat Dohar Apul Lumban Tobing: study concept, data collection, data interpretation, and writing the paper, guarantor.

Danar Lukman Akbar: data collection, data interpretation and writing the paper.

**Registration of research studies**

N/A.

**Guarantor**

None.

**Provenance and peer review**

Not commissioned, externally peer-reviewed.

**Acknowledgements**

Authors would like to give their biggest gratitude to the Department of Orthopaedic and Traumatology, Universitas Indonesia and Cipto Mangunkusumo Hospital for making this case report deliverable.

**References**

- [1] D.P. Judge, H.C. Dietz, Marfan's syndrome, *Lancet* 366 (366) (1986) 1965–1976.
- [2] C.A. Demetracopoulos, P.D. Sponseller, Spinal deformities in Marfan Syndrome, *Orthop. Clin. North Am.* 38 (4) (2007) 563–572.
- [3] S. Negrini, S. Minozzi, N. Chockalingam, G. Tb, T. Kotwicki, T. Maruyama, et al., Braces for idiopathic scoliosis in adolescents (review) summary of findings for the main comparison, *Cochrane Database Syst. Rev.* Braces (6) (2015).
- [4] R.A. Agha, M.R. Borrelli, R. Farwana, K. Koshy, A.J. Fowler, D.P. Orgill, et al., The SCARE 2018 statement: updating consensus surgical CAsE RReport (SCARE) guidelines, *Int. J. Surg.* 60 (2018) 132–136.
- [5] J. Zenner, W. Hitzl, O. Meier, A. Auffarth, H. Koller, Surgical outcomes of scoliosis surgery in marfan syndrome, *J. Spinal Disord. Tech.* 27 (1) (2014) 48–58.
- [6] T. Juvenile, C.S. Spinal, P. Spinal, Natural E. Scoliosis and Kyphosis, 2019.
- [7] E.M. Pinto, J. Alves, A. Teixeira, A. Miranda, Sagittal balance in adolescent idiopathic scoliosis, *Coluna/Columna* 18 (3) (2019) 182–186.
- [8] O. Kubat, D. Ovidia, Frontal and sagittal imbalance in patients with adolescent idiopathic deformity, *Ann. Transl. Med.* 8 (2) (2020), 29–29.
- [9] C.L. Hamill, L.G. Lenke, K.H. Bridwell, M.P. Chapman, K. Blanke, C. Baldus, The use of pedicle screw fixation to improve correction in the lumbar spine of patients with idiopathic scoliosis: is it warranted? *Spine* 21 (1996) 1241–1249.
- [10] P. Bakarania, Sagittal Alignment in Spinal Deformity: Implications for the Non-Operative Care Practitioner, Intech, 2012, <http://dx.doi.org/10.1016/j.colsurfa.2011.12.014>, 13. [Internet]. Available from: <https://www.intechopen.com/books/advanced-biometric-technologies/liveness-detection-in-biometrics%0A>.

**Open Access**

This article is published Open Access at [sciencedirect.com](https://www.sciencedirect.com). It is distributed under the [IJSCR Supplemental terms and conditions](#), which permits unrestricted non commercial use, distribution, and reproduction in any medium, provided the original authors and source are credited.