



CASE REPORT

Disseminated lung cancer presenting as a rectal mass

Mia M. Noergaard¹, Inger M. H. Stamp² and Uffe Bodtger^{1,3*}

¹Department of Pulmonology, Naestved Hospital, Naestved, Denmark; ²Department of Pathology, Naestved Sygehus, Naestved, Denmark; ³Institute of Regional Health Research, University of Southern Denmark, Odense, Denmark

Primary lung cancer is the leading cause of cancer-related deaths globally, and approximately 50% had metastatic disease at the time of diagnosis. A rectal mass and unintended weight loss are common manifestations of rectal cancer. Our case presented with a rectal mass, but workup revealed a metastatic lesion from lung cancer. Lung cancer metastases to the lower gastrointestinal tract imply reduced survival compared with the already poor mean survival of stage IV lung cancer. Despite relevant therapy, the patient died 5 months after referral.

Keywords: *non-small cell lung cancer; endoscopy; diagnosis; rectum; histology*

*Correspondence to: Uffe Bodtger, Department of Pulmonology, Naestved Hospital, 61 Ringstedgade, DK-4700 Naestved, Denmark, Email: Ubt@regionsjaelland.dk

Received: 25 March 2016; Accepted in revised form: 25 August 2016; Published: 27 September 2016

Primarily lung cancer is the leading cause of cancer-related deaths globally. Metastatic disease at diagnosis is very common, typically involving liver, brain, adrenals, and bones. Symptomatic intestinal/colonic metastases affect 0.2–0.5% (5% in autopsy studies) but imply a median survival of 3 months compared with 8 months in overall stage IV non-small cell lung cancer (1, 2). This case presented with a rectal mass, a common clinical manifestation of another common malignancy, colorectal cancer. The case illustrates the unpredictability of malignant spread, and the occasional mismatch between clinical presentation and tissue sampling results.

Case presentation

A 70-year-old male never-smoker experienced an 8-kg weight loss during 6 months, alternating diarrhoea/obstipation without bloody stools, slight coughing, and dyspnoea. He had a history of hypertension for many years, uncomplicated and treated with losartan/thiazide 50/12.5 mg and amlodipine 10 mg once daily. Nine years earlier, he was diagnosed with a transitiocellular, papillary bladder tumour, grade III with invasion; underwent successful endoscopic resection without need for oncological treatment; and was followed with annual cystoscopy. Three years later, he was surgically treated for a relapse of transitiocellular, papillary bladder tumour (grade I) and was followed for an additional 5 years without signs of recurrent disease at annual cystoscopy.

He was a retired industrial worker but with no known occupational exposure to asbestosis, silica, or dust. He

was living with his spouse and had no hobbies resulting in exposure to hazardous fumes or dusts.

Diagnostic workup

He was referred to an outpatient colonoscopy (17 months after he ended urological control visits), revealing an obstructing lower rectal mass. Only a paediatric coloscope could pass the lesion, and biopsies revealed adenocarcinoma, immunohistochemical (IHC) analyses positive for CK7 and TTF-1 (Fig. 1), and negative for GATA, CK20, CDX2, PLAP, CD117, PSA, and S100P. PCR showed wild-type EGFR status. Direct histological comparison showed no resemblance with his urological cancer.

Thoracoabdominal contrast-enhanced PET-CT scan showed multiple, PET-positive, enlarged mediastinal and retroperitoneal lymph nodes, a right-sided pleural effusion and associated ipsilateral compression lower lobe atelectasis, ascites, and a tumour located in the rectum with invasion to levator muscles and vesicula seminalis (Figs. 2 and 3). Cytological sampling from mediastinal lymph nodes and pleural exudate showed identical adenocarcinoma including IHC profile cells with a high proliferation index assessed by Ki-67. A bronchoscopy showed no visual tumour.

At a multidisciplinary team conference, it was decided that the final diagnosis was primary lung cancer, stage TxN3M1b with local metastases to mediastinal lymph nodes, pleura, rectum, and peritoneum. The IHC results were considered to rule out primary colorectal cancer or vesical cancer with thoracic dissemination.

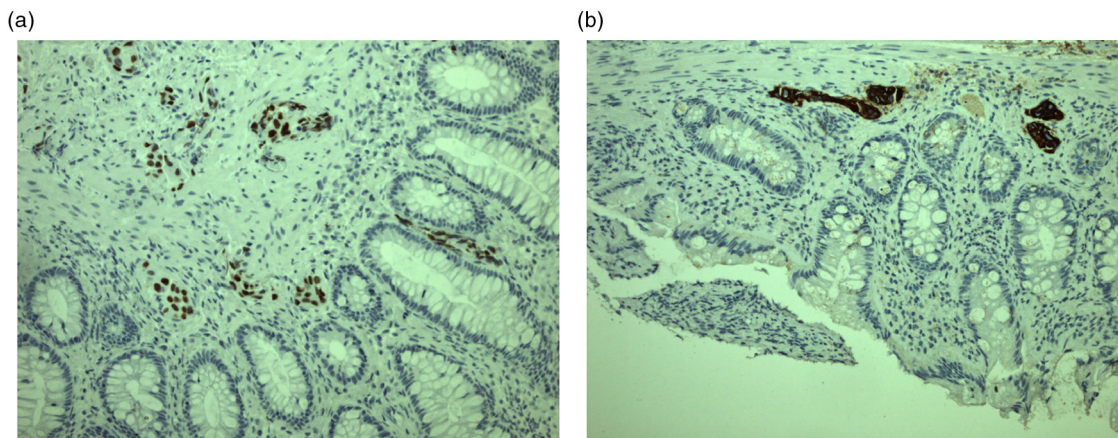


Fig. 1. Immunohistochemical staining of histological biopsy from rectal mass: an adenocarcinoma positive for TTF-1 (A) and CK7 (B).

He started palliative carboplatin/vinorelbine and avastin (43 days after referral to gastroenterologist) as 4 series with 3 weeks intervals. Three-month PET-CT showed a mixed response with an overall sign of progression, and second-line chemotherapy was planned. Before onset, he was admitted with acute dyspnoea and died 2 days later.

Discussion

The current case describes a rare site of primary lung cancer metastasis with fatal outcome 153 days after referral. Despite an unusual presentation, neither diagnosis nor therapy onset was delayed.

One can question the validity of the diagnosis as the patient was a never-smoker without evident lung lesions. However, as three key IHC markers for colorectal cancer were negative, positive CK7 and TTF-1, and no upper G-I CT/PET lesions, neither a primary upper or lower

G-I cancer seems likely (3). We found three published case reports on rectal metastases from lung cancer: two were late metastases in earlier surgically resected patients (4, 5), and a recently published case on metastatic, poorly differentiated squamous cell lung carcinoma with multiple metastases to liver, skin, bone, and muscle (6).

It is unresolved if intestinal spread reflects a more aggressive or more advanced disease. G-I metastasis may occur through haematogenic spread via the mesenteric inferior artery supplying descending colon, sigmoideum and superior part of rectum (7, 8). Yet, cancer metastasis is complex, involving coordination of expression/suppression of numerous genes, and is not fully understood. IL-8 overexpression may contribute to a more aggressive phenotype yet our case was negative for CK20, the IL-8 receptor (9).

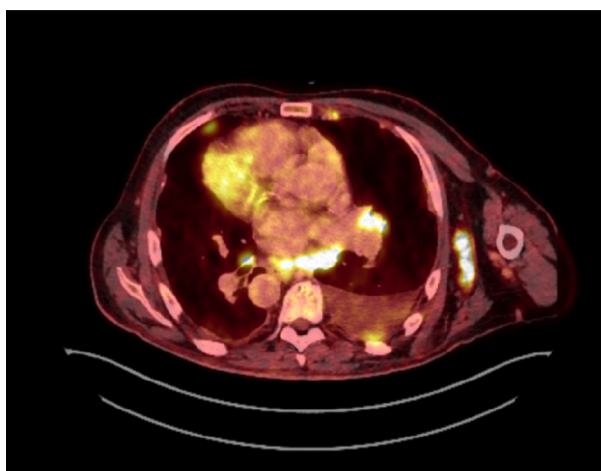


Fig. 2. Chest PET-CT scan showing no sign of a primary lung lesion but multiple enlarged lymph nodes, a left-sided compression atelectasis, and ipsilateral pleural effusion.

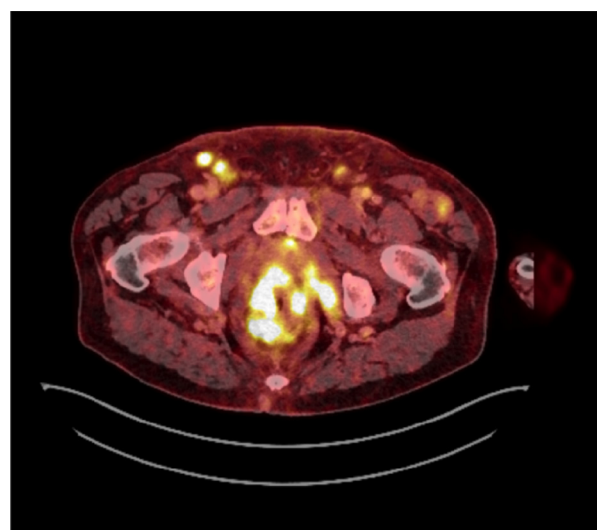


Fig. 3. Abdominal PET-CT scan showing a rectal mass, moderate quantities of ascites, and enlarged lymph nodes in pelvis and groin.

Improved survival after intestinal single-metastasis resection has been demonstrated in carefully selected patients, but for most patients with intestinal metastases, palliation remains the only available therapy (10).

An improved understanding of the pathobiological mechanisms involved in cancer metastases is needed to elucidate targets for improved therapy.

Conflict of interest and funding

The authors have not received any funding or benefits from industry or elsewhere to conduct this study.

References

1. Mehta RS, Liman AD, Passero VA, Liman AK. Lung cancer with gastrointestinal metastasis – review of theories of metastasis with three rare case descriptions. *Cancer Microenviron*. 2013; 6: 203–11. doi: <http://dx.doi.org/10.1007/s12307-013-0135-1>
2. Kim MS, Kook EH, Ahn SH, Jeon SY, Yoon JH, Han MS, et al. Gastrointestinal metastasis of lung cancer with special emphasis on a long-term survivor after operation. *J Cancer Res Clin Oncol*. 2009; 135: 297–301. doi: <http://dx.doi.org/10.1007/s00432-008-0424-0>
3. Miura K, Ishida K, Fujibuchi W, Ito A, Niikura H, Ogawa H, et al. Differentiating rectal carcinoma by an immunohistological analysis of carcinomas of pelvic organs based on the NCBI Literature Survey and the Human Protein Atlas database. *Surg Today*. 2012; 42: 515–25. doi: <http://dx.doi.org/10.1007/s00595-012-0167-z>
4. Miyazu K, Kobayashi K. Rectal metastasis from lung cancer; report of a case. *Kyobu Geka*. 2012; 65: 165–7.
5. Martinez GE, Coursey CA, Dodd L, Martinez S. Simultaneous thigh muscle metastasis from lung cancer and *Escherichia coli* gas producing myonecrosis. *Skeletal Radiol*. 2008; 37: 763–6. doi: <http://dx.doi.org/10.1007/s00256-008-0489-5>
6. Win AZ, Aparici CM. A case of metastatic rectal squamous cell carcinoma initially diagnosed as lung cancer. *J Clin Imaging Sci*. 2015; 5: 22. doi: <http://dx.doi.org/10.4103/2156-7514.156125>
7. Kabwa L, Mattei JP, Noël JP. Intestinal metastases of bronchopulmonary cancer. Apropos of a case. *J Chir (Paris)* 1996; 133: 290–3.
8. Pezzuto A, Mariotta S, Fioretti F, Uccini S. Metastasis to the colon from lung cancer presenting with severe hyponatremia and dyspnea in a young male: a case report and review of the literature. *Oncol Lett*. 2013; 5: 1477–80.
9. Sunaga N, Imai H, Shimizu K, Shames DS, Kakegawa S, Girard L, et al. Oncogenic KRAS-induced interleukin-8 overexpression promotes cell growth and migration and contributes to aggressive phenotypes of non-small cell lung cancer. *Int J Cancer*. 2012; 130: 1733–44. doi: <http://dx.doi.org/10.1002/ijc.26164>
10. Fujiwara A, Okami J, Tokunaga T, Maeda J, Higashiyama M, Kodama K. Surgical treatment for gastrointestinal metastasis of non-small-cell lung cancer after pulmonary resection. *Gen Thorac Cardiovasc Surg*. 2011; 59: 748–52. doi: <http://dx.doi.org/10.1007/s11748-011-0811-3>