

## Case Report

# Spontaneous Concomitant Intracranial and Spinal Subdural Hematomas in Association with Anticoagulation Therapy

Ui Suk Wang, M.D.,<sup>1</sup> Chang Il Ju, M.D., Ph.D.,<sup>1</sup> Seok Won Kim, M.D., Ph.D.,<sup>1</sup> Sung Hoon Kim, M.D., Ph.D.<sup>2</sup>

*Department of Neurosurgery,<sup>1</sup> School of Medicine, Chosun University, Gwangju, Korea*

*Department of Rehabilitation,<sup>2</sup> Wonju College of Medicine, Yonsei University, Wonju Christian Hospital, Wonju, Korea*

Simultaneous intracranial and spinal subdural hematomas are extremely rare. In most cases, they are attributed to major or minor trauma and iatrogenic causes, such as those resulting from spinal puncture. To the best of the authors' knowledge, there has been only two reports of spontaneous concomitant intracranial and spinal subdural hematomas in a patient receiving anticoagulant therapy who had an absence of evident trauma history. We report on a case of spontaneous concomitant intracranial and spinal subdural hematomas that occurred in association with anticoagulant therapy and present a review of the relevant literature.

**Key Words :** Cranial · Spinal · Subdural hematoma · Anticoagulant therapy.

## INTRODUCTION

A spinal subdural hematoma (SDH) is a rare clinical entity that accounts for only 4.1% of all spinal hematomas. It can be caused by major or minor trauma and iatrogenic injuries, such as those resulting from spinal punctures performed for diagnostic or anesthetic purposes<sup>5</sup>. Simultaneous intracranial and spinal SDHs are rare and may be a distinct subgroup, and only 12 cases have been reported in English literature<sup>1-3,6,7,9-14</sup>. Among them, only two cases of spontaneous concomitant cranial and spinal SDHs were reported in a patient receiving anticoagulant therapy who did not have a history of antecedent head or back injuries or lumbar spinal puncture<sup>3</sup>. Here, we report on a case of patient with a spontaneous nontraumatic spinal SDH that occurred with a simultaneous intracranial subacute SDH. The pathophysiological mechanisms of this uncommon entity are discussed, and the relevant literature is reviewed.

## CASE REPORT

A 67-year-old female who complained of back pain and both

leg radiating pain was referred to our emergency room. She also complained of a severe bitemporal headache at the same time. During the previous 3 years, she had taken oral antiplatelet agents for atrial fibrillation. She was treated with combined low dose aspirin and 75 mg clopidogrel bisulfate (Plavix<sup>®</sup>) per day. Examination of blood tests had shown a platelet count of  $142 \times 10^3/\mu\text{L}$ , a prothrombin time of 10.4 sec (range 9.4-12.5), an international normalize ratio of 1.2 (range 0.9-1.27) and partial thromboplastin time of 40.2 sec (range 28.0-44.0). They were all within normal ranges. Upon physical examination, she was alert and fully oriented in spite of the severe headache. No neurologic abnormalities were found in the cranial nerves or cerebellar system. The neurological examination revealed slight motor weakness (Grade IV<sup>+</sup>) and numbness in the lower extremities. An immediate magnetic resonance imaging of the brain and spine revealed a subacute SDH in the left fronto-temporo-parietal area that was 8 mm at its thickest point and a well-circumscribed intradural lesion, which was isodense with the dural sac, that measured 8 mm at its maximum diameter and compressed the cauda equina at L4-S1. The intradural lesion showed high signal intensities on T1 weighted images and

• Received : August 19, 2011 • Revised : November 17, 2011 • Accepted : April 17, 2012

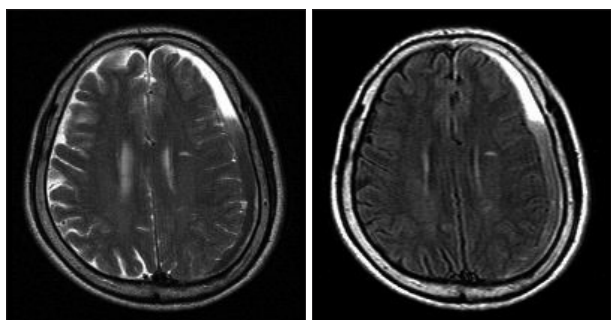
• Address for reprints : Seok Won Kim, M.D., Ph.D.

Department of Neurosurgery, School of Medicine, Chosun University, 365 Pilmun-daero, Dong-gu, Gwangju 501-717, Korea

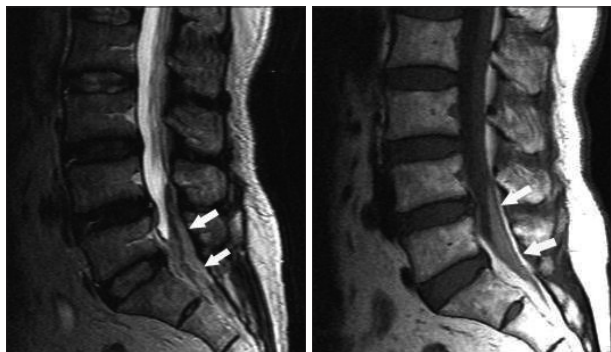
Tel : +82-62-220-3126, Fax : +82-62-227-4575, E-mail : ns64902@hanmail.net

• This is an Open Access article distributed under the terms of the Creative Commons Attribution Non-Commercial License (<http://creativecommons.org/licenses/by-nc/3.0>) which permits unrestricted non-commercial use, distribution, and reproduction in any medium, provided the original work is properly cited.

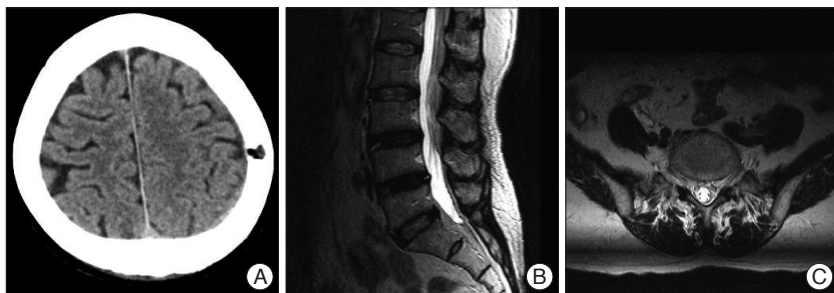
low signal intensities on T2 weighted images. No contrast enhancement was seen on fat-suppressed T1-weighted images (Fig. 1, 2). These findings confirmed that the hematoma was localized in the subdural space. Based on these magnetic resonance (MR) findings, the patient was diagnosed with concomitant cranial and spinal SDHs. The level of headache fluctuated and was resistant to medical treatment. The hematoma was evacuated under local anesthesia through one burr hole using a 5-L catheter 7 days after admission. The headache improved immediately after the hematoma evacuation. The spinal SDH was treated conservatively. To distinguish this case from other conditions for differential diagnosis, a lumbar spinal puncture was performed at L5-S1 level. The cerebrospinal fluid (CSF) analysis revealed 190000 red blood cells/mm<sup>3</sup> and 267 white



**Fig. 1.** Radiological findings of brain (pretreatment). T2 and fluid-attenuated inversion recovery magnetic resonance images show mixed signal intensity spinal subdural hematoma in left fronto-temporo-parietal area.



**Fig. 2.** Radiological findings of spine (pretreatment). T2 and T1 weighted sagittal images reveal intradural lesion compressing the cauda equina at L4-S1 level (arrows).



**Fig. 3.** Radiological findings after treatment. A : Brain computed tomographic scan taken 14 days after hematoma drainage shows complete removal of hematoma. B and C : Magnetic resonance images taken 14 days after admission reveals complete resolution of hematoma.

blood cells/mm<sup>3</sup>. A brain computed tomographic scan and lumbar spine MR images taken 14 days after admission revealed that the spinal SDH had completely resolved (Fig. 3). The patient was in good health and free of neurological deficits during the 12-month follow-up period.

## DISCUSSION

Unlike the cranial counterpart, the spinal subdural space lacks the bridging veins that act as an origin for a SDH. The lower incidence of SDH in the spine has been attributed to the protection of the spinal subdural space by the vertebrae and broad paravertebral muscles and to the rare passage of blood vessels, such as bridging veins, through the subdural space<sup>3,14</sup>. Moreover, a concomitant intracranial and spinal SDH is extremely rare, and, to the best of the authors' knowledge, a total of 13 cases of the concomitant occurrence of intracranial and spinal SDHs have been reported so far in the English literature (Table 1). Among them, most cases were attributed to head injury or changes of CSF hydrodynamics, and there has been only two reports, including our report, associated with anticoagulation in the absence of trauma<sup>3,4</sup>. When using antiplatelet agents, the ADP receptor antagonists prevent ADP-induced fibrinogen binding to platelets, a necessary step in the platelet aggregation process. They would not influence the coagulation profiles of our patient, so the patient's coagulation status remained normal. The exact etiology of the simultaneous occurrence of intracranial and spinal SDHs has not been clearly elucidated. The spinal subdural hematoma may be caused by a rupture in the spinal vessels. Initial hemorrhage in the subarachnoid space is thought to be the primary lesion that eventually dissects into the subdural space, and the subarachnoid hemorrhage is washed out by cerebrospinal flow<sup>3</sup>. However, the causal relationship between cranial and spinal bleeding is not clearly documented by this theory. Hung et al.<sup>2</sup> hypothesized that a rise of intracranial pressure may also increase shearing force between spinal subdural and subarachnoid spaces so that the inner dura may tear and bleed. It may then migrate from the cranial lesion. Either high or low intracranial pressure has been proposed as a predisposing factor for this migration. Raised intracranial pressure due to brain swelling might displace the hematoma to the skull base or spinal canal<sup>3,15</sup>.

The anatomic continuity between the intracranial and spinal subdural spaces can be observed using an electron microscope<sup>8</sup>. A spinal SDH and an intracranial acute SDH could result from this phenomenon. In the present case, rebleeding might have occurred in the cranial lesion before the onset because MR imaging of the brain suggested that the hematoma was in the subacute phase on admission. A growing hematoma might have torn the membrane.

**Table 1.** Summary of the previous and present cases of spinal subdural hematoma (SDH) concomitant with intracranial SDH

Author (year)	Age/Sex	Cranial SDH	Level	MR imaging (T1WI/T2WI) signal intensity	Treatment of spinal SDH	Outcome	Predisposing factor	Trauma history
Silver and Wilkins (1991)	14/F	Chronic	T12-L2	NP/NP	Conservative	GR	VP shunt	×
Wurm et al. (1996)	16/M	Chronic	L3-S2	High/NM	Conservative	GR	VA shunt	×
Leber et al. (1997)	54/M	Chronic	L1-S2	High/NM	Surgery	GR	Chronic SDH	○
Shimizu et al. (1999)	52/F	Acute	L4-S2	High/iso	Conservative	GR	Craniotomy	×
Tillich et al. (1999)	54/M	Chronic	L1-S2	High/high	Surgery	GR	Chronic SDH	○
Ohta et al. (2001)	10/F	Chronic	L3-S2	High/high	Surgery	GR	VP shunt	×
Hung et al. (2002)	12/M	Acute	L1-L5	High/NM	Conservative	GR	Brain swelling	○
Lecouvet et al. (2003)	31/M	Acute	L1-S2	High/NM	Conservative	GR	Brain metastasis	×
Yamaguchi et al. (2003)	52/F	Acute	L1-S2	High/iso	Conservative	GR	CSF drainage	○
Bortolotti et al. (2004)	23/F	Acute	L1-S2	High/iso	Surgery	GR	Brain swelling	○
Yamaguchi et al. (2005)	59/M	Chronic	L4-S2	Iso/iso	Conservative	GR	Brain atrophy	×
Jimbo et al. (2006)	72/M	Chronic	L4-S2	High/low	Surgery	GR	Anticoagulation	×
Jain et al. (2008)	12/M	Chronic	C1-S3	High/high	Conservative	Death	Anticoagulation	×
Present case	67/F	Subacute	L4-S2	High/low	Conservative	GR	Anticoagulation	×

CSF : cerebrospinal fluid, GR : good recovery, MR : magnetic resonance, NM : not mentioned, NP : not performed, T1WI : T1-weighted image, T2WI : T2-weighted image, VA : ventriculoatrial, VP : vertriculoperitoneal

Oral antiplatelet therapy and brain atrophy with aging may have facilitated the rebleeding and migration of the hematoma. The limitation of this study is that even though we discard the possibility of a minor trauma and thoroughly educate the patient, there is not enough to rule out the possibility of chronic subdural hematoma due to an accidental minor injury to the head.

## CONCLUSION

Although rare, concomitant intracranial subacute SDH and spinal SDH should be included in the differential diagnosis of nerve root compression in a patient receiving anticoagulant therapy.

## References

- Bortolotti C, Wang H, Fraser K, Lanzino G : Subacute spinal subdural hematoma after spontaneous resolution of cranial subdural hematoma : causal relationship or coincidence? Case report. *J Neurosurg* **100** : 372-374, 2004
- Hung KS, Lui CC, Wang CH, Wang CJ, Howng SL : Traumatic spinal subdural hematoma with spontaneous resolution. *Spine (Phila Pa 1976)* **27** : E534-E538, 2002
- Jain V, Singh J, Sharma R : Spontaneous concomitant cranial and spinal subdural haematomas with spontaneous resolution. *Singapore Med J* **49** : e53-e58, 2008
- Jimbo H, Asamoto S, Mitsuyama T, Hatayama K, Iwasaki Y, Fukui Y : Spinal chronic subdural hematoma in association with anticoagulant therapy : a case report and literature review. *Spine (Phila Pa 1976)* **31** : E184-E187, 2006
- Kim HY, Ju CI, Kim SW : Acute cervical spinal subdural hematoma not related to head injury. *J Korean Neurosurg Soc* **47** : 467-469, 2010
- Leber KA, Pendl G, Kogler S, Kammerhuber F, Ebner F : Simultaneous spinal and intracranial chronic subdural hematoma. Case illustration. *J Neurosurg* **87** : 644, 1997
- Lecouvet FE, Annet L, Duprez TP, Cosnard G, Scordidis V, Malghem J : Uncommon magnetic resonance imaging observation of lumbar subdural hematoma with cranial origin. *J Comput Assist Tomogr* **27** : 530-533, 2003
- Nicholas DS, Weller RO : The fine anatomy of the human spinal meninges. A light and scanning electron microscopy study. *J Neurosurg* **69** : 276-282, 1988
- Ohta H, Ottomo M, Nakamura T : [A case of the spinal subdural hematoma formation following ventriculoperitoneal shunting for von Recklinghausen's disease associated with aqueductal stenosis]. *No Shinkei Geka* **29** : 53-57, 2001
- Shimizu S, Tachibana S, Maezawa H, Fujii K, Kan S : Lumbar spinal subdural hematoma following craniotomy--case report. *Neurol Med Chir (Tokyo)* **39** : 299-301, 1999
- Silver JM, Wilkins RH : Spinal subdural hematoma formation following ventriculoperitoneal shunting for hydrocephalus. Case report. *Acta Neurochir (Wien)* **108** : 159-162, 1991
- Tillich M, Kammerhuber F, Reittner P, Leber KA, Szolar DH : Chronic spinal subdural haematoma associated with intracranial subdural haematoma : CT and MRI. *Neuroradiology* **41** : 137-139, 1999
- Wurm G, Pogady P, Lungenschmid K, Fischer J : Subdural hemorrhage of the cauda equina. A rare complication of cerebrospinal fluid shunt. Case report. *Neurosurg Rev* **19** : 113-117, 1996
- Yamaguchi S, Hida K, Akino M, Yano S, Iwasaki Y : Spinal subdural hematoma : a sequela of a ruptured intracranial aneurysm? *Surg Neurol* **59** : 408-412; discussion 412, 2003
- Yamaguchi S, Kurisu K, Arita K, Takeda M, Tani I, Araki O : Simultaneous cranial and spinal subdural hematoma. *Neurol Med Chir (Tokyo)* **45** : 645-649, 2005