

# Changes of Serum Inflammatory Molecules and Their Relationships with Visual Function in Retinitis Pigmentosa

Ayako Okita,<sup>1</sup> Yusuke Murakami,<sup>1</sup> Shotaro Shimokawa,<sup>1</sup> Jun Funatsu,<sup>1</sup> Kohta Fujiwara,<sup>1</sup> Shunji Nakatake,<sup>1</sup> Yoshito Koyanagi,<sup>1</sup> Masato Akiyama,<sup>1,2</sup> Atsunobu Takeda,<sup>1,3</sup> Toshio Hisatomi,<sup>1,4</sup> Yasuhiro Ikeda,<sup>1,5</sup> and Koh-Hei Sonoda<sup>1</sup>

<sup>1</sup>Department of Ophthalmology, Graduate School of Medical Sciences, Kyushu University, Fukuoka, Japan

<sup>2</sup>Department of Ocular Pathology and Imaging Science, Graduate School of Medical Sciences, Kyushu University, Fukuoka, Japan

<sup>3</sup>Department of Ophthalmology, Clinical Research Institute, National Hospital Organization, Kyushu Medical Center, Fukuoka, Japan

<sup>4</sup>Department of Ophthalmology, Fukuoka University Chikushi Hospital, Fukuoka, Japan

<sup>5</sup>Department of Ophthalmology, Faculty of Medicine, University of Miyazaki, Miyazaki, Japan

Correspondence: Yusuke Murakami, Department of Ophthalmology, Graduate School of Medical Sciences, Kyushu University, Fukuoka 812-8582, Japan; [ymuraka3@med.kyushu-u.ac.jp](mailto:ymuraka3@med.kyushu-u.ac.jp)

Received: April 28, 2020

Accepted: August 30, 2020

Published: September 16, 2020

Citation: Okita A, Murakami Y, Shimokawa S, et al. Changes of serum inflammatory molecules and their relationships with visual function in retinitis pigmentosa.

*Invest Ophthalmol Vis Sci.* 2020;61(11):30.

<https://doi.org/10.1167/iovs.61.11.30>

**PURPOSE.** Retinal degeneration involves neuroinflammation, and pro-inflammatory cytokines/chemokines are markedly increased in the eyes of patients with retinitis pigmentosa (RP). In this study, we investigated the changes of serum cytokines/chemokines in RP, and their relationships with visual parameters.

**METHODS.** Forty-five consecutive patients with typical RP aged 20 to -39 years and 28 age-matched and gender-matched controls were included. Fifteen cytokines (interleukin [IL]-1 $\alpha$ , IL-1 $\beta$ , IL-2, IL-4, IL-5, IL-6, IL-10, IL-12p70, IL-13, IL-15, IL-17, IL-23, interferon [IFN]- $\gamma$ , and tumor necrosis factor [TNF]- $\alpha$ , TNF- $\beta$ ) and 9 chemokines (eotaxin, growth-related oncogene [GRO]- $\alpha$ , I-309, IL-8, IFN- $\gamma$ -inducible protein [IP]-10, monocyte chemoattractant protein [MCP]-1, MCP-2, regulated activation normal T-cell expressed and secreted [RANTES], and thymus and activated regulated chemokine [TARC]) in the serum were simultaneously measured by a multiplexed immunoarray (Q-Plex). Relationships between these cytokines/chemokines and indices of central vision, such as visual acuity (VA), the values of static perimetry tests (Humphrey Field analyzer, the central 10-2 program), and optical coherence tomography measures were analyzed in the patients with RP.

**RESULTS.** Among the 15 cytokines and 9 chemokines, serum IL-8 and RANTES levels were significantly increased in patients with RP compared with controls (IL-8:  $P < 0.0001$ ; RANTES:  $P < 0.0001$ ). Among the elevated cytokines/chemokines, the levels of IL-8 were negatively correlated with VA ( $\rho = 0.3596$  and  $P = 0.0165$ ), and the average retinal sensitivity of four central points ( $\rho = -0.3691$  and  $P = 0.0291$ ), and 12 central points ( $\rho = -0.3491$  and  $P = 0.0398$ ), as well as the central subfield thickness ( $\rho = -0.3961$  and  $P = 0.0094$ ), and ellipsoid zone width ( $\rho = -0.3841$  and  $P = 0.0120$ ).

**CONCLUSIONS.** Peripheral inflammatory response may be activated and serum IL-8 levels are associated with central vision in patients with RP.

Keywords: retinitis pigmentosa, cytokine/chemokine, inflammation, IL-8

Retinitis pigmentosa (RP) is a group of inherited diseases that cause progressive rod-cone degeneration, and a major cause of adult blindness that affects more than 1.5 million patients globally.<sup>1</sup> Over 80 different causal genes have been identified in patients with RP; however, the biological processes by which these mutations cause rod and subsequent cone cell death remain to be elucidated.<sup>1</sup>

Neuronal cell death and inflammation are tightly interconnected in neurodegenerative diseases, including RP. We and others previously showed that ocular inflammatory markers, such as inflammatory cells in the anterior

vitreous and aqueous flare values, are correlated with visual function defects in patients with RP.<sup>2,3</sup> In addition, experimental studies have revealed that retinal inflammation in RP is not just a passive response to photoreceptor cell death, but also actively modulates the disease progression in both protective and detrimental ways.<sup>4-6</sup>

Cytokines and chemokines are critical players for the regulation of innate and adaptive immune responses. We previously showed that the levels of pro-inflammatory interleukin (IL) 1- $\beta$ , IL-2, IL-4, IL-6, IL-8, interferon (IFN)- $\gamma$ , and monocyte chemoattractant protein 1 (MCP-1), as well

as anti-inflammatory IL-10 were substantially elevated in the vitreous of patients with RP,<sup>7</sup> suggesting that these cytokines/chemokines may mediate or regulate immune response in RP.

Although tissue-resident microglial cells appear to be the prominent population of retinal inflammatory cells in RP,<sup>8</sup> monocytes and lymphocytes also infiltrate into the retina from the peripheral blood.<sup>9</sup> We recently reported that the serum high-sensitivity C-reactive protein (hs-CRP) was elevated and correlated with the rate of visual sensitivity loss in patients with RP,<sup>10</sup> suggesting that not only local but also peripheral inflammatory response is activated and implicated in RP. Alterations in the levels of serum inflammatory cytokines have been reported in patients with age-related macular degeneration (AMD) and diabetic retinopathy (DR).<sup>11,12</sup> However, the changes of serum cytokines/chemokines in RP have not been fully explored.

In the present study, we measured 15 cytokines and 9 chemokines in the serum of patients with RP and healthy controls using a multiplexed immunoarray (Q-Plex), and evaluated the correlations between the serum cytokines/chemokines and visual parameters in patients with RP.

## MATERIALS AND METHODS

### Study Design and Ethics Statement

This cross-sectional study was conducted in accord with the principles outlined in the Declaration of Helsinki and was approved by the Institutional Review Board of Kyushu University Hospital (Fukuoka, Japan). All enrolled participants were informed regarding the potential consequences of the study and written informed consent was obtained from all of them.

### Participants

Patients with RP were recruited from the Kyushu University Hospital in 2017 and 2018, and blood samples were collected upon enrollment. Forty-five consecutive patients with typical RP (i.e. patients with rod-cone dystrophy) of age 20 to –39 years, as well as 28 age-matched and gender-matched healthy control subjects were included. The analysis used the results of the right eye of each subject. The diagnosis of typical RP was based on a history of night blindness, visual field constriction and/or ring scotoma, and markedly reduced or nonrecordable a-wave and b-wave amplitudes on electroretinography testing, in addition to ophthalmoscopic findings (e.g. bone spicule-like pigment clumping in the midperipheral and peripheral retina and attenuation of retinal vessels). Genetic analysis of 83 RP causative genes was previously performed in 33 of the 45 patients with RP. The genetic inheritance patterns were determined based on the detected variants.<sup>13</sup>

The information on smoking habits, regular physical activity status, medication, and systemic diseases at the time of blood collection was obtained using a standard questionnaire by direct contact or telephone. Patients engaging in sports at least once per week were defined as the regular exercise group. Obesity was defined as a body mass index (BMI) > 30 kg/m<sup>2</sup>, based on a report that obese subjects with BMI > 30 kg/m<sup>2</sup> have higher serum chemokines compared with nonobese subjects with BMI < 25 kg/m<sup>2</sup>.<sup>14</sup> Systemic diseases, such as hypertension, diabetes

mellitus (DM), hyperlipidemia, and autoimmune diseases were defined by self-report and prescription drugs. Patients with ocular diseases other than RP or systemic diseases, those who had undergone prior intraocular operations, or those taking medications, such as anti-inflammatory drugs, statins, or hormone replacement therapy were excluded.

### Clinical Examination

Baseline acuity for subsequent best-corrected visual acuity (BCVA) was measured with the Landolt decimal VA chart (CV-6000: Tomey, Nagoya, Japan; or AVC-36: Kowa, Nagoya, Japan) at 5 m or with single Landolt test cards (HP-1258; Handaya, Tokyo). The values were converted into logarithm of the minimum angle of resolution (logMAR) units for statistical evaluation. Automated static perimetry tests were performed with a Humphrey Field Analyzer (HFA) (Humphrey Instruments, San Leandro, CA, USA) using the central 10-2 Swedish Interactive Thresholding Algorithm Standard Program. The lens was corrected as appropriate for the test distance. If the test reliability was not satisfactory (i.e. fixation loss > 20%, false positive > 15%, or false negative > 33%), the results were not used for the analysis.

The mean deviation (MD) and averaged retinal sensitivity at the central 4 or 12 points were obtained as described previously.<sup>15,16</sup> The perimetry tests were adopted within 6 months before and after blood collection.

### Optical Coherence Tomography Measurement

Spectral-domain optical coherence tomography (SD-OCT; Cirrus HD-OCT; Carl-Zeiss Meditec, Dublin, CA, USA) images were taken at the time of blood collection. Research software (Carl Zeiss Meditec) was used to measure the central subfield thickness (CST) and ellipsoid zone (EZ) width. The average retinal thickness within the central 1 mm-diameter circle was defined as the CST. The EZ width was defined as the horizontal distance between the nasal and temporal borders where the EZ band met the upper surface of the retinal pigment epithelium (RPE), and was measured using the built-in caliper tool. If the EZ width exceeded the scanned images, the borders of the EZ width were set as the edge of the scanned image (3 mm eccentricity from the fovea). Epiretinal membrane (ERM), cystoid macular edema (CME), and macular hole (MH) were detected by both fundus examination and SD-OCT.

### Blood Testing

All samples from patients with RP and controls were collected between October 2017 and June 2018, and the serum was aliquoted within 1 hour from blood drawing and stored at –80 deg Celsius (°C) until use. There was no difference in the storage period between patients with RP and controls ( $P = 0.6868$ ). Measurement of 15 cytokines (interleukin [IL]-1 $\alpha$ , IL-1 $\beta$ , IL-2, IL-4, IL-5, IL-6, IL-10, IL-12p70, IL-13, IL-15, IL-17, IL-23, interferon [IFN]- $\gamma$ , and tumor necrosis factor [TNF]- $\alpha$ , TNF- $\beta$ ) and 9 chemokines (eotaxin, growth-related oncogene [GRO]- $\alpha$ , I-309, IL-8, IFN- $\gamma$ -inducible protein [IP]-10, monocyte chemoattractant protein [MCP]-1, MCP-2, regulated activation normal T-cell expressed and secreted [RANTES], and thymus and activated regulated chemokine [TARC]) was performed with the multiplex ELISA-based Q-Plex Human Cytokine array (Quansys Bioscience). The array was used according to the manufac-

**TABLE 1.** Baseline Characteristics of the Patients With Retinitis Pigmentosa (RP) and Control Subjects

	Control*	RP*	P Value
Sex, female (%)	16 (57)	23 (51)	0.64 <sup>  </sup>
Parameters at baseline			
Age, y	30.57 ± 4.54	32.51 ± 5.55	0.06*
BMI, kg/m <sup>2</sup>	20.73 ± 2.22	22.43 ± 3.53	0.06*
< 18.5, n (%)	4 (15)	4 (9)	
18.5 - < 25 (%)	22 (85)	30 (67)	
≥ 25	0	11 (24)	
Ex- and current smoker, n (%)	4 (15)	16 (36)	0.10 <sup>  </sup>
Regular physical activity status, n (%)			
Yes	2 (8)	10 (22)	0.12 <sup>  </sup>
No	24 (92)	35 (78)	
Medication, n	antihistamine, 3	antihistamine, 3	0.67 <sup>  </sup>
VA, log MAR		0.23 ± 0.56 <sup>†</sup>	
MD, dB		-14.52 ± 7.60 <sup>‡</sup>	
Average retinal sensitivity of central 4 points, dB		27.23 ± 8.76 <sup>‡</sup>	
Average retinal sensitivity of central 12 points, dB		26.06 ± 8.11 <sup>‡</sup>	
CST, μm		217.14 ± 50.10 <sup>§</sup>	
EZ width, μm		2074.33 ± 1826.73 <sup>§</sup>	
Macular complications, n		ERM, 7 CME, 7	
Inheritance mode, n			
AD		4	
RP causative gene, n		<i>IMPDH1</i> , 2 <i>RHO</i> , 1 <i>SNRNP200</i> , 1	
AR		7	
RP causative gene, n		<i>EYS</i> , 3 <i>IMPG2</i> , 1 <i>PRCD</i> , 1 <i>TULP1</i> , 1 <i>USH2A</i> , 1	
X-linked		3	
RP causative gene, n		<i>RPGR</i> , 3	
ND		19	
NT		12	

AD = autosomal dominant; AR = autosomal recessive; BMI = body mass index; CME = cystoid macular edema; CST = central subfield thickness; dB = decibel; ERM = epiretinal membrane; EZ = ellipsoid zone; IQR = interquartile range; log MAR = logarithm of the minimal angle of resolution; MD = mean deviation; ND = not determined, NT = not tested, VA = visual acuity.

\* Data are mean ± SD. Ocular characteristics are derived from the right eyes.

† n = 44.

‡ n = 35.

§ n = 42.

|| Fisher's exact test.

# Wilcoxon's rank-sum test.

turer's instructions and analyzed in duplicate. The signals of the cytokine/chemokine arrays were determined using chemiluminescence and imaged with LAS 4010 CCD cameras (Fujifilm, Tokyo). If the detection rate of a given cytokine was ≥ 50% in either of the two groups, the detection rate was compared between the groups. Similarly, if the detection rate was ≥ 80% in either of the two groups, the concentrations in the groups were compared by multiplex ELISA, as described in a previous report.<sup>17</sup>

### Statistical Analysis

All statistical analyses were performed using SAS software (version 14.1; SAS Institute, Cary, NC, USA). The data of baseline characteristics were presented as the arithmetic mean ± standard deviation (SD). Statistical differences in the mean values between the groups were analyzed by Wilcoxon's rank-sum test, and the differences of frequency were tested by Fisher's exact tests. The levels of cytokines/chemokines

are shown as the median and interquartile range. If the detection rate of a given cytokine was ≥ 50% in either of the two groups, the detection rate was compared between the groups. Similarly, if the detection rate was ≥ 80% in either of the two groups, the concentrations in the groups were compared as described in a previous report.<sup>17</sup> Correlations between chemokines and visual parameters were determined by Spearman's rank test. P values < 0.05 were considered significant.

### RESULTS

The demographic characteristics of the patients with RP and controls are shown in Table 1. There were no significant differences in gender, age, BMI, smoking habits, regular physical activity status, or medications (3 patients with RP and 3 controls used antihistamine drugs) between the two groups. Four patients with RP received vitamin A.

**TABLE 2.** Detection Rates of Serum Cytokine Levels in the Control Subjects and Patients With RP

	Control			RP			P Value
	Detection Rates, %	Median	IQR	Detection Rates, %	Median	IQR	
IL-1 $\alpha$	4	0	(0, 0)	0	0	(0, 0)	NA
IL-1 $\beta$	0	0	(0, 0)	2	0	(0, 0)	NA
IL-2	18	0	(0, 0)	67	11.61	(0, 22.96)	0.0003*
IL-4	4	0	(0, 0)	2	0	(0, 0)	NA
IL-5	0	0	(0, 0)	2	0	(0, 0)	NA
IL-6	0	0	(0, 0)	2	0	(0, 0)	NA
IL-10	29	0	(0, 2.95)	73	8.68	(0, 21.46)	0.0003*
IL-12p70	7	0	(0, 0)	33	0	(0, 4.89)	NA
IL-13	25	0	(0, 0.64)	38	0	(0, 5.64)	NA
IL-15	0	0	(0, 0)	0	0	(0, 0)	NA
IL-17	21	0	(0, 0)	53	7	(0, 19.91)	0.0081*
IL-23	7	0	(0, 0)	31	0	(0, 80.41)	NA
IFN- $\gamma$	18	0	(0, 0)	22	0	(0, 0)	NA
TNF- $\alpha$	100	28.60	(19.59, 47.86)	89	22.75	(9.80, 41.30)	0.0953†
TNF- $\beta$	0	0	(0, 0)	0	0	(0, 0)	NA

IFN = interferon; IL = interleukin; IQR = interquartile range; NA = not applicable; TNF = tumor necrosis factor.

All values are pg/mL.

\* Fisher's exact test.

† Wilcoxon's rank-sum test.

**TABLE 3.** Serum Chemokine Levels in the Control Subjects and Patients With RP

	Control			RP			P Value
	Detection Rates, %	Median	IQR	Detection Rates, %	Median	IQR	
Eotaxin	100	49.61	(36.74, 56.73)	100	46.58	(40.07, 57.90)	0.9277*
Gro- $\alpha$	100	14.47	(12.54, 20.18)	100	15.60	(11.94, 21.60)	0.5105*
I-309	100	30.09	(20.41, 43.22)	100	26.36	(18.78, 33.19)	0.2519*
IL-8	100	15.34	(12.55, 22.32)	100	57.28	(31.33, 113.18)	< 0.0001*
IP-10	100	38.88	(29.72, 46.95)	100	42.45	(34.96, 49.16)	0.2248*
MCP-1	97	64.14	(50.87, 82.30)	100	68.37	(57.59, 86.24)	0.2662*
MCP-2	100	33.26	(28.41, 41.18)	100	32.10	(25.78, 34.88)	0.1403*
RANTES	100	913.86	(679.15, 1777.12)	100	1986.28	(1428.34, 4946.07)	< 0.0001*
TARC	54	29.32	(0, 53.60)	51	43.32	(0, 75.37)	1.0000†

Gro- $\alpha$  = growth related oncogene- $\alpha$ ; IL = interleukin; IP-10 = interferon  $\gamma$  inducible protein 10; IQR = interquartile range; MCP = monocyte chemoattractant protein; RANTES = regulated activation normal T-cell expressed and secreted; TARC = thymus and activated regulated chemokine.

All values are pg/mL.

\* Wilcoxon's rank-sum test.

† Fisher's exact test.

Regarding macular complications in patients with RP, mild ERM with a hyper-refractive line or band over the macular surface, but without wavy changes in the underlying retina, was observed in seven patients. CME involving the fovea was not associated with RP, but extrafoveal cysts were observed in seven patients. MH was not associated with RP.

**Expression Levels of Cytokines and Chemokines**

The serum values of 15 cytokines (IL-1 $\alpha$ , IL-1 $\beta$ , IL-2, IL-4, IL-5, IL-6, IL-10, IL-12p70, IL-13, IL-15, IL-17, IL-23, IFN- $\gamma$ , TNF- $\alpha$ , and TNF- $\beta$ ) and 9 chemokines (Eotaxin, GRO- $\alpha$ , I-309, IL-8, IP-10, MCP-1, MCP-2, RANTES, and TARC), which were simultaneously measured by a multiplexed immunoarray (Q-Plex), are summarized in Tables 2 and 3. The detection rates of 11 cytokines (IL-1 $\alpha$ , IL-1 $\beta$ , IL-4, IL-5, IL-6, IL-12p70, IL-13, IL-15, IL-23, IFN- $\gamma$ , and TNF- $\beta$ ) were not  $\geq$  50% in either the RP or control group.

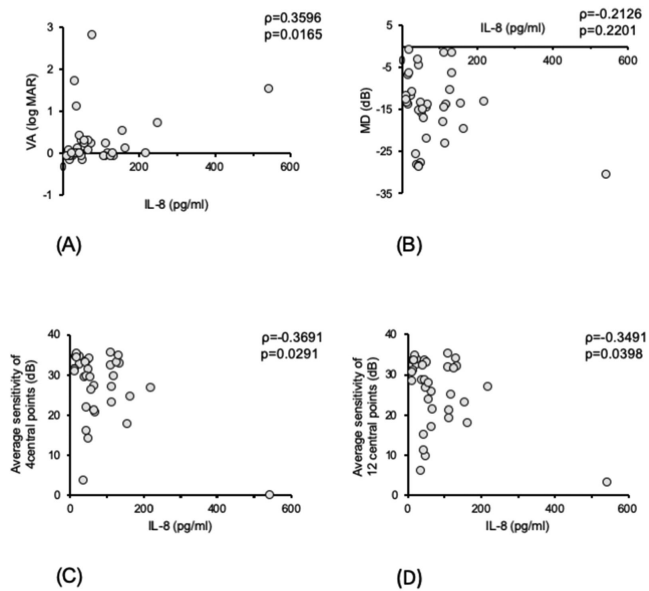
The detection rates of IL-2, IL-10, and IL-17 were upregulated in patients with RP compared with controls (IL-2: 67%

vs. 18%,  $P = 0.0003$ ; IL-10: 73% vs. 29%,  $P = 0.0003$ ; IL-17: 53% vs. 21%,  $P = 0.0081$ ; Table 2). All chemokines except for TARC were detected at almost 100% in both groups. The levels of IL-8 ( $P < 0.0001$ ) and RANTES ( $P < 0.0001$ ) were upregulated in patients with RP compared with controls (Table 3).

We also examined the relationships between cytokine detectability and chemokine levels. In the patients with RP with detectable IL-2, IL-10, and IL-17, the levels of IL-8 but not RANTES were higher than in the group with undetectable levels of these cytokines (IL-2:  $P < 0.0001$ ; IL-10:  $P < 0.0001$ ; and IL-17:  $P < 0.0001$ ; Supplementary Fig. S1).

**Correlations Between Cytokine/Chemokine Levels and Visual Parameters in the Patients With RP**

We next investigated the relationships between the levels of the chemokines that were elevated in patients with RP (i.e. IL-8 and RANTES) and the visual parameters. Spearman's correlation coefficient analysis showed that, in the



**FIGURE 1.** Relationships between the levels of serum interleukin (IL)-8 and visual function in patients with retinitis pigmentosa (RP). The *scatterplot* shows the levels of serum IL-8 and visual acuity (VA) (A), the MD values in Humphrey Field Analyzer (HFA) 10-2 tests (B), the average sensitivity of 4 central points (C), and the average sensitivity of 12 central points (D).

patients with RP, there were significant correlations between IL-8 and VA ( $\rho = 0.3596$  and  $P = 0.0165$ ; Fig. 1A), between IL-8 and averaged retinal sensitivity at the central 4 points ( $\rho = -0.3691$  and  $P = 0.0291$ ; Fig. 1C), and between IL-8 and averaged retinal sensitivity at the central 12 points ( $\rho = -0.3491$  and  $P = 0.0398$ ; Fig. 1D; Table 4).

We also evaluated the relationships between serum cytokine/chemokine levels and macular structural measures. There were significant correlations between IL-8 and CST ( $\rho = -0.3961$  and  $P = 0.0094$ ), and between IL-8 and EZ width ( $\rho = -0.3841$  and  $P = 0.0120$ ; Table 5 and Figs. 2A, 2B). These structural analyses further support the association between IL-8 and central vision loss in patients with RP.

## DISCUSSION

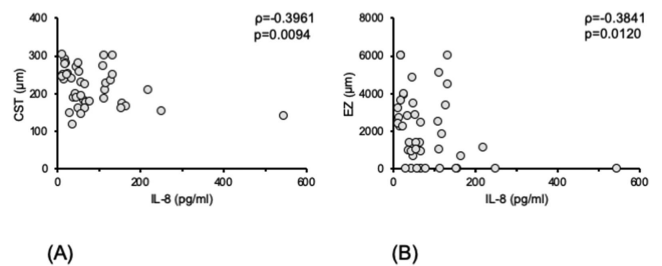
In the present study, we conducted a multiplex array analysis of serum inflammatory cytokines/chemokines in patients with RP and investigated the relationships between these molecules and visual parameters. Our data showed that the serum IL-8 and RANTES were significantly increased in

**TABLE 5.** Correlations Between Serum IL-8 Level and OCT Parameters of Patients With RP

	CST*, $\mu\text{m}$		EZ Width*, $\mu\text{m}$	
	$\rho$	P Value	$\rho$	P Value
IL-8	-0.3961	0.0094	-0.3841	0.0120

CST = central subfield thickness; EZ = ellipsoid zone; IL = interleukin.

\*  $n = 42$ .



**FIGURE 2.** Relationships between the levels of serum interleukin (IL)-8 and OCT parameters in patients with retinitis pigmentosa (RP). The *scatterplot* shows the relation between the levels of serum IL-8 and each of central subfield thickness (CST) (A) and the ellipsoid zone (EZ) width (B).

patients with RP, and IL-8 was negatively correlated with central visual function.

There is one previous study that investigated the serum levels of cytokines/chemokines in patients with RP, and there were no significant elevations compared with controls in that study.<sup>18</sup> In contrast, our study showed significant increases of IL-8 and RANTES in patients with RP. This discrepancy may be attributable to one or more of the following. First, the larger sample size of our study (45 patients in the present study versus 6 patients in the study by ten Berge et al.) may have increased the power to detect statistical differences. In addition, there were differences in the inclusion criteria for participants. Aging and obesity are important factors that affect blood inflammatory molecules and markers, such as IL-1, IL-6, IL-8, TNF- $\alpha$ , and CRP.<sup>14,19-21</sup> Whereas the previous study examined patients over 50 years of age,<sup>18</sup> we collected serum samples from relatively young (< 40 years of age) and otherwise healthy subjects, which may have reduced the confounding effects of age, obesity, and other systemic disorders.

Our present study demonstrated associations between serum IL-8 and central visual parameters in patients with RP. Central vision in RP can be attenuated by retinal

**TABLE 4.** Correlations Between Serum Chemokines and Visual Functions of Patients With RP

	VA*		MD, Per dB Increase <sup>†</sup>		Average Sensitivity of 4 Central Points, Per dB Increase <sup>†</sup>		Average Sensitivity of 12 Central Points, Per dB Increase <sup>†</sup>	
	$\rho$	P Value	$\rho$	P Value	$\rho$	P Value	$\rho$	P Value
IL-8	0.3596	0.0165	-0.2126	0.2201	-0.3691	0.0291	-0.3491	0.0398
RANTES	-0.0886	0.5675	-0.0510	0.7711	0.0596	0.7337	0.0039	0.9821

dB = decibel; IL = interleukin; MD = mean deviation; RANTES = regulated activation normal T-cell expressed and secreted; VA = visual acuity.

\*  $n = 44$ .

†  $n = 35$ .

degeneration itself as well as by macular complications, such as ERM and CME. Because the patients with RP in this study did not have visually significant ERM or foveal CME, we considered that the central vision loss was mainly attributable to retinal degeneration due to RP. However, the possibility that ERM or extrafoveal cysts affect the central vision cannot be excluded. An association between IL-8 and ocular disease has been reported in patients with glaucoma, in whom aqueous IL-8 levels were related to faster disease progression.<sup>22</sup> Together, these findings suggest that IL-8 may be an important factor in retinal and optic nerve degeneration, although the cause-effect relationship cannot be elucidated by an observational clinical study. To address this point, a longitudinal study to monitor serum IL-8 levels and their relationships to the functional and structural disease progression will be needed.

IL-8 is a potent chemoattractant for neutrophils and monocytes, and it mediates innate immune response, angiogenesis, and cancer formation.<sup>23,24</sup> Increased IL-8 has been shown to be associated with obesity, hypertension, DM, dyslipidemia, and autoimmune diseases.<sup>25–28</sup> On the other hand, drugs, such as statins, have been reported to lower serum IL-8.<sup>29</sup> Therefore, we excluded the subjects with these systemic conditions. In our cohort, there was no association between IL-8 and age ( $\rho = -0.0588$  and  $P = 0.7011$ ), or between IL-8 and BMI ( $\rho = -0.0981$  and  $P = 0.5241$ ) in patients with RP. Based on these findings, we conjectured that the increased IL-8 may have been at least partly attributable to RP, but we cannot rule out the possibility that other subclinical or undiagnosed systemic factors may have confounded the results.

IL-8 expression is promoted by inflammatory signals (e.g. TNF- $\alpha$ , IL-1 $\beta$ , and IL-17) as well as environmental stresses (e.g. hypoxia and oxidative stress).<sup>30,31</sup> Our study also showed that IL-8 levels were associated with the Th17-related cytokine (IL-17) as well as regulatory molecules of T cell fate (IL-2 and IL-10) in patients with RP. These results suggest that the activation and imbalance of T cell response may stimulate peripheral IL-8 production in RP. IL-17 has been implicated in psoriasis and other immune diseases, and anti-IL-17 antibodies are clinically approved for psoriasis.<sup>32</sup> Therefore, further investigation of the IL-8-related and IL17-related pathways would be intriguing and could lead to the development of novel treatments or drug repositioning for RP.

Although rod cells are primarily injured by genetic mutations in RP (i.e. rod-cone dystrophy), bystander cells including cone cells undergo progressive degeneration subsequent to rod cell loss. The mechanisms for this mutation-independent cone degeneration in RP remain to be elucidated; however, laboratory evidence suggests that microenvironmental factors, such as inflammation, oxidation, and nutrient shortage, contribute to this process.<sup>6,33–35</sup> Our present and previous clinical studies have demonstrated an association between cone-mediated central visual function and inflammatory markers/molecules,<sup>2,7,10</sup> which may support a role of inflammation in cone degeneration in RP.

There are some limitations in our study. First, the sample was from a single center and was relatively small. To minimize the influence of systemic factors, we included relatively young patients (< 40 years old), which reduced the number of participants. Second, serum cytokines/chemokines were measured at only one time point, and thus the time course changes of cytokines/chemokines associated with disease progression are unknown. Third, it should be

noted that there was an outlier with a high level of IL-8 (544.42 pg/mL) among the patients with RP. We did not measure the body temperature of participants and it is unclear whether or not this patient had a common cold. However, this patient did not show such extreme values in other cytokines/chemokines, and the serum hs-CRP of this patient was within the normal range. Moreover, even if this outlier was excluded from the analysis, the correlations between IL-8 and visual function/macular structure remained statistically significant (VA:  $\rho = 0.3200$  and  $P = 0.0364$ ; CST:  $\rho = -0.3599$  and  $P = 0.0224$ ; and EZ width:  $\rho = -0.3479$  and  $P = 0.0258$ ). Last, the relationships of the ocular and serum cytokines/chemokines are unclear. We were unable to address this question because there are limited opportunities to obtain aqueous humor from younger patients with RP.

In conclusion, peripheral inflammatory response may be activated and the serum IL-8 levels are associated with central vision in patients with RP.

### Acknowledgments

Support for this work was provided in the form of Grants-in-Aid for Scientific Research (KAKEN #16H06268 and #19K09952 to Y.M.); a Uehara Memorial Foundation grant (to Y.M.); a grant from the Charitable Trust Fund for Ophthalmic Research in Commemoration of Santen Pharmaceutical's Founder (to Y.M.); a Kaibara Morikazu Medical Science Promotion Foundation grant (to Y.M.); a Bayer Retina Award (to Y.M.); and a Takeda Science Foundation grant (to Y.M.).

Disclosure: **A. Okita**, None; **Y. Murakami**, None; **S. Shimokawa**, None; **J. Funatsu**, None; **K. Fujiwara**, None; **S. Nakatake**, None; **Y. Koyanagi**, None; **M. Akiyama**, None; **A. Takeda**, None; **T. Hisatomi**, None; **Y. Ikeda**, None; **K.-H. Sonoda**, None

### References

- Hartong DT, Berson EL, Dryja TP. Retinitis pigmentosa. *Lancet*. 2006;368:1795–1809.
- Murakami Y, Yoshida N, Ikeda Y, et al. Relationship between aqueous flare and visual function in retinitis pigmentosa. *Am J Ophthalmol*. 2015;159:958–963.e951.
- Nishiguchi KM, Yokoyama Y, Kunikata H, Abe T, Nakazawa T. Correlation between aqueous flare and residual visual field area in retinitis pigmentosa. *Br J Ophthalmol*. 2019;103:475–480.
- Peng B, Xiao J, Wang K, So KF, Tipoe GL, Lin B. Suppression of microglial activation is neuroprotective in a mouse model of human retinitis pigmentosa. *J Neurosci*. 2014;34:8139–8150.
- Zabel MK, Zhao L, Zhang Y, et al. Microglial phagocytosis and activation underlying photoreceptor degeneration is regulated by CX3CL1-CX3CR1 signaling in a mouse model of retinitis pigmentosa. *Glia*. 2016;64:1479–1491.
- Zhao L, Zabel MK, Wang X, et al. Microglial phagocytosis of living photoreceptors contributes to inherited retinal degeneration. *EMBO Mol Med*. 2015;7:1179–1197.
- Yoshida N, Ikeda Y, Notomi S, et al. Clinical evidence of sustained chronic inflammatory reaction in retinitis pigmentosa. *Ophthalmology*. 2013;120:100–105.
- Gupta N, Brown KE, Milam AH. Activated microglia in human retinitis pigmentosa, late-onset retinal degeneration, and age-related macular degeneration. *Exp Eye Res*. 2003;76:463–471.

9. Saban DR. New concepts in macrophage ontogeny in the adult neural retina. *Cell Immunol.* 2018;330:79–85.
10. Murakami Y, Ikeda Y, Nakatake S, et al. C-Reactive protein and progression of vision loss in retinitis pigmentosa. *Acta Ophthalmol.* 2018;96:e174–e179.
11. Nassar K, Grisanti S, Elfar E, Luke J, Luke M, Grisanti S. Serum cytokines as biomarkers for age-related macular degeneration. *Graefes Arch Clin Exp Ophthalmol.* 2015;253:699–704.
12. Yuuki T, Kanda T, Kimura Y, et al. Inflammatory cytokines in vitreous fluid and serum of patients with diabetic vitreo-retinopathy. *J Diabetes Complications.* 2001;15:257–259.
13. Koyanagi Y, Akiyama M, Nishiguchi KM, et al. Genetic characteristics of retinitis pigmentosa in 1204 Japanese patients. *J Med Genet.* 2019;56:662–670.
14. Kim CS, Park HS, Kawada T, et al. Circulating levels of MCP-1 and IL-8 are elevated in human obese subjects and associated with obesity-related parameters. *Int J Obes (Lond).* 2006;30:1347–1355.
15. Fujiwara K, Ikeda Y, Murakami Y, et al. Assessment of central visual function in patients with retinitis pigmentosa. *Sci Rep.* 2018;8:8070.
16. Iijima H. Correlation between visual sensitivity loss and years affected for eyes with retinitis pigmentosa. *Jpn J Ophthalmol.* 2012;56:224–229.
17. Lu B, Yin H, Tang Q, et al. Multiple cytokine analyses of aqueous humor from the patients with retinitis pigmentosa. *Cytokine.* 2019;127:154943.
18. Ten Berge JC, Fazil Z, van den Born I, et al. Intraocular cytokine profile and autoimmune reactions in retinitis pigmentosa, age-related macular degeneration, glaucoma and cataract. *Acta Ophthalmol.* 2019;97:185–192.
19. Ter Horst R, Jaeger M, Smeekens SP, et al. Host and environmental factors influencing individual human cytokine responses. *Cell.* 2016;167:1111–1124.e1113.
20. Michaud M, Balardy L, Moulis G, et al. Proinflammatory cytokines, aging, and age-related diseases. *J Am Med Dir Assoc.* 2013;14:877–882.
21. Zheng Y, Rao YQ, Li JK, Huang Y, Zhao P, Li J. Age-related pro-inflammatory and pro-angiogenic changes in human aqueous humor. *Int J Ophthalmol.* 2018;11:196–200.
22. Chono I, Miyazaki D, Miyake H, et al. High interleukin-8 level in aqueous humor is associated with poor prognosis in eyes with open angle glaucoma and neovascular glaucoma. *Sci Rep.* 2018;8:14533.
23. Ghasemi H, Ghazanfari T, Yaraee R, Faghihzadeh S, Hassan ZM. Roles of IL-8 in ocular inflammations: a review. *Ocul Immunol Inflamm.* 2011;19:401–412.
24. Ha H, Debnath B, Neamati N. Role of the CXCL8-CXCR1/2 axis in cancer and inflammatory diseases. *Theranostics.* 2017;7:1543–1588.
25. Tanase DM, Gosav EM, Radu S, et al. Arterial hypertension and interleukins: potential therapeutic target or future diagnostic marker? *Int J Hypertens.* 2019;2019:3159283.
26. Marek-Trzonkowska N, Kwieczyńska A, Reiwer-Gostomska M, Koliński T, Molisz A, Siebert J. Arterial hypertension is characterized by imbalance of pro-angiogenic versus anti-angiogenic factors. *PLoS One.* 2015;10:e0126190.
27. Cimini FA, D'Eliseo D, Barchetta I, Bertocchini L, Velotti F, Cavallo MG. Increased circulating granzyme B in type 2 diabetes patients with low-grade systemic inflammation. *Cytokine.* 2019;115:104–108.
28. Araújo LS, da Silva MV, da Silva CA, et al. Analysis of serum inflammatory mediators in type 2 diabetic patients and their influence on renal function. *PLoS One.* 2020;15:e0229765.
29. Marino F, Maresca AM, Castiglioni L, et al. Simvastatin down-regulates the production of interleukin-8 by neutrophil leukocytes from dyslipidemic patients. *BMC Cardiovasc Disord.* 2014;14:37.
30. Waugh DJ, Wilson C. The interleukin-8 pathway in cancer. *Clin Cancer Res.* 2008;14:6735–6741.
31. Brat DJ, Bellail AC, Van Meir EG. The role of interleukin-8 and its receptors in gliomagenesis and tumoral angiogenesis. *Neuro Oncol.* 2005;7:122–133.
32. Blauvelt A, Chiricozzi A. The immunologic role of IL-17 in psoriasis and psoriatic arthritis pathogenesis. *Clin Rev Allergy Immunol.* 2018;55:379–390.
33. Komeima K, Rogers BS, Lu L, Campochiaro PA. Antioxidants reduce cone cell death in a model of retinitis pigmentosa. *Proc Natl Acad Sci USA.* 2006;103:11300–11305.
34. Punzo C, Kornacker K, Cepko CL. Stimulation of the insulin/mTOR pathway delays cone death in a mouse model of retinitis pigmentosa. *Nat Neurosci.* 2009;12:44–52.
35. Venkatesh A, Ma S, Le YZ, Hall MN, Ruegg MA, Punzo C. Activated mTORC1 promotes long-term cone survival in retinitis pigmentosa mice. *J Clin Invest.* 2015;125:1446–1458.