

Psychogenic Pseudo-responses in an Electrical Cortical Stimulation

Tomoaki TAMADA,¹ Rei ENATSU,¹ Yuto SUZUKI,¹ Rintaro YOKOYAMA,¹
Hime SUZUKI,¹ Satoko OCHI,¹ and Nobuhiro MIKUNI¹

¹*Department of Neurosurgery, Sapporo Medical University School of Medicine,
Sapporo, Hokkaido, Japan*

Abstract

An electrical cortical stimulation provides important information for functional brain mapping. However, subjective responses (i.e. sensory, visual, and auditory symptoms) are purely detected by patients' descriptions, and may be affected by patients' awareness and intelligence levels. We experienced psychogenic responses in the electrical cortical stimulation of two patients with intractable epilepsy. A sham stimulation was useful for differentiating pseudo-responses from real responses in the electrical cortical stimulation. Inductive questions, long testing durations, and clear cues of stimulation onsets need to be avoided to prevent psychogenic pseudo-responses in the electrical cortical stimulation. Furthermore, a sham stimulation is applicable for detecting pseudo-responses the moment patients show atypical or inexplicable symptoms.

Key words: electrical stimulation, functional mapping, psychogenic responses, sham stimulation

Introduction

An electrical cortical stimulation is the gold standard for functional brain mapping, and provides important information for preserving brain function.¹⁾ It may produce either observable objective (i.e. tonic or clonic movements and speech arrest) or subjective responses (i.e. sensory, visual, and auditory symptoms).²⁾ These subjective symptoms are purely detected by patients' descriptions, and may be affected by patients' awareness and intelligence levels.³⁾

We experienced psychogenic responses in the electrical cortical stimulation of two patients with intractable epilepsy.

Materials and Methods

Functional mapping and sham stimulation

Electrical stimulation of the brain was performed to localize the eloquent cortex. First, functional mapping was performed in the manner of a bipolar stimulation for screening eloquent cortices. Thereafter,

a monopolar stimulation was performed for more accurate localization of functional areas. The stimulation parameters at our institution were: 50 Hz, alternative, constant current stimuli, a duration of 300 μ s, with intensity of 1–15 mA for grid type subdural electrode and 1–12 mA for stereotactic electroencephalography. Stimulus intensity was increased stepwise at 1–2 mA while monitoring for neurological symptoms and afterdischarges. The electroencephalography (EEG) monitoring and functional mapping were performed using Neurofax EEG-1200 with the JE-120 amplifier, the MS-120-EEG cortical stimulator and the Nihon Kohden PE-210 software stimulator switch box (Nihon Kohden, Tokyo, Japan). The software can switch the real and sham stimulation by unchecking and checking "sham stimulation box" respectively. In the sham stimulation, the examiners manipulated in the same way as the real stimulation, whereas, the electrical stimulation was not delivered. The patients were sitting on beds and were not requested to perform any specific tasks. The examiners observed and asked the patients about induced symptoms in the same manner as the real stimulation. The sham stimulation was applied mixed with the real stimulation when the patients showed atypical or inexplicable symptoms. At least two sham stimuli were performed to confirm the reproducibility of the psychogenic responses.

Received December 26, 2018; Accepted March 7, 2019

Copyright© 2019 by The Japan Neurosurgical Society
This work is licensed under a Creative Commons Attribution-NonCommercial-NoDerivatives International License.

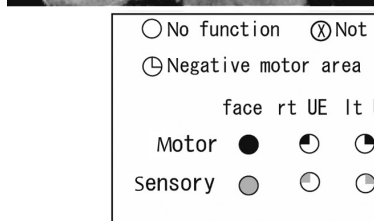
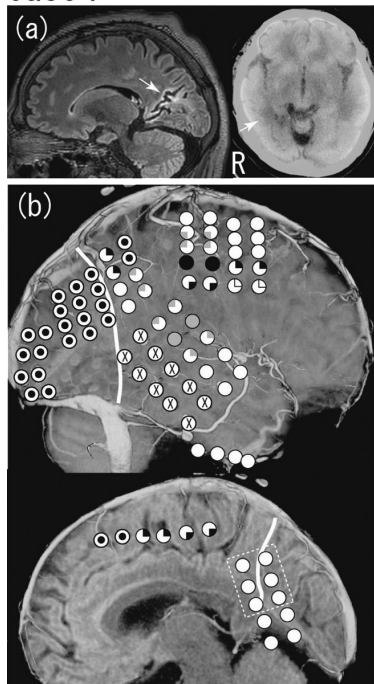
Case Report

Case 1

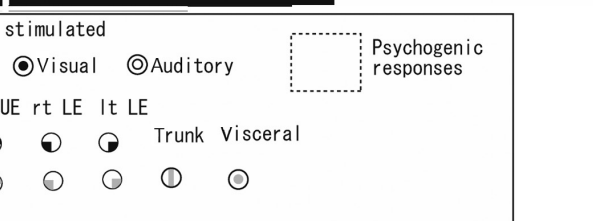
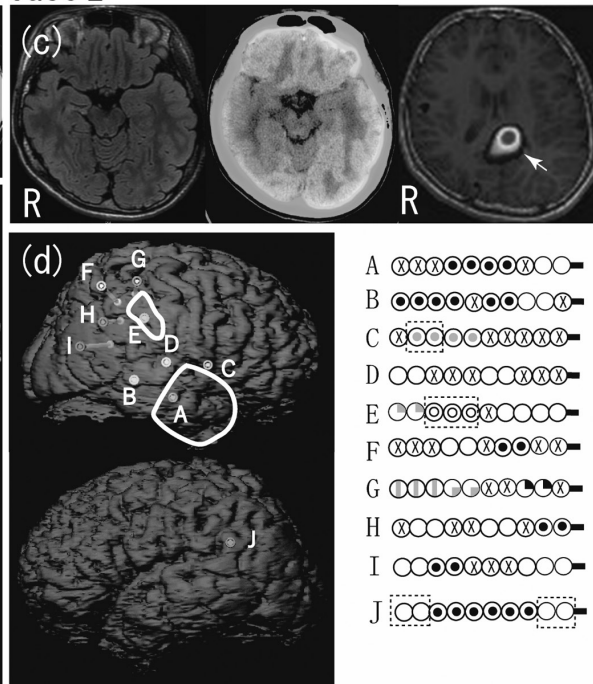
A 43-year-old right-handed male presented with focal seizures refractory to medical treatment since the age of 5 years old. He was having two types of seizures, including focal impaired awareness seizures and focal aware tonic seizures followed by focal to bilateral tonic-clonic seizures. His cognitive function was impaired with a full IQ of 75 and a neurological examination showed left hemianopsia. Magnetic resonance imaging (MRI) of the brain revealed ulegyria in right mesial occipital area, and fluorodeoxyglucose positron emission tomography (FDG-PET) showed hypometabolism in the mesial temporal and parieto-occipital areas in the right hemisphere (Fig. 1a). Interictal and ictal scalp epileptiform discharges were localized to the right hemisphere using long-term video EEG monitoring. A magnetoencephalography (MEG) analysis calculated equivalent current dipoles (ECDs) of interictal spikes to the right temporo-parietal area. Based on these non-invasive evaluations, the patient underwent an invasive evaluation with chronic subdural electrodes.

Interictal spikes were observed in the lateral and basal aspects of the right parieto-occipital area, and the ictal onset zone was also localized to the same region as the interictal spikes. Functional mapping was performed and motor, sensory, visual, and negative motor areas were identified in the manner of a bipolar stimulation on the first day of mapping. However, several unclear results were included: i.e. the atypical localization of functional areas (e.g. visual symptoms in the mesial frontal lobe, left arm motor symptoms in the superior parietal lobule, and left leg motor symptoms in the ventral precentral gyrus), and dissociation between unexpectedly broad visual areas and clinical symptoms (left hemianopsia) (Fig. 1b). Therefore, a monopolar stimulation was performed in the combination of a sham and real stimulation to differentiate between real- and pseudo-responses on the second day. The real and sham stimulation of the right precuneus induced visual symptoms (white light in the center of the visual field), although a bipolar stimulation elicited no symptom on the first day. There were not remarkable differences of onset of visual symptom between real and sham stimulation, and the patient complained of these

Case 1



Case 2



○ No function	⊗ Not stimulated								
⊖ Negative motor area	⊙ Visual	⊙ Auditory							⊡ Psychogenic responses
	face	rt UE	lt UE	rt LE	lt LE				
Motor	●	◐	◑	◒	◓	Trunk	Visceral		
Sensory	◔	◕	◖	◗	◘				

Fig. 1 (a) Magnetic resonance imaging (MRI) revealed ulegyria in the right mesial occipital area, and fluorodeoxyglucose positron emission tomography (FDG-PET) showed hypometabolism in the mesial temporal and parieto-occipital areas in the right hemisphere in Case 1. (b) The results of functional brain mapping. The sham stimulation of the dashed square area induced visual symptoms. The white thick line shows disconnection line. (c) MRI showed right hippocampal sclerosis, and FDG-PET showed hypometabolism in the right temporo-parietal area in Case 2. Ictal single-photon emission computed tomography showed hyperperfusion in the left posterior cingulate gyrus. (d) The results of functional brain mapping. The sham stimulation of the dashed square area induced various psychogenic symptoms. The areas surrounded by white thick lines shows resected areas.

symptoms responding to the examiner's question. We concluded that these visual symptoms were psychogenic responses and further mapping was difficult to complete. Right parieto-occipital disconnection was subsequently performed, and the disconnected area included part of areas which showed psychogenic responses (Fig. 1b). Postoperatively, the patient presented no additional neurological deficits and seizures disappeared for 2 years.

Case 2

A 17-year-old right-handed male presented with focal infectious epilepsy refractory to medical treatment since the age of 7 years old. He developed influenza encephalopathy at the age of 3 years old. His seizures started with two types: focal impaired awareness autonomic seizures and focal aware left arm tonic seizures. His full IQ was 89 and a neurological examination revealed no neurological deficits. MRI showed right hippocampal sclerosis, while FDG-PET showed hypometabolism in the right temporo-parietal area (Fig. 1c). Interictal and scalp epileptiform discharges were localized to the right fronto-temporal region, and ictal activities started from the vertex. Single-photon emission computed tomography during seizures showed hyperperfusion in the left posterior cingulate gyrus. MEG revealed ECDs of spikes in the right temporo-parietal area. The patient underwent an invasive evaluation with stereotactic electroencephalography. Interictal spikes were observed in the temporal lobe and supramarginal gyrus over right hemisphere. Independent ictal onset zones were localized to the right lateral and mesial temporal regions and right supramarginal gyrus. Functional mapping was performed. The patient was in nervous state and complained of indefinite symptoms before the stimulation. Therefore, sham stimulation was performed mixed with real stimulation. Consequently, a sham stimulation of right parietal white matter (electrode E), left posterior cingulate gyrus, and left supramarginal gyrus induced symptoms. Both sham and real stimuli of the right anterior insula (electrode C) induced gluteal numbness. A real stimulation of right parietal white matter (electrode E) induced hearing impairment, whereas a sham stimulation induced bilateral hand hotness.

Bilateral foot numbness and visual symptoms (white light) were induced in the sham stimulation of left posterior cingulate gyrus and left supramarginal gyrus (electrode J) respectively, although a real stimulation of these areas showed no symptom. Resection of the right temporal lobe

and supramarginal gyrus was performed, and the areas which showed psychogenic responses were not resected. Postoperatively, the patient had left upper quadrantanopsia and seizures disappeared for 5 months.

Discussion

We observed psychogenic responses in the electrical cortical stimulation of two patients with intractable epilepsy. Sensory, visual, and auditory symptoms induced by an electrical cortical stimulation are purely described by patients' subjective feelings, and distinctive findings of psychogenic responses were not found in our cases. Therefore, psychogenic responses hamper the localization of these eloquent cortices, and an effective method is not available for preventing psychogenic responses. These responses are critical limitation of cortical stimulation, and disable for continuing functional mapping. To the best of our knowledge, psychogenic responses in an electrical cortical stimulation have not yet been reported, and risk factors for pseudo-responses remain unclear. On the other hand, a previous study reported that personality disorders, particularly emotionally unstable (borderline) personality disorders, are strongly associated with psychogenic non-epileptic seizures.⁴⁾ Personality disorders may also be a risk factor for psychogenic responses in an electrical cortical stimulation. Risk factors for psychogenic responses may include cognitive impairment (Case 1), a young age (Case 2), nervous disposition (Case 2), inductive questions, and long testing durations.

A sham stimulation is widely used in transcranial magnetic stimulation research to differentiate between real and placebo effects,^{5,6)} and has been useful for differentiating pseudo-responses from real responses in the electrical cortical stimulation. The sham stimulation should be similar to the real stimulation so that the patients have the same beliefs regarding the stimulation effects. In addition, patients should be blind to the stimulation condition.

In the electrical cortical stimulation, the possibility of pseudo-responses need to be considered and inductive questions, long testing durations, and clear cues of stimulation onsets need to be avoided. Furthermore, a sham stimulation is applicable for detecting pseudo-responses the moment patients show atypical or inexplicable symptoms.

Conflicts of Interest Disclosure

There are no conflicts of interest.

References

- 1) Enatsu R, Mikuni N: Invasive evaluations for epilepsy surgery: a review of the literature. *Neurol Med Chir (Tokyo)* 56: 221–227, 2016
- 2) Kanno A, Enatsu R, Ookawa S, Ochi S, Mikuni N: Location and threshold of electrical cortical stimulation for functional brain mapping. *World Neurosurg* 119: e125–e130, 2018
- 3) Kanno A, Mikuni N: Evaluation of language function under awake craniotomy. *Neurol Med Chir (Tokyo)* 55: 367–373, 2015
- 4) Hovorka J, Nezádál T, Herman E, Nemcová I, Bajacek M: Psychogenic non-epileptic seizures, prospective clinical experience: diagnosis, clinical features, risk factors, psychiatric comorbidity, treatment outcome. *Epileptic Disord* 9 (Suppl 1): S52–S58, 2007
- 5) George MS, Wassermann EM, Kimbrell TA, et al.: Mood improvement following daily left prefrontal repetitive transcranial magnetic stimulation in patients with depression: a placebo-controlled crossover trial. *Am J Psychiatry* 154: 1752–1756, 1997
- 6) Klein E, Kreinin I, Chistyakov A, et al.: Therapeutic efficacy of right prefrontal slow repetitive transcranial magnetic stimulation in major depression: a double-blind controlled study. *Arch Gen Psychiatry* 56: 315–320, 1999

Address reprint requests to: Nobuhiro Mikuni, MD, PhD, Department of Neurosurgery, Sapporo Medical University, South1, West16, Chuo-ku, Sapporo, Hokkaido 060-8543, Japan.
e-mail: mikunin@sapmed.ac.jp