



Contents lists available at [ScienceDirect](#)

Asia-Pacific Journal of Sports Medicine, Arthroscopy, Rehabilitation and Technology

journal homepage: www.ap-smart.com



Technical Notes

The use of vancomycin-soaked wrapping of hamstring grafts to reduce the risk of infection after anterior cruciate ligament reconstruction: An early experience in a district general hospital



Keith Hay-Man Wan^{*}, Stephen Pui-Kit Tang, Richard Hin-Lun Lee, Kevin KH Wong, Kam-Kwong Wong

Department of Orthopaedics and Traumatology, Kwong Wah Hospital, 25 Waterloo Road, Hong Kong Special Administrative Region

ARTICLE INFO

Article history:

Received 28 February 2020

Received in revised form

14 May 2020

Accepted 25 May 2020

ABSTRACTS

Introduction: The purpose of the study was to investigate whether pre-soaked hamstring graft with a solution of vancomycin followed by the 'vancomycin wrap' provides an effective way to reduce the risk of post-operative infection. We hypothesized that with the addition of the 'vancomycin wrap' there would be a significant reduction in the risk of post-operative infection.

Methods: A retrospective review of data collected on 305 consecutive patients who underwent anterior cruciate ligament reconstruction (ACLR) with hamstring autograft from April 2012 to March 2019. In the initial 4-year period, 185 patients (group 1) underwent ACLR with pre-operative intravenous antibiotic. In the subsequent 3-year period, 120 patients underwent ACLR with vancomycin pre-soaked graft together with pre-operative intravenous antibiotic before tourniquet inflation. After graft harvest, the grafts were soaked into a 5 mg/ml vancomycin solution for 1 min. The graft was then fastened within the graft sizing tube and wrapped by a sterile gauze saturated with the vancomycin solution beforehand.

Results: A total of 3 culture-positive joint infection were documented (1.6%) in group 1, requiring arthroscopic debridement. In group 2 no infection (0%) was recorded.

Conclusions: We proposed a safe, simple and easy-to-do method to reduce the risk of such complication. Prophylactic vancomycin soaking of hamstring autograft is effective to reduce the infection rate in this series compared with pre-operative antibiotic alone.

© 2020 Asia Pacific Knee, Arthroscopy and Sports Medicine Society. Published by Elsevier (Singapore) Pte Ltd. This is an open access article under the CC BY-NC-ND license (<http://creativecommons.org/licenses/by-nc-nd/4.0/>).

Introduction

Every anterior cruciate ligament reconstruction (ACLR) surgery faces two challenges. The first one is how to improve the surgical technique and subsequently the overall results. The second one is how to minimize the morbidity of the procedure. The potential consequence of a deep infection can be devastating.

Septic arthritis after an ACLR is a serious but uncommon complication, with incidence ranging from 0.14% to 1.8%.¹ Risk factors including the use of hamstring autograft, concomitant open surgical procedure, the use of drain or previous surgery on the same knee have been reported.¹

The use of preoperative systemic prophylactic antibiotic, as well

as the proper removal of body hair over the surgical incision site, has been reported as a useful way of reducing the infection rate in ACLR.^{2,3} Recently the use of vancomycin to pre-soak the autograft has been increasingly described in the literature and early results were promising in reducing the rate of infection following ACLR.^{1,4,5} However, data in our ethnic Chinese population is lacking. Moreover, in our early experience we have found that the prepared graft would occasionally swell up after bathing in the vancomycin solution, causing substantial difficulties during the passage of grafts through the pre-drilled tunnels. We have therefore proposed a modified method to tackle the problem.

The purpose of the study was to investigate whether pre-soaked hamstring autograft with vancomycin provides an effective way to reduce the risk of post-operative infection following ACLR.

^{*} Corresponding author.

E-mail address: drkeithwan@gmail.com (K.H.-M. Wan).

Materials and methods

A retrospective review of 305 patients undergoing primary ACLR using hamstring autograft in our institution over a 7-year period, from April 2012 to March 2019, was carried out. In the initial 4-year period, 185 patients received prophylactic pre-operative intravenous antibiotic (Group 1). In the subsequent 3-year period, 120 patients received prophylactic pre-operative intravenous antibiotic, in addition the graft was pre-soaked in a vancomycin solution (Group 2).

Surgical technique

All patients were operated on by the same surgical team, consisted of three fellowship-trained senior surgeons. The prophylactic pre-operative antibiotic consisted of 1 g intravenous cefazolin or, in cases of penicillin allergy, 500 mg of intravenous vancomycin. No patient in this series reported vancomycin allergy. The hamstring graft femoral fixation was carried out with a suspensory fixation system (Endobutton™ – Smith and Nephew). Tibial fixation was carried out with a resorbable interference screw (BioRCI – Smith and Nephew).

500 mg of vancomycin powder was mixed into a solution of 100 ml saline Fig. 2. After the hamstring graft was harvested and prepared, it was soaked into the 5 mg/ml vancomycin solution (Fig. 4). After the brief pre-soaking of the graft for 1 minute, it was brought back to the tensioner wrapped by a sterile gauze that had been saturated with the vancomycin solution beforehand. The graft was left there for 15–20 minutes until it was used for the ACL reconstruction. From our early experience we have found that in some cases the graft would swell up, causing difficulties while passing the graft through the pre-drilled femoral and tibial tunnels, which were made with reference to the graft diameter measured before the soaking. Later we modify the technique by fastening the front end of the graft within the graft sizing tube and wrapped the whole construct in a gauze that had been saturated with the vancomycin solution while the graft is still on the tensioner (Figs. 1 and 3). In this way, the aforementioned problem could be prevented.

Diagnostic criteria for septic arthritis

Diagnosis of septic arthritis was based on clinical examination, laboratory parameters and bacterial cultures of synovial fluid of the knee joint. All patients had at least nine months of post-operative follow-up. The patients were followed up at 2 weeks, 6 weeks and 3 months post-operatively. The patients were assessed for any signs and symptoms of septic arthritis. For those suspicious cases, blood tests for inflammatory markers and knee aspirations were done.

Statistical analysis

Statistical analysis was performed using SPSS (Version 26.0). Power analysis was used to calculate the adequate size of the study sample in order to avoid getting a type II error. We set the incidence of infection to be around 1%, the power to be 80% and type I error (α) to be 0.05. The sample size needed was calculated to be 119 in each group. P value of less than 0.05 was defined as statistically significant.

Results

A total of 3 culture positive intra-articular infections were identified in group 1 (1.6%). All cases were acute infections that developed in the early post-operative period (<4 weeks). Among

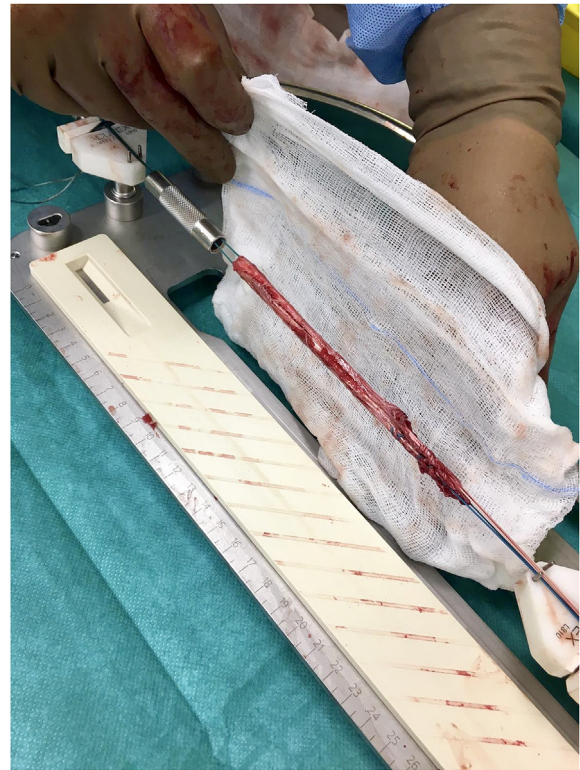


Fig. 1. Prepared hamstring graft pre-tensioned with its end through the sizing tube, which is then wrapped around by a gauze soaked with vancomycin solution (Vancomycin wrap).

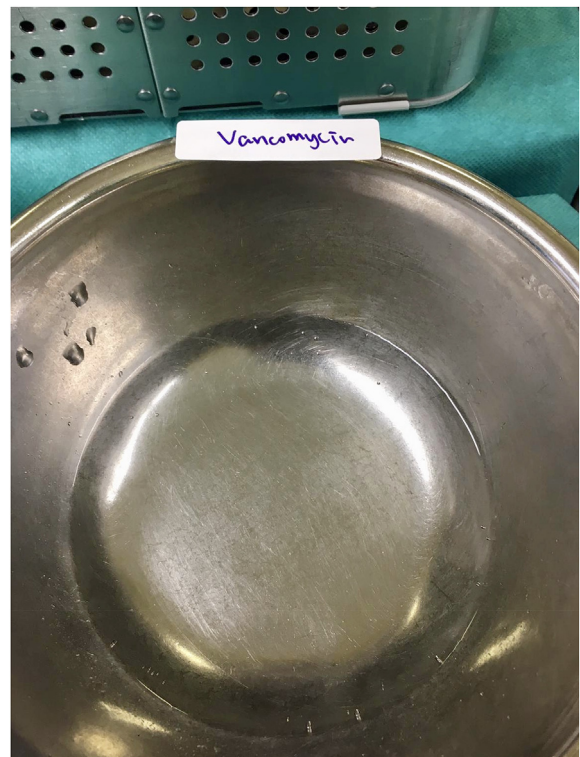


Fig. 2. The vancomycin solution. 500 mg of vancomycin mixed with 100 ml of normal saline.

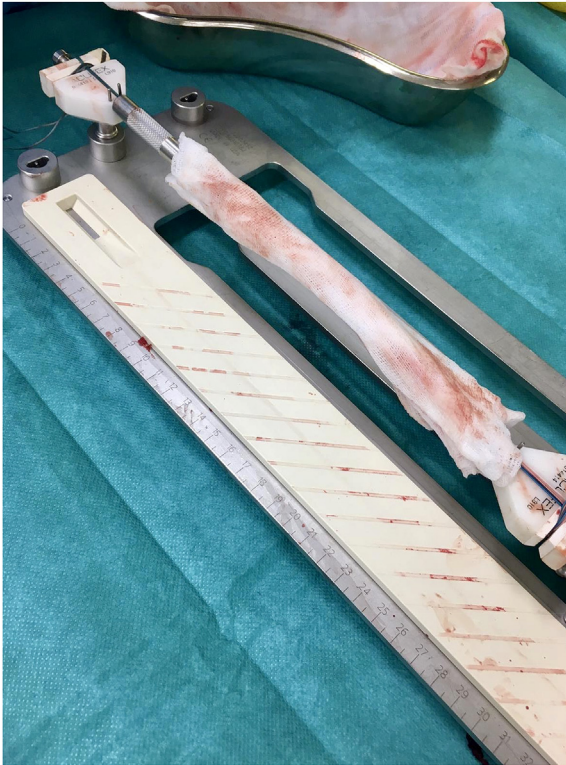

Fig. 3. The vancomycin wrap.

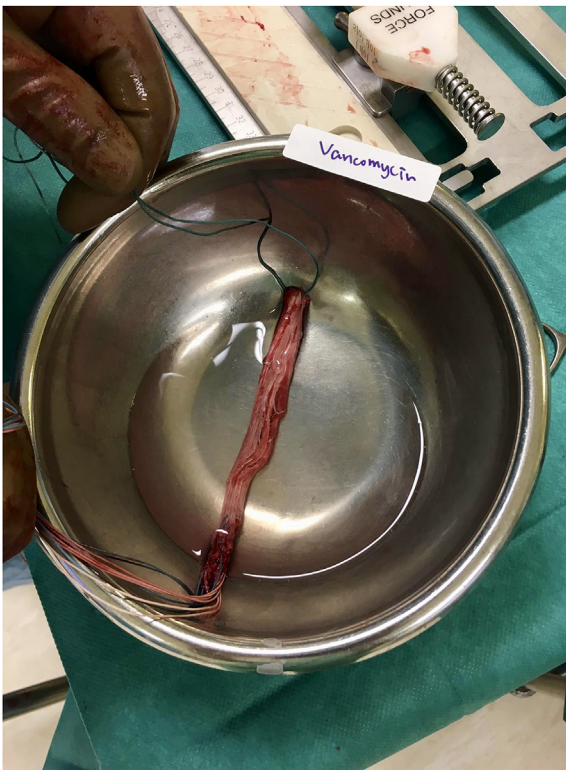

Fig. 4. Pre-soaking of graft with vancomycin solution before pre-tensioning.

Table 1

Demographics (age and gender) of all the study groups. Age at ACLR is presented as Mean (Standard deviation).

	Group 1	Group 2	p-value
Sample size (n)	185	120	
Age at ACLR (Years old)	27.867 (8.442)	26.559 (7.986)	0.217
Gender (Male/Female)	154/31	96/24	0.566

All the three patients were managed with a single episode of arthroscopic debridement and lavage together with intravenous antibiotics according to the bacterial culture and sensitivity results. Two of the patients required graft removal and a 2-stage revision ACLR.

There was no infection identified in patients receiving systemic antibiotic prophylaxis and graft pre-soaking with vancomycin (group 2). The infection rate was 0% (0 out of 120).

Statistical analysis showed that the prior saturation of the ACL graft in a vancomycin solution significantly reduced the infection rate ($p < 0.01$) in comparison with patients in which this technique was not performed.

There was no increase in the re-rupture rate with the use of the 'vancomycin wrap'. The re-rupture rate in group 1 was 5.4% (10 in 185 patients), and 2.5% (3 in 120 patients) in group 2.

There was no statistical difference in the demographics of the two groups of patients in terms of age and gender (Table 1).

No systemic vancomycin toxicity was noted among patients treated with the 'vancomycin wrap'.

Discussions

The main finding of this study was that the use of vancomycin in the pre-soaking of hamstring graft in combination with prophylactic intravenous antibiotic significantly reduced the rate of infection following ACLR, when compared to intravenous antibiotic alone.

The risk of intra-articular infection following ACLR is not as common as other implant-related complications and is reported to be between 0.14% and 1.7%.^{4,6,7} However, this deep-seated infection is a nightmare for orthopaedic surgeons as it often jeopardise the outcome of the surgery.^{8,9} The eradication of infection is made difficult by reduced intra-articular antibiotic penetration and biofilm formation.¹⁰ Many studies in the past has focused on the management of such complication by aggressive arthroscopic debridement and systemic antibiotic therapy.¹¹ However, little has been done focusing on the prevention of such infection.

Vancomycin has been used in many aspects in orthopaedic surgery. The use of heat stable vancomycin demonstrated reduced infection rate in arthroplasty surgeries.^{12,13} Using antibiotic-loaded bone cement has provided an effective antibiotic levels in surrounding tissues for several days as it disseminated. Antoci et al. showed that in titanium prosthetic implants covalently coated with vancomycin, bacterial adherence, proliferation, and formation of a biofilm by *Staphylococcus aureus* were prevented.¹⁴

Vancomycin is heat stable, has a low allergenicity. It is bactericidal against skin commensals such as staphylococcus aureus and coagulase negative staphylococcus, which are the commonest infecting bacteria associated with ACLR surgery.^{15,16} Grayson et al. observed that by rinsing the tendon with vancomycin, there is a continuous elution of vancomycin for at least 24 h, indicating the ability of the tendon to act as a 'reservoir'.¹⁷ Limited evidence regarding the potential toxicity of vancomycin on chondrocytes and tendons exist. A concentration of 2 mg per ml of vancomycin is required for effective eradication of staphylococcal species, and 5 mg per ml for the eradication of staphylococcus epidermidis.^{10,18}

these 3 cases, concomitant meniscal repair was performed in two patients. One case was infected by staphylococcus aureus, one by coagulase-negative staphylococcus and one by Propionibacterium acnes.

Vancomycin concentration exceeding 125 mg per ml is required for osteoblastic toxicity and inhabitation of bone regeneration¹⁴, far exceeding the 5 mg per ml concentration used in wrapping during our ACLR procedure.^{1,5,10,19}

Vertullo et al. first proposed the use of vancomycin in pre-soaking the hamstring grafts during ACLR in 2012.⁵ There was significant reduction in infection rate following ACLR, from 1.4% in 285 patients with intravenous antibiotics alone, to 0% in 870 patients with intravenous antibiotics and an additional vancomycin soaking. Phegan et al. further demonstrated the efficacy of vancomycin wrapping in their study, with 0% infection rate in 1300 consecutive patients with ACLR.¹⁰ Perez-Prieto et al. revealed a significant reduction of infection rate from 1.85% to 0% with the additional use of vancomycin wrapping.¹ In a follow up study they showed that vancomycin soaking fully eradicates contamination after harvesting of hamstring grafts by comparing vancomycin soaked and control cultured graft samples taken at differing points of harvesting and preparation. No growth was found in the group with vancomycin soaking, while 14% of the samples without vancomycin soaking grew positive cultures.¹⁹

The technique described by previous authors focused on rinsing the graft with the vancomycin solution. However, not much details had been written on how to prepare and standardize the 'vancomycin wrap'. We believe that making the 'vancomycin wrap' is an important step because the graft was spent 'hanging' on the tensioner within the gauze for a significant amount of time. And in addition, sometimes after absorbing the vancomycin solution, the graft would swell up. As the femoral and tibial bone tunnels were prepared with reference to the initial graft diameter before the soaking, it would result in substantial difficulty when the graft was being pulled through the tunnels during the later stage of the surgery. Hence in addition to standardizing the duration of graft rinsing to 1 minute, we have also put both ends of the graft within the graft sizing tubes before being covered by the 'vancomycin wrap'. We believe that it is an effective way to prevent the graft from expanding and to avoid the aforementioned problems during the graft passing.

All the cases have at least nine months of follow-up post-operatively. We believe that most post-ACLR infection occurred in the early post-operative period and a 9-month follow would hence be sufficient.

Different limitation can be attributed to this study. Firstly, it had a retrospective design with a lack of randomization. Secondly, with regards to the sample size, although it fulfilled the one calculated from the power analysis, it was still a relative small one. Thirdly, the review was done using the electronic record system of the Hospital Authority. We may have missed those patients with post-ACLR septic arthritis who were not admitted to the Hospital Authority medical system. However, we think it is not a usual practice for patients with post-operative complications to seek help from doctors other than those who did the initial surgeries. And even if that is the case, it would be very highly unlikely for the doctors treating the infection not to notify the initial surgeons.

All the cases had at least nine months of follow-up. We are aware of the fact that the follow-up period may not be long enough. But as majority of the post-ACLR infection happens within the early post-operative period, we believe that the limitation posed by the relatively short period of follow-up of some cases may not be significant.

Despite these limitations, the technique presented will be of relevance in the daily clinical practice to prevent infection after ACLR. It is a safe, simple and easily reproducible method.

Our study, together with those done by our predecessors^{4,13–15}, showed a remarkable reduction in infection rates using vancomycin wrap in addition to standard intravenous antibiotic. Vancomycin

wrap is a simple method, and its universal use during ACLR may save those patients from undergoing further revision surgeries in eradicating the infection. Our technique of modified graft wrapping may improve the subsequent graft passing. Large scale randomized control study should be conducted to confirm this point.

Conclusions

Hamstring autograft pre-soaking with vancomycin followed by the vancomycin wrap significantly reduce the rate of infection following ACLR.

Conflict of interest statement

They authors declare that they have no conflict of interest.

Ethical approval

This article does not contain any studies with human participants or animals performed by any of the authors.

Funding

The authors did not receive any sort of funding.

Consent for publication

The consent for publication was obtained by the authors and the Department of Orthopaedics and Traumatology, Kwong Wah Hospital, Hong Kong SAR.

Authors' contributions

The manuscript was prepared together by the authors.

Availability of data and material

All the data and material are available for publication should the article be accepted.

Declaration of competing interest

The authors declare that they have no conflict of interest.

Appendix A. Supplementary data

Supplementary data to this article can be found online at <https://doi.org/10.1016/j.asmart.2020.05.005>.

References

- Pérez-Prieto D, Torres-Claramunt R, Gelber PE, Shehata TM, Pelfort X, Monllau JC. Autograft soaking in vancomycin reduces the risk of infection after anterior cruciate ligament reconstruction. *Knee Surg Sports Traumatol Arthrosc.* 2016;24(9):2724–2728.
- Trampuz A, Zimmerli W. Antimicrobial agents in orthopaedic surgery: prophylaxis and treatment. *Drugs.* 2006;66(8):1089–1105.
- Tanner J, Norrie P, Melen K. Preoperative hair removal to reduce surgical site infection. *Cochrane Database Syst Rev.* 2011;9(11), CD004122.
- Torres-Claramunt R, Pelfort X, Erquicia J, Gil-Gonzalez S, Gelber PE, Puig L, et al. Knee joint infection after ACL reconstruction: prevalence, management and functional outcomes. *Knee Surg Sports Traumatol Arthrosc.* 2013;21(12):2844–2849.
- Vertullo CJ, Quick M, Jones A, Grayson JE. A surgical technique using presoaked vancomycin hamstring grafts to decrease the risk of infection after anterior cruciate ligament reconstruction. *Arthroscopy.* 2012;28(3):337–342.
- Stucken C, Garras DN, Shaner JL, Cohen S. Infections in anterior cruciate ligament reconstruction. *Sport Health.* 2013;5(6):553–557.
- Matava MJ, Evans TA, Wright RW, Shively RA. Septic arthritis of the knee

- following anterior cruciate ligament reconstruction: results of a survey of sports medicine fellowship directors. *Arthroscopy*. 1998;14(7):717–725.
8. Fong Sy, Tan JL. Septic arthritis after arthroscopic anterior cruciate ligament reconstruction. *Ann Acad Med Singapore*. 2014;33(2):228–234.
 9. Judd MD, Bottoni LC, Kim D, Burke CM, Hooker MS. Infections following arthroscopic anterior cruciate ligament reconstruction. *Arthroscopy*. 2006;22(4):375–384.
 10. Phegan M, Grayson JE, Vertullo CJ. No infections in 1300 anterior cruciate ligament reconstructions with vancomycin pre-soaking of hamstring grafts. *Knee Surg Sports Traumatol Arthrosc*. 2016;24(9):2729–2735.
 11. Eriksson K, Karlsson J. Local vancomycin in ACL reconstruction: a modern rationale (2016) for morbidity prevention and patient safety. *Knee Surg Sports Traumatol Arthrosc*. 2016;24(9):2721–2723.
 12. Antoci Jr V, Adams CS, Hickok NJ, Shapiro IM, Parvizi J. Antibiotics for local delivery systems cause skeletal cell toxicity in vitro. *Clin Orthop Relat Res*. 2008;462:200–206.
 13. Hanssen AD, Spanghel MJ. Practical applications of antibiotic-loaded bone cement for treatment of infected joint replacements. *Clin Orthop Relat Res*. 2004;427:79–85.
 14. Antoci Jr V, Adams CS, Hickok NJ, Shapiro IM, Parvizi J. Antibiotics for local delivery systems cause skeletal cell toxicity in vitro. *Clin Orthop Relat Res*. 2007;462:200–206.
 15. Wang C, Lee YH, Siebold R. Recommendations for the management of septic arthritis after ACL reconstruction. *Knee Surg Sports Traumatol Arthrosc*. 2014;22(9):2136–2144.
 16. Phegan M, Grayson JE, Vertullo CJ. No infections in 1300 anterior cruciate ligament reconstructions with vancomycin pre-soaking of hamstring grafts. *Knee Surg Sports Traumatol Arthrosc*. 2016;24(9):2729–2735.
 17. Grayson JE, Grant GD, Dukie S, Vertullo CJ. The in vitro elution characteristics of vancomycin from tendons. *Clin Orthop Relat Res*. 2011;469(10):2948–2952.
 18. Schüttler KF, Scharm A, Stein T, Heyse TJ, Lohoff M, Sommer F. Biomechanical and microbiological effects of local vancomycin in anterior cruciate ligament (ACL) reconstruction: a porcine tendon model. *Arch Orthop Trauma Surg*. 2018: 1–6.
 19. Pérez-Prieto D, Portillo ME, Torres-Claramunt R, Pelfort X, Hinarejos P, Monllau JC. Contamination occurs during ACL graft harvesting and manipulation, but it can be easily eradicated. *Knee Surg Sports Traumatol Arthrosc*. 2018;26(2):558–562.