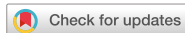

## Case Report



# Successful Management of Pan-Resistant *Acinetobacter baumannii* Meningitis without Intrathecal or Intraventricular Antibiotic Therapy in a Neonate

## OPEN ACCESS

### Corresponding Author:

#### Farhad Abolhasan Choobdar, MD

Department of Pediatrics, Iran University of Medical Sciences, Ali Asghar Children Hospital, Vahid Dastgerdi Street, Shariati Avenue, Tehran 1919816766, Iran.

Tel: +98 -21-22255218

Fax: +98-21-220063

E-mail: drchoobdar@gmail.com

Copyright © 2021 by The Korean Society of Infectious Diseases, Korean Society for Antimicrobial Therapy, and The Korean Society for AIDS

This is an Open Access article distributed under the terms of the Creative Commons Attribution Non-Commercial License (<https://creativecommons.org/licenses/by-nc/4.0/>) which permits unrestricted non-commercial use, distribution, and reproduction in any medium, provided the original work is properly cited.

### ORCID iDs

Shirin Sayyahfar

<https://orcid.org/0000-0002-7772-8353>

Farhad Abolhasan Choobdar

<https://orcid.org/0000-0002-0666-5711>

Mahdi Mashayekhi

<https://orcid.org/0000-0002-0799-5974>

Faramarz Masjedani Jazi

<https://orcid.org/0000-0002-0242-6000>

### Conflict of Interest

No conflicts of interest.

### Author Contributions

Conceptualization: SS, FAC, MM. Writing - original draft: SS. Writing - review & editing: SS. Final approval: SS, FAC, MM, FMJ.

Shirin Sayyahfar <sup>1</sup>, Farhad Abolhasan Choobdar <sup>2</sup>, Mahdi Mashayekhi <sup>3</sup>, and Faramarz Masjedani Jazi <sup>4</sup>

<sup>1</sup>Research Center of Pediatric Infectious Diseases, Institute of Immunology and Infectious Diseases, Iran University of Medical Sciences, Tehran, Iran

<sup>2</sup>Iran University of Medical Sciences, Tehran, Iran

<sup>3</sup>Tehran University of Medical Sciences, Tehran, Iran

<sup>4</sup>Department of Microbiology, School of Medicine, Iran University of Medical Sciences, Tehran, Iran

## ABSTRACT

*Acinetobacter baumannii* is one of the most important etiologies of nosocomial infections in recent years mainly because of increasing in frequency of multidrug and pan-resistant pathogens. Meningitis caused by this organism is a dilemma; because polymyxins are the only effective antibiotics against pan-resistant serotypes, but have poor penetration via blood brain barrier; however, it has still remained uncertain whether the intravenous therapy with these agents is an effective treatment with the sufficient concentration of the drug in the cerebrospinal fluid. Herein, we report a neonate who suffered from pan-resistant *A. baumannii* nosocomial meningitis successfully treated with intravenous colistin combined with meropenem and rifampin. It seems that intravenous colistin at least in combination with rifampin and meropenem might be considered as an option to try in patients in whom daily intrathecal injection or insertion of intraventricular device is not possible.

**Keywords:** *Acinetobacter baumannii*; Colistin; Meningitis; Multi-drug resistant; Neonate, Polymyxin

## INTRODUCTION

*Acinetobacter baumannii* is one of the most important etiologies of the nosocomial infection in recent years, mainly due to increasing frequency in hospital setting and development of multidrug and pan-resistant pathogens [1]. At this time, polymyxins are the only antibiotics which might be considered as the last chance for the treatment of pan-resistant serotypes [2, 3]. Meningitis caused by these organisms is still challenging as well as the treatment that has remained a dilemma because polymyxin E (colistin) has a poor penetration via the blood brain barrier and it is uncertain whether intravenous therapy with this antibiotic is an effective treatment with a sufficient concentration in the cerebrospinal fluid (CSF).

Many believe that it is necessary to use intraventricular (IVT) or intrathecal route (IT) in the treatment of meningitis with this antibiotic [2]. At this time, there is no clear guideline to define the proper strategy for the treatment of pan-resistant *A. baumannii* (PRA) meningitis in neonates. In addition, there are no randomized controlled studies conducted to evaluate the different treatments for *Acinetobacter* meningitis in pediatrics group and the current treatment regimen is based on the case reports and pharmacological data [4]. Herein, we report a neonate with PRA meningitis, successfully treated with colistin via intravenous (IV) route combined with using IV rifampin and meropenem and without IT or IVT antibiotic therapy.

We acknowledge that this case report was approved by Institutional Review Board (IRB) of Ali Asghar Children's Hospital (No: IR.IUMS.aach1395.20101).

## CASE REPORT

A two-day old female preterm neonate with gestational age of 34 weeks birth weighting 2,450 grams was admitted in the neonatal intensive care unit (NICU) of Ali Asghar Children's Hospital with omphalocele. Her mother was premature rupture of membrane (PROM) for more than 24 hours before caesarian section. She was evaluated in order to find the associated anomalies and had ventricular septal defect (VSD), patent ductus arteriosus (PDA) which was closed spontaneously and mild enlargement of the left atrium but normal ejection fraction on the echocardiography. Ultrasonography of the urinary tract revealed malrotation of kidneys and the right pelvis diameter of 7 mm. Her omphalocele was repaired with the primary closure and she was intubated and mechanically ventilated for four days and needed supplemental oxygen therapy for two other days before clinical deterioration. She had a peripherally inserted central catheter (PICC) from the first day of admission. On the seventh day of the post-operation, she unexpectedly became mottled, febrile and cyanotic. She had poor feeding and vomiting. Her blood pressure was in the normal range but she had tachycardia. Except in the decreased neonatal reflexes, there was no other neurological sign. Moreover; she had one episode of apnea that responded to skin stimulation. The full sepsis work up was conducted and her laboratory data was as follows: white blood cell (WBC) 15,700/mm<sup>3</sup> (neutrophil 80%, Band 3%, lymphocyte 16%), hemoglobin (Hb) 8.6 g/dl, platelet 386,000/mm<sup>3</sup>, and C-reactive protein (CRP) 119 mg/L. CSF analysis showed WBC 7,200/mm<sup>3</sup> (neutrophil 41%, lymphocyte 59%), glucose 15 mg/dl and protein 157 mg/dl. Blood and wound culture were negative but throat and CSF culture were positive for *A. baumannii* and the antibiotic susceptibility test by the disk diffusion method showed resistance to cefuroxime, ceftazidime, ceftriaxone, cefepime, imipenem, ciprofloxacin, cotrimoxazole, piperacillin/tazobactam, amikacin and sensitivity only to colistin. OXA \_ Gyr \_ VER- AMP- KPC -VIM-NDM- IMP resistance genes were detected by a multiplex PCR method.

The brain ultrasonography was normal but the brain CT scan without contrast revealed a diffuse cerebral white matter hypodensity in favor of edema. The ventricles and subarachnoid spaces were normal in the appearance and there was no midline shift.

Regarding first diagnosis of nosocomial septicemia, she was treated empirically using vancomycin and meropenem and then switched to IV colistin, meropenem and rifampin, when the result of antibiotic sensitivity test showed a pan- resistant strain only susceptible to colistin.

**Table 1.** Serial CSF analysis results of the patient

CSF analysis indices day	1st	3rd	7th	21st
WBC (mm <sup>3</sup> )	7,200	32	0	0
Neutrophil (%)	41	80	0	0
Lymphocyte (%)	59	20	0	0
RBC (mm <sup>3</sup> )	15	5,120	0	3,200
Glucose (mg/dl)	10	15	25	25
Protein (mg/dl)	157	155	130	107
Appearance	Turbid	Clear	Clear	Clear
Gram stain	Negative	Negative	Negative	Negative
Culture	<i>Acinetobacter baumannii</i>	Negative	Negative	Negative

CSF, cerebrospinal fluid; WBC, white blood cell; RBC, red blood cell.

The dosage of colistin and meropenem administered was 20,000 unit/kg every 8 hours and 40 mg/kg every 12 hours parenterally infused in one hour respectively. Rifampin was infused at a dosage of 10 mg/kg every 12 hours for 30 minutes and CRP reached <1 mg/L within 7 days. The patient was treated for 21 days and CSF analysis at termination of treatment revealed WBC 0/mm<sup>3</sup>, glucose 21 mg/dl and protein 107 mg/dl. The results of CSF analysis of the serial lumbar punctures are shown in the **Table 1**. Six months of follow up showed the normal auditory brain stem response and normal neurodevelopment.

## DISCUSSION

*A. baumannii* is a commensal Gram negative coccobacillus which is ubiquitous in both natural and hospital environment and may be a part of normal skin flora in about 25% of the population [5].

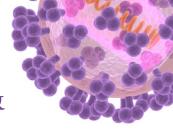
*A. baumannii* infections are uncommon and usually involve the organ systems with a high fluid content such as respiratory tract, CSF, peritoneal cavity and urinary tract with nosocomial pneumonia being the most common clinical manifestation [1].

The risk factors associated with nosocomial infections due to this microorganism include mechanical ventilation, prolonged hospitalization, intensive care unit admission, recent surgical procedures, central venous catheter use, prior hospitalization, and nursing home residence [6].

*Acinetobacter* meningitis may occur following neurosurgery, traumatic head injury or/and metastatic infection in bacteremic patients [7]. Although *A. baumannii* is not the dominant cause of nosocomial infection in our NICU, concomitant admission of two neonates with *A. baumannii* infection might be the cause of nosocomial infection with this organism in our case.

Resistance of *Acinetobacter* to more than two antibiotic classes of anti-pseudomonal cephalosporins, anti-pseudomonal carbapenems, ampicillin–sulbactam, fluoroquinolones and aminoglycosides is defined as multi drug resistant (MDR) [9]. Pan-resistant *Acinetobacter* (PRA) is defined as a resistance to all these five classes of antibiotics [8].

Meningitis caused by MDR and PRA spp. is a main problem due to limited therapeutic choices, and probably more complications and longer duration of the treatment [5].



In addition to potential life threatening side effects including nephrotoxicity, neurotoxicity and neuromuscular blockade, most studies suggest poor penetration of intravenous polymyxin in CSF [9-14]. There are several reports representing the failure with systemic therapy alone; whereas, the successful outcomes more likely achieved with IVT or IT instillation of colistin in children with or without concurrent systemic therapy [10-14]. On the other hand, there are few case reports revealing the successfulness of IV treatment of colistin without IVT or IT route [8, 15-18]. Anyhow, there is not a clear guideline in neonates and children for the treatment of PRA meningitis.

Our case had meningitis with a PRA which was only sensitive to colistin. The parents of our case did not accept insertion of extra ventricular device for intra ventricular injection of colistin, so we decided to use combination therapy of intravenous colistin, rifampin and meropenem. As far as the uncertainty about the definite dosage of these antibiotics in premature neonates, we used the suggested dosage of these drugs beyond the newborn period [19]. Serial CSF analysis showed decreasing in WBC count, protein and increasing in glucose level and after 7 days of treatment WBC count of the CSF reached to zero. Whether IV colistin solely or in combination with rifampin and meropenem could clear the CSF of our patient is not well-defined, but this case report is at least an example showing that IV combination therapy might be effective in clearance of the CSF in PRA meningitis and an option to try in the patients for whom daily intrathecal injection or insertion of IVT device is not possible.

## REFERENCES

1. Kim BN, Peleg AY, Lodise TP, Lipman J, Li J, Nation R, Paterson DL. Management of meningitis due to antibiotic-resistant *Acinetobacter* species. *Lancet Infect Dis* 2009;9:245-55.  
[PUBMED](#) | [CROSSREF](#)
2. Mehar V, Zade P, Joshi M, Rajput N, Bhatambar G. Neonatal ventriculitis with multi drug resistant *Acinetobacter baumannii*: a case report and review of literature. *Pediatr Therapeut* 2012;2:1-3.  
[CROSSREF](#)
3. Katragkou A, Roilides E. Successful treatment of multidrug-resistant *Acinetobacter baumannii* central nervous system infections with colistin. *J Clin Microbiol* 2005;43:4916-7.  
[PUBMED](#) | [CROSSREF](#)
4. Tuon FF, Penteado-Filho SR, Amarante D, Andrade MA, Borba LA. Mortality rate in patients with nosocomial *Acinetobacter* meningitis from a Brazilian hospital. *Braz J Infect Dis* 2010;14:437-40.  
[PUBMED](#) | [CROSSREF](#)
5. Piparsania S, Rajput N, Bhatambare G. Intraventricular polymyxin B for the treatment of neonatal meningo-ventriculitis caused by multi-resistant *Acinetobacter baumannii*--case report and review of literature. *Turk J Pediatr* 2012;54:548-54.  
[PUBMED](#)
6. Fishbain J, Peleg AY. Treatment of *Acinetobacter* infections. *Clin Infect Dis* 2010;51:79-84.  
[PUBMED](#) | [CROSSREF](#)
7. Lowman W, Kalk T, Menezes CN, John MA, Grobusch MP. A case of community-acquired *Acinetobacter baumannii* meningitis - has the threat moved beyond the hospital? *J Med Microbiol* 2008;57:676-8.  
[PUBMED](#) | [CROSSREF](#)
8. Saleem AF, Shah MS, Shaikh AS, Mir F, Zaidi AK. *Acinetobacter* species meningitis in children: a case series from Karachi, Pakistan. *J Infect Dev Ctries* 2011;5:809-14.  
[PUBMED](#) | [CROSSREF](#)
9. Cascio A, Conti A, Sinardi L, Iaria C, Angileri FF, Stassi G, David T, Versaci A, Iaria M, David A. Post-neurosurgical multidrug-resistant *Acinetobacter baumannii* meningitis successfully treated with intrathecal colistin. A new case and a systematic review of the literature. *Int J Infect Dis* 2010;14:e572-9.  
[PUBMED](#) | [CROSSREF](#)
10. Benifla M, Zucker G, Cohen A, Alkan M. Successful treatment of *Acinetobacter meningitis* with intrathecal polymyxin E. *J Antimicrob Chemother* 2004;54:290-2.  
[PUBMED](#) | [CROSSREF](#)

11. Bukhary Z, Mahmood W, Al-Khani A, Al-Abdely HM. Treatment of nosocomial meningitis due to a multidrug resistant *Acinetobacter baumannii* with intraventricular colistin. Saudi Med J 2005;26:656-8.  
[PUBMED](#)
12. Fernandez-Viladrich P, Corbella X, Corral L, Tubau F, Mateu A. Successful treatment of ventriculitis due to carbapenem-resistant *Acinetobacter baumannii* with intraventricular colistin sulfomethate sodium. Clin Infect Dis 1999;28:916-7.  
[PUBMED](#) | [CROSSREF](#)
13. Ng J, Gosbell IB, Kelly JA, Boyle MJ, Ferguson JK. Cure of multiresistant *Acinetobacter baumannii* central nervous system infections with intraventricular or intrathecal colistin: case series and literature review. J Antimicrob Chemother 2006;58:1078-81.  
[PUBMED](#) | [CROSSREF](#)
14. Hu J, Robinson JL. Systematic review of invasive *Acinetobacter* infections in children. Can J Infect Dis Med Microbiol 2010;21:83-8.  
[PUBMED](#) | [CROSSREF](#)
15. Jiménez-Mejías ME, Pichardo-Guerrero C, Márquez-Rivas FJ, Martín-Lozano D, Prados T, Pachón J. Cerebrospinal fluid penetration and pharmacokinetic/pharmacodynamic parameters of intravenously administered colistin in a case of multidrug-resistant *Acinetobacter baumannii* meningitis. Eur J Clin Microbiol Infect Dis 2002;21:212-4.  
[PUBMED](#) | [CROSSREF](#)
16. Fulnecky EJ, Wright D, Scheld WM, Kanawati L, Shoham S. Amikacin and colistin for treatment of *Acinetobacter baumannii* meningitis. J Infect 2005;51:e249-51.  
[PUBMED](#) | [CROSSREF](#)
17. Jiménez-Mejías ME, Becerril B, Márquez-Rivas FJ, Pichardo C, Cuberos L, Pachón J. Successful treatment of multidrug-resistant *Acinetobacter baumannii* meningitis with intravenous colistin sulfomethate sodium. Eur J Clin Microbiol Infect Dis 2000;19:970-1.  
[PUBMED](#) | [CROSSREF](#)
18. Levin AS, Barone AA, Penço J, Santos MV, Marinho IS, Arruda EA, Manrique EI, Costa SF. Intravenous colistin as therapy for nosocomial infections caused by multidrug-resistant *Pseudomonas aeruginosa* and *Acinetobacter baumannii*. Clin Infect Dis 1999;28:1008-11.  
[PUBMED](#) | [CROSSREF](#)
19. Garcia C, McCracken GH. Antibacterial therapeutic agents. In: Cherry JD, Gail J, Demmler-Harrison JG, Kaplan SL, Hotez P, Steinbach WJ, eds. Feigin and Cherry's textbook of pediatric infectious diseases. Philadelphia: Saunders; 2014;3182–241.