



# Endoscopic negative pressure therapy for upper gastrointestinal leaks: description of a fashioned device allowing simultaneous enteral feeding

Rami Archid, MD,<sup>1</sup> Fateh Bazerbachi, MD,<sup>2</sup> Maria Cecily Thomas,<sup>3</sup> Alfred Königsrainer, MD,<sup>1</sup> Doerte Wichmann, MD<sup>1</sup>

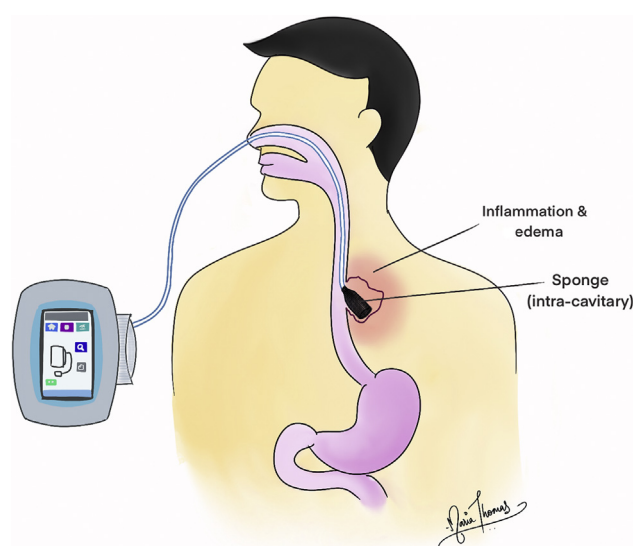
Endoscopic negative pressure therapy (ENPT) represents a modern and effective treatment strategy for gastrointestinal tract wall defects. The intracavitary treatment strategy is based on placing a sponge within the defect cavity (Fig. 1), whereas the intraluminal treatment approach is based on placing a drainage device within the visceral lumen overlapping the defect area (Fig. 2).<sup>1</sup> These strategies complement each other and are successful treatments for gastrointestinal perforation and postoperative adverse events in the upper or lower GI tract.<sup>2</sup>

An open-pore film drainage (OFD) device was first described in 2015 by Loske et al<sup>3</sup> and has been used for several indications in the upper GI tract, urinary tract, and other sites.<sup>2</sup> OFD may offer several advantages in terms of easier placement, adhesiveness to the wound base, less frequent reintervention, and better fluid mobilization.<sup>4,5</sup> In this video (Video 1, available online at [www.giejournal.org](http://www.giejournal.org)), we present the assembly and placement procedure of a fashioned OFD device that allows simultaneous enteral feeding.

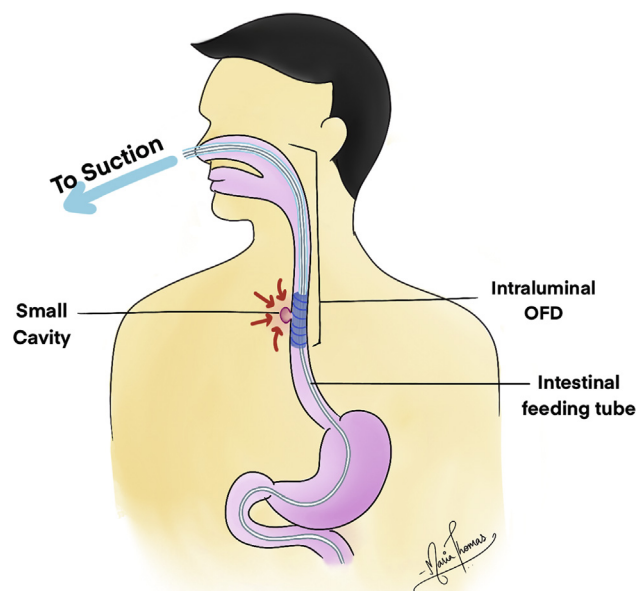
## OFD DEVICE ASSEMBLY AND PLACEMENT

The demonstrated OFD device is fashioned by wrapping an open-pore double-layered drainage film (Suprasorb CNP Drainage Film; Lohmann & Rauscher International GmbH & Co KG, Rengsdorf, Germany) around the distal end of a 16F gastric decompression tube (Freka EasyIn, ENFit, Fresenius Kabi AG, Bad Homburg, Germany) (Figs. 3 and 4). The use of Suprasorb CNP and Freka EasyIn for fashioning an OFD is an off-label use.


A standard gastroscope with a working channel width of 3.2 mm is passed transorally into the jejunum. The working channel of the endoscope should be lubricated with 1 ampule of medium-chain triglyceride oil. The 8F feeding tube (Freka EasyIn, ENFit, Fresenius Kabi AG, Bad Homburg, Germany) is introduced through the working channel of the gastroscope into the jejunum, and the endoscope is exchanged out of the patient. Next, the feeding tube is



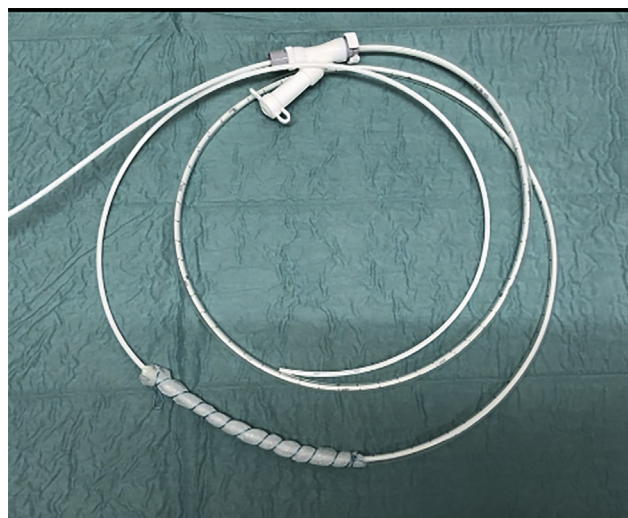
**Figure 1.** Intracavitary endoscopic negative pressure therapy. The vacuum device (sponge) is placed within the defect cavity.



**Figure 2.** Intraluminal endoscopic negative pressure therapy. The vacuum device (open-pore film drainage) is placed within the lumen of the GI tract.



**Figure 3.** Equipment needed to assemble the open-pore film drainage device: dual-lumen tube for intestinal feeding (8F) and gastric decompression (16F), drainage film, and suturing material.



**Figure 4.** Assembled open-pore film drainage device with (A) a vacuum treatment segment and (B) an intestinal feeding tube.

rerouted from the mouth to the nose with a nasal exchange catheter.

Over the now-transnasal feeding tube, the OFD-fashioned decompression tube is passed to the desired treatment location using the Seldinger technique. The feeding tube stiffness alone will allow the gastric tube to be pushed to the treatment area. Positioning of the drainage film is guided endoscopically. The proximal end of the gastric decompression tube is then connected to an electronic vacuum device generating continuous negative pressure of  $-125$  mm Hg (KCI V.A.C. Ulta or V.A.C. Freedom; KCI USA Inc, San Antonio, Tex, USA).

Endoscopic control of treatment success and concomitant changing of the device is performed every 4 to 5 days, or earlier in the case of interruption of therapy due to device migration.

[Video 1](#) relays details of the device assembly and placement. Variants of OFD assembly are described elsewhere.<sup>6</sup>

## TREATMENT ALGORITHM

ENPT is used in our department as a first-line endoscopic treatment for the following indications in the upper GI tract:

- Surgical anastomotic leaks
- Iatrogenic and traumatic perforations of the esophagus or duodenum
- Staple line leaks after sleeve gastrectomy

When a GI leak/perforation is suspected, a CT scan is obtained, and endoscopy is performed in equivocal cases. Proceeding with ENPT is possible during the index endoscopy as a single-step intervention. ENPT can be a stand-alone treatment for leaks resulting in a collection smaller than 3 cm in the largest diameter.

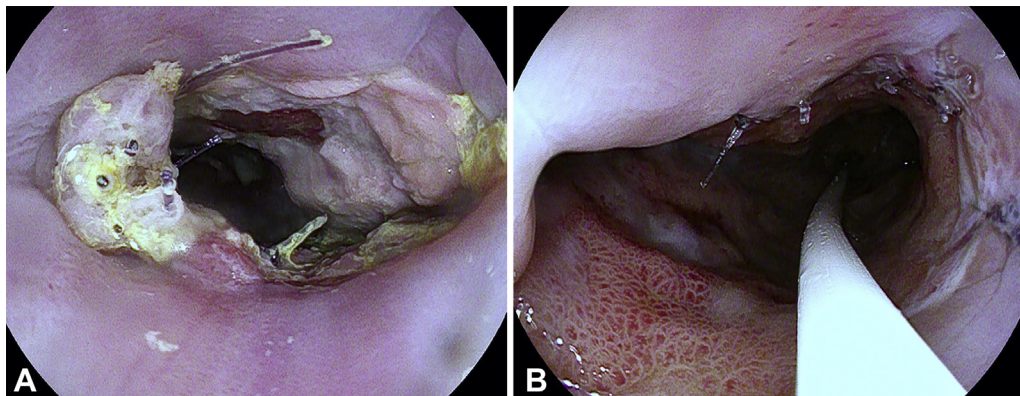
Laparoscopy/thoracoscopy is indicated in septic patients and those showing free perforation or abscess formation/defect cavity  $\geq 5$  cm in the largest diameter. In these cases, endoscopy can be performed intraoperatively, and ENPT can be commenced thereafter. Single abscesses ( $>3$  cm in the largest diameter) may be addressed by interventional radiology, in addition to ENPT.

The ENPT placement strategy hinges on the size and characteristics of the mural defect and wound cavity.

**TABLE 1. Endoscopic negative pressure therapy paradigms using a sponge or handmade open-pore film drainage<sup>6</sup>**

ENPT device	Sponge	OFD
Outer diameter of device	15-30 mm	4-8 mm
Debridement effect	+++	+
Mobilization of fluids	+	+++
Adhesion at the wound base	++	-
Treatment intervals (day)	3-5	3-7
Adverse event risk	+	-

ENPT, endoscopic negative pressure therapy; OFD, openpore film drainage.



**Figure 5. A,** Endoscopic view of the cervical esophagostomy on the third postoperative day. Intraluminal endoscopic negative pressure therapy applied using open-pore film drainage. **B,** Repeat endoscopy on 13th postoperative day showed significant restoration and healing of the anastomosis.

Sponges are placed when wall defects are larger than 2 cm or when a larger putrid or necrotic defect cavity is evident. OFD is applied for smaller wall defects and preferred for intraluminal placement. Characteristics of both methods have been discussed elsewhere in detail<sup>2,6</sup> (Table 1).

## CLINICAL CASE

A 61-year-old man was treated for Siewert type I<sup>7</sup> gastroesophageal junction adenocarcinoma. Neoadjuvant chemotherapy using a FLOT regimen (5-fluorouracil, leucovorin, oxaliplatin, docetaxel) with trastuzumab was followed by esophagectomy with cervical esophagogastrotomy. On postoperative day 3, sepsis developed. Bedside endoscopy showed a compromised anastomosis (Fig. 5A) without obvious leakage. Endoscopic OFD was performed to promote healing of the anastomosis. Repeat endoscopy 10 days after the procedure showed significant improvement (Fig. 5B).

## DISCUSSION

Although standard endoscopic therapies, such as self-expanding metal stents or advanced clip systems, can be implemented in GI leaks to close mucosal defects and restore luminal continuity, they do not address

the resultant extraluminal fluid collections, which may become infected. However, ENPT paradigms promote the healing process of these injuries through constant mobilization of wound secretions and debris, removal of infected material, mitigation of interstitial edema, modification of cellular signaling milieu, stimulation of tissue perfusion and wound granulation, and rapid fibrin deposition and epithelialization, among other factors.<sup>8</sup> Other approaches for endoscopic internal drainage, such as placement of double-pigtail stents, work through passive drainage from the inflammatory side.<sup>9</sup> This passive approach may not be effective when leaks are located in the thorax, owing to the inspiration-associated negative pressure toward the extraluminal cavity, or in the case of an unorganized collection.<sup>9</sup>

The demonstrated OFD tool, with a diameter of 4 to 8 mm, makes it easier to establish ENPT for small defects and is optimal for intraluminal placement because of the reduced adhesiveness, easy removal, and decreased damage to the surrounding tissue.<sup>2,5</sup> The possibility of simultaneous enteral feeding is critical, especially when prolonged therapy is needed, given the need for adequate nutrition to promote healing in patients often afflicted with cancer or sepsis. Moreover, ENPT is not solely an inpatient treatment, given that it can be continued in the outpatient setting when sepsis is controlled.



## SUMMARY

ENPT using the OFD method is an effective strategy to heal GI leaks and anastomotic defects. The capacity for simultaneous feeding is paramount and advantageous, obviating the need for 2 transnasal catheters and allowing easier placement in the target lesion, with minimal tissue adhesiveness.

## DISCLOSURE

*All authors disclosed no financial relationships.*

*Abbreviations: ENPT, endoscopic negative pressure therapy; OFD, open-pore film drainage.*

## REFERENCES

1. Loske G, Schorsch T, Muller C. Intraluminal and intracavitary vacuum therapy for esophageal leakage: a new endoscopic minimally invasive approach. *Endoscopy* 2011;43:540-4.
2. Archid R, Wichmann D, Klingert W, et al. Endoscopic vacuum therapy for staple line leaks after sleeve gastrectomy. *Obes Surg* 2020;30:1310-5.
3. Loske G, Schorsch T, van Ackeren V, et al. Endoscopic vacuum therapy in Boerhaave's syndrome with open-pore polyurethane foam and a new open-pore film drainage. *Endoscopy* 2015;47:E410-1.
4. Kuehn F, Loske G, Schiffmann L, et al. Endoscopic vacuum therapy for various defects of the upper gastrointestinal tract. *Surg Endosc* 2017;31:3449-58.
5. Loske G, Schorsch T, Rucktaeschel F, et al. Open-pore film drainage (OFD): a new multipurpose tool for endoscopic negative pressure therapy (ENPT). *Endosc Int Open* 2018;6:E865-71.
6. Wichmann D, Stuker D, Schempf U, et al. Endoscopic negative pressure therapy with open-pore film drainage and open-pore polyurethane sponge drainage for iatrogenic perforation of the esophagus. *Endoscopy* 2020;52:377-82.
7. Siewert JR, Stein HJ. Classification of adenocarcinoma of the oesophago-gastric junction. *Br J Surg* 1998;85:1457-9.
8. Willy C, von Thun-Hohenstein H, von Lubken F, et al. [Experimental principles of the V.A.C.-therapy – pressure values in superficial soft tissue and the applied foam]. *Zentralbl Chir* 2006;131:S50-61.
9. Kumbhari V, Abu Dayyeh BK. Keeping the fistula open: paradigm shift in the management of leaks after bariatric surgery? *Endoscopy* 2016;48:789-91.

Department of General, Visceral and Transplant Surgery, Eberhard-Karls-University Hospital, Tuebingen, Germany (1), Division of Gastroenterology, Department of Medicine, Massachusetts General Hospital and Harvard Medical School, Boston, Massachusetts (2), Harvard Medical School, Boston, Massachusetts (3).

If you would like to chat with an author of this article, you may contact Dr Archid at [ramiarchid@gmx.net](mailto:ramiarchid@gmx.net).

Copyright © 2021 American Society for Gastrointestinal Endoscopy. Published by Elsevier Inc. This is an open access article under the CC BY-NC-ND license (<http://creativecommons.org/licenses/by-nc-nd/4.0/>).

<https://doi.org/10.1016/j.vgie.2020.10.009>

### Facebook

Follow *VideoGIE* on Facebook to receive the latest news, updates, and article links. Visit <https://www.facebook.com/videogiejournal/> and keep checking back to view our most recent posts.