

CASE SERIES

Reconstruction of Dorsal Hand Burn Scars Using Microdissected Tailoring of the Free Anterolateral Thigh Flap

Tran Thiet Son^{1,2}, Nguyen-Vu Hoang^{1,3}, Pham-Thi Viet Dung^{1,3}, Phan-Van Tan¹, Truong The Duy¹, Nguyen Minh Duc⁴

¹Department of Plastic and Reconstructive Surgery, Hanoi Medical University, Hanoi, Vietnam

²Department of Plastic and Aesthetic Surgery, Bach Mai Hospital, Hanoi, Vietnam

³Department of Plastic Surgery, Saint Paul General Hospital, Hanoi, Vietnam

⁴Department of Radiology, Pham Ngoc Thach University of Medicine, Ho Chi Minh City, Vietnam

Corresponding author: Nguyen-Vu Hoang, MD. Department of Plastic and Reconstructive Surgery, Hanoi Medical University, Hanoi, Vietnam. E-mail: nvuhoangmd@gmail.com. ORCID ID: 0000-0001-7079-2734.

doi: [10.5455/aim.2022.30.125-128](https://doi.org/10.5455/aim.2022.30.125-128)

ACTA INFORM MED. 2022 JUN 30(2): 125-128

Received: May 03, 2022

Accepted: Jun 06, 2022

© 2022 Tran Thiet Son, Nguyen-Vu Hoang, Pham-Thi Viet Dung, Phan-Van Tan, Truong The Duy, Nguyen Minh Duc

This is an Open Access article distributed under the terms of the Creative Commons Attribution Non-Commercial License (<http://creativecommons.org/licenses/by-nc/4.0/>) which permits unrestricted non-commercial use, distribution, and reproduction in any medium, provided the original work is properly cited.

ABSTRACT

Background: Currently, large defects of the dorsum and finger of the hand pose a great challenge to plastic surgeons. The most difficult problem is finding a suitable material that has a large area and a thin, reliable blood supply and can be tailored into many small flaps to cover the fingers. **Case series:** We present the cases of two patients admitted to our hospital with scars on the dorsal side of the hand after gas burns. The defects after scar release were reconstructed by microdissected tailoring of the free anterolateral thigh flap. Complete survival was achieved for all flaps, including the small flaps tailored for finger defects. The function and aesthetics of the hands significantly improved. The patients were satisfied after the pain, itching, and burning symptoms of the scar were relieved. **Conclusion:** Microdissected tailoring of the free anterolateral thigh flap is an ideal method for addressing hand defects. The microdissected tailoring technique allows the surgeon to construct a thin flap with a reliable blood supply from the perforator.

Keywords: burn scar, anterolateral thigh flap, hand reconstruction, thin flap, microdissected tailoring.

1. BACKGROUND

The treatment plan for hypertrophic scarring of the dorsal hand includes scar excision, soft tissue contracture releasing, the reconstruction of tendons and joints, and defect covering. This defect requires a thin flap with a compatible skin color that can prevent post-operation tendon adhesion (1). The main obstacle is finding an adequate reconstructive material. The cover material must be congruous with the hand skin in structure, color, elasticity, and thickness to achieve suitable functional and aesthetic results. The free anterolateral thigh flap (ALTF), first introduced by Song et al. in 1984, is a well-known versatile flap (2).

2. OBJECTIVE

This paper presents the case reports of two patients with extensive hypertrophic scars of the dorsal hand and finger after gas burns (one patient had burn scars on both hands and had undergone two surgeries), which were reconstructed by micro-

dissected tailoring of the free ALTF.

3. CASE PRESENTATION

CASE 1

A 43-year-old male patient was admitted to our hospital with burn scars on both hands after a gas burn 6 months previously. On the right hand, a hypertrophic scar extended from the wrist to the distal interphalangeal joint. The extensor tendon and interdigit webspace were adhered to the scar tissue. The scar was indurated and itchy with a scratching-induced ulcer.

For the first operation on the right hand, the scar was radically excised and dissected to release the extensor tendon, and microdissected tailoring of the free ALTF was utilized to cover the defect. The flap size was 19 × 14 cm, and the perforator was type 1 according to the Kimura classification. The flap was thinned using the microdissection technique introduced by Kimura et al. (3, 4).

The small branch stem from the perforator was meticulously dis-

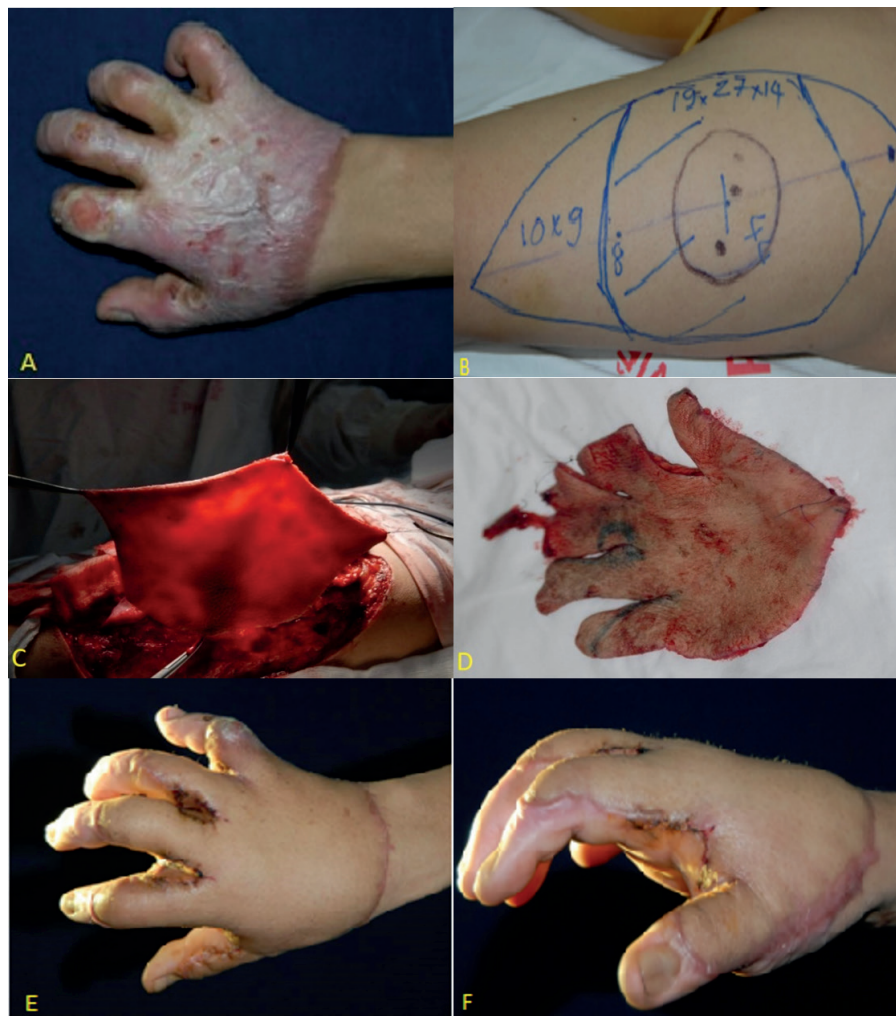

Figure 1. Microdissected tailoring of the free anterolateral thigh flap to reconstruct the right hand. **A.** Burn scar on the right hand. **B.** Flap design. **C.** Microdissected flap. **D.** Microdissected tailoring. **E, F.** Six months after operation.

sected under a microscope. Fat lobules were eliminated from the distal margin to the point at which their distance to the perforator was 1.5 cm. The thickness of the flap after dissection was 2.5 mm. Subsequently, the flap was designed and cut using the tailoring method, and the subcutaneous vessels were secured. The resulting flap had the shape of a glove (Figures 1 and 2). The surgery on the left hand was conducted 3 months later using the same technique. Six months after the operation, the flaps had completely survived on both hands, and the color was compatible with the hand skin. The itching symptom vanished and did not reappear at the scar of the flap border. Flexion movement dramatically improved with the successful replacement of the scar tissue with the healthy flap tissue. Because of the symptoms of induration, parts of the extensor tendons were fibrotic, so we observed only marginal improvement. The patient was able to perform daily activities, including wearing gloves and long sleeve shirts and holding a bowl while eating.

CASE 2

A 41-year-old female patient was admitted to our hospital with a burn scar on the right hand from a gas burn 14 months previously. The indurating, hypertrophic scar extended across the dorsal hand and fingers of the right hand. Contractive scar tissue caused a deformity in finger

anatomy, and the patient could not conduct flexion or extension movements. The itching and pain symptoms were burdensome for the patient. The surgery procedures were the same as in case 1, with a flap size of 23×14 cm and a type 1 perforator (Figure 3). The microdissected tailoring technique was used to reduce the flap thickness from 23 mm to 3 mm. Six months after the procedure, the patient showed improvement in hand function.

4. DISCUSSION

A flash burn on the dorsum of the hand caused by an explosion of natural gas, propane, or gasoline often causes severe damage over a large area. This can result in hypertrophic scar formation, contracture deformity, and finger adhesion, which lead to detrimental functional deficits and poor aesthetic outcomes. In addition, hand burn scars can cause itching, ulcers, pain, and discomfort. Surgical treatment is often indicated to restore hand function. Replacing all of the scar tissue with healthy skin is the primary goal of plastic surgery. However, it is difficult to find a material with harmonious color, similar texture and thickness, and sufficient area that will result in a lower degree of deformation after surgery. The skin on the dorsum of the hand is very thin and has high elasticity, allowing the fingers to easily perform complex

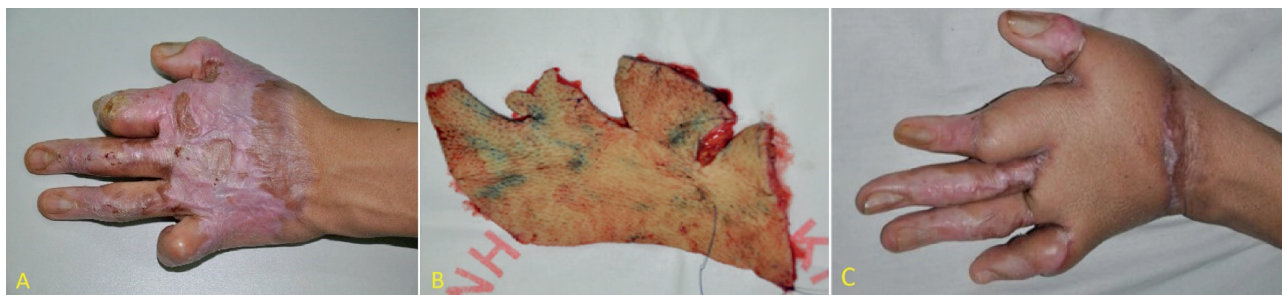

Figure 2. Microdissected tailoring of the free anterolateral thigh flap to reconstruct the left hand. **A:** Burn scar of the dorsal hand. **B:** Microdissected tailoring. **C:** Six months after operation.

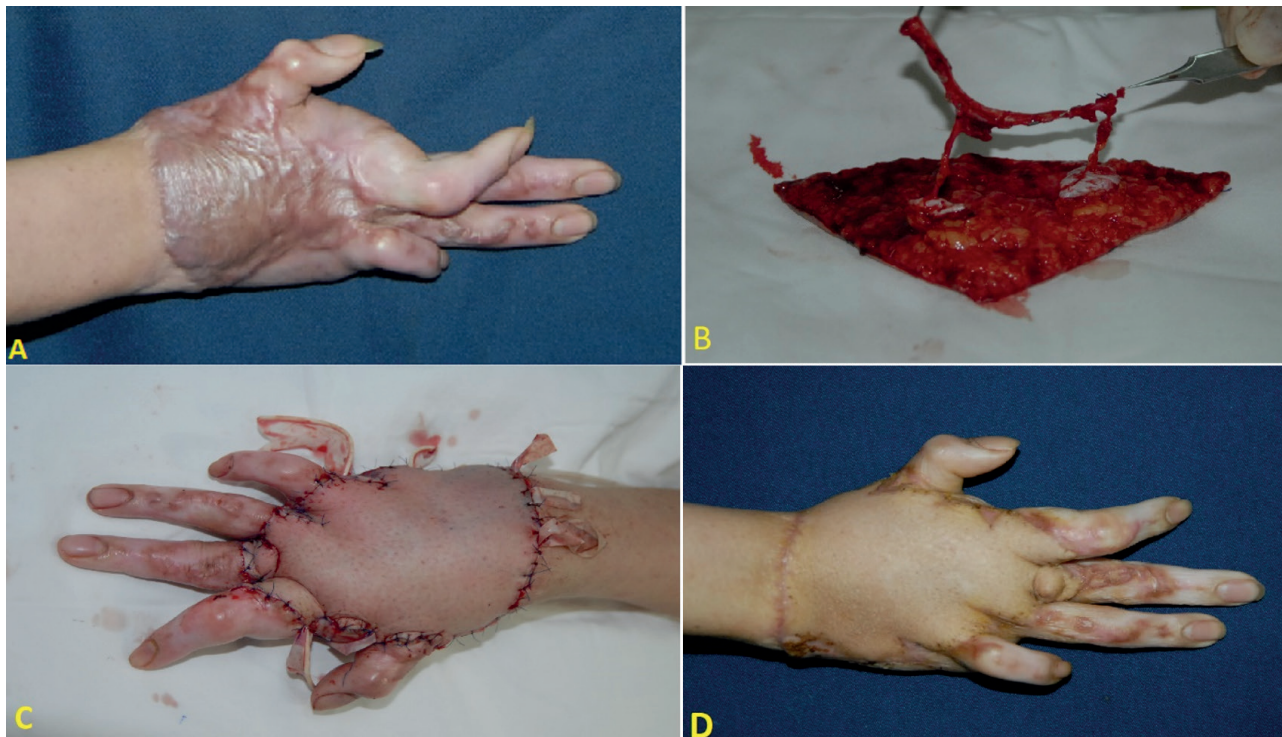


Figure 3. Free microdissected tailoring anterolateral thigh flap to reconstruct the right hand. **A:** Hypertrophic scar. **B:** Microdissected flap. **C:** Right hand after the operation. **D:** Six-month follow-up.

movements. Gasoline burns are typically deep burns, and the tendons may be exposed after the removal of the full thickness of the scar; therefore, a skin graft is not a feasible treatment (5). To completely cover the dorsum of the hand and fingers, it is necessary to use a large, thin flap so that the flap can be tailored. Regional flaps, such as posterior interosseous flap and radial forearm flap, and free flaps, such as medial sural flap, radial forearm flap, and lateral arm flap, typically do not meet this requirement (6). The random pedicled abdominal flap is an alternative solution (covering the defect and excising the pedicle), but the disadvantage of this flap is its thickness, which requires thinning surgery (7, 8).

The central part of the ALTF containing the perforator was thinned to cover the dorsum of the hand, and the distal end of the flap was dissected according to the defects of the fingers. ALTF debulking is typically achieved by liposuction or direct excision in the second phase (9). However, this technique is only suitable for covering a simple surface without a three-dimensional structure. The ALTF can be thinned during operation by the removal

of the adipose tissue on the superficial fascia (without microdissection), as suggested by Kimura. Flap thinning is safe if the deep fascia within 2 to 3 cm of the perforator is preserved. During this procedure, the direction of perforators and their branches are predicted, and adipose tissue removal is restricted to the area with the least expected vascular distribution. Therefore, this can be considered a blind procedure and can sometimes damage the flap vascularization. The Kimura classification divides perforator flaps into three types according to the path of the perforators in the adipose tissue: type 1 perforators run within the adipose tissue and extend nearly perpendicular into the subcutaneous plexus (50%); type 2 perforators run into the adipose tissue and extend to the side of the flap, within 2 cm of it (35%); and type 3 perforators widen on the deep fascia, extending roughly parallel to the deep fascia for a certain distance and gradually entering the adipose tissue (15%). Type 1 and 2 perforator flaps can be safely thinned by microdissection, whereas type 3 flaps cannot be thinned safely (10).

To increase the safety of flap thinning, Kimura et al.

used the microdissection technique to meticulously dissect the small blood vessels in the fatty tissue and gradually remove each fat particle from the periphery to the center of the flap to prevent damage to the perforators. As a result, the perforated flaps could be removed from the fatty tissue and completely nourished by the subcutaneous vascular network (3). Microdissection not only provides a thin flap but also allows a clear view of the direction of the exposed small vessels and precise determination of their reference to the skin (the branches of the perforator into the subepidermal layer); in this way, the flap can be completely cut to minimize the impact on the flap's blood supply (4). This is the basis of the development of microdissected tailoring (4). This technique allows the central part of the flap containing the perforator to be placed on the dorsum of the hand and allows the distal end to be safely cut according to the defect shape of the dorsal fingers (11).

5. CONCLUSION

Microdissected tailoring of the free ALTF is an ideal technique for hand burn scar reconstruction. The microdissection technique allows the surgeon to preserve the small branches of the perforator, which increases the efficacy and safety of the operation.

- **Ethical approval and Declaration of patient consent:** This study was approved by the Ethics Committee of Hanoi Medical University (Ref: 06NCS17/HĐĐDBHYHN). All participants provided written informed consent prior to enrolment in the study. Privacy and confidentiality of the patient records were adhered to, in managing the clinical information in the conduct of this research.
- **Author's contribution:** Nguyen-Vu Hoang and Tran Thiet Son gave a substantial contribution to the acquisition, analysis, and data interpretation. Nguyen-Vu Hoang and Pham-Thi Viet Dung had a part in preparing the article for drafting and revising it critically for important intellectual content. Each author gave final approval of the version to be published and agreed to be accountable for all aspects of the work in ensuring that questions related to the accuracy or integrity of any part of the work are appropriately investigated and resolved.
- **Conflicts of interest:** There are no conflicts of interest to declare.
- **Financial support and sponsorship:** Nil.

REFERENCES

1. Tocco-Tussardi I, Presman B, Cherubino M, Garusi C, Bassetto F. Microsurgery "without borders": new limits for reconstruction of post-burn sequelae in the humanitarian setting. *Ann Burns Fire Disasters*. 2016 Mar 31; 29(1): 66-70.
1. Song YG, Chen GZ, Song YL. The free thigh flap: a new free flap concept based on the septocutaneous artery. *Br J Plast Surg*. 1984 Apr; 37(2): 149-159. doi: 10.1016/0007-1226(84)90002-x.
2. Kimura N, Satoh K, Hosaka Y. Microdissected thin perforator flaps: 46 cases. *Plast Reconstr Surg*. 2003 Dec; 112(7): 1875-1885. doi: 10.1097/01.PRS.0000091248.41007.2D.
3. Kimura N, Saitoh M, Okamura T, Hirata Y, Itoh Y, Sumiya N. Concept and anatomical basis of microdissected tailoring method for free flap transfer. *Plast Reconstr Surg*. 2009 Jan; 123(1): 152-162. doi: 10.1097/PRS.0b013e3181934756.
4. Webster GV, Rowland WD. Skin-grafting the Burned Dorsum of the Hand. *Ann Surg*. 1946 Aug; 124(2): 449-462.
5. Yannascoli SM, Thibaudeau S, Levin LS. Management of soft tissue defects of the hand. *J Hand Surg Am*. 2015 Jun; 40(6): 1237-1244; quiz 1245. doi: 10.1016/j.jhssa.2014.12.037.
6. Putri AC, Runisa PA, Hasibuan L, Faried A, Mose JC. The use of modified glove-like abdominal flap for reconstruction of contracture following burns of dorsal hand and fingers: A case report. *Int J Surg Case Rep*. 2022 Mar 29; 94: 106962. doi: 10.1016/j.ijscr.2022.106962.
7. Jabaiti S, Ahmad M, AlRyalat SA. Reconstruction of Upper Extremity Defects by Random Pedicle Abdominal Flaps: Is It Still a Valid Option? *Plast Reconstr Surg Glob Open*. 2020 Mar 20; 8(3): e2687. doi: 10.1097/GOX.0000000000002687.
8. Ren J, Lu L, Gao F. The use of the posterior interosseous artery flap and anterolateral thigh flap for post-traumatic soft tissue reconstruction of the hand. *Medicine (Baltimore)*. 2021 Jul 2; 100(26): e26517. doi: 10.1097/MD.00000000000026517.
9. Kimura N, Satoh K, Hasumi T, Ostuka T. Clinical application of the free thin anterolateral thigh flap in 31 consecutive patients. *Plast Reconstr Surg*. 2001 Oct; 108(5): 1197-1208; discussion 1209-10. doi: 10.1097/00006534-200110000-00015.
10. Kimura N, Saito M, Itoh Y, Sumiya N. Giant combined microdissected thin thigh perforator flap. *J Plast Reconstr Aesthet Surg*. 2006; 59(12): 1325-9. doi: 10.1016/j.bjps.2006.06.019.