



Received: 2015.10.29
Accepted: 2015.12.13
Published: 2016.06.22

Effectiveness of Computed Tomography Guided Percutaneous Radiofrequency Ablation Therapy for Osteoid Osteoma: Initial Results and Review of the Literature

Authors' Contribution:

- A** Study Design
- B** Data Collection
- C** Statistical Analysis
- D** Data Interpretation
- E** Manuscript Preparation
- F** Literature Search
- G** Funds Collection

Erdal Karagöz^{ABCDEF}, Deniz Özel^{ACDEF}, Fuat Özkan^{ACDEF}, Betül Duran Özel^{AE},
Özgür Özer^{AE}, Zafer Ünsal Coşkun^{AE}

Department of Radiology, Okmeydani Education and Research Hospital, Istanbul, Turkey

Author's address: Deniz Özel, Department of Radiology, Okmeydani Education and Research Hospital, Istanbul, Turkey,
e-mail: denizozel34@hotmail.com

Background:

The aim of this retrospective study is to determine our experience of technique success rate, complications and clinical results in long term follow up for computed tomography (CT)-guided radiofrequency ablation [RA] therapy for osteoid osteoma (OO).

Material/Methods:

We performed RA therapy to 18 patients with OO referred to interventional radiology from other clinics primarily from orthopedics; between January 2011 to May 2014. Daytime and nighttime pain intensity of 18 patients was noted according to visual analog scale (VAS). After procedure pain intensity was compared with before one. We also discussed other factors can affect it.

Results:

All procedures were completed technically successful for all patients [100%]. We did not experience any major complication or mortality. However we had 3 minor complications. Pain came back in 1 patient after 5 months from procedure and it was considered as recurrence. Dramatic pain intensity fall was seen in patients after procedure, both daytime and nighttime. However we did not find and statistically significant change in comparison of pain intensity reduce and time needed to return back to routine life when using patients demographic data and lesion size.

Conclusions:

CT guided RA therapy of OO is minimally invasive, effective and secure procedure.

MeSH Keywords:

Catheter Ablation • Osteoma, Osteoid • Tomography, Spiral Computed

PDF file:

<http://www.polradiol.com/abstract/index/idArt/896475>

Background

Osteoid osteoma (OO) is a small, painful, benign bone tumor specified as a nidus surrounded by sclerosed bone, maybe calcified [1]. It constitutes 10–12% of all benign tumors and 2–3% of all primary bone tumors [2]. 75% of cases are seen between ages 5–25. However, up to 70 years it can be seen in any bone completed its growth. It is detected more frequently in men. OO is often seen in the cortex of the long bones. More than 50% of the lesions localized in the femur and tibia [3]. The classical clinical finding is pain; increased intensity in nighttime and responds to salicylates [1]. This is a typical clinical history, seen in more than 75% of the cases [4].

The best modalities to localize the lesion is bone scintigraphy [5]. Classic scintigraphic 'double density' view is quite specific for OO is used as a guide for the CT scan [6]. CT, is very successful in showing periosteal reaction, sclerosis and bone around the nidus [1].

OO treatment options are, conservative medical therapy with nonsteroidal anti-inflammatory drugs (NSAIDs), minimally invasive percutaneous treatment and surgery [1]. NSAIDs usually is the first choice of treatment. Pain subsided after the use of oral NSAIDs for 2–3 years [7]. However, many patients cannot tolerate long term drug use due to gastrointestinal side effects, and recurrence of pain when the drug is discontinued [1]. Additionally, many patients,

are faced with serious complications such as, degenerative arthritis, scoliosis, growth disorders and muscle atrophy in this long process, depending on the location of the lesion [8].

Invasive methods for OO treatment in its application are; wide en bloc resection of open surgery, curettage, CT guided percutaneous, minimally invasive surgery, RA, laser ablation, cryoablation and alcohol ablation [3]. Whichever method is chosen, aim of treatment is completely removed or destroyed nidus [9]. To ensure complete excision it is essential to remove the block a large bone with tumor in conventional open surgery (en bloc resection). This process can lead to broken bones, reducing the durability. Therefore, additional procedures such as internal fixation, bone grafting and postoperative immobilization are required [10].

OO surgical treatment success rate is between 88% and 100% and recurrence rates are between 4.5% and 25% in the literature [3,11]. Surgical treatment, remains the standard method in doubt of the histological examination of the lesion, neurovascular structures located closer than 1–1.5 cm to the lesion and in case of twice failed percutaneous ablative method [3,11].

Difficulties for localizing the lesion in surgery, has led to the discovery of imaging guided minimally invasive new methods [3,9]. CT guided percutaneous methods was fundamental change in OO treatment [12]. Techniques used in percutaneous ablation are, alcohol injection, laser photocoagulation, cryoablation and RFA [3]. Alcohol ablation can be combined with percutaneous CT guided (drill) resection [3] and RF [13]. It is a simple and low cost method compared to other ones. However, controlling the alcohol spread to surrounding tissue is very difficult, which may lead to failure and complications of treatment [3,14].

Laser ablation therapy of OO can be applied in MR guidance. Unlike the RA it is fully compatible with MR. The success rate is close to the RA, but has a higher cost [15]. In literature, success rates are reported between 87% and 100%. Minor complication rate is higher than the RFA. In addition, a major disadvantage is that, it does not allow the histological diagnosis [3].

A new method is magnetic resonance imaging guided cryoablation. The most important advantages of the method are; changes that occur during the process can be monitored in real time, providing high soft tissue contrast and without ionizing radiation use. But the cost is high compared to other methods [3,16].

One of these techniques is CT guided RA method. Rosenthal et al., [12] has been described as a minimally invasive treatment option for the first time in 1992. In recent years, high success and similar recurrence rates has been reported with open surgical procedure in CT guided RA. But it has been shown to be superior to surgery with lower complication rates and shorter hospitalization time [11]. RA is safe, effective, minimally invasive and low cost method for OO treatment at present [1].

The aim of this retrospective study is to determine our experience of technique success rate, complications and clinical results in long term follow up for CT-guided radiofrequency ablation therapy for OO.

Material and Methods

Patients

Our study was included total of 18 patients as 6 female and 12 male aged between 10–27 years. Our patients were sent our clinic with OO preliminary diagnosis of various clinical, primarily orthopedics, between January 2011 – May 2014. All patients undergone radiofrequency ablation therapy. Three patients with age 3,7 and 8 years were excluded, because of the VAS values could not be trusted. Also 7 patients could not be included to study, they were not be able to followed up. Our study was accepted as ethical according to our Education and Research Hospital Clinical Research Ethics Committee Decision no. 255 dated 20.01.2015. The diagnosis of the patients, was based on pain, typically increased intensity at night and responding to NSAIDs; and radiologic findings. Informed consent was obtained from all individual participants included in the study.

Procedure

After diagnosis confirmed, all patients were informed about RA and other treatment methods. Before procedure protrombin time and (international normalized ratio) INR values were controlled. Patients were starved for 12 hours. Whole blood count, allergy and anesthesia status were controlled. VAS of daytime and nighttime were noted. Procedure was performed under general anesthesia in CT unit and aseptic conditions. Localization was confirmed with CT scan (Sensation 40, Siemens Medical Solutions, Forchheim, Germany) after placement of multiple radiopaque skin signers. KV and MAs values were chosen according to ALARA (as low as reasonably achievable) principle to minimize ionizing radiation exposure. After the entrance point signed with a pen, surrounding area was cleaned with iodine based antiseptic solution. Local anesthetic administered from entrance point to bone cortex. Skin cut was created. From this skin cut bone penetration canule (RITA StarBust Access System, 11G, AngioDynamics, Inc., USA) was advanced and cortex was penetrated with a hammer in case of necessary. After canule reached to nidus it was replaced with RFA electrode (UniBlate, AngioDynamics, Inc., USA) (Figure 1). Grounding pads and electrode were connected to generator (RITA 1500X, AngioDynamics, Inc., USA). Generator was set up to provide 77–90°C in 2–3 minutes. Procedure was performed around 90°C and 4–6 minutes. After procedure canule and electrode removed. IV parasetamol was administrated to control pain, as a result of released prostaglandins with nidus ablation. NSAIDs use was recommended for 3 days. All patients followed up in orthopedics clinic for one night. If there was no complication patients were externed. Heavy exercises forbidden to patients have lesion in weight bearing bones. All patients were called for follow up after one week, one month and six months after procedure. VAS values were obtained after procedure rather with follow up or telephone

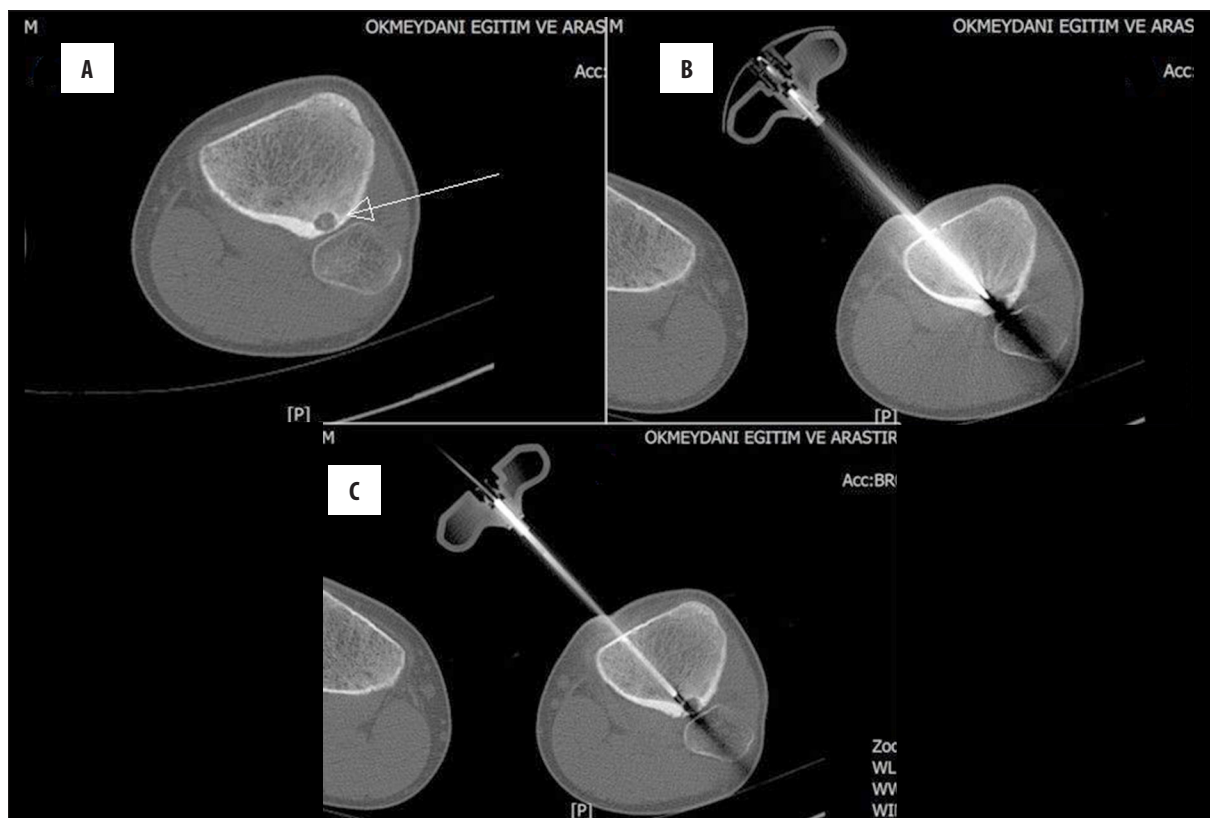


Figure 1. Ablation of an osteoid osteoma of the left proximal metaphyseal tibia. (A) CT scan demonstrates the nidus [arrow] of the osteoid osteoma. (B) During ablation procedure the tiny RF ablation probe being inserted into the nidus through a needle. (C) After the procedure.

Table 1. Data concerning the duration of pain and time required to return to normal activity.

	Mean	Standard deviation	Data range
Duration of pain before procedure (months)	8.72	2.99	5–17
Time to pain disappearance (days)	4.56	2.15	3–10
Time required to return to normal activity (days)	13.39	8.34	7–30

communication. Time to return back normal daily activity was also noted.

Statistical analysis

Change of VAS before and after procedure, and the factors can affect it (demographic data, nidus localization and size) was evaluated with statistical analysis. For analysis frequency, percent, mean value, standard deviation, median value, data range and interquartile range were used. For intergroup parametric comparison Mann Whitney U test, for in group comparison Wilcoxon sign test was used. Spearman correlation analysis was used to compare two quantitative values. Results were obtained in 95% security range (p<0.05).

Results

All procedures completed successfully (100%). The mean age of the study group was 17.4 years (range, 10–27 years). The mean size of the nidus was 8.06 mm (range, 5–13 mm).

The distribution of lesions according to their localization are, femur: 8, tibia: 7, ulna: 1, foot: 1 and sacrum: 1. The data about durance of pain and time needed to return back to normal activity summarized in Table 1. Major complication never happened as anesthetic or procedural mortality was not seen. In one patient superficial skin infection seen around entrance point and successfully treated with antibiotics. Left foot local contracture developed during procedure and it was treated with physical therapy in one patient. In one patient, penetration needle was broken. Needle was removed and procedure was completed by using a new needle.

We experienced one recurrence in a 25 year old male patient. After second procedure his treatment completed successfully.

All patients were using NSAIDs before but after one week from treatment none of them was going on. In comparison daytime VAS change before and after procedure, difference was statistically significant (Z=−3.785; p<0.05).

Table 2. VAS data.

	Before procedure			After procedure			Wilcoxon Z	p
	Median	IQR		Median	IQR			
Daytime	7	6	7	0	0	0.2	-3.785	<0.05
Nighttime	9	8	9	0	0	0	-3.769	<0.05
Wilcoxon Z	-3.787			-1.000				
p	<0.05			0.317				

Table 3. Age relation.

	Age	
	r	p
Pain duration before procedure	-0.134	0.597
Time needed for pain to disappear	0.185	0.462
Time required to return to regular life	-0.335	0.174

Table 4. Lesion size.

	Lesion size	
	r	p
Pain duration before procedure	0.129	0.610
Time needed for pain to disappear	0.396	0.104
Time needed to return to regular life	-0.195	0.438

Table 5. Gender.

	Female		Male		p
	Median	IQR	Median	IQR	
Pain duration before procedure	6	5-10.5	8	7-11	0.291
Time needed for pain to disappear	3	3-7	3	3-5	0.892
Time needed to return to regular life	10	7-15	7	7-15	0.682

In comparison nighttime VAS change before and after procedure, difference was statistically significant ($Z=-3.769$; $p<0.05$). In comparison VAS values before procedure between daytime and nighttime, difference was statistically significant ($Z=-3.787$; $p<0.05$). As last VAS values after procedure between daytime and nighttime, difference was not statistically significant ($Z=-1.0$; $p>0.05$) (Table 2).

There was not statistically significant relation between age and pain duration before procedure, time needed for pain disappear, time needed to return back to regular life (Table 3). There was not statistically significant relation between lesion size and pain duration before procedure, time needed for pain disappear, time needed to return back to regular life (Table 4). There was not statistically significant relation between gender and pain duration before procedure, time needed for pain disappear, time needed to return back to regular life (Table 5).

Discussion

OO RA treatment has close to 100% technical and 76-100% clinical success rate are reported for the first procedure in literature. After the first RA procedure in cases with recurrent or residual, it is stated that the clinical success rate for the second RA procedure is between 87% and 100% [3,9,17].

Rehnitz et al. reported clinical success of 99% after the first, 100% after the second RF process in their study of 72 patients [18]. In our study, technical success rate was 100% and clinical success rate was 94% as being consistent with the results reported in literature.

The average follow up period after the procedure is reported as 5 to 92 months in literature and average follow up period of our study was 26.5 months [19,20].

Duration of pain prior to treatment of OO, are highly variable in series in literature. Sung et al., reported this period from one month to 180 months, an average of 26 months [11]. In addition, there are studies report mean duration of pain between 12 months to 31 months in literature [2,21] is. In our study, pain duration ranged from 5 to 17 months with an average of 8.7 months.

There are publications examining the changes of VAS in RFA treatment of OO. De Palma et al. reported in their studt with 20 patients, mean VAS as 8.5 pre and 0.5 after treatment respectively for nighttime. Mean VAS was 5.95 pre and 0.9 after treatment as well for daytime. The severity of pain reduce was statistically significant [22].

Morassi et al. reported VAS decrease from 8.6 to 0 for their 11 patients after the procedure. Two of patients were considered as recurrence and after second procedure their VAS

reduced to 0 as well [23]. In our study VAS reduction for both day and nighttime was statistically significant.

Rehnitz et al. reported; there was no significant correlation between nidus size and VAS, duration of pain and time needed to return to daily activities in their study including 72 patients [20]. Cantwell et al. reported; there was no significant correlation between nidus size its localization and VAS, duration of pain and time needed to return to daily activities in their study [24]. Rosenthal et al. stated that the patient's age, gender, lesion size and its localization does not affect the clinical success [25]. In our study, we did not find a statistically significant relationship between patient age, sex, and lesion size and duration of pain before the procedure, and time needed to pain disappear and return to daily activities.

In Vanderschueren et al's study; lesion localization, calcified nidus, processing time, lesion size and treatments that previously applied has not been identified as risk factors that increase the rate of failure of the RA. However incorrect needle placement reduces the success rate such as deep seated lesions in the pelvis or close proximity to neurovascular structures [26].

Recurrence rate after RA procedure is between 5-10%, in some studies found as 12% [12,27]. Most of them occur within 3-6 months after the procedure. After six months, the frequency decreases gradually. After two years it is very rare to be seen [12]. Latest recurrence after RF treatment has been reported as after 44 months from the process [3]. The recurrence rate of our study was 6% and similar to literature.

Recurrence rates was higher when nidus size is 1 cm or more [28,29]. Cribb et al. reported diaphyseal lesions affecting local recurrence in their study. Age of patients, pain duration before procedure, lesion size, previously applied treatments, multiple different placement of the needle and the generator type used was not associated with local recurrence in this study [30].

In our study, we experienced a recurrence in a 25 years old patient after 5 months from treatment. The lesion was in the posterior proximal metaphyseal tibia. Nidus size was smaller than 1 cm.

Time required to completely disappear pain varies from 1 day to 2 weeks after treatment. Vanderschueren et al. reported; 47 of 54 patients [87%] on the first day, and remnant 7 [13%] pain completely disappeared in 2 weeks [31]. Woert et al. in 47 patients and Lindner et al. in 58

patients reported that the pain disappeared in one week [29,32]. In our study, average time needed was 4.5 days [between 3–10 days] for the pain completely disappeared after treatment.

Time to return to daily activities without exercise restraint in many studies are usually referred as just the next day after treatment [29–31]. Cantwell et al. reported an average of 7 days after the procedure in their study including 11 patients [25]. In our study, the time to return to daily activities was an average of 13 days longer than the time specified in the literature. Reason could be as; most of the lesions [83%] were located in weight bearing bone of the lower extremity and patients were mostly in the pediatric age group so their parents would want to protect their limb and act conservatively.

Rosenthal et al. compared the results of their study in the RFA and open surgery; 68 patients underwent open surgery, 33 patients have applied the RFA. Patients treated with RFA had been followed for an average of 3.4 years and found a recurrence rate of 12%. In this study there were no significant statistical differences in recurrence rates between the two methods [26]. Average stay time in hospital was 4.7 days in open surgical procedures, and 0.18 days in RFA. Similarly, shorter hospital length of stay was reported in many other studies [15,28,32]. In our study, the average length of stay in hospital was one day, was similar to the literature.

Advantages of the percutaneous RA compared with traditional surgical methods are, low cost, short hospital stay and early recovery of normal function after the procedure, can be easily repeated if the process fails and is suitable under spinal or local anesthesia when general anesthesia conditions are not available [12,31,33].

Limitations of our retrospective study can be counted as, the number of cases is relatively low, and the lack of consequent diversity of localization, histopathological confirmation was not to be done before the procedure. Nevertheless, the high technical and clinical success of RFA treatment of OO was shown successfully with low complication and recurrence rates.

Conclusions

For final words, CT guided RA treatment of OO, was defined as the first time since 1992, has proved its technical and clinical success and has begun to take place in the gold standard methods in more than 20 years.

References:

- Hoffmann RT, Jakobs TF, Kubisch CH et al: Radiofrequency ablation in the treatment of osteoid osteoma 5 year experience. *Eur J Radiol*, 2010; 73: 374–79
- Bourgault C, Vervoort T, Szymanski C et al: Percutaneous CT guided radiofrequency thermocoagulation in the treatment of osteoid osteoma: A 87 patient series. *Orthop Traumatol Surg Res*, 2014; 100: 323–27
- Cantwell CP, Obyrne J, Eustace S: Current trends in treatment of osteoid osteoma with an emphasis on radiofrequency ablation. *Eur Radiol*, 2004; 14: 607–17
- Greenspan A *Orthopedic Imaging: A Practical Approach*. 3rd Edition. Philadelphia: Lippincott Williams & Wilkins, 2000; 550–61
- Pratali R, Zuiani G, Inada M et al: Open resection of osteoid osteoma guided by a gamma-probe. *Int Orthop*, 2009; 33: 219–23
- Helms CA, Hattner RS, Vogler JB: Osteoid osteoma: radionuclide diagnosis. *Radiology*, 1984; 151: 779–84
- Ilyas I, Younge DA: Medical management of osteoid osteoma. *Can J Surg*, 2002; 45: 435–37
- Sung KS, Seo JG, Shim JS et al: Computed-tomography-guided percutaneous radiofrequency thermoablation for the treatment of osteoidosteoma: 2 to 5 years follow up. *Int Orthop*, 2009; 33: 215–18

9. Yang WT, Chen WM, Wang NH et al: Surgical treatment for osteoid osteoma experience in both conventional open excision and CT guided mini incision surgery. *J Chin Med Assoc*, 2007; 70: 545-50
10. Akhlaghpour S, Aziz Ahari A, Arjmand Shabestari A et al: Radiofrequency ablation of osteoid osteoma in atypical locations: a case series. *Clin Orthop Relat Res*, 2010; 468: 1963-70
11. Lee EH, Shafi M, Hui JH: Osteoid osteoma: A current review. *J Pediatr Orthop*, 2006; 26: 695-700
12. Rosenthal DI, Alexander A, Rosenberg AE et al: Ablation of osteoid osteomas with a percutaneously placed electrode: A new procedure. *Radiology*, 1992; 183: 29-33
13. Boscaino PJ, Cousins GR, Kulshreshtha R et al: Osteoid osteoma. *Orthopedics*, 2013; 36: 792-800
14. Akhlaghpour S, Tomasian A, Arjmand Shabestari A et al: Percutaneous osteoid osteoma treatment with combination of radiofrequency and alcohol ablation. *Clin Radiol*, 2007; 62: 268-73
15. Moser T, Buy X, Goyault G: Image guided ablation of bone tumors: Review of current techniques. *J Radiol*, 2008; 89: 461-71
16. Streitparth F, Gebauer B, Melcher I et al: MR guided laser ablation of osteoid osteoma in an open high-field system [1.0 T]. *Cardiovasc Intervent Radiol*, 2009; 32: 320-25
17. Skjeldal S, Lilleås F, Follerås G et al: Real time MRI guided excision and cryo treatment of osteoid osteoma in os ischii: A case report. *Acta Orthop Scand*, 2000; 71: 637-38
18. Rehnitz C, Sprengel SD, Lehner B et al: CT-guided radiofrequency ablation of osteoid osteoma: correlation of clinical outcome and imaging features. *Diagn Interv Radiol*, 2013; 19: 330-39
19. Çakar M, Esenyel CZ, Seyran M et al: Osteoid osteoma treated with radiofrequency ablation. *Adv Orthop*, 2015; 2015: 807274
20. Neumann D, Berka H, Dorn U et al: Follow up of thirty three computed tomography guided percutaneous radiofrequency thermoablations of osteoid osteoma. *Int Orthop*, 2012; 36: 811-15
21. Albisinni U, Bazzocchi A, Bettelli G et al: Treatment of osteoid osteoma of the elbow by radiofrequency thermal ablation. *J Shoulder Elbow Surg*, 2014; 23: e1-7
22. De Palma L, Candelari R, Antico E et al: Treatment of osteoid osteoma with CT guided percutaneous radiofrequency thermoablation. *Orthopedics*, 2013; 36: 581-87
23. Morassi LG, Kokkinis K, Evangelopoulos DS et al: Percutaneous radiofrequency ablation of spinal osteoid osteoma under CT guidance. *Br J Radiol*, 2014; 87: 20140003
24. Cantwell CP, O'Byrne J, Eustace S: Radiofrequency ablation of osteoid osteoma with cooled probes and impedance control energy delivery. *Am J Roentgenol*, 2006; 186: 244-48
25. Rosenthal DI, Hornicek FJ, Torriani M et al: Osteoid osteoma: Percutaneous treatment with radiofrequency energy. *Radiology*, 2003; 229: 171-75
26. Vanderschueren GM, Taminiau AH, Obermann WR et al: Osteoid osteoma: Factors for increased risk of unsuccessful thermal coagulation. *Radiology*, 2004; 233: 757-62
27. Sim FH, Dahlin CD, Beabout JW: Osteoid osteoma: diagnostic problems. *J Bone Joint Surg Am*, 1975; 57: 154-59
28. Kjar RA, Powell GJ, Schlicht SM et al: Percutaneous radiofrequency ablation for osteoid osteoma: Experience with a new treatment. *Med J Aust*, 2006; 184: 563-65
29. Woertler K, Vestring T, Boettner F et al: Osteoid osteoma: CT guided percutaneous radiofrequency ablation and follow up in 47 patients. *J Vasc Interv Radiol*, 2001; 12: 717-22
30. Cribb GL, Goude WH, Cool P et al: Percutaneous radiofrequency thermocoagulation of osteoid osteomas: factors affecting therapeutic outcome. *Skeletal Radiol*, 2005; 34: 702-6
31. Vanderschueren GM, Taminiau AH, Obermann WR et al: Osteoid osteoma: Clinical results with thermocoagulation. *Radiology*, 2002; 224: 82-86
32. Lindner NJ, Ozaki T, Roedel R et al: Percutaneous radiofrequency ablation in osteoid osteoma. *J Bone Joint Surg Br*, 2001; 83: 391-96
33. Lindner NJ, Scarborough M, Ciccarelli JM et al: CT controlled thermocoagulation of osteoid osteoma in comparison with traditional methods. *Z Orthop Ihre Grenzgeb*, 1997; 135: 522-27