

Propionibacterium acnes Infection of the Shoulder After a Manipulation Under Anesthesia for Stiffness Status Post Open Reduction and Internal Fixation Proximal Humerus: A Case Report

Jeremy Ruskin¹, Daniel Seigerman², Michael Sirkin¹, Mark Reilly¹, Mark Adams¹

Learning Point for this Article:

Latent infection may be present in the shoulder after ORIF and cause stiffness. Manipulation of the joint can cause an acute presentation of that infection.

Abstract

Introduction: Propionibacterium acnes infection has been more frequently recognized as an important cause of post-operative shoulder infection. Infection by this organism is more frequently seen after total shoulder arthroplasty but can also be seen after an open reduction and internal fixation (ORIF) of the proximal humerus. We present a patient with P. acnes infection of the shoulder that only became apparent after he underwent a manipulation under anesthesia for stiffness of the shoulder after an ORIF.

Case Report: Our patient was a 64-year-old male who sustained a proximal humerus fracture after a motorcycle collision and underwent an ORIF of the proximal humerus with plate fixation. Postoperatively, the patient had stiffness of the shoulder so he underwent a manipulation under anesthesia of the shoulder. On post-operative day 5, the patient developed an erythematous area over the incision. This area opened up and began to drain by post-operative day 10. The patient underwent an irrigation and debridement of the shoulder with partial removal of hardware. He was also started on antibiotics and clinically cleared his infection.

Conclusion: Infection by P. acnes can be difficult to diagnose and may present with shoulder stiffness as the only initial symptom. This case is unique as there have not been any documented cases of a latent P. acnes infection presenting after a manipulation under anesthesia of the shoulder. There must be a high clinical suspicion for P. acnes infection in any patient presenting with post-operative stiffness.

Keywords: Propionibacterium acnes, infection, trauma.

Introduction:

Post-operative infection after open reduction and internal fixation (ORIF) of a proximal humerus fracture is a serious complication, occurring in approximately 4% of patients.[1] Although most commonly seen as a cause of post-operative infections after total shoulder arthroplasty, P. acnes infection has been seen after ORIF as well. The diagnosis of P. acnes infection is difficult, as infection is often indolent and may present with a lack of clinical signs [1,2]. We present the case of a 64-year-old male who underwent an ORIF of his left proximal humerus and developed a P. acnes infection. The infection only

became apparent when he developed a draining wound after undergoing a manipulation under anesthesia for shoulder stiffness 4 months postoperatively.

Case report :

Our patient is a 64-year-old left-hand dominant male who was involved in a motorcycle collision and sustained a right valgus impacted four-part proximal humerus fracture (Fig. 1). He also sustained a left small finger distal phalanx fracture. The patient's medical history was significant for coronary artery disease. His

Access this article online

Website:
www.jocr.co.in

DOI:
2250-0685.1030

Author's Photo Gallery




Dr. Jeremy Ruskin



Dr. Daniel Seigerman



Dr. Michael Sirkin



Dr. Mark Reilly



Dr. Mark Adams

¹Department of Orthopaedics, Rutgers – New Jersey Medical School, Newark, New Jersey,
²Institute for Hand and Arm Surgery, Millburn, New Jersey.

Address of Correspondence:

Dr. Jeremy Ruskin,
Department of Orthopaedics, Rutgers – New Jersey Medical School, 90 Bergen St. Suite 7300, Newark, NJ 07103, New Jersey.
E-mail: jbruskin1@gmail.com



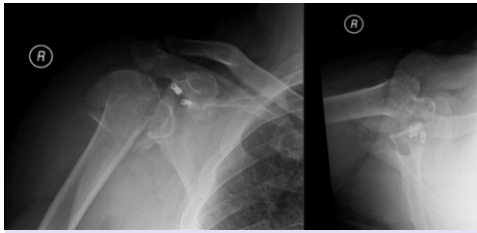


Figure 1: Pre-operative radiographs show the patient's proximal humerus fracture.

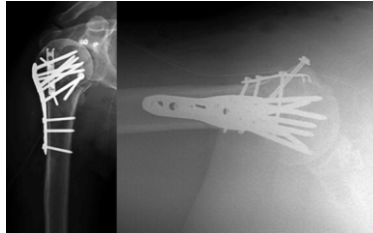


Figure 2: Immediate post-operative radiographs showing fixation of the proximal humerus fracture.

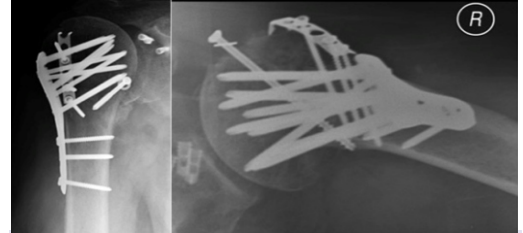


Figure 3: 4-month post-operative showing backing out of the lag screw in the lesser tuberosity.

past surgical history included a right shoulder arthroscopic superior labral repair and biceps tenodesis multiple years prior, and his social history included a history of cigarette smoking and social alcohol use. He denied having any pain or decreased range of motion in the right shoulder before the injury. The patient underwent open reduction internal fixation of the closed right proximal humerus 2 days after his initial presentation without complication. The fixation consisted of a lateral locking plate, separate plate, and screw fixation of the lesser tuberosity, and sutures into the supraspinatus, infraspinatus, and subscapularis that were anchored to the locking plate (Fig. 2). Pre-operative antibiotics included both 2 g of cefazolin and 600 mg of clindamycin per protocol for open shoulder surgery in the senior author's practice, and this was readjusted throughout the procedure and continued for 24 h postoperatively. The patient was continued on the same antibiotics for the 24 h after surgery. He had a drain placed after surgery, and this was discontinued on post-operative day 2. He was discharged on post-operative day 3, after adequate pain control had been achieved on oral pain medications. His post-operative therapy regimen included a five-pound weight-bearing restriction for the first 6 weeks. He was encouraged to use his hand for activities of daily living. The patient was sent to physical therapy to work on active and active assisted range of motion, beginning with pendulums and progressing to full

activity. At 4 months postoperatively, the patient was reporting continued pain and decreased range of motion in the right shoulder. His wound was well healed with no erythema or signs of infection. His motion measured 30° of external rotation with the arm at the side, 50° of internal rotation with the shoulder abducted to 90°, abduction to 60°, and forward flexion to 95°. His radiographs noted healing, with no change in the alignment of the proximal humerus from initial post-operative radiographs. The lateral locking plate appeared well maintained, but the partially threaded screw in the lesser tuberosity had backed out several millimeters (Fig. 3). As the patient had significant stiffness affecting the function of the extremity, a manipulation under anesthesia was performed 4 months after the index procedure. The manipulation was performed while holding counter-pressure over the lateral border of the scapula. Audible and palpable release of scar tissue was felt and heard. Post-manipulation range of motion included 70° of external rotation both at 0° and 90° of abduction, internal rotation of 45°, forward flexion of 160°, and abduction of 160° (Fig. 4). Imaging was performed after the procedure to ensure that there was no propagation of old fracture lines or any new fractures. The patient was given post-operative regional anesthesia for 24 h and was seen by the occupational and physical therapists for range of motion exercises during this time period.

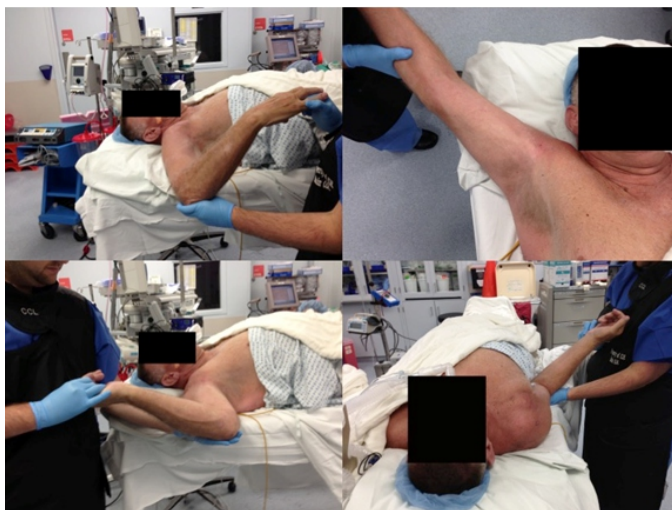

Figure 4: Photographs from the manipulation under anesthesia of the left shoulder, after manipulation has been performed. Clockwise from the top left, maximal internal rotation at 90° of abduction, abduction, external rotation at 90° of abduction, and external rotation with the arm at the side.

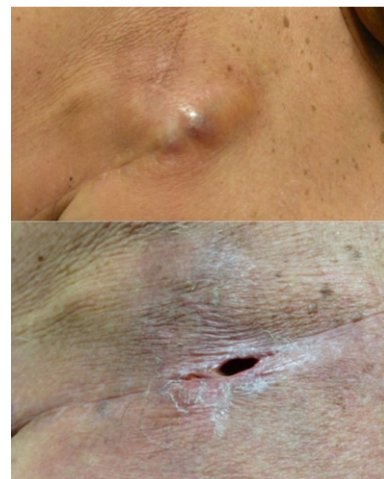

Figure 5: The patient developed an area of erythema and fluctuance on post-operative day 5 (top), which later converted into an open wound on post-operative day 10 (bottom).

The patient was seen in the office on post-manipulation day 5, and a raised, erythematous and fluctuant 2-centimeter area was noted in the central portion of his prior incision. He denied any systemic symptoms such as fevers or night sweats. The assessment was that this was either a hematoma or deep infection. On post-manipulation day 10, this area converted into a draining wound (Fig. 5).

His white blood cell count was 10.4/mm³, erythrocyte sedimentation rate (ESR) 26 mm/h, and C-reactive protein (CRP) 17 mg/L. The patient was taken to the operating room the following day, for irrigation and debridement, and partial removal of hardware. The prior deltopectoral incision was opened in line with the draining wound, the cavity was explored, and purulent fluid was noted. Multiple culture swabs were sent for microbiological analysis, and empiric vancomycin and piperacillin/tazobactam were started. In terms of the anterior hardware, the screws in the quarter tubular plate overlying the lesser tuberosity were noted to be loose and were removed, as were the independent partially threaded screw. The lateral locking plate and screws were covered in soft tissue that was adherent to the plate, and it was therefore not visible through the wound. The lateral plate was maintained in place as it appeared well-fixed on radiographs, and it may have still been supporting the fracture. An irrigation and debridement were performed. The infectious disease service was consulted, and on the 8th post-operative day, 4/4 cultures were positive for *P. acnes*. The cultures were beta-lactamase negative. The patient was placed on oral cephalexin for 6 weeks' time. His wound healed, and 6 months later, the patient had the remainder of his hardware removed by another surgeon. His range of motion at this time was forward flexion of 150° with some assistance of the left arm, abduction of 90°, internal rotation to the lumbar spine, and external rotation of 40°.

Discussion:

This case highlights the importance of considering infection as a possible cause of shoulder stiffness after an ORIF of the proximal humerus. Over the past few years, there has been increased knowledge about *P. acnes* as a causal agent of post-operative shoulder infections due to the fact that it tends to colonize the skin overlying the shoulder [3]. *P. acnes* infection has been known to cause post-operative stiffness in patients who have undergone total shoulder arthroplasty [2,4]. However, post-operative stiffness has been more seldom mentioned after ORIF of the proximal humerus, likely because *P. acnes* is not the most common infective agent of acute deep infections after ORIF of the proximal humerus [1,5]. In a large study of 452 proximal humerus fractures, 18 patients had acute deep infections, and only 1 of the patients had cultures positive for *P. acnes* [1]. It is unique that our patient presented with his infection, only after undergoing a manipulation of his shoulder. To the best of our knowledge, this is the 1st time that an acute exacerbation of a *P. acnes* infection has resulted from a chronic infection after shoulder manipulation for stiffness.

In retrospect, after examining the radiographs from this patient, it appears that he did have evidence of a deep infection before

manipulation of his shoulder. The patient did not present with any of the typical signs and symptoms of infection such as wound drainage, swelling, fevers, or malaise. This is consistent with *P. acnes* infections of the shoulder, as the most common symptom is pain [4,6]. In one case series, 10 patients were diagnosed with *P. acnes* infection of the shoulder and 9 out of 10 of these patients presented with pain as their predominant symptom. Three of the patients presented with stiffness of the shoulder. CRP was elevated in two patients and ESR elevated in eight patients. Only one patient out of 10 in that series underwent ORIF of the proximal humerus [4]. Likewise, in a study of patients undergoing revision shoulder arthroscopy for pain and stiffness, 16 out of 68 patients had cultures positive for *P. acnes*. One patient had elevated inflammatory markers, and no patients had constitutional symptoms or local wound complications [5]. These series highlight the inconsistent clinical picture in patients with *P. acnes* infections of the shoulder, as well as the difficulty in diagnosing such infections due to the non-specific symptoms that they present with, and the infrequent laboratory elevation of inflammatory markers [7].

Conclusion:

Our case is unique in that our patient's infection with *P. acnes* only became apparent after he underwent a manipulation under anesthesia for shoulder stiffness. He, then, required a surgical irrigation and debridement and removal of hardware to treat the infection [8]. We believe that the patient had an indolent infection contained by scar tissue in the shoulder joint and the anterior hardware. On manipulation and breakage of the scar tissue, the infection was able to spread through the deep tissues and clinically manifest as wound drainage. Only the hardware in the anterior portion of the proximal humerus was loose during reoperation, and it is likely that this area and the surrounding scar tissue harbored the infection in the first place. The remainder of the hardware was kept in place because it did not appear to communicate with the infected area in the shoulder and it was not visualized at the time of surgery. Removal of the proximal humeral plate would also likely have decreased the stability of the proximal humerus and made it more likely to refracture before the bone healed [9]. This case also highlights the importance of considering infection as a cause of post-operative stiffness after ORIF of the proximal humerus. There needs to be a high index of suspicion for *P. acnes* infection because it most often presents with pain as the only symptom. We would recommend infection be considered in any patient presenting with pain or stiffness after an ORIF of the proximal humerus, and an aspiration of the shoulder joint should be obtained in those patients in whom there is a concern for

infection as a cause of their symptoms.

Clinical Message

Infection with *Propionibacterium acnes* should be considered in any patient with shoulder stiffness after undergoing open reduction internal fixation of a proximal humerus fracture.

References

1. Blonna D, Barbasetti N, Banche G, Cuffini AM, Bellato E, Massè A, et al. Incidence and risk factors for acute infection after proximal humeral fractures: A multicenter study. *J Shoulder Elbow Surg* 2014;23:528-35.
2. Dodson CC, Craig EV, Cordasco FA, Dines DM, Dines JS, Dicarlo E, et al. *Propionibacterium acnes* infection after shoulder arthroplasty: A diagnostic challenge. *J Shoulder Elbow Surg* 2010;19:303-7.
3. Patel A, Calfee RP, Plante M, Fischer SA, Green A. *Propionibacterium acnes* colonization of the human shoulder. *J Shoulder Elbow Surg* 2009;18:897-902.
4. Millett PJ, Yen YM, Price CS, Horan MP, van der Meijden OA, Elser F, et al. *Propionibacterium acnes* infection as an occult cause of postoperative shoulder pain: A case series. *Clin Orthop Relat Res* 2011;469:2824-30.
5. Athwal GS, Sperling JW, Rispoli DM, Cofield RH. Acute deep infection after surgical fixation of proximal humeral fractures. *J Shoulder Elbow Surg* 2007;16:408-12.
6. Horneff JG 3rd, Hsu JE, Voleti PB, O'Donnell J, Huffman GR. *Propionibacterium acnes* infection in shoulder arthroscopy patients with postoperative pain. *J Shoulder Elbow Surg* 2015;24:838-43.
7. Saper D, Capiro N, Ma R, Li X. Management of *propionibacterium acnes* infection after shoulder surgery. *Curr Rev Musculoskelet Med* 2015;8:67-74.
8. Saltzman MD, Marecek GS, Edwards SL, Kalainov DM. Infection after shoulder surgery. *J Am Acad Orthop Surg* 2011;19:208-18.
9. Berkes M, Obrebsky WT, Scannell B, Ellington JK, Hymes RA, Bosse M, et al. Maintenance of hardware after early postoperative infection following fracture internal fixation. *J Bone Joint Surg Am* 2010;92:823-8.

Conflict of Interest: Nil

Source of Support: Nil

Consent: The authors confirm that Informed consent of the patient is taken for publication of this case report

How to Cite this Article

Ruskin J, Seigerman D, Sirkin M, Reilly M, Adams M. *Propionibacterium acnes* Infection of the Shoulder After a Manipulation Under Anesthesia for Stiffness Status Post Open Reduction and Internal Fixation Proximal Humerus: A Case Report. *Journal of Orthopaedic Case Reports* 2018. Mar-April; 8(2): 19-22