



Biomaterial scaffolds for clinical procedures in endodontic regeneration

He Liu^{a,b}, Jing Lu^c, Qianzhou Jiang^d, Markus Haapasalo^b, Junrong Qian^{a,*},
Franklin R. Tay^{e,**}, Ya Shen^{b,***}

^a Department of Stomatology, Affiliated Hospital of Jining Medical University, China

^b Division of Endodontics, Department of Oral Biological and Medical Sciences, Faculty of Dentistry, University of British Columbia, Canada

^c Key Laboratory of Oral Disease, School and Hospital of Stomatology, Fujian Medical University, Fuzhou, China

^d Department of Endodontics, Stomatology Hospital of Guangzhou Medical University, Guangzhou, China

^e Department of Endodontics, The Dental College of Georgia, Augusta University, Augusta, GA, USA

ARTICLE INFO

Keywords:

Biomaterials
Clinical approach
Regenerative endodontics
Scaffolds

ABSTRACT

Regenerative endodontic procedures have been rapidly evolving over the past two decades and are employed extensively in clinical endodontics. These procedures have been perceived as valuable adjuvants to conventional strategies in the treatment of necrotic immature permanent teeth that were deemed to have poor prognosis. As a component biological triad of tissue engineering (i.e., stem cells, growth factors and scaffolds), biomaterial scaffolds have demonstrated clinical potential as an armamentarium in regenerative endodontic procedures and achieved remarkable advancements. The aim of the present review is to provide a broad overview of biomaterials employed for scaffolding in regenerative endodontics. The favorable properties and limitations of biomaterials organized in naturally derived, host-derived and synthetic material categories were discussed. Preclinical and clinical studies published over the past five years on the performance of biomaterial scaffolds, as well as current challenges and future perspectives for the application of biomaterials for scaffolding and clinical evaluation of biomaterial scaffolds in regenerative endodontic procedures were addressed in depth.

1. Introduction

Oral diseases are one of the most prevalent diseases encountered by humans and have posed significant health and economic risks [1]. Dental caries (tooth decay) is the most pervasive disease/injury worldwide, with 2.3 billion people suffering from caries of the permanent dentition [1,2]. Traumatic dental injuries are the second most frequently encountered oral disease after dental caries and the 5th most prevalent disease/injury in the world [3]. These injuries often occur during the earlier stages of life and have a prevalence of 15.2% in permanent dentition [3]. Caries and traumatic dental injuries, if left untreated or improperly managed, can lead to the death of the dental pulp (i.e., necrosis) as well as inflammation and destruction of the tissues around the tooth (i.e., apical periodontitis) in immature permanent teeth [4,5].

Loss of pulp vitality during an early stage of root development prevents subsequent root maturation and closure of the root-end. This

renders immature permanent teeth with thin and fragile dentinal walls [6,7]. Traditionally, immature permanent teeth with pulpal necrosis and apical periodontitis are treated by apexification, using long-term calcium hydroxide dressing, to stimulate continued root development and natural apical closure. More recently, teeth with these symptoms are managed by artificial apical closure via immediate placement of an apical plug that consists of hydraulic tricalcium silicate cements [8,9]. Nevertheless, these treatment modalities provide no benefit in restoring normal pulpal function and responses to injury [10]. Moreover, continued root elongation and dentinal wall thickening are unpredictable because of inflammation, infection or traumatic injury to the Hertwig's epithelial root sheath, which plays a pivotal role in root maturation and morphogenesis [11,12]. Immature teeth that have been treated with the aforementioned strategies remain susceptible to catastrophic cervical fracture and have low survival rates [13,14]. Young patients undergoing craniofacial development are not candidates for

Peer review under responsibility of KeAi Communications Co., Ltd.

* Department of Stomatology, Affiliated Hospital of Jining Medical University, Jining, Shandong, 272000, China.

** Corresponding author. Augusta University, Augusta, GA, USA.

*** Corresponding author. UBC Faculty of Dentistry, 2199, Wesbrook Mall, Vancouver, BC, V6T 1Z3, Canada.

E-mail addresses: qianjunrong@mail.jnmc.edu.cn (J. Qian), ftay@augusta.edu (F.R. Tay), yashen@dentistry.ubc.ca (Y. Shen).

<https://doi.org/10.1016/j.bioactmat.2021.10.008>

Received 20 July 2021; Received in revised form 4 October 2021; Accepted 4 October 2021

Available online 14 October 2021

2452-199X/© 2021 The Authors. Publishing services by Elsevier B.V. on behalf of KeAi Communications Co. Ltd. This is an open access article under the CC

BY-NC-ND license (<http://creativecommons.org/licenses/by-nc-nd/4.0/>).

implants and hence may have severe functional and psychosocial impairment because of the loss of teeth [15].

Regenerative endodontic procedures (REPs) are biologically based procedures that deploy the principles of tissue engineering and regenerative medicine in using a triad of endogenously or exogenously derived stems cells, scaffolds and growth factors to regenerate damaged tissues/organs. These procedures offer alternative approaches to apexification treatments in treating necrotic immature permanent teeth with apical periodontitis [10,16–20]. The objectives of REPs include primary (resolution of clinical signs/symptoms and periapical bone destruction, restoration of normal tooth function), secondary (stimulation of root maturation) and tertiary goals (regeneration of true pulp-dentin complex and the complete restoration of pulpal function) [10,16–20]. Since the first report of successful clinical outcome, REPs have primarily been used for the treatment of immature permanent teeth with the necrotic dental pulp and apical periodontitis (Fig. 1) [21–29]. More recently, the role of REPs has been expanded to the management of mature permanent teeth with necrotic pulp and apical periodontitis (Fig. 2) [30–32], as well as traumatized permanent teeth with root fracture, external root resorption or perforation (Figs. 3–5) [33–37].

The clinical approaches of REPs may be classified into cell-free and

cell-based procedures, according to whether exogenous delivery of cells is involved (Fig. 6) [20]. Cell-free procedures do not introduce exogenously prepared cells into the host for regeneration of the pulp and dentin. Instead, host-derived bioactive materials such as blood clots that can be obtained readily from the host and prepared easily in the clinic are used as scaffolds and sources of endogenous cells and growth factors. Some of the growth factors may also stimulate homing of endogenous stem cells from stem cell niches to the site of injury (i.e., the pulpal space). Although cell-free regenerative endodontic therapy has achieved high success rates in randomized clinical trials including resolution of clinical signs/symptoms and periapical bone destruction, restoration of normal tooth function, it does not regenerate the pulp-dentin complex. In contrast, cell-based procedures apply contemporary tissue engineering methods as clinical procedures with attempts to regenerate pulp and dentin (e.g., seeding exogenously prepared dental pulp stem cells onto bioactive synthetic scaffolds). To date, these procedures are mostly experimentally performed in animal models, and only a couple of procedures have been evaluated in humans in the preliminary stages of clinical trials. Nevertheless, some of those human studies have reported promising results, including favorable clinical and radiographic outcomes as well as potential regeneration of the pulp-dentin complex

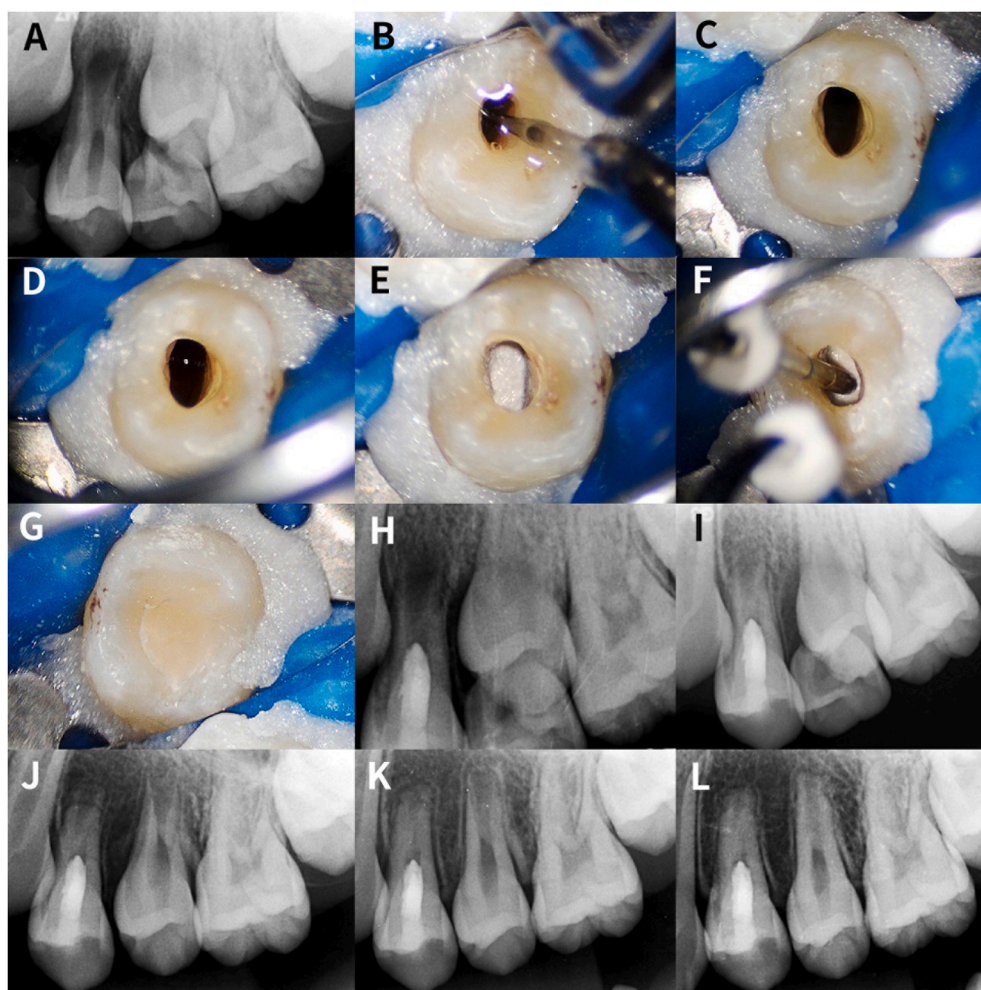


Fig. 1. Regenerative endodontic procedures (RPEs) performed in tooth 12 of a 10-year-old boy who sought endodontic care because of intraoral buccal swelling. Tooth 12 was diagnosed as pulpal necrosis with symptomatic apical periodontitis. The tooth was treated with REPs using the dental operating microscope according to the American Association of Endodontists' recommendations on clinical considerations for regenerative procedures. (A) Preoperative periapical radiograph showed that tooth 12 had a periapical lesion, immature root and thin dentinal walls. (B) After rubber dam isolation and access, the root canal was copiously irrigated with 1.5% sodium hypochlorite and 17% ethylenediamine tetraacetic acid (EDTA). The root canal was dried with paper points and temporized with calcium hydroxide paste for two weeks. At the second visit, the tooth was irrigated copiously with 17% EDTA to remove the calcium hydroxide dressing and release growth factors from the radicular dentin. (C) The root canal was dried with paper points. (D) Apical bleeding was induced into the canal space up to the cemento-enamel junction by rotating a K-file beyond the apex to irritate the periapical tissues physically. (E) After a blood clot was formed, a piece of CollaCote collagen sponge (Integra Life Sciences, Shanghai, China) placed over the blood clot as a matrix. (F) A 3-mm thick layer of iRoot BP Plus Root Repair Material (Innovative BioCeramix Inc, Vancouver, BC, Canada) was placed against the matrix. (G) The tooth was restored with resin composite. (H) Post-operative radiograph of tooth 12. (I) Three-month follow-up periapical radiograph of tooth 12 indicating periapical healing. (J) Six-month follow-up radiograph of tooth 12 showing the formation of hard tissue in the middle of the canal. (K) Twelve-month follow-up radiograph of tooth 12 showing continued formation of hard tissue along the apical part of the root canal wall. (L) Twenty-month follow-up radiograph of tooth 12 showing root canal space narrowing. The tooth showed a positive response to cold and electric pulp tests.

along the apical part of the root canal wall. (L) Twenty-month follow-up radiograph of tooth 12 showing root canal space narrowing. The tooth showed a positive response to cold and electric pulp tests.

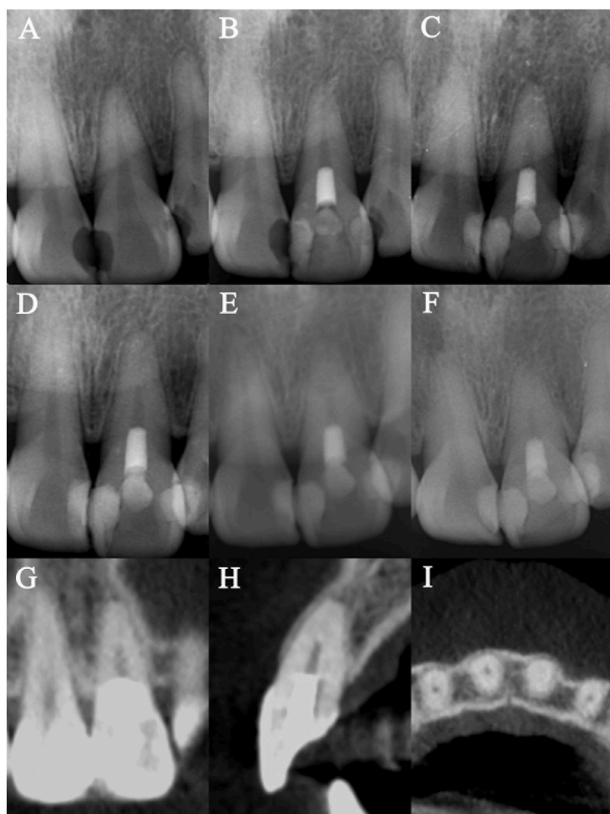


Fig. 2. Regenerative endodontic procedures performed on tooth 9 of a 26-year-old female patient diagnosed with necrotic pulp and symptomatic apical periodontitis. (A) Preoperative periapical radiograph of tooth 9. (B) Postoperative radiograph of tooth 9. In the second treatment visit, apical bleeding was induced into the canal space up to the cementoenamel junction by rotating a K-file beyond the apex to irritate the periapical tissues physically. After a blood clot was formed, CollaCote was placed over the blood clot in the canal. A 3-mm thickness of iRoot BP Plus Root Repair Material was then placed against the CollaCote. The tooth was restored with glass ionomer cement and composite resin. (C) 4-month follow-up radiograph showed the apical canal was filled with hard tissue. (D) 12-month follow-up radiograph. (E–F) 28-month and 48-month follow-up radiographs revealed more hard tissue deposition in the apical portion of the canal space. (G–I) 60-month follow-up cone-beam computed tomographic images of tooth 9 showed the apical canal was filled with hard tissue. Cold and electric pulp tests showed positive responses for tooth 9.

[38–40].

A scaffold is a bioactive framework or structural base that supports cell adhesion, regulates their proliferation and differentiation and facilitates tissue formation [41]. An ideal scaffold in REPs should closely resemble the extracellular matrix of the pulp-dentin complex in terms of biological and mechanical properties [42–44]. It should establish a three-dimensional micro-environment that allows stem/progenitor cells to bind, migrate, proliferate and organize themselves spatially, to differentiate into odontogenic, vasculogenic and neurogenic lineages, as well as facilitates angiogenesis and neurogenesis [42–44]. It should also require adequate pore size to facilitate cell diffusion as well as effective transport of nutrients, oxygen, and waste [42–44]. Another essential feature of an ideal scaffold is the rate of degradation should match the tissue growth in a spatial-temporally appropriate manner [42–44]. However, fabricating an ideal scaffold which can meet all the desired properties including biocompatibility, biodegradability, viscoelasticity, mechanical strength, structure stability, antimicrobial activity, clinical simplicity, cost-effective, odontoinductivity and odontoconductivity to achieve the complete pulp-dentine regeneration is still a challenge [42–44]. A variety of types of biomaterials have been used to fabricate scaffolds in regenerative endodontics. These biomaterial scaffolds may

be classified as host-derived, natural or synthetic according to the sources and properties of biomaterials [42–46] (Table 1). Over the last decade, a plethora of preclinical and clinical studies have been conducted to evaluate and compare the performance of various biomaterial scaffolds in REPs. The efficacy regarding the application of biomaterial scaffolds in preclinical studies is assessed by the outcomes of radiographic evaluation (i.e., dynamic changes of periapical status and hard tissue formation of the root) and by the phenotypes of tissue (e.g., histological characteristics of the hard and soft tissue) regenerated in the root through histological and molecular analysis [47,48]. The outcomes of clinical studies are primarily measured through clinical and radiographic examinations by the degree to which primary (i.e., healing of apical periodontitis), secondary (i.e., continued development of root) and tertiary goals (i.e., regaining positive response to pulp testing) of REPs may be met [47,49]. Because of the immense potential and rapidly evolving advancements on biomaterial scaffolds in REPs, the present review aimed to provide a timely overview of the biomaterials that have been applied for scaffolding in regenerative endodontics. This involved summarizing the findings of preclinical and clinical studies on the performance of biomaterial scaffolds and discussing the associated challenges and future research and clinical perspectives.

2. Host-derived biomaterial scaffolds

2.1. Blood clot

A blood clot is a gel-like clump when blood changes from a liquid state to a solid-state in response to an injury or scission [20,50]. Blood clot formation represents a critical event in wound healing and tissue regeneration. Both the European Society of Endodontology and the American Association of Endodontists recommend blood clot as the scaffold of choice for REPs [49,51]. Induction of apical bleeding into the canal space creates a cross-linked fibrin meshwork that serves as a scaffold for stem cell homing. The cross-linked fibrin meshwork contains essential growth factors for recruiting and supporting endogenous stem cell migration, proliferation and differentiation. In addition, mechanical irritation of the periapical tissues also stimulates the influx of different types of mesenchymal stem cells (MSCs) into the canal space, especially in immature permanent teeth containing apical papilla. These stem cells can restore the physiological structure and function of the pulp-dentin complex [16–20]. The use of blood clots as scaffolds are expected to achieve promising biological outcomes in REPs. Fig. 7 presents a case where a blood clot was used as a scaffold in REPs to treat immature tooth 29 with symptomatic apical periodontitis. At 3-month follow-up, tooth 29 was asymptomatic and a complete resolution of the periapical lesion was noted in the periapical radiograph. At 36-month follow-up, periapical radiograph showed that tooth 29 had a similar root morphology as tooth 28, which underwent normal development. Cold and electric pulp tests revealed positive results for tooth 29. This case showed the use of blood clot as a scaffold could attain the primary, secondary and tertiary goals of REPs. Blood clots represent the most clinically prevalent scaffolds in REPs because of their simplicity in harvesting, without the need for using additional equipment or complicated laboratory manipulation. Their low cost is also beneficial to both patients and clinicians [52]. Although blood clots have been used as scaffolds in REPs for only two decades, they have been introduced into endodontics as early as in the 1960s. Nygaard-Østby first described the role of the blood clot in promoting the healing of apical periodontitis and pulp tissue repair [53]. In this seminal work, the author provoked bleeding in the apical third of the canal space of necrotic teeth with apical periodontitis. These teeth were debrided, apically enlarged prior to the placement of interim dressings. After different observation periods that ranged from thirteen days to 3.5 years, the teeth were extracted for histological analysis. The author observed the resolution of apical periodontitis, ingrowth of connective tissue and blood vessels into the canal, as well as the deposition of cementum on the canal walls. These findings established the

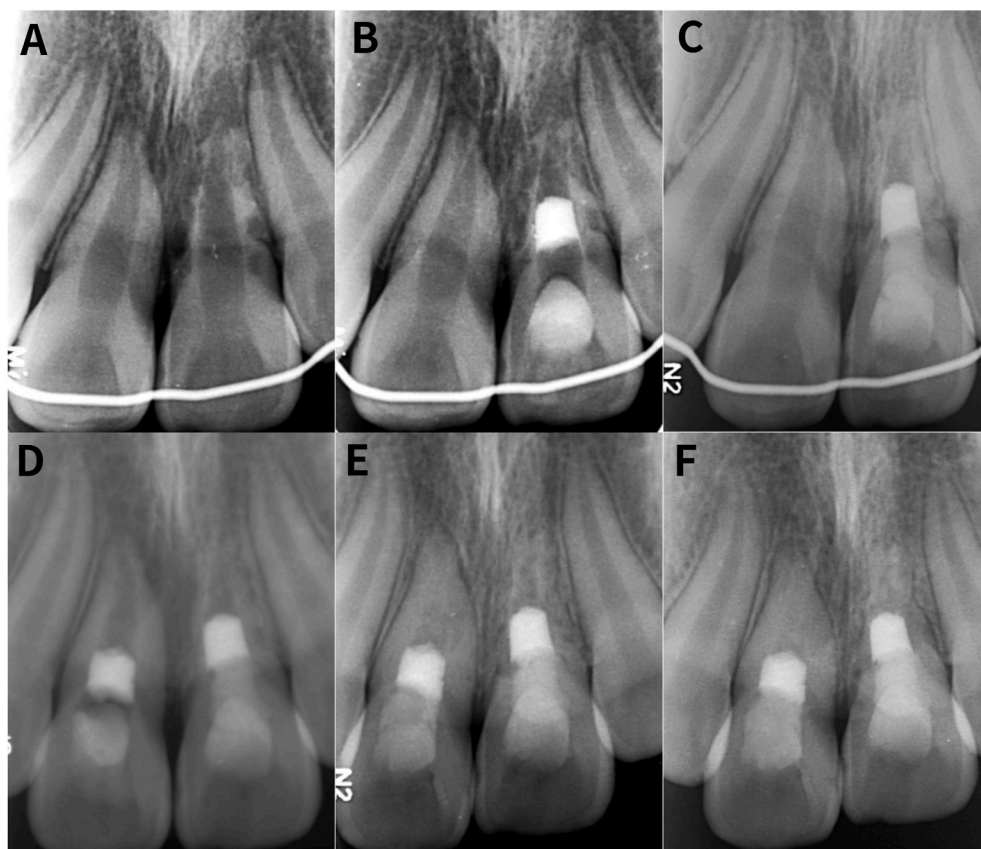


Fig. 3. Regenerative endodontic procedures performed on a 9-year-old girl who was referred for evaluation and treatment of traumatized anterior teeth. The patient had traumatic dental injury four months ago. Tooth 9 was replanted after avulsion for 5 h (dry storage). Tooth 8 was extruded and repositioned at a local hospital. Teeth 6–10 were splinted after clinical examination. (A) Preoperative periapical radiograph showed that tooth 9 had a periapical lesion and severe external root resorption. (B) Post-operative radiograph. In the second treatment visit, apical bleeding was induced into the canal space up to the cemento-enamel junction by rotating a K-file beyond the apex to irritate the periapical tissues physically. After a blood clot was formed, CollaCote was placed over the blood clot in the canal. A 3-mm thickness of ProRoot Mineral Trioxide Aggregate (Dentsply; Tulsa Dental, Tulsa, Oklahoma, USA) was then placed against the CollaCote. The tooth was restored with glass ionomer cement and composite resin. (C) 6-month follow-up radiograph showed resolution of the periapical lesion and arrest of external root resorption of tooth 9. (D) 12-month follow-up radiograph indicated that the mesial root perforation in tooth 9 appeared to be repaired with hard tissue. Apical radiolucency was present in tooth 8 and REPs were performed. (E) 24-month follow-up radiograph of tooth 9 and 12-month follow-up radiograph of tooth 8 showed the formation of hard tissue in the canal spaces of both teeth and the resolution of the periapical lesion originally detected in tooth 8. (F) 30-month follow-up radiograph of tooth 9

the 18-month follow-up radiograph of tooth 8 showed that the canals of both teeth were filled with hard tissue. The root of tooth 9 was surrounded by an intact lamina dura. Reprinted with permission [37]. Copyright 2021, Elsevier.

healing and revascularization potentials of the intracanal blood clot, which were supported by subsequent studies in dental traumatology [54–60].

Although these pioneering studies set the stage for REPs, it was only until the early 2000s when two remarkable case reports attracted people's attention on the value of blood clots in pulp revascularization [21, 61]. Subsequently, numerous case reports, case series and clinical studies about using blood clots as scaffolds were published. These archives achieved promising results and high success rates for permanent necrotic teeth, with the resolution of apical periodontitis, continued root development, apical narrowing and even restoration of vitality [24–37]. Recently published systematic review and meta-analysis studies also provided a high level of evidence [62–64]. Although REPs using blood clots as scaffolds have achieved satisfactory clinical outcomes, favorable histological outcomes are still far less predictable. Indeed, the majority of histological studies showed that the tissue formed in the canal was fibrous connective tissue and cementum-like or bone-like tissue instead of the pulp-dentin complex [20,65–68]. In a systematic review that screened 123 studies and finally incorporating 13 animal studies, hard tissue formation was observed in 80% of the studies which used blood clots as scaffolds in root canals. The hard tissues reported included dentin-like tissue (4%), cementum-like tissue (64%) and bone-like tissue (10%). In the majority of cases, the vital intracanal tissue was connective tissue with blood vessels that resembled periodontal ligament. Only some cases showed the formation of pulp-like tissue with or without odontoblast-like cells [48]. The suboptimal histological outcome may be attributed to many factors, including the incorporation of unregulated

cell types and the lack of desired cell types, as well as the adverse effects of antibacterial agents and residual bacteria on the micro-environment and stem cells [68–70].

Irrigation is a critical step in REPs for disinfection and release of chemotactic molecules from the dentin matrix (Fig. 8) [19]. The American Association of Endodontists recommends the use of 17% EDTA as final irrigation prior to evoking apical bleeding to release growth factors from dentin and promote the biological activities of stem cells [8]. However, as an anticoagulant, residual EDTA in the canal may affect the formation of a blood clot [71–73]. A recent study evaluated the effects of residual EDTA on the characteristics and fiber density of the blood clots [73]. The results showed that EDTA irrigation for 1- or 5-min reduced clot formation, whereas final flushing with the normal saline solution improved fibrin formation. Accordingly, the irrigation protocol should be optimized prior to creating a blood clot. In some cases, there is little or no bleeding when irritating the apical tissue. The evoked intracanal blood may take a long time to clot or it may never clot. The placement of a bioceramic material also complicates the use of blood clot as scaffold [74,75]. Given the unfavorable histological results and the aforementioned shortcomings, blood clot may not be an ideal scaffold for REPs. To regenerate true pulp-dentin complex, other alternative scaffolds or composite scaffolds that combine blood clots with additional materials, growth factors or stem cells have been developed. However, a systematic review showed that blood clot based-composite scaffolds did not achieve significantly better histological results. Hard tissue formation was observed in 100% of the studies using composite scaffolds, including dentin-like tissue (2%), cementum-like tissue (80%),

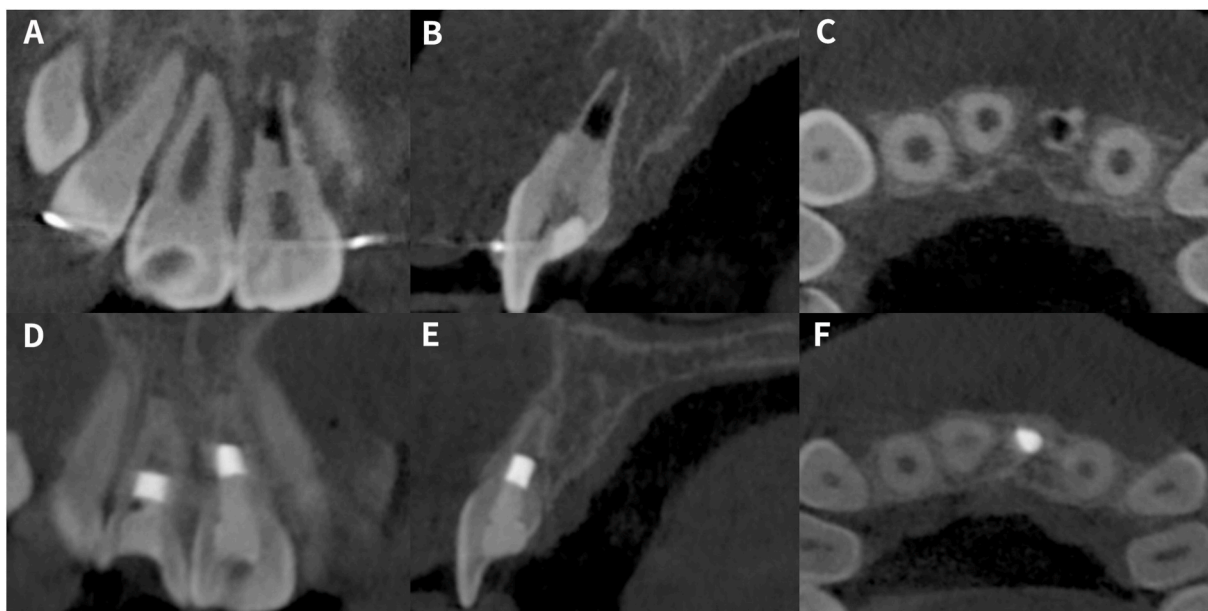


Fig. 4. Cone-beam computed tomographic (CBCT) images of teeth 8 and 9 in the previous figure. (A) The coronal view showed apical radiolucency present in tooth 9 with accompanying mesial root perforation. (B) The sagittal view showed the thin buccal and palatal bony plates of tooth 9. (C) The axial view showed mesial root perforation of tooth 9. (D) The coronal view of CBCT images of 24-month follow-up of tooth 9 and 12-month follow-up of tooth 8. There was resolution of the periapical lesion in tooth 8. Thickening of the root canal walls was observed for both teeth 8 and 9. The mesial root perforation in tooth 9 was repaired with hard tissue. (E) The sagittal view showed thickening of the buccal and palatal bony plates. (F) The axial view showed repair of mesial root perforation of tooth 9 with hard tissue. Reprinted with permission [37]. Copyright 2021, Elsevier.

and bone-like tissue (2%). The soft tissue formed in teeth treated with composite scaffolds was similar to that treated with blood clots [48].

2.2. Autologous platelet concentrates

Platelets are an essential component of whole blood. They act as pivotal regulators during the wound healing process [76–80]. When activated, immediate degranulation of platelets will result in a burst release of growth factors that actively promote stem cell homing, proliferation, differentiation and speedy vascularization. The released growth factors include platelet-derived growth factor, transforming growth factor (TGF), vascular endothelial growth factor (VEGF), epithelial growth factor and insulin-like growth factor [43,78]. Autologous platelet concentrates are biomaterials made by centrifuging a patient's own blood, which contain a high concentration of platelets. Based on the presence of leukocytes and fibrin architecture, the platelet concentrates may be classified into a four-family system, including platelet-rich plasma (PRP), platelet plasma-rich fibrin (PRF), leukocyte-and platelet-rich plasma (L-PRP) and leukocyte-and platelet-rich fibrin (L-PRF) [80]. Concentrated growth factor (CGF) is the latest generation of autologous platelet concentrates [81].

2.2.1. PRP

PRP is the first-generation platelet concentrate that was introduced into dentistry more than 20 years ago [82]. The procedure involves the accumulation and isolation of platelets using two or multiple centrifuge cycles. Briefly, a volume of venous blood is obtained from the patient. Because the preparation protocol is lengthy, anti-coagulants such as bovine thrombin and sodium citrate are mixed with the blood in the collection tubes. The tubes are then centrifuged to separate the platelets and leukocytes from the erythrocytes. The blood separates into three layers: erythrocytes at the bottom because of their higher density, a buffy coat layer in the middle and platelet-poor plasma on the top. The erythrocytes layer is discarded and the PRP is then separated from the platelet-poor plasma layer after a second cycle of centrifuging. The final platelet concentration varies with the preparation systems and protocols

utilized, which is approximately 3–5 times more concentrated than the physiologic platelet concentration in whole blood. Before PRP is injected into the root canal for REPs, it is re-activated for clotting via the addition of an external clotting factor such as saline, calcium chloride or bovine thrombin. After the platelets are activated, an immediate burst release of 70% of their stored growth factors is noted within 10 min, while 95% of the release is noted within the first hour. However, re-activation of PRP by endogenous clotting factors derived from the apical tissue via evoked bleeding permits better sustained release of growth factors. These growth factors, along with the fibrin matrix formed by the PRP clot, play a critical role in stem cell homing and promote their biological activities. This, in turn, expedites tissue repair and regeneration [78,81–86]. PRP has been described as a potentially ideal scaffold for REPs. Fig. 9 presents a case where PRP was used as an alternative to creating blood clot for traumatized tooth 8 with apical periodontitis and external root resorption because there was not sufficient blood induced into the canal space by physical irritation of the periapical tissues. Six-month follow-up radiograph showed discontinued external root resorption and significant resolution of periapical lesion of tooth 8. This case showed that PRP could be considered to be used as an alternative scaffold in REPs when the formation of blood clot in the canal is not achievable. During the past decade, a few studies have demonstrated the clinical success of PRP for REPs [87–93]. Torabinejad et al. reported a case in which an immature maxillary premolar had been accidentally extracted and immediately replanted using PRP. Clinical and radiographic examinations after 5.5 months showed promising outcomes. Notably, the tooth responded positively to pulp sensitivity tests [87]. Jadhav et al. showed that the use of PRP achieved better performance in periapical healing than a blood clot, with definitive evidence of apical closure and dentinal wall thickening [88]. Conversely, Bezgin et al. and Ulusoy et al. reported similar clinical outcomes between a blood clot and PRP [89, 93]. In an animal study, Zhang et al. compared the histological outcomes of PRP and blood clots in REPs [94]. No significant difference was observed between the two groups; both groups revealed ingrowth of cementum-like tissue, root canal wall thickening and apical closure. In another animal study, four different scaffolds were evaluated on REPs

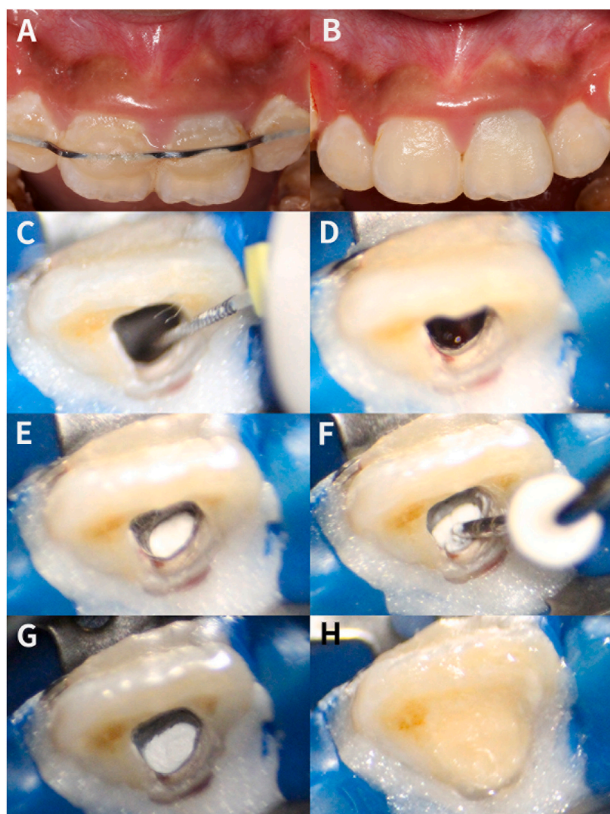


Fig. 5. Clinical images. (A) Preoperative buccal view of maxillary anterior teeth revealed intraoral swelling in the vestibule and a sinus tract associated with tooth 9. Teeth 7–10 were splined together. (B) Clinical view of the maxillary anterior teeth at 12-month follow-up. The soft tissue had a normal appearance. (C–D) Apical bleeding was induced in the canal space up to the cemento-enamel junction by rotating a K-file beyond the apex to irritate the periapical tissues physically. (E) After a blood clot was formed, a piece of CollaCote collagen sponge was placed over the blood clot as a matrix. (F–G) A 3-mm thick layer of iRoot BP Plus Root Repair Material was placed against the matrix. (H) The tooth was restored with resin composite.

performed on necrotic immature dog teeth with apical periodontitis. Those scaffolds included blood clots, dental pulp cells, PRP, or a mixture of dental pulp cells and PRP [95]. After three months, radiographic examination showed no obvious difference in periradicular healing among the experimental groups, although the groups that employed dental pulp cells achieved significantly better performance in root thickening. Histological examinations showed that the groups with PRP produced more soft tissue in the canals, whereas the groups using dental pulp cells produced more mineralized tissue. These findings suggest that PRP offers the potential advantage of soft issue formation; however, no dentin-like tissue formation was observed on the root canal wall irrespective of whether PRP was used. Based on published clinical and histological studies, PRP shows equivalent or better performance in REPs compared to blood clots [87–97]. It is worth noting that the use of PRP requires additional devices and complex preparation protocol and increases the cost and the possibility of infection. Therefore, the use of PRP in REPs should be rationalized based on cost benefits. Nevertheless, PRP is an alternative to blood clot in cases in which little or no blood clot is created when evoking apical bleeding.

2.2.2. PRF

PRF is the second-generation platelet concentrate introduced in 2001 [98]. The development of PRF focused on simplified preparation without biochemical blood handling. Compared to PRP, the preparation protocol of PRF is relatively simple, involving one centrifuge cycle and

excluding the use of anticoagulant and clotting factors [43,98]. Centrifuging should be commenced as soon as the blood is obtained from the patient because the blood will clot immediately in the tube. The recommended protocol is a spin cycle at 2700 rpm (400-g force) for 12 min. After centrifuge, the blood will separate into three layers: erythrocytes at the bottom, platelet-poor plasma on the top and a PRF clot with entrapment of platelets and leukocytes in the middle. The PRF is capable of slow release of growth factors for more than seven days. After removal with tweezers, the PRF can be cut into pieces or further pressed into a membrane by driving out the serum. Because of the slow and natural fibrin polymerization mode, PRF forms a three-dimensional (3D) fibrin matrix with a physiologic architecture, which is particularly favorable for cytokine enmeshment and cellular migration. The PRF incorporates the three critical parameters for tissue engineering: cells (platelets and leukocytes) that promote tissue healing and regeneration, continuous release of growth factors and a fibrin scaffold. Recent *in vitro* studies showed that PRF improved the migration, proliferation and differentiation of stem cells from the apical papilla (SCAPs) [99–102]. Therefore, PRF has been perceived as a better alternative to blood clot or PRP for REPs. Clinical studies showed that the use of PRF achieved favorable outcomes in the resolution of periapical lesion, root lengthening, dentin wall thickening and the restoration of tooth vitality [103–108]. In a retrospective controlled cohort study, Lv and coworkers compared the clinical outcomes of PRF and blood clots in REPs [108]. The results showed that both scaffolds achieved comparable clinical outcomes. Ulusoy et al. evaluated the clinical and radiographic outcome of blood clots, PRP and PRF in REPs. Similar outcomes were found among the three groups [93]. In an animal study, PRF and blood clot showed similar effectiveness in promoting periapical healing, inducing root development and reinforcing tooth fracture resistance [109]. In addition, histological studies showed that PRF did not achieve better results than blood clots and PRPs [110,111]. Considering the results derived from clinical and histological studies, the application of PRFs in REP for necrotic immature permanent teeth with apical periodontitis does not appear to show better performance than blood clots and PRP. A systematic review of human studies has also reported the lack of clinical studies with high quality and long-term follow-ups to confirm the superiority of PRP and PRF over blood clot as a scaffold for REPs. Therefore, the question of whether autologous platelet concentrates add additional benefits to the clinical and histological outcomes in REPs requires further investigation [112].

2.2.3. L-PRP, L-PRF and CGF

L-PRP and L-PRF contain higher concentrations of leukocytes compared to PRP and PRF, these cells play a prominent role in the anti-infectious action and immune regulation of the wound healing process [80]. Leucocytes in L-PRP and L-PRF produce large amounts of angiogenesis stimulators such as vascular endothelial growth factor (VEGF) [80]. In recent years, L-PRF has been used as a biomaterial scaffold in REPs in an immature permanent tooth in association with apical surgery [106] or in autologous DPSCs therapy for a mature permanent tooth with symptomatic irreversible pulpitis [113]. A multicenter controlled clinical trial was recently reported to evaluate the effect of L-PRF on REPs of immature permanent teeth [114]. Twenty-nine patients between 6 and 25 years with an inflamed or necrotic immature permanent tooth were included and divided into the test group (REPs with L-PRF) and control group (REPs without L-PRF). After 3, 6, 12, 24 and 36 months, the patients were recalled, and the teeth were clinically and radiographically examined at each recall session. Twenty-three teeth (9 test, 14 control) were analyzed, and the results showed that complete periapical bone healing was obtained qualitatively (91.3%) and quantitatively (87%) in most of the cases based on periapical radiograph evaluation, with no significant difference between the groups with respect to the baseline. No significant difference was found between the control and the test group regarding further root development based on peri-apical radiograph evaluation. Despite the limitations of this study,

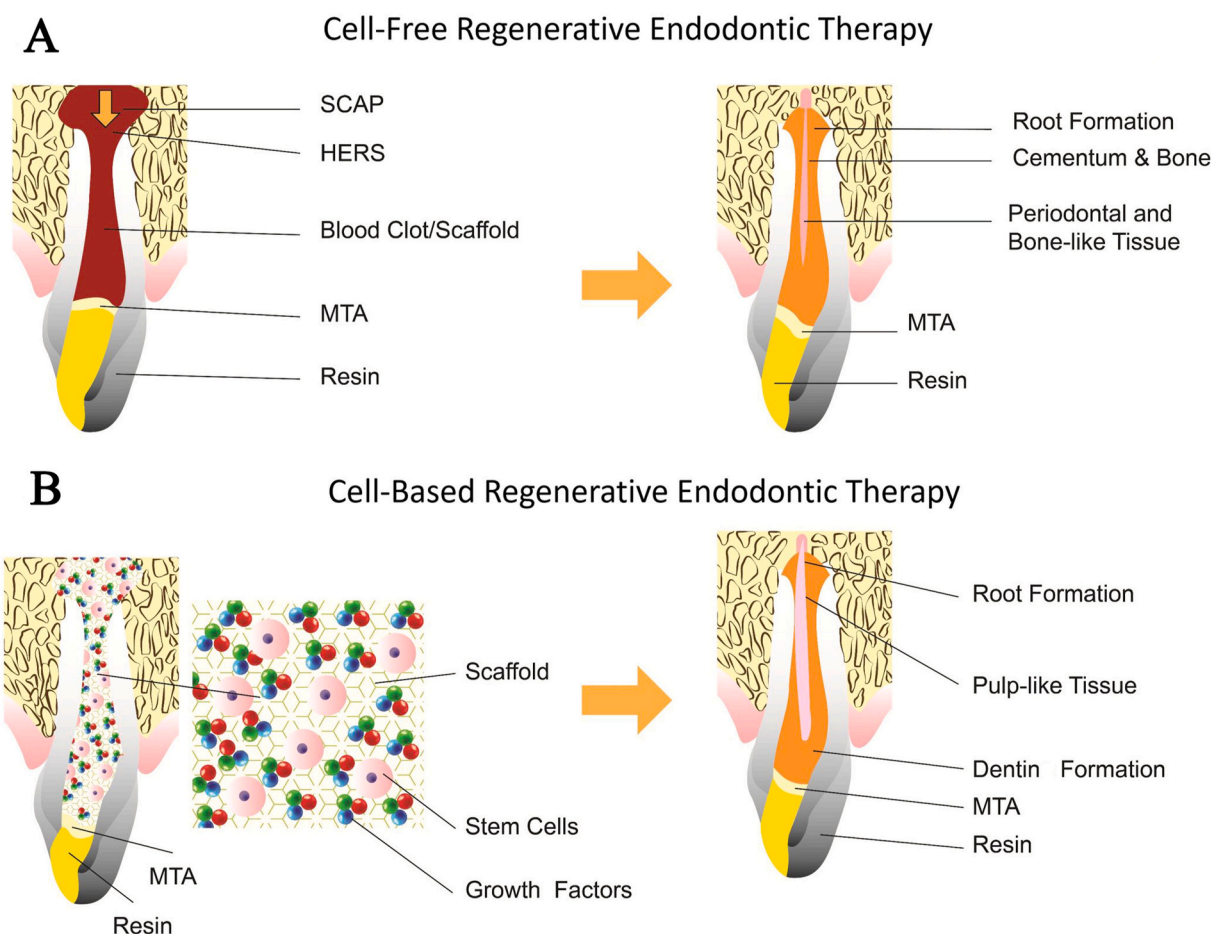


Fig. 6. Schematic diagram showing the clinical approaches and application of biomaterial scaffolds in regenerative endodontic procedures. (A) Cell-free endodontic therapy in which blood clot/scaffold is introduced into the canal space. (B) Cell-based endodontic therapy in which stem cells, scaffold and growth factors are introduced into the canal space. There is regeneration of pulp-like tissue as opposed to repair tissue in the cell-free approach in (A). SCAP: stem cells from the apical papilla; HERS: Hertwig's epithelial root sheath; MTA: mineral trioxide aggregate. Reprinted with permission [20]. Copyright 2021, Wiley.

L-PRF seems to be a viable biomaterial scaffold in REPs to obtain peri-apical bone healing and aid further root development of necrotic immature permanent teeth. It is worth noting that flare-ups appeared only in three teeth of the test group in the first-year post REPs. The pro-inflammatory cytokines in L-PRF might lead to flare-up when applied in REPs. Future well-designed randomized clinical studies are needed to investigate the benefits and the adverse reactions when using L-PRF as a biomaterial scaffold in REPs.

As the latest generation of platelet concentrate products, CGF has been used for tissue engineering such as bone regeneration. Recently, it has been shown that CGF can promote the proliferation, migration, and differentiation of SCAPs [99]. In a study by Xu et al. [115], CGF has been demonstrated to inhibit proinflammatory cytokines release and exert positive effect of the proliferation, migration, and differentiation of human dental stem pulp cells (hDPSCs) exposed to lipopolysaccharide (LPS). In this study, CGF fragment was used to fill the root canals of the immature single-rooted teeth in the beagle dogs. The teeth were then radiographed and extracted for histologic analyses at 8 weeks. The results of *in vivo* experiments showed the continued development of the immature teeth and immunohistochemical staining of VEGF and Nestin in the regenerated pulp-like tissues. Therefore, CGF could be a promising alternative biomaterial in REPs.

2.3. Decellularized extracellular matrix

Acellular extracellular matrix (ECM) derived through tissue decellularization has been used as a natural scaffold for many decades in

medicine and dentistry. Recently, human and animal dental pulp tissues have been successfully decellularized and used as scaffolds [116–121]. Song et al. evaluated three different decellularization protocols for 1.5 mm thick pulp-dentin discs prepared from extracted third molars. The authors selected the most optimal protocol to generate the maximum decellularization while preserving ECM composition and organization. Apical papilla stem cells that were seeded in the optimized decellularized dental pulp scaffold showed 3D proliferation and differentiation into odontoblast-like cells with their cell processes extending into the dentinal tubules [116]. Another study reported decellularization of the entire human dental pulp using a single cycle of a lower concentration of sodium dodecyl sulfate. The decellularized scaffold preserved the histological architecture and composition of the native tissue, which provided the dental pulp stem cells with a biological micro-environment [117]. Both studies used dental pulp tissue from extracted human teeth for decellularization. Extracted teeth are an abundant resource for the preparation of these allograft scaffolds because autogenic sources of ECM are not always feasible for each patient in the clinical setting. Decellularized dental pulp derived from animals is also a potentially practical solution. Alqahtani et al. decellularized swine dental pulp tissue to obtain a xenograft scaffold, which was then implanted into fully debrided root canals in dogs [119]. The implanted decellularized scaffold promoted the recruitment of apical stem cells to form pulp-like tissue with the expression of odontoblastic marker. In a more recent study, bovine pulp was successfully decellularized and processed to create a 3D macro-porous, injectable scaffold which favored the viability, proliferation, attachment and morphology of human bone

Table 1
Biomaterial scaffolds employed in regenerative endodontic procedures.

Biomaterials	Favorable properties	Limitations	References
Host-derived biomaterial scaffolds			
Blood clot	<ul style="list-style-type: none"> • Low cost • Clinical simplicity • Host compatibility 	<ul style="list-style-type: none"> • Instability • Difficulties in invoking bleeding and hemostasis 	[42–44]
Autologous platelet concentrates			
Platelet-rich plasma	<ul style="list-style-type: none"> • Controlled release of growth factors 	<ul style="list-style-type: none"> • Comparatively expensive 	[42–44,82,84,85,89,91,
Platelet plasma-rich fibrin	<ul style="list-style-type: none"> • Host compatibility 	<ul style="list-style-type: none"> • Special equipment and reagents 	92,96,105,116–121]
Decellularized extracellular matrix	<ul style="list-style-type: none"> • Host compatibility • Creates an environment that is conducive to tissue growth 	<ul style="list-style-type: none"> • Time-consuming 	
Natural-derived biomaterial scaffolds			
Collagen	<ul style="list-style-type: none"> • Biocompatible • Biodegradable • Viscoelastic 	<ul style="list-style-type: none"> • Rapid degradation • Weak mechanical strength • Undergoes shrinkage 	[42–44,127,128]
Alginate	<ul style="list-style-type: none"> • Host compatibility • Inexpensive • Provide favorable structure for nutrient exchange 	<ul style="list-style-type: none"> • Weak mechanical strength before cross-linking and modification 	[42–44,138–141]
Chitosan	<ul style="list-style-type: none"> • Host compatibility • Biodegradable • Antibacterial activity 	<ul style="list-style-type: none"> • Weak mechanical strength • Undergoes shrinkage 	[42–44,147–152]
Hyaluronic Acid	<ul style="list-style-type: none"> • Biocompatible • Biodegradable • Bioactive 	<ul style="list-style-type: none"> • Rapid degradation • Weak mechanical strength before cross-linking and modification 	[42–44,161–166]
Hydrogel, natural	<ul style="list-style-type: none"> • Biocompatible • Injectable • Adaptive to the root canal space 	<ul style="list-style-type: none"> • Rapid degradation • Weak mechanical strength • Undergoes shrinkage 	[42–44,195]
Synthetic biomaterial scaffolds			
Hydraulic calcium silicate cements	<ul style="list-style-type: none"> • Biocompatible • Bioactive 	<ul style="list-style-type: none"> • Tooth discoloration • Slow degradation rate 	[42–44]
Synthetic polymers	<ul style="list-style-type: none"> • Biodegradable • Precise modification of physicochemical properties 	<ul style="list-style-type: none"> • Host response • Decrease of local environment pH • Relatively slow degradation rate compared with naturally derived biomaterials 	[42–44,187–191]
Hydrogel, synthetic	<ul style="list-style-type: none"> • Biocompatible • Injectable • Adaptive to the root canal space • Potential to self-assembly • Allow gelation <i>in situ</i> 	<ul style="list-style-type: none"> • Slow gelation • Ultraviolet light required for gelation may cause cell death 	[42–44,194,197,198]

marrow mesenchymal stem cells [120]. Xenogenous dental pulp has the adverse potential of inducing antigenic response or disease transmission. An ideal tissue decellularization protocol involves meticulous removal of all antigenic cellular components without adversely altering ECM composition, morphology and stem cell scaffold functions. As such, the protocols for preparing xenogenous pulp tissues need to be improved and optimized. A study compared the effect of seven different decellularization protocols on the decellularization of bovine dental pulp tissues [121]. The remnant cellular and nuclear contents, collagen and glycosaminoglycan composition, as well as the immune compatibility of

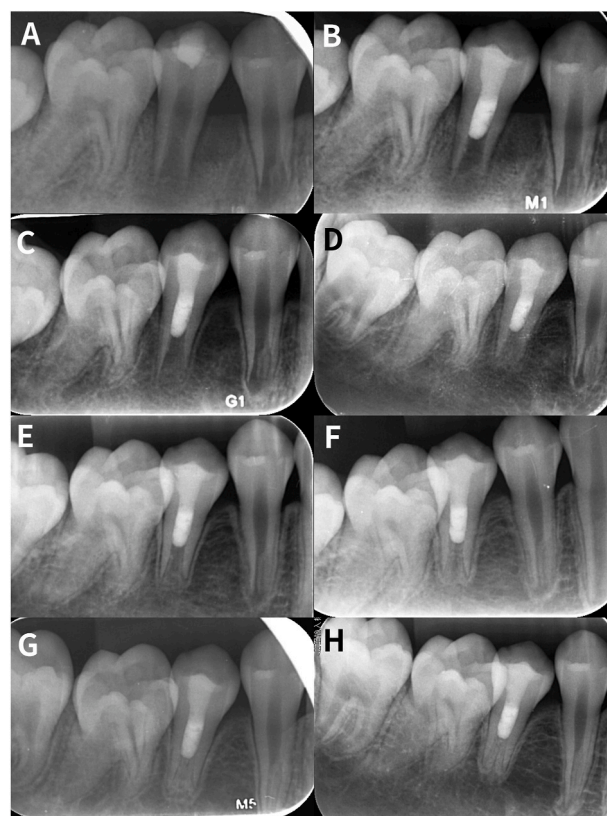

Fig. 7. Regenerative endodontic procedures performed on tooth 29 of a 9-year-old boy. Tooth 29 was diagnosed as pulpal necrosis with symptomatic apical periodontitis. (A) Preoperative periapical radiograph showing tooth 29 had a periapical lesion, an open apex and thin dentinal walls. (B) Postoperative radiograph of tooth 29. In the second treatment visit, apical bleeding was induced into the canal space up to the cementoenamel junction by rotating a K-file beyond the apex to irritate the periapical tissues physically. After a blood clot was formed, a 3-mm thickness of ProRoot Mineral Trioxide Aggregate was then placed against the CollaCote. The tooth was restored with glass ionomer cement and composite resin. (C) 3-month follow-up radiograph of tooth 29 showing resolution of the periapical lesion. (D–G) 6-month, 9-month, 12-month and 24-month follow-up radiographs of tooth 29 showing the continued growth of the apical portion of the root canal. (H) 36-month follow-up radiograph showed that tooth 29 had a similar root morphology as tooth 28, which underwent normal development. Cold and electric pulp tests showed positive results for tooth 29.

the pulp ECM were evaluated. Among the seven decellularization protocols, the 12E-0S-1T protocol had the best performance for REPs.

3. Natural biomaterial scaffolds

3.1. Collagen

Collagen is a large family of extracellular matrix proteins widely distributed in nature. Collagen possesses complex supramolecular structure, which provides a highly organized structural and biological framework [122]. Collagen has the potential to be used as a biomaterial in tissue engineering because of its biocompatible and biodegradable properties [113,114]. To date, different collagen-based scaffolds have been used for dental pulp regeneration, including pure collagen scaffolds (i.e., collagen sponge, pellet and membrane), collagen-based scaffolds combined with other natural or synthetic material, as well as composite scaffolds comprising collagen, growth factors or stem cells [115–128].

Pure collagen scaffolds can be molded into different shapes and adapt to the morphology of the targets, thus providing excellent clinical

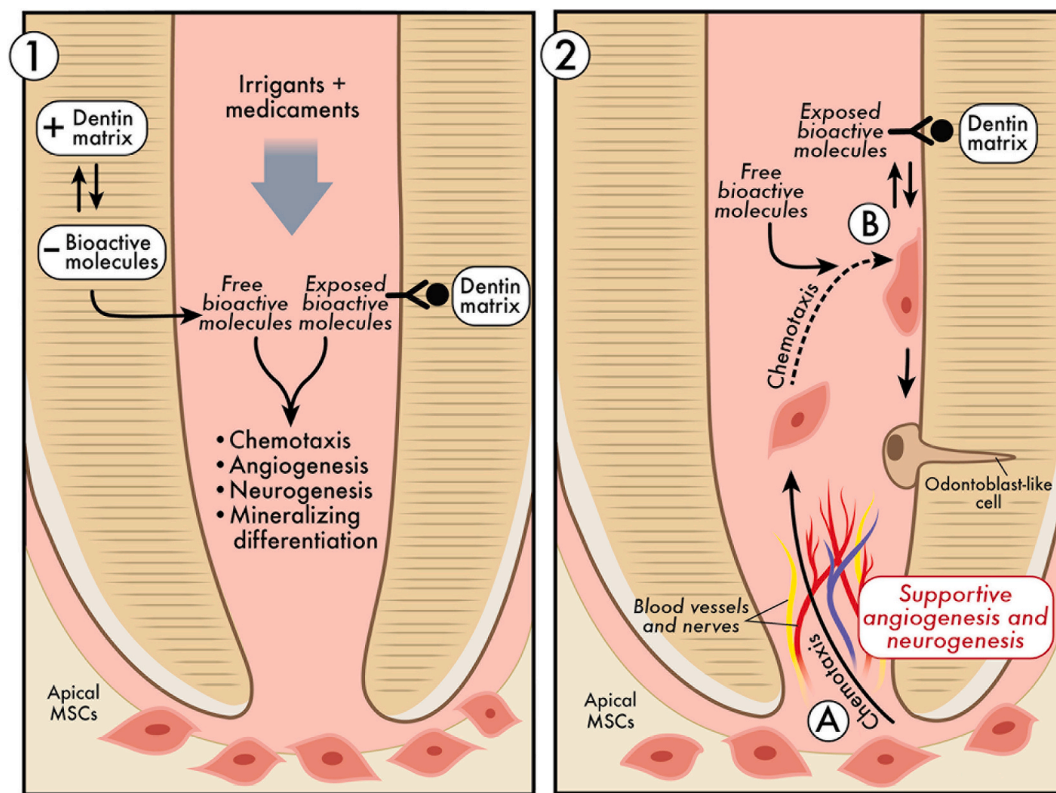


Fig. 8. Schematic illustrating the potential roles of irrigants and medicaments in the release and/or exposure of bioactive molecules sequestered from dentin and their influences on regenerative events. These events include chemotaxis, odontoblast-like cell differentiation, mineralization, angiogenesis and neurogenesis. Reprinted with permission [19]. Copyright 2021, Elsevier.

operating simplicity. In REPs, pure collagen scaffolds are recommended to be placed over the blood clot as the internal matrix to support the capping material [127]. Fig. 10 presents a case where collagen sponge was placed over the blood clot to secure the capping material against dislodgement. Collagen sponge or membrane can also be used when the formation of blood clot is not achievable within 15 min or the capping material should be placed immediately as soon as the blood is induced to the desired level of the canal. In a randomized, controlled clinical study, Jiang et al. evaluated the use of a collagen membrane as an intracanal scaffold in REPs [128]. Forty-three patients with 46 necrotic immature teeth were included and divided randomly into two groups according to whether a collagen membrane was used. After 7–28 months, the teeth using the collagen membrane showed thicker dentinal wall formation in the middle third of the roots, compared to those that did not utilize collagen membranes. The results from that study suggest that the use of pure collagen scaffolds produces better clinical outcome than just creating blood clot; however, the histological advantage is not evident.

Collagen-based composite scaffolds have been developed and they induced root development in human and animal studies [129–131]. SynOss Putty (Collagen Matrix, Oakland, NJ, USA) is a novel collagen-based composite scaffold comprising synthetic carbonated apatite. This putty has been approved by the US Food and Drug Administration (FDA) for use in dentistry. A case series study described the use of SynOss Putty in REPs for teeth with apical periodontitis [129]. After evoking apical bleeding, SynOss Putty was placed into the root canal. The follow-up radiographs showed rapid periapical healing and hard tissue formation. Nosrat et al. investigated the effect of SynOss Putty on the clinical, radiographic and histological outcomes of REPs in immature teeth [130]. Three pairs of mandibular premolars scheduled for extraction from three patients were pulpectomized and treated using different scaffolds. After 2.5–7.5 months, all teeth demonstrated root development. Histological examination showed the formation of

mineralized tissue in the root canal spaces and the cementum-like tissue on the dentinal walls in teeth treated with SynOss Putty and blood clot scaffold. In contrast, periapical lesions did not heal in teeth that were treated with SynOss Putty only, without a supplemental blood clot; there was no pulpal tissue formation in the root canal spaces. The teeth that were treated with blood clot only revealed the formation of fibrotic connective tissue, malformed cementum in the root canal spaces and cementum-like tissue on the dentinal walls. These findings suggest that a combination of SynOss Putty and blood clot as a scaffold for REPs may promote hard tissue formation in human infected or non-infected teeth. An animal study compared the histological outcomes of using blood clots or SynOss Putty in REPs for immature ferret teeth [131]. Bone-like or cementum-like tissue was formed in the root canals of the teeth treated with blood clots. However, pulpal tissue and the odontoblastic layer were absent. For teeth treated with SynOss Putty and blood clot, no hard tissue formation was evident in most of the canals. The unfavorable results achieved by using SynOss Putty and blood clot as a scaffold were not consistent with the results reported in the two previous studies. This may be attributed to the different experimental designs among the three studies. However, no newly formed pulp tissue was observed in any tooth in all of the three studies.

Collagen plays an essential role in regulating stem cell biological activities by providing specific cellular markers and homing signals [132]. The pore size and structure of pure collagen scaffolds or collagen-based composite scaffolds may be controlled and customized to provide an ideal 3D architecture for the colonization of seeded stem cells [127]. Previous studies showed that collagen based-composite scaffolds incorporating growth factors promoted proliferation and differentiation of dental stem cells, with enhanced hard and soft tissue formation [133–135]. Murakami et al. showed that a collagen scaffold containing granulocyte-colony-stimulating factor (G-CSF) promoted mobilization, proliferation and differentiation of dental pulp stem cells (DPSCs) [136].

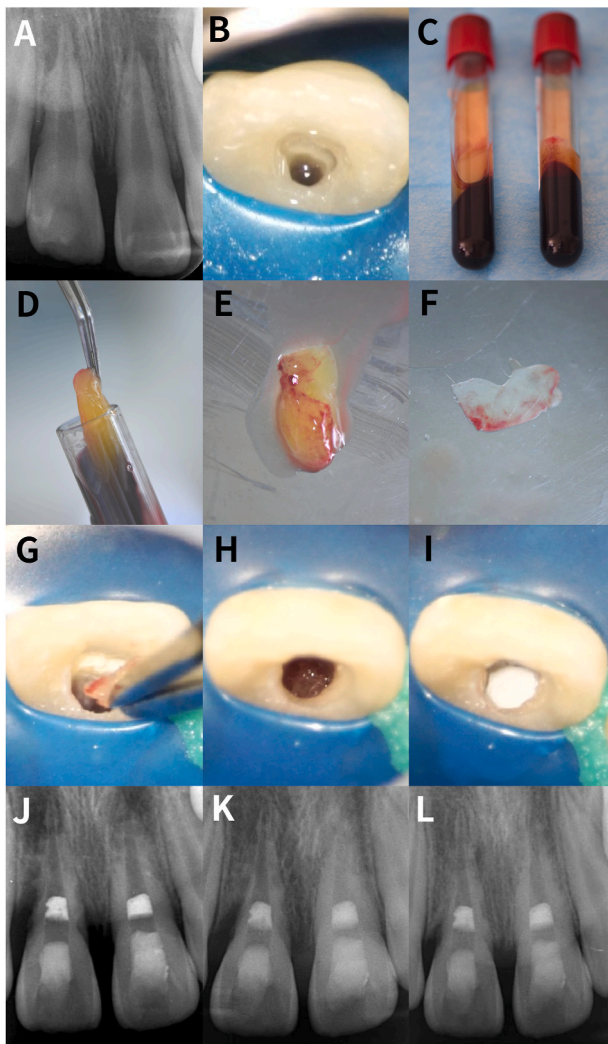


Fig. 9. Regenerative endodontic procedures performed with platelet-rich plasma on teeth 8 and 9 of a 9-year-old boy. Both teeth were diagnosed as pulpal necrosis with asymptomatic apical periodontitis. (A) Periapical radiograph obtained at the first visit showed teeth 8 and 9 had external root resorption and periapical lesions. Tooth 8 had an angular bony defect at the distal aspect. The REPs were scheduled one week later for teeth 8 and 9. (B) At the second visit, teeth 8 and 9 were accessed, copiously irrigated and medicated with calcium hydroxide paste for two weeks. At the third visit, platelet-rich plasma was used as an alternative to creating a blood clot for tooth 8 because there was not sufficient blood induced into the canal space by physical irritation of the periapical tissues. Conventional REPs were applied for tooth 9. (C) Venous blood was drawn from the patient and centrifuged to obtain platelet-rich plasma. (D) The platelet-rich plasma was removed from the test tube with sterile pliers. (E) Platelet-rich plasma. (F) A membrane consisting of platelet-rich plasma was prepared by compression using a sterile glass plate. (G) The platelet-rich plasma membrane was cut into fragments. The fragments were placed incrementally into the canal. (H) The platelet-rich plasma membrane fragments were placed to a level that was 3 mm below the cemento-enamel junction (I) A 3-mm thick layer of bioceramic paste was placed over the platelet-rich plasma fragments. (J) Periapical radiograph after REPs. (K) Three-month follow-up radiograph showed complete resolution of the periapical lesion in tooth 9. The distal angular bony defect and periapical lesion of tooth 8 were partially repaired. (L) Six-month follow-up radiograph showed continued healing of the distal angular bony defect and periapical lesion of tooth 8.

Ihara et al. transplanted a collagen scaffold loaded with G-CSF and mobilized DPSCs in a pulpctomized dog tooth and successfully generated the pulp-dentin complex without toxicity or adverse events [137]. In a pilot clinical study, mobilized DPSCs were transplanted with G-CSF

in a collagen scaffold into five mature pulpctomized teeth [38]. Clinical and laboratory examination demonstrated the safety, success and efficacy of this combinatorial therapy for regeneration of the pulp-dentin complex. This study represents the first clinical study that utilizes mobilized DPSCs transplantation in human teeth. However, no histological evaluation was conducted to reveal the true nature of the regenerated soft and hard tissue. The specimens included in this study were mature teeth with severe irreversible pulpitis instead of necrotic immature teeth with apical periodontitis. The intracanal micro-environment of necrotic teeth probably exerted a negative effect on the survival and differentiation of DPSCs. Therefore, further studies are required to elucidate the clinical and histological efficacy of mobilized DPSCs transplantation in necrotic immature or mature teeth with periradicular lesions.

3.2. Alginate

Alginate is a naturally occurring salt of alginic acid consisting of linear copolymers of β -(1–4) linked D-mannuronic acid and β -(1–4)-linked L-guluronic acid monomers, which is polysaccharide extract of brown seaweeds [138]. It is a highly esteemed biomaterial in tissue engineering because of its biocompatibility and low cost [138]. When cross-linked chemically or physically through various approaches, alginate may be transformed into highly tunable hydrogels that resemble a 3D tissue ECM network. Hence, alginate is a promising matrix for tissue engineering. Alginate hydrogels alone or in combination with other biomaterials have been used extensively as scaffolds in REPs for loading stem cells, with or without the supplement of growth factors [139–141]. Alginate hydrogels containing TGF- β 1 promoted dentin matrix secretion and induced stem cell differentiation into odontoblast-like cells [139]. Dental pulp cells seeded in an alginate scaffold can differentiate into odontoblast-like cells and stimulated mineralization after the cell-loaded scaffold was transplanted subcutaneously into nude mice [140]. The anatomical complexity of root canal systems adds significant mechanical and biological difficulties to the design and delivery of scaffolds in pulp tissue engineering, especially for molar teeth. Bhoj et al. developed a novel alginate hydrogel scaffold that anatomically resembled the pulp tissue [142]. The incorporation of growth factors and stem cells in the scaffold provided internal cellular and molecular micro-environments necessary for the initiation of dental pulp regeneration. To facilitate easy delivery of stem cells and growth factors into the canals, Zhang et al. designed injectable alginate/laponite hydrogel microspheres for encapsulation of human dental pulp stem cells (hDPSCs) and VEGF, which promoted the regeneration of pulp-like tissue [143].

Although alginate scaffolds have gained increasing attention in REPs, one of their drawbacks lies in their low mechanical stiffness. The addition of nano-hydroxyapatite in alginate scaffolds not only reinforces the mechanical properties but also promotes the differentiation of hDPSCs and biomineralization [144]. Recently adopted 3D bioprinting technology also offers exciting opportunities for scaffold fabrication in tissue engineering [145]. Yu et al. fabricated a 3D-printed alginate/gelatin hydrogel scaffold which enabled better differentiation and mineralization of hDPSCs compared with common alginate/gelatin hydrogel scaffolds [146].

3.3. Chitosan

Chitosan is a natural amino-polysaccharide with a random arrangement of β -(1–4)-linked D-glucosamine and N-acetyl-D-glucosamine, which are derived from the exoskeletons of crustaceans [147,148]. It is used extensively as a scaffold biomaterial in tissue engineering and drug delivery because of its biocompatibility, biodegradability and broad antimicrobial spectrum [147–149]. Chitosan scaffolds provide a conductive and favorable micro-environment to promote the biological activities of DPSCs [150–152]. An animal study showed that chitosan

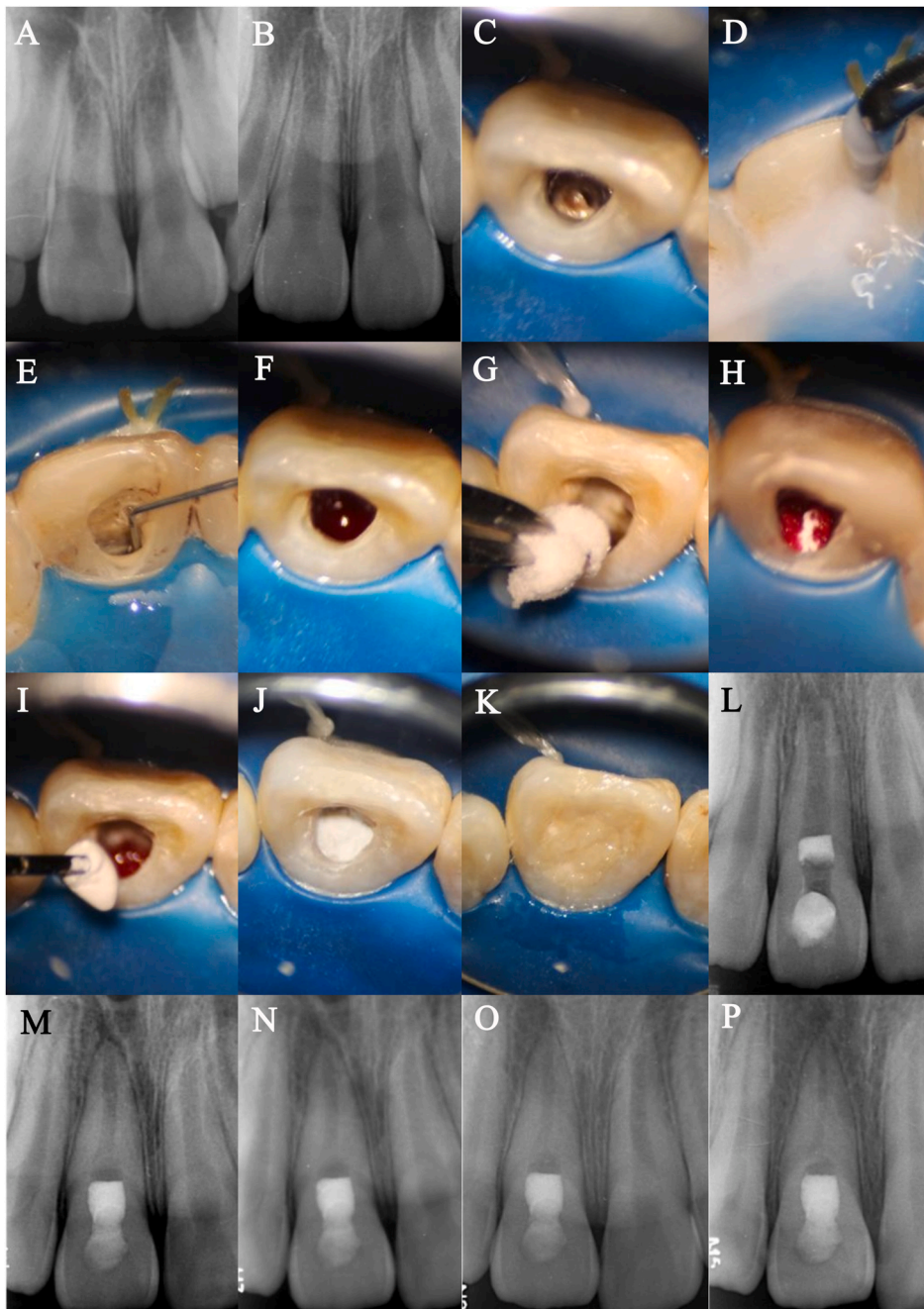


Fig. 10. Regenerative endodontic procedures performed with a pure collagen scaffold for an 8-year-old girl who had trauma of tooth 8 with intrusive luxation. The tooth was diagnosed as pulpal necrosis and symptomatic apical periodontitis approximately four months after injury. (A) Periapical radiograph of tooth 8 after injury indicating intrusive luxation. (B) 4-month radiograph of tooth 8 after injury. (C–E) Clinical image of tooth 8. After rubber dam isolation and access, the tooth was copiously irrigated with 1.5% NaOCl and 17% EDTA. The root canal was dried with paper points and medicated with calcium hydroxide dressing for two weeks. During the second visit, the calcium hydroxide dressing was removed with ultrasonic irrigation. The canal was copiously irrigated with 17% EDTA to induce release of growth factors from the partially demineralized dentin matrix. (F) After the root canal was dried with paper points, a pre-curved K-file was inserted to 2 mm beyond the root apex and rotated to physically irritate the periapical tissues and induce apical bleeding into the canal space up to the cemento-enamel junction. (G–H) After blood clot formation, a piece of resorbable collagen sponge was placed over the blood clot. (I–J) A 3-mm thick layer of bioceramic paste was incrementally placed over the collagen sponge. (K) The access cavity was filled with resin composite. (L) Postoperative periapical radiograph of tooth 8. (M) 6-month follow-up radiograph of tooth 8 showing root canal space narrowing. (N–O) 12-month and 24-month follow-up radiographs of tooth 8 showing the formation of hard tissue at the cervical level. (P) 48-month follow-up radiographs of tooth 8 showing continued root canal space narrowing. The tooth was asymptomatic and functional. It responded positively to cold and electric pulp tests.

hydrogels loaded with DPSCs and growth factors were capable of regeneration of pulp-dentin like tissues, with complete root maturation in necrotic immature teeth with periapical lesions [153]. However, in another animal study, the incorporation of chitosan scaffolds in REPs did not promote the formation of intracanal hard and soft tissue when compared with a blood clot scaffold [154].

The first step in REPs for necrotic teeth with apical periodontitis is disinfection. Different antibacterial agents containing antibiotic-loaded chitosan or chitosan-based scaffolds have been developed [155,156]. Ducret et al. designed a chitosan-enriched fibrin hydrogel that possessed potent antibacterial property and the absence of detrimental effects on dental pulp cells [155]. Aksel et al. compared the antimicrobial activity and biocompatibility of several antibiotic-loaded hydrogel scaffolds. Among those scaffolds, the double antibiotic-loaded chitosan-fibrin hydrogels demonstrated the best antimicrobial performance [156].

The spatial and temporal control of the release of bioactive molecules

is pivotal in pulp tissue engineering. Chitosan derivatives have been used as delivery systems for bioactive molecules and have the potential to provide effective, sustained release of those molecules [157–160]. Shrestha et al. showed that the dexamethasone-loaded chitosan nanoparticles fabricated by adsorption method were capable of releasing dexamethasone for at least four weeks to promote odontogenic differentiation of SCAPs [159]. Soares and coworkers showed that a simvastatin-releasing chitosan scaffold significantly enhanced the chemotaxis and biomineralization potential of dental pulp cells [160].

3.4. Hyaluronic acid

Glycosaminoglycans are long linear polysaccharide molecules consisting of repeating disaccharide units. They have shown great potential in the fabrication of tissue engineering constructs for wound healing in the dermis and cornea, for restoring articular cartilage and for

regeneration of neural tissues [161,162]. Hyaluronic acid is a glycosaminoglycan that is naturally present in the ECM. Hyaluronic acid has been found in the human dental pulp tissue and plays an important role in maintaining extracellular spacing, preserving the morphologic integrity of the dental pulp and modulating the development of the dentin and enamel matrix during odontogenesis [163]. Hyaluronic acid may be injected into the root canal in the form of a hydrogel. The injected hyaluronic acid adapts to the irregular morphology of the root canal system and undergoes gelation within the canal space [164]. In cell-free regenerative endodontic therapy, a promising scaffold should be capable of recruiting endogenous stem cells from the periapical tissue. Hyaluronic acid interacts with the membrane receptors of SCAPs and accelerates the migration of SCAPs into the canal space. The viability, differentiation and mineralization of SCAPs can be promoted when cultured in hydrogel containing hyaluronic acid-based scaffolds [165]. These attractive properties render hyaluronic acid a potential candidate for the fabrication of scaffolds in REPs. Ferroni et al. showed that DPSCs could differentiate into neuronal, glial, endothelial and osteogenic cell lineages and form dental pulp-like tissue when seeded onto a hyaluronic acid-based scaffold and cultivated in the presence of various differentiation factors [166]. Osteodentin-like tissue could be regenerated after hyaluronic acid-DPSCs constructs were implanted into critical-size bone defects in rats.

4. Synthetic biomaterial scaffolds

4.1. Hydraulic calcium silicate cements

Hydraulic calcium silicate cements are tricalcium silicate-based materials with hydration and hydraulic properties. These cements possess bioactivity by forming a carbonated apatite surface layer in the presence of water or tissue fluid containing calcium and phosphate ions. This biomineralization process endows hydraulic calcium silicate cements with a variety of biological properties including biocompatibility, antibacterial property, sealing ability, osteoconductivity and osteoinductivity [167–170]. Mineral trioxide aggregate (MTA), the first-generation hydraulic calcium silicate cement, was introduced in endodontics in the 1990s [171]. Several other hydraulic calcium silicate cements have since been commercialized. Since their introduction, the clinical indications of hydraulic calcium silicate cements have widened, including root canal treatment, apical surgery, vital pulp therapy and REPs [172]. In a case report published in 2004, Banchs et al. first advocated the placement of MTA over a blood clot to produce a bacteria-tight cervical seal [173]. Currently, MTA is one of the most popular intracoronary filling materials in REPs [52]. It has been reported that MTA promotes the biological activities of dental stem cells and the release of essential growth factors. These favorable properties suggest that MTA may be used as a scaffold in REPs [174–176]. The idea of using MTA as a scaffold was first described by Chaniotis et al. in a case report [177]. In that report, the authors outlined the use of MTA/blood mixture in REPs to treat a maxillary central incisor with multiple horizontal fractures [177]. After evoking apical bleeding, MTA powder was mixed with blood to create a bioceramic mixture to cover the fractures. At 24 months follow-up, healing of the horizontal fractures was observed. The authors of the case report claimed that the use of MTA/blood mixture might be beneficial for the induction of hard tissue healing. However, there is no study to validate the assumption that the hydraulic calcium silicate cement as a solo scaffold can improve the material characteristics/bioactivity of blood clot. Several composite scaffolds that combine hydraulic calcium silicate cements with other bioactive materials have been developed [178–180]. Budiraharjo et al. used a tooth model to test a novel carboxymethyl chitosan scaffold. Interestingly, the bioactive potential of this scaffold was enhanced by incorporating MTA [178]. Ho et al. used a 3D printer to fabricate composite scaffolds from Biodentine (Septodont, Saint-Maur-des-Fossés, France)/polycaprolactone mixture [179]. The hDPCs cultured on the scaffolds showed favorable

odontogenic properties and mineralization characteristics. Further research is needed to investigate their clinical translation potential. Previous studies showed that root canal fillings performed with MTA increase the fracture resistance of simulated immature roots, even to the level comparable with intact roots [181,182]. Therefore, it is reasonable to expect that MTA plugs may reinforce the immature teeth after REPs. This assumption was supported by a recent 3D finite element analysis study which showed that using a 5 mm thick MTA plug reduced stress values in the middle-third of the root [183]. Although REPs using MTA plug have achieved a high success rate, tooth discoloration associated with MTA poses an esthetic concern, especially in anterior teeth [184]. New generations of hydraulic calcium silicate cements with similar or superior biological properties have been recommended as alternatives to MTA in REPs. These alternative formulations have also achieved promising clinical outcomes [185,186].

4.2. Synthetic polymers

Synthetic polymers that have been successfully used as scaffold materials in pulp tissue engineering include polylactic acid (PLA), polyglycolic acid (PGA), poly-L-lactic acid (PLLA), and polylactic-glycolic acid (PLGA) [43,187]. These synthetic polymers are nontoxic, biodegradable and allow precise manipulation of their physicochemical properties such as mechanical stiffness, degradation rate, porosity and microstructure [187]. The US FDA has approved polymer scaffolds for some medical treatments. Thus, the possibility exists that polymer scaffolds may be approved for pulp tissue engineering in the future [188]. Polylactic acid has been used successfully to create dental pulp and periodontal constructs for preserving the vitality of DPSCs and periodontal ligament stem cells [189]. Polylactic acid scaffolds may also enhance the proliferation of mature dental pulp cells compared with collagen or calcium phosphate scaffolds. It is known that the morphological characteristics of scaffolds, such as pore size and gap width between struts, affect cell adhesion, proliferation and differentiation [190]. It is possible to control cell fate by modification of the structural properties of a scaffold [191]. Recently, 3D printing technology has been used to produce tailored PLA scaffolds for pulp tissue engineering. Alksne et al. produced two types of 3D-printed PLA scaffolds with macroscopical patterns (i.e., larger than the cell's diameter): wavy scaffolds and porous scaffolds. Both scaffolds enhanced DPSCs proliferation and increased osteogenic differentiation [192]. Hsiao et al. compared two types of 3D-printed PLA scaffolds with between-struts gap widths of 150 μ m and 200 μ m. The authors reported that scaffolds with narrower gaps could induce the neural differentiation of hDPSCs [193].

5. Hydrogels

Injectable biomaterials such as hydrogels are of particular interest for fabricating scaffolds in REPs because of their ease of application and the ability to adapt to irregular-shaped root canal systems [194]. Hydrogels are 3D hydrophilic polymer networks that can absorb large amounts of water or tissue fluids [195]. These highly tunable and biocompatible materials are not only designed to resemble the structure of the ECM but can also be modified to facilitate sustained release of chemotactic and angiogenic agents for cell homing and angiogenesis. Hydrogels that are prepared by self-assembly of peptides may be used as matrices to create micro-environments for enhancing cell attachment and proliferation [196]. Gelatin methacryloyl (GelMA)-based hydrogels have been used to construct a wide range of tissue engineering scaffolds because of their excellent biocompatibility and physicochemical compliance when compared with other artificial hydrogels. Recently, GelMA-based hydrogels have been used to fabricate various acellular or cell-laden constructs that can be injected into human tooth root segments [197,198]. In a recently published study, hDPSCs and human umbilical vein endothelial cell (HUVEC)-encapsulated GelMA constructs/root segments were cultivated in osteogenic medium prior to

subcutaneous implantation into the mouse dorsum for 4 or 8 weeks [197]. The implanted GelMA-based hydrogels facilitated attachment and proliferation of the hDPSCs/HUVECs as well as provided attachment for the infiltrating host cells. The hDPSC/HUVEC-seeded GelMA hydrogels promoted the formation of well-organized and functional pulp-like tissue in the root segments, unlike acellular GelMA constructs or empty root segment. The GelMA may be mixed with photoinitiators that initiate photo-polymerization to produce photo-crosslinkable hydrogels by irradiation with visible light-curing devices. These light-curing devices are more common and have fewer adverse effects on DNA and biological functions when compared with ultraviolet dental curing devices [198].

6. Challenges and future prospects for the application of biomaterial scaffolds in regenerative endodontics

Regenerative endodontic procedures have witnessed substantial advancements in recent years. There has been a paradigm shift from revascularization by creating an intracanal blood clot to the regeneration of the pulp-dentin complex. Tissue engineering and regenerative medicine offer exciting opportunities for amalgamating biomaterial scaffolds, bioactive molecules and stem/progenitor cells to enhance the efficacy of REPs. Despite the high success rates in the resolution of apical periodontitis, the prognosis of continued root development in REPs that utilize the blood clot as a scaffold remains unpredictable. In addition, most human histological studies appear to indicate that the tissue generated by this approach is more likely to be pulp-like soft tissue and cementum-like or bone-like hard tissues. In strict histological terms, these tissues are simply manifestations of tissue repair via fibrosis and mineralization of the fibrotic tissues [199] and do not represent genuine regeneration of the pulp-dentin complex [200].

A plethora of challenges lie ahead for REPs for favorable clinical and histological outcomes to be achieved in the future. It has been shown that residual bacteria in the root canal adversely affect wound healing and root maturation [19,201,202]. Microbial control of necrotic immature teeth with apical periodontitis is challenging; bacterial biofilms that adhere to the uneven surface of the blunderbuss canals render conventional debridement and disinfection exorbitantly difficult in root canal systems [19,201,202]. Antibacterial strategies or agents employed in REPs should accomplish efficient disinfection without interfering with the survival of the essential cellular and molecular components that are mandatory for the regenerative process. To enhance disinfection control in REPs, antimicrobial biomaterials or antibiotics may be used for the fabrication of scaffolds for REPs. For example, antibiotic-loaded nanofibrous scaffolds fabricated by electrospinning technique are capable of sustained release of low concentrations of antibiotics. These scaffolds create an environment that is conducive to tissue regeneration until the host immune function is sufficiently restored in the root canal system to deal with the residual bacteria [203]. The spatial control on the regeneration of the pulp-dentin complex is one major challenge in REPs [204]. The clinical outcomes of REPs based on the current protocols are unpredictable, and the regenerated tissue lacks the spatial organization observed in normal dentin–pulp complex: the regeneration of pulp in the center and dentin in the peripheral area [204]. A bilayered scaffold manufactured from biodegradable biomaterial (PLGA) has been demonstrated to provide spatial control of differential DPSCs penetration and dentinogenic differentiation [205]. Such a biomaterial scaffold in conjunction with DPSCs may facilitate the regeneration of a physiologic dentin–pulp complex *in vivo*.

Existing protocols for cell-free regenerative endodontic therapy attempt to regenerate damaged or lost dental pulp tissue, dentin and root structures by introducing endogenous stem cells into the canal space. This is followed by filling the canal with blood-derived scaffolds or any other biomaterial scaffolds. However, the majority of human histological studies have shown that these protocols are unlikely to regenerate the pulp-dentin complex apart from provoking fibrotic

wound repair [20]. Recently identified and isolated proteins sequestered within dentine mineralized matrix serve as intracellular signals to control events such as cell recruitment, migration, proliferation or differentiation [206]. The release of these specific biomolecules by ultrasonic activation of certain irrigants or medicaments could enable these signaling cues available after a biocompatible disinfection approach and incorporate the cell-homing approaches in the cell-free regenerative endodontic therapy [72]. In addition, the current protocols for cell-free regenerative endodontic therapy cannot control the formation of specific tissue types in the pulp space. Therefore, the combination of mobilization factors and functionalized biomaterial scaffolds and delivery platforms may be considered to regulate and enhance the regeneration of the blood vessels, nerves as well as dentine in the canal [207].

Host-derived biomaterials that can release mobilization factors to stimulate the recruitment of mesenchymal stem cells from the periapical tissues can be potential candidates for scaffolding in cell-free regenerative endodontic therapy [208,209]. The amniotic membrane represents the innermost layer of the placenta, which consists of a single epithelial layer, a thick basement membrane and an avascular stromal matrix [210]. The embryonic ectodermal-derived amniotic epithelial cells in the epithelial layer and the embryonic mesodermal-derived mesenchymal stromal cells in the stromal layer maintain multipotent/pluripotent characteristics for tissue regeneration [210–213]. The biological molecules within the membrane such as growth factors (i.e., vascular endothelial growth factor, platelet-derived growth factor, transforming growth factor- β 1 and basic fibroblast growth factor) and anti-inflammatory cytokines (i.e., interleukin-4, -6, -8 and -10) have been shown to mobilize hematopoietic and mesenchymal stem cells and promote cellular growth and differentiation [210–213]. It has been shown that both basement membrane side and stromal side of the acellular amniotic membrane matrix could promote the osteogenic differentiation of human dental apical papilla cells. Recent published case reports suggest amniotic membrane may be a promising biomaterial scaffold in cell-free regenerative endodontic treatment for immature tooth [211,212]. An animal study compared the efficacy of blood clot, collagen membrane and amnion-chorion membrane as scaffolds in regenerative endodontic procedures for necrotic mature teeth of dogs [213]. The teeth were accessed and left open for two weeks to induce root canal infection and inflammation. The regenerative endodontic procedures were applied after the teeth were irrigated with 1.5% sodium hypochlorite solution and had two weeks of calcium hydroxide intracanal medicament. After 12 weeks, the dogs were euthanized for histologic evaluation. The results of histologic analysis revealed that compared to the blood clot and collagen membrane groups, a higher volume of intracanal fibrous connective tissue was formed in the amnion-chorion membrane group. Moreover, the amnion-chorion membrane group showed less periapical inflammation than the blood clot group. It should also be noted that odontoblast-like cells were only observed in the amnion-chorion membrane group. Based on the results of this animal study, the use of the amnion-chorion membrane may be beneficial in improving the outcomes of cell-free regenerative endodontic therapy. However, further preclinical and clinical studies are warranted to investigate the efficacy of amniotic membrane or amniotic membrane-based materials in regenerative endodontic procedures for immature and mature permanent teeth.

Scaffolds fabricated by conventional techniques may fail to recapitulate the complex physiological microstructure of dental pulp tissue with heterogeneous, porous, and permeable properties [42,146]. Moreover, an ideal scaffold should mimic the microenvironment in the dentin–pulp complex and facilitate the temporal and spatial regulation of cell distribution and cell proliferation [146]. The emerging 3D bioprinting technologies may serve as a promising alternative to address challenges and provide possibilities in the manufacturing of customized construct with three-dimensional patient-tailored shapes and compositions [214–216]. A recently published study showed that compared with Alginate/gelatin hydrogel scaffold, 3D-printed Alginate/gelatin

hydrogel scaffold is more suitable for the growth and adhesion of hDPSCs [217]. The aqueous extract of the 3D-printed scaffold contained more calcium and phosphorus ions and can better promote cell proliferation and differentiation. Vascularization of a functional and interconnected vasculature in REPs through traditional strategies may require time intensive biological processes, especially for full-length root canals of mature teeth [218]. Recently, 3D bioprinting technology and odontoblast-laden photocrosslinkable hydrogels were used to fabricate pre-vascularized pulp-like tissue constructs with 500 μm microchannels throughout the root canals [219]. Endothelial colony-forming cells seeded into the microchannels formed monolayers that underwent endothelial sprouting into the hydrogel matrix within seven days in culture.

Nanotechnology has been undergoing rapid development in science and technology and witnessed tremendous achievements in creating a wide variety of biomedical applications such as tissue regeneration, drug delivery, biosensors, antimicrobial application, gene transfection and imaging [220,221]. In the last two decades, nanotechnology has become a powerful tool for the design, synthesis and fabrication of advanced nanoscale biomaterials that can be harnessed for root canal disinfection, stabilization of root dentine, delivery of bioactive molecules and scaffolding for regenerative endodontics [157–159,220–230]. The effective elimination of bacterial biofilms is considered as the major challenge in the clinical procedures of endodontic regeneration. Nanomaterials such as antibacterial nanoparticles (e.g., chitosan nanoparticles, bioactive glass and silver nanoparticles) have been extensively investigated and shown significant potential for eliminating endodontic biofilms [222–225]. Kishen et al. firstly revealed the efficacy of various cationic nanoparticles in improving root canal disinfection [222]. Two *in vitro* studies by the same team showed that chitosan nanoparticles can be delivered into the anatomic complexities and dentinal tubules to enhance root canal disinfection and retained their antibacterial properties after aging for 90 days [223,224]. Chitosan nanoparticles can also be used as delivery systems for bioactive molecules (e.g., bovine serum albumin, dexamethasone and transforming growth factor- β 1) and have the potential to provide effective, sustained release of those molecules to promote the migration, differentiation and alkaline phosphatase activity of SCAPs [157–159]. Recent advances in nanotechnology have revolutionized design strategies of biomaterial scaffolds for endodontic regeneration. Nanotechnology-based design can mimic mechanical, chemical and biological properties of native tissues and promote the temporal and spatial control of various biological processes [228–230]. For example, a hierarchical growth factor-loaded nanofibrous PLLA microsphere scaffolding system with a highly porous injectable form was designed, synthesized and demonstrated to control the sustained release of VEGF and efficiently support the proliferation of DPSCs. Pulp-like tissue regeneration in a full-length root canal was achieved for the first time [230]. Collectively, the results of abovementioned studies suggest that the future perspective of nanotechnology in endodontic regeneration seems promising. Future studies are warranted to investigate the clinical and *in vivo* application of nanotechnology in the clinical procedure of endodontic regeneration.

Clinical trials on cell-based regenerative endodontic therapy have shown the potential of these procedures in regenerating the pulp–dentin complex [38–40]. In the study by Xuan et al., autologous DPSCs aggregates derived from primary teeth were implanted into traumatized immature permanent teeth with pulp necrosis and apical periodontitis after root canal disinfection and the formation of an intracanal blood clot by induction of apical bleeding [39]. After a 24-month follow-up, histological examination of one extracted tooth with unresorable crown-root fracture showed that the newly formed soft tissue in the canal appeared to be dental pulp tissue. This tissue contained a characteristic odontoblast layer, blood vessels and nerves. The potential of employing biomaterial scaffolds and stem cells simultaneously may shed light on a new trend to create cohesive tissue constructs. An example of these constructs is cell spheroid-laden 3D biodegradable scaffolds that

are synthesized using state-of-the-art bioprinting technology [231].

Translation of basic science into clinical practice is essential for rendering REPs more predictable. The current focus has been concentrated on direct clinical manipulation of cell-free regenerative endodontic therapy and the evaluation of a variety of biomaterial scaffolds. Over the last decade, a plethora of randomized controlled trials on REPs have been performed on evaluation or comparison of the different biomaterial scaffolds, including blood clot, collagen, PRP, PRF, PPP, PP, hydrogels, chitosan, and PLGA [28,31,40,88,89,93,128,186,232–241] (Table 2). However, there is no sufficient evidence of a high level that compares the clinical outcome regarding the application of these biomaterial scaffolds in REPs. A systematic review and meta-analysis study was conducted to quantitatively assess the effect of various biomaterial scaffolds on the clinical outcomes of regenerative endodontic procedures in necrotic immature permanent teeth [242]. Sixteen studies were included, and the overall risk of bias in these studies was moderate. Evidence of moderate quality showed no significant difference between blood clot and PRP in the healing of apical lesions and the continued development of the root, such as apical closure and the increase of root length. PRP and PRF are equally effective in the healing of apical lesions, an increase of root length and apical closure. Blood clot performs better than PRP in promoting healing of the peri-apical lesion. However, it is still difficult to make a direct comparison of other biomaterial scaffolds (i.e., collagen, PPP, PP, hydrogels, chitosan and PLGA) because of the small case sample and wide variation in the case selection, clinical procedure and case assessment in those studies. Further studies conducted under the standardization of all variables are needed to make a more compelling conclusion regarding the clinical performance of biomaterial scaffolds in REPs. Based on the current best available evidence, cell-free procedures appear to be viable treatment options for necrotic teeth with or without open apices. However, for standardization of the protocols involved in cell-free regenerative endodontic therapy, well-designed randomized controlled trials with long-term follow-ups are required to provide supportive and confirmatory evidence. Although proof-of-concept of cell-based regenerative endodontic therapy in the regeneration of the pulp-dentin complex has been established in animal studies with histological analyses, very few studies have reported the clinical outcomes of this procedure [243–245]. Consequently, more studies are needed to validate the outcomes and predictability of cell-based regenerative endodontic therapy in the clinical setting for predictable regeneration of the pulp-dentin complex.

To sum up, a variety of types of biomaterials have been extensively investigated and applied for the construction of scaffolds in regenerative endodontic procedures. However, a candidate that possesses all favorable properties required for the fabrication of an ideal scaffold that can successfully support and guide the complete regeneration of the pulp-dentin complex remains to be identified. The introduction of biomaterials that has been successfully used in tissue engineering to regenerative endodontics may hold promise, whereas the combination of complex biomaterials can also pave the road to provide potential source for scaffolding. Besides, no conventional method can be used to construct biomaterial scaffolds that completely mimic the 3D architectures of the pulp-dentin complex. With the rapid development of 3D bioprinting technology and nanotechnology, the precise manufacture of various biomaterials with desired structure and the construction of scaffolds that resemble the intricate structure of targeted tissue may stimulate progress in the development of strategies that facilitate the transition of regenerative endodontic from lab bench to chairside practice.

CRediT authorship contribution statement

He Liu: Writing – original draft, Visualization. **Jing Lu:** Visualization. **Qianzhou Jiang:** Review. **Markus Haapasalo:** Review. **Junrong Qian:** Conceptualization, Resourcing. **Franklin R. Tay:** Writing – review & editing. **Ya Shen:** Writing – review & editing.

Table 2
Summary of the results reported by randomized controlled trials on the application of biomaterial scaffolds in regenerative endodontic procedures.

Study	Biomaterial scaffold	Procedure	Group	Patient	Tooth	Follow-up	Outcome
Jiang et al. [232], 2021	Pure collagen membrane (Bio-Gide; Geistlich Pharma AG, Wolhusen, Switzerland) or blood clot	Cell-free	Group 1: blood clot Group 2: Bio-Gide	71 patients (mean age: 10.6 ± 1.7 y for group 1 and 11.0 ± 1.9 y for group 2)	76 immature teeth with necrotic pulp	Group 1: 33.1 ± 21.8 months Group 2: 28.1 ± 18.6 months	All patients from both groups showed clinical success. Radiographic examination revealed thicker dentin wall at the middle third of the root for the Bio-Gide group.
El- Kateb et al. [186], 2020	Blood clot	Cell-free	Group 1: ADS, 0.3 mm Group 2: ADS, 0.5 mm	18 patients (age range: 20–34 y)	18 mature teeth with necrotic pulp and apical lesions	12 months	Clinical and radiographic examinations showed favorable and similar results in both groups. MRI examination showed signal intensity.
Brizuela et al. [40], 2020	PPP encapsulating human UC-MSCs	Cell-based	Group 1: REPs Group 2: NSRCT	36 patients (age range: 16–58 y)	36 mature teeth with necrotic pulp and apical lesions	12 months	Both groups achieved favorable and similar clinical and radiographic healing. The thermal test results of REPs were better than that of NSRCT group.
ElSheshtawy et al. [233], 2020	PRP or blood clot	Cell-free	Group 1: PRP Group 2: blood clot	26 patients (average age: 12.6 ± 4.9 y for group 1 and 12.7 ± 4.0 y for group 2)	31 immature teeth with necrotic pulp	12-month	Clinical and radiographic examinations showed successful and comparable outcomes between the PRP group and the blood clot group.
Arslan et al. [31], 2019	Blood clot	Cell-free	Group 1: REPs Group 2: NSRCT	46 patients (age range: 18–30 y)	46 mature teeth with necrotic pulp and apical lesions	12-month	REPs achieved favorable and similar clinical and radiographic results as that of NSRCT.
Ulusoy et al. [93], 2019	PRP, PRF, PP or blood clot	Cell-free	Group 1: PRP Group 2: PRF Group 3: PP Group 4: blood clot	65 patients (age range: 8–11 y)	73 immature teeth with necrotic pulp	10–49 months	PRP, PRF and PP achieved similar clinical and radiographic outcomes to blood clot and showed significantly less tendency for root canal obliteration.
Rizk et al. [234], 2019	PRP or blood clot	Cell-free	Group 1: PRP Group 2: blood clot	13 patients (age range: 8–14 y)	26 immature teeth with necrotic pulp	12 months	All teeth from both groups achieved clinical success. Compared to blood clot group, the PRP group showed better radiographic outcomes in terms of increase in root length, width, and reduction of the width of the apical foramen.
Jha et al. [235], 2019	Blood clot	Cell-free	Group 1: REPs Group 2: NSRCT	30 patients (age range: 9–15 y)	30 mature teeth with necrotic pulp and apical lesions	18 months	Clinical and radiographic examinations showed favorable and similar results in both groups.
Santhakumar et al. [236], 2018	PRF gel or PRF membrane	Cell-free	Group 1: PRF gel Group 2: PRF membrane	40 patients (age range: 7–12y)	40 mature teeth with necrotic pulp and apical lesions	12 months	All teeth from both groups achieved comparable clinical success. However, the PRF gel group revealed better radiographic outcome.
Jiang et al. [128], 2017	Bio-Gide or blood clot	Cell-free	Group 1: blood clot Group 2: Bio-Gide	40 patients (mean age: 9.8 ± 1.5 y for group 1 and 10.3 ± 1.9 y for group 2)	43 immature teeth with necrotic pulp	Group 1: 16.1 ± 8.8 months Group 2: 15.0 ± 5.8 months	Clinical examination showed both groups had favorable and comparable results. The Bio-Gide group showed greater increase in dentin wall thickness in the middle-third of the root.
Lin et al. [28], 2017	Blood clot	Cell-free	Group 1: REPs Group 2: Apexification	103 patients (age range: 8–16 y)	103 immature teeth with necrotic pulp and apical lesions	12 months	Both groups achieved comparable clinical outcomes. REPs showed better results than apexification in radiographic evaluation, such as increased root thickness and root length.
Alagl et al. [237], 2017	PRP or blood clot	Cell-free	Group 1: PRP Group 2: blood clot	15 patients (age range: 8–11 y)	30 immature teeth with necrotic pulp	12 months	Apart from a significant increase in root length, the clinical and radiographic outcomes of REPs group were similar to those of the blood clot group.
	PRP, PRF or blood clot	Cell-free	Group 1: PRP				

(continued on next page)

Table 2 (continued)

Study	Biomaterial scaffold	Procedure	Group	Patient	Tooth	Follow-up	Outcome
Shivashankar et al. [238], 2017			Group 2: PRF Group 3: blood clot	60 patients (age range: 6–28 y)	60 immature teeth with necrotic pulp	12 months	PRP-treated teeth were associated with better periapical healing than teeth treated with PRF or blood clot. All groups achieved comparable radiographic results in terms of root lengthening and thickening.
Sharma et al. [239], 2016	PRF, collagen sponge (Cologenes Healthcare Pvt. Ltd., India), PLGA crystals (MilliporeSigma, Burlington, MA, USA) or blood clot	Cell-free	Group 1: PRF Group 2: collagen Group 3: PLGA Group 4: blood clot	16 patients (age range: 10–25 y)	16 immature teeth with necrotic pulp	12 months	PRF and collagen groups achieved better results than other groups in terms of periapical healing, apical closure, and dentinal wall thickening.
Bezgin et al. [89], 2015	PRP or blood clot	Cell-free	Group 1: PRP Group 2: blood clot	18 patients (age range: 7–12 y)	20 immature teeth with necrotic pulp and apical lesions	18 months	Clinical and radiographic examinations showed favorable and similar results in both groups.
Narang et al. [240], 2015	PRP, PRF or blood clot	Cell-free	Group 1: MTA apexification Group 2: blood clot Group 3: PRF Group 4: PRP	20 patients (age range: <20 y)	20 immature teeth with necrotic pulp	18 months	The PRF group showed better radiographic results in terms of periapical healing, root height and dentinal wall thickening.
Nagy et al. [241], 2014	A hydrogel scaffold or blood clot	Cell-free	Group 1: MTA apical plug Group 2: REPs using blood clot as a scaffold Group 3: REPs using an injectable hydrogel scaffold impregnated with basic fibroblast growth factor	36 patients (age range: 9–13 y)	36 immature teeth with necrotic pulp	18 months	REP groups showed comparable clinical and radiographic outcomes in terms of increase in root length, thickness, and decrease in apical foramen width.
Jadhav et al. [88], 2012	PRP or blood clot	Cell-free	Group 1: PRP Group 2: blood clot	20 patients (age range: 15–28 y)	20 immature teeth with necrotic pulp	12 months	All patients from both groups achieved clinical success. The PRP group had better radiographic evidence periapical healing, apical closure and root thickening. Root height was comparable for both groups.

ADS, apical diameter size; MRI, magnetic resonance imaging; PPP, Platelet-poor plasma; UC-MSCs, umbilical cord mesenchymal stem cells; REPs, regenerative endodontic procedures; NSRCT, nonsurgical root canal treatment; PRP, Platelet-rich plasma; PRF, platelet rich fibrin; PP, platelet pellet; PLGA, poly-lactic-co-glycolic acid; MTA, mineral trioxide aggregate.

Declaration of competing interest

The authors declare no conflicts of interest.

References

- [1] M.A. Peres, L.M.D. Macpherson, R.J. Weyant, B. Daly, R. Venturelli, M.R. Mathur, S. Listl, R.K. Celeste, C.C. Guarnizo-Herreño, C. Kearns, H. Benzian, P. Allison, R. G. Watt, Oral diseases: a global public health challenge, *Lancet* 394 (2019) 249–260.
- [2] GBD 2017 Disease and Injury Incidence and Prevalence Collaborators, Global, regional, and national incidence, prevalence, and years lived with disability for 354 diseases and injuries for 195 countries and territories, 1990–2017: a systematic analysis for the Global Burden of Disease Study 2017, *Lancet* 392 (2018) 1789–1858.
- [3] S. Petti, U. Glendor, L. Andersson, World traumatic dental injury prevalence and incidence, a meta-analysis-One billion living people have had traumatic dental injuries, *Dent. Traumatol.* 34 (2018) 71–86.
- [4] D.T. Zero, A.F. Zandona, M.M. Vail, K.J. Spolnik, Dental caries and pulpal disease, *Dent. Clin.* 55 (2011) 29–46.
- [5] A. Robertson, F.M. Andreasen, G. Bergholtz, J.O. Andreasen, J.G. Norén, Incidence of pulp necrosis subsequent to pulp canal obliteration from trauma of permanent incisors, *J. Endod.* 22 (1996) 557–560.
- [6] J.O. Andreasen, B. Farik, E.C. Munksgaard, Long-term calcium hydroxide as a root canal dressing may increase risk of root fracture, *Dent. Traumatol.* 18 (2020) 134–137.
- [7] A.M. Elnaghy, S.E. Elsaka, Fracture resistance of simulated immature teeth filled with Biodentine and white mineral trioxide aggregate: an in vitro study, *Dent. Traumatol.* 32 (2016) 116–120.
- [8] M. Rafter, Apexification: a review, *Dent. Traumatol.* 21 (2005) 1–8.
- [9] K. Vidal, G. Martin, O. Lozano, M. Salas, J. Trigueros, G. Aguilar, Apical Closure in Apexification: a review and case report of apexification treatment of an immature permanent tooth with Biodentine, *J. Endod.* 42 (2016) 730–734.
- [10] S.G. Kim, M. Malek, A. Sigurdsson, L.M. Lin, B. Kahler, Regenerative endodontics: a comprehensive review, *Int. Endod. J.* 51 (2018) 1367–1388.
- [11] G.T. Huang, Pulp and dentin tissue engineering and regeneration: current progress, *Regen. Med* 4 (2009) 697–707.
- [12] J. Li, C. Parada, Y. Chai, Cellular and molecular mechanisms of tooth root development, *Development* 144 (2017) 374–384.
- [13] T. Jeeruphan, J. Jantararat, K. Yanpiset, L. Suwannapan, P. Khewsawai, K. M. Hargreaves, Mahidol study 1: comparison of radiographic and survival outcomes of immature teeth treated with either regenerative endodontic or apexification methods: a retrospective study, *J. Endod.* 38 (2012) 1330–1336.
- [14] J. Silujjai, P. Linsuwanont, Treatment outcomes of apexification or revascularization in nonvital immature permanent teeth: a retrospective study, *J. Endod.* 43 (2017) 238–245.
- [15] P.L. Judd, M.J. Casas, Psychosocial perceptions of premature tooth loss in children, *Ont. Dent.* 72 (1995) 22–23, 16–8, 20.
- [16] K.M. Hargreaves, A. Diogenes, F.B. Teixeira, Treatment options: biological basis of regenerative endodontic procedures, *J. Endod.* 39 (2013) S30–S43.
- [17] L.M. Lin, D. Ricucci, G.T. Huang, Regeneration of the dentine-pulp complex with revitalization/revascularization therapy: challenges and hopes, *Int. Endod. J.* 47 (2014) 713–724.
- [18] A. Diogenes, N.B. Ruparel, Y. Shiloah, K.M. Hargreaves, Regenerative endodontics: a way forward, *J. Am. Dent. Assoc.* 147 (2016) 372–380.
- [19] A.J. Smith, H.F. Duncan, A. Diogenes, S. Simon, P.R. Cooper, Exploiting the bioactive properties of the dentin-pulp complex in regenerative endodontics, *J. Endod.* 42 (2016) 47–56.

- [20] L.M. Lin, G.T. Huang, A. Sigurdsson, B. Kahler, Clinical cell-based versus cell-free regenerative endodontics: clarification of concept and term, *Int. Endod. J.* 54 (2021) 887–901.
- [21] S.I. Iwaya, M. Ikawa, M. Kubota, Revascularization of an immature permanent tooth with apical periodontitis and sinus tract, *Dent. Traumatol.* 17 (2001) 185–187.
- [22] N. Shah, A. Logani, U. Bhaskar, V. Aggarwal, Efficacy of revascularization to induce apexification/apexogenesis in infected, nonvital, immature teeth: a pilot clinical study, *J. Endod.* 34 (2008) 919–925.
- [23] S. Simon, A.J. Smith, Regenerative endodontics, *Br. Dent. J.* 216 (2014) E13.
- [24] B. Kahler, S. Mistry, A. Moule, A.K. Ringsmuth, P. Case, A. Thomson, T. Holcombe, Revascularization outcomes: a prospective analysis of 16 consecutive cases, *J. Endod.* 40 (2014) 333–338.
- [25] S. Bukhari, M.R. Kohli, F. Setzer, B. Karabucak, Outcome of revascularization procedure: a retrospective case series, *J. Endod.* 42 (2016) 1752–1759.
- [26] L. Li, Y. Pan, L. Mei, J. Li, Clinical and radiographic outcomes in immature permanent necrotic evaginated teeth treated with regenerative endodontic procedures, *J. Endod.* 43 (2017) 246–251.
- [27] E.K. Chan, M. Desmeules, M. Cielecki, B. Dabbagh, B. Ferraz Dos Santos, Longitudinal cohort study of regenerative endodontic treatment for immature necrotic permanent teeth, *J. Endod.* 43 (2017) 395–400.
- [28] J. Lin, Q. Zeng, X. Wei, W. Zhao, M. Cui, J. Gu, J. Lu, M. Yang, J. Ling, Regenerative endodontics versus apexification in immature permanent teeth with apical periodontitis: a prospective randomized controlled study, *J. Endod.* 43 (2017) 1821–1827.
- [29] V. Chrepa, R. Joon, O. Austah, A. Diogenes, K.M. Hargreaves, M. Ezeldeen, N. B. Ruparel, Clinical outcomes of immature teeth treated with regenerative endodontic procedures: a San Antonio study, *J. Endod.* 46 (2020) 1074–1084.
- [30] L. He, S.G. Kim, Q. Gong, J. Zhong, S. Wang, X. Zhou, L. Ye, J. Ling, J.J. Mao, Regenerative endodontics for adult patients, *J. Endod.* 43 (2017) S57–S64.
- [31] H. Arslan, H.M.A. Ahmed, Y. Şahin, E. Doganay Yıldız, E.C. Gündoğdu, Y. Güven, R. Khalilov, Regenerative endodontic procedures in necrotic mature teeth with periapical radiolucencies: a preliminary randomized clinical study, *J. Endod.* 45 (2019) 863–872.
- [32] A. Glynis, F. Foschi, I. Kefalou, D. Koletsis, G.N. Tzanetakis, Regenerative endodontic procedures for the treatment of necrotic mature teeth with apical periodontitis: a systematic review and meta-analysis of randomized controlled trials, *J. Endod.* 47 (2021) 873–882.
- [33] T.M. Saoud, S. Mistry, B. Kahler, A. Sigurdsson, L.M. Lin, Regenerative endodontic procedures for traumatized teeth after horizontal root fracture, avulsion, and perforating root resorption, *J. Endod.* 42 (2016) 1476–1482.
- [34] A. Chaniotis, The use of a single-step regenerative approach for the treatment of a replanted mandibular central incisor with severe resorption, *Int. Endod. J.* 49 (2016) 802–812.
- [35] G.N. Tzanetakis, Management of intruded immature maxillary central incisor with pulp necrosis and severe external resorption by regenerative approach, *J. Endod.* 44 (2018) 245–249.
- [36] M. Yoshpe, S. Einy, N. Ruparel, S. Lin, A.Y. Kaufman, Regenerative endodontics: a potential solution for external root resorption (case Series), *J. Endod.* 46 (2020) 192–199.
- [37] J. Lu, H. Liu, Z. Lu, B. Kahler, L.M. Lin, Regenerative endodontic procedures for traumatized immature permanent teeth with severe external root resorption and root perforation, *J. Endod.* 46 (2020) 1610–1615.
- [38] M. Nakashima, K. Iohara, M. Murakami, H. Nakamura, Y. Sato, Y. Arijii, K. Matsushita, Pulp regeneration by transplantation of dental pulp stem cells in pulpitis: A pilot clinical study, *Stem. Cell. Res. Ther.* 1 (2017) 61.
- [39] K. Xuan, B. Li, H. Guo, W. Sun, X. Kou, X. He, Y. Zhang, J. Sun, A. Liu, L. Liao, S. Liu, W. Liu, C. Hu, S. Shi, Y. Jin, Deciduous autologous tooth stem cells regenerate dental pulp after implantation into injured teeth, *Sci. Transl. Med.* 22 (2018) 3227.
- [40] C. Brizuela, G. Meza, D. Urrejola, M.A. Quezada, G. Concha, V. Ramírez, I. Angelopoulos, M.I. Cadiz, R. Tapia-Limonchi, M. Khoury, Cell-based regenerative endodontics for treatment of periapical lesions: a randomized, controlled phase I/II clinical trial, *J. Dent. Res.* 5 (2020) 523–529.
- [41] F.J. O'Brien, Biomaterials & scaffolds for tissue engineering, *Mater. Today* 14 (2011) 88–95.
- [42] W.L. Dissanayaka, C. Zhang, Scaffold-based and scaffold-free strategies in dental pulp regeneration, *J. Endod.* 46 (2020) S81–S89.
- [43] G. Raddall, I. Mello, B.M. Leung, Biomaterials and scaffold design strategies for regenerative endodontic therapy, *Front. Bioeng. Biotechnol.* 7 (2019) 317.
- [44] K.M. Gathani, S.S. Raghavendra, Scaffolds in regenerative endodontics: a review, *Dent. Res. J.* 5 (2016) 379–386.
- [45] K.M. Galler, F.P. Brandl, S. Kirchhof, M. Widbill, A. Eidt, W. Buchalla, A. Göpferich, G. Schmalz, Suitability of different natural and synthetic biomaterials for dental pulp tissue engineering, *Tissue Eng. Part A* 24 (2018) 234–244.
- [46] L.H. Berman, K.M. Hargreaves, *Cohen's Pathways of the Pulp Expert Consult*, twelfth ed., Elsevier, Missouri, 2020.
- [47] K.M. Hargreaves, A. Diogenes, F.B. Teixeira, Paradigm lost: a perspective on the design and interpretation of regenerative endodontic research, *J. Endod.* 40 (2014) S65–S69.
- [48] M. Altai, L. Richards, G. Rossi-Fedele, Histological assessment of regenerative endodontic treatment in animal studies with different scaffolds: a systematic review, *Dent. Traumatol.* 33 (2017) 235–244.
- [49] American Association of Endodontists, *Clinical Considerations for a Regenerative Procedure*, Online, 2018, https://www.aae.org/uploadedfiles/publications_and_research/research/currentregenerativeendodonticconsiderations.pdf.
- [50] T. Velnar, T. Bailey, V. Smrkolj, The wound healing process: an overview of the cellular and molecular mechanisms, *J. Int. Med. Res.* 37 (2009) 1528–1542.
- [51] K.M. Galler, G. Krastl, S. Simon, G. Van Gorp, N. Meschi, B. Vahedi, P. Lambrechts, European society of endodontology position statement: revitalization procedures, *Int. Endod. J.* 49 (2016) 717–723.
- [52] J.Y. Lee, D.D. Kersten, P. Mines, T.A. Beltran, Regenerative endodontic procedures among endodontists: a web-based survey, *J. Endod.* 44 (2018) 250–255.
- [53] B. Nygaard-Ostby, The role of the blood clot in endodontic therapy: an experimental histological study, *Acta Odontol. Scand.* 19 (1961) 324–353.
- [54] B. Nygaard-Ostby, O. Hjortdal, Tissue formation in the root canal following pulp removal, *Scand. J. Dent. Res.* 79 (1971) 333–349.
- [55] W.T. Johnson, J.L. Goodrich, G.A. James, Replantation of avulsed teeth with immature root development, *Oral Surg. Oral Med. Oral Pathol.* 60 (1985) 420–427.
- [56] M. Kling, M. Cvek, I. Mejare, Rate and predictability of pulp revascularization in therapeutically reimplanted permanent incisors, *Endod. Dent. Traumatol.* 2 (1986) 83–89.
- [57] J.O. Andreasen, M.K. Borum, H.L. Jacobsen, F.M. Andreasen, Replantation of 400 avulsed permanent incisors. 1. Diagnosis of healing complications, *Endod. Dent. Traumatol.* 11 (1995) 51–58.
- [58] J.O. Andreasen, M.K. Borum, H.L. Jacobsen, F.M. Andreasen, Replantation of 400 avulsed permanent incisors. 2. Factors related to pulpal healing, *Endod. Dent. Traumatol.* 11 (1995) 59–68.
- [59] J.O. Andreasen, M.K. Borum, F.M. Andreasen, Replantation of 400 avulsed permanent incisors. 3. Factors related to root growth, *Endod. Dent. Traumatol.* 11 (1995) 69–75.
- [60] J.O. Andreasen, M.K. Borum, H.L. Jacobsen, F.M. Andreasen, Replantation of 400 avulsed permanent incisors. 4. Factors related to periodontal ligament healing, *Endod. Dent. Traumatol.* 11 (1995) 76–89.
- [61] F. Banchs, M. Trope, Revascularization of immature permanent teeth with apical periodontitis: new treatment protocol? *J. Endod.* 30 (2004) 196–200.
- [62] H.J. Tong, S. Rajan, N. Bhujel, J. Kang, M. Duggal, H. Nazzal, Regenerative endodontic therapy in the management of nonvital immature permanent teeth: a systematic review-outcome evaluation and meta-analysis, *J. Endod.* 43 (2017) 1453–1464.
- [63] T.K. Ong, G.S. Lim, M. Singh, A.V. Fial, Quantitative assessment of root development after regenerative endodontic therapy: a systematic review and meta-analysis, *J. Endod.* 46 (2020) 1856–1866.
- [64] A. Glynis, F. Foschi, I. Kefalou, D. Koletsis, G.N. Tzanetakis, Regenerative endodontic procedures for the treatment of necrotic mature teeth with apical periodontitis: a systematic review and meta-analysis of randomized controlled trials, *J. Endod.* 47 (2021) 873–882.
- [65] P. Becerra, D. Ricucci, S. Loghin, J.L. Gibbs, L.M. Lin, Histological study of a human immature permanent premolar with chronic apical abscess after revascularization/revitalization, *J. Endod.* 40 (2014) 133–139.
- [66] E. Shimizu, D. Ricucci, J. Albert, A.S. Alobaid, J.L. Gibbs, G.T. Huang, L.M. Lin, Clinical, radiographic, and histological observation of a human immature permanent tooth with chronic apical abscess after revitalization treatment, *J. Endod.* 39 (2013) 1078–1083.
- [67] J.N. Lui, W.Y. Lim, D. Ricucci, An immunofluorescence study to analyze wound healing outcomes of regenerative endodontics in an immature premolar with chronic apical abscess, *J. Endod.* 46 (2020) 627–640.
- [68] T.W. Lovelace, M.A. Henry, K.M. Hargreaves, A. Diogenes, Evaluation of the delivery of mesenchymal stem cells into the root canal space of necrotic immature teeth after clinical regenerative endodontic procedure, *J. Endod.* 37 (2011) 133–138.
- [69] N.B. Ruparel, F.B. Teixeira, C.C. Ferraz, A. Diogenes, Direct effect of intracanal medicaments on survival of stem cells of the apical papilla, *J. Endod.* 38 (2012) 1372–1375.
- [70] P. Verma, A. Nosrat, J.R. Kim, J.B. Price, P. Wang, E. Bair, H.H. Xu, A.F. Fouad, Effect of residual bacteria on the outcome of pulp regeneration in vivo, *J. Dent. Res.* 96 (2017) 100–106.
- [71] R.I. Althumairy, F.B. Teixeira, A. Diogenes, Effect of dentin conditioning with intracanal medicaments on survival of stem cells of apical papilla, *J. Endod.* 40 (2014) 521–525.
- [72] Q. Zeng, S. Nguyen, H. Zhang, H.P. Chebrolu, D. Alzebeid, M.A. Badi, J.R. Kim, J. Ling, M. Yang, Release of growth factors into root canal by irrigations in regenerative endodontics, *J. Endod.* 42 (2016) 1760–1766.
- [73] P. Taweewattanapaisan, J. Jantarat, P. Ounjai, K. Janebodin, The effects of EDTA on blood blot in regenerative endodontic procedures, *J. Endod.* 45 (2019) 281–286.
- [74] A. Timmerman, P. Parashos, Delayed root development by displaced mineral trioxide aggregate after regenerative endodontics: a case report, *J. Endod.* 43 (2017) 252–256.
- [75] A.J. Nevins, J.J. Cymerman, Revitalization of open apex teeth with apical periodontitis using a collagen-hydroxyapatite scaffold, *J. Endod.* 41 (2015) 966–973.
- [76] M. Rodrigues, N. Kosaric, C.A. Bonham, G.C. Gurtner, Wound healing: a cellular perspective, *Physiol. Rev.* 99 (2019) 665–706.
- [77] M. Gawaz, S. Vogel, Platelets in tissue repair: control of apoptosis and interactions with regenerative cells, *Blood* 122 (2013) 2550–2554.

- [78] E. Anitua, P. Nurdén, R. Prado, A.T. Nurdén, S. Padilla, Autologous fibrin scaffolds: when platelet- and plasma-derived biomolecules meet fibrin, *Biomaterials* 192 (2019) 440–460.
- [79] E. Cenni, D. Granchi, M. Vancini, A. Pizzoferrato, Platelet release of transforming growth factor-beta and beta-thromboglobulin after in vitro contact with acrylic bone cements, *Biomaterials* 23 (2002) 1479–1484.
- [80] D.M. Dohan Ehrenfest, L. Rasmusson, T. Albrektsson, Classification of platelet concentrates: from pure platelet-rich plasma (P-PRP) to leukocyte- and platelet-rich fibrin (L-PRF), *Trends Biotechnol.* 27 (2009) 158–167.
- [81] J. Qiao, N. An, X. Ouyang, Quantification of growth factors in different platelet concentrates, *Platelets* 28 (2017) 774–778.
- [82] A. Riaz, F.A. Shah, Regenerating the pulp-dentine complex using autologous platelet concentrates: a critical appraisal of the current histological evidence, *Tissue Eng. Regen. Med.* 18 (2021) 37–48.
- [83] L. Wang, Y. Zhao, S. Shi, Interplay between mesenchymal stem cells and lymphocytes: implications for immunotherapy and tissue regeneration, *J. Dent. Res.* 91 (2012) 1003–1010.
- [84] N. Meschi, A.B. Castro, K. Vandamme, M. Quiryne, P. Lambrechts, The impact of autologous platelet concentrates on endodontic healing: a systematic review, *Platelets* 27 (2016) 613–633.
- [85] K.H. Yeom, W. Ariyoshi, T. Okinaga, A. Washio, T. Morotomi, C. Kitamura, T. Nishihara, Platelet-rich plasma enhances the differentiation of dental pulp progenitor cells into odontoblasts, *Int. Endod. J.* 49 (2016) 271–278.
- [86] K.M. Hargreaves, T. Giesler, M. Henry, Y. Wang, Regeneration potential of the young permanent tooth: what does the future hold? *J. Endod.* 34 (2008) S51–S56.
- [87] M. Torabinejad, M. Turman, Revitalization of tooth with necrotic pulp and open apex by using platelet-rich plasma: a case report, *J. Endod.* 37 (2011) 265–268.
- [88] G. Jadhav, N. Shah, A. Logani, Revascularization with and without platelet-rich plasma in nonvital, immature, anterior teeth: a pilot clinical study, *J. Endod.* 38 (2012) 1581–1587.
- [89] T. Bezgin, A.D. Yilmaz, B.N. Celik, M.E. Kolsuz, H. Sonmez, Efficacy of platelet-rich plasma as a scaffold in regenerative endodontic treatment, *J. Endod.* 41 (2015) 36–44.
- [90] G.S. Sachdeva, L.T. Sachdeva, M. Goel, S. Bala, Regenerative endodontic treatment of an immature tooth with a necrotic pulp and apical periodontitis using platelet-rich plasma (PRP) and mineral trioxide aggregate (MTA): a case report, *Int. Endod. J.* 48 (2015) 902–910.
- [91] A. Lolato, C. Bucchi, S. Taschieri, A.E. Kabbaney, M.D. Fabbro, Platelet concentrates for revitalization of immature necrotic teeth: a systematic review of the clinical studies, *Platelets* 27 (2016) 383–392.
- [92] J.F. Gaviño Orduña, J. Caviades-Bucheli, M.C. Manzanares Céspedes, E. Berástegui Jimeno, B. Martín Biedma, J.J. Segura-Egea, J. López-López, Use of platelet-rich plasma in endodontic procedures in adults: regeneration or repair? a report of 3 cases with 5 years of follow-up, *J. Endod.* 43 (2017) 1294–1301.
- [93] A.T. Ulusoy, I. Turedi, M. Cimen, Z.C. Cehreli, Evaluation of blood clot, platelet-rich plasma, platelet-rich fibrin, and platelet pellet as scaffolds in regenerative endodontic treatment: a prospective randomized trial, *J. Endod.* 45 (2019) 560–566.
- [94] D.D. Zhang, X. Chen, Z.F. Bao, M. Chen, Z.J. Ding, M. Zhong, Histological comparison between platelet-rich plasma and blood clot in regenerative endodontic treatment: an animal study, *J. Endod.* 40 (2014) 1388–1393.
- [95] W. Zhu, X. Zhu, G.T. Huang, G.S. Cheung, W.L. Dissanayaka, C. Zhang, Regeneration of dental pulp tissue in immature teeth with apical periodontitis using platelet-rich plasma and dental pulp cells, *Int. Endod. J.* 46 (2013) 962–970.
- [96] M. Del Fabbro, A. Lolato, C. Bucchi, S. Taschieri, R.L. Weinstein, Autologous platelet concentrates for pulp and dentin regeneration: a literature review of animal studies, *J. Endod.* 42 (2016) 250–257.
- [97] M. Altaii, P. Cathro, M. Broberg, L. Richards, Endodontic regeneration and tooth revitalization in immature infected sheep teeth, *Int. Endod. J.* 50 (2017) 480–491.
- [98] D.M. Dohan, J. Choukroun, A. Diss, S.L. Dohan, A.J. Dohan, J. Mouhyi, B. Gogly, Platelet-rich fibrin (PRF): a second-generation platelet concentrate. Part I: technological concepts and evolution, *Oral Surg. Oral Med. Oral Pathol. Oral Radiol. Endod.* 101 (2006) e37–44.
- [99] S. Hong, W. Chen, B. Jiang, A comparative evaluation of concentrated growth factor and platelet-rich fibrin on the proliferation, migration, and differentiation of human stem cells of the apical papilla, *J. Endod.* 44 (2018) 977–983.
- [100] L. He, Y. Lin, X. Hu, Y. Zhang, H. Wu, A comparative study of platelet-rich fibrin (PRF) and platelet-rich plasma (PRP) on the effect of proliferation and differentiation of rat osteoblasts in vitro, *Oral Surg. Oral Med. Oral Pathol. Oral Radiol. Endod.* 108 (2009) 707–713.
- [101] M.O. Schär, J. Diaz-Romero, S. Kohl, M.A. Zumstein, D. Nestic, Platelet-rich concentrates differentially release growth factors and induce cell migration in vitro, *Clin. Orthop. Relat. Res.* 473 (2015) 1635–1643.
- [102] J. Bi, Y. Liu, X.M. Liu, S. Lei, X. Chen, Platelet-rich fibrin improves the osteo-/odontogenic differentiation of stem cells from apical papilla via the extracellular signal-regulated protein kinase signaling pathway, *J. Endod.* 46 (2020) 648–654.
- [103] D. Keswani, R.K. Pandey, Revascularization of an immature tooth with a necrotic pulp using platelet-rich fibrin: a case report, *Int. Endod. J.* 46 (2013) 1096–1104.
- [104] H.L. Ray Jr., J. Marcelino, R. Braga, R. Horwat, M. Lisien, S. Khaliq, Long-term follow up of revascularization using platelet-rich fibrin, *Dent. Traumatol.* 32 (2016) 80–84.
- [105] H. Bakhtiar, S. Esmaeili, S. Fakhri Tabatabayi, M.R. Ellini, M.H. Nekoofar, P. M. Dummer, Second-generation platelet concentrate (platelet-rich fibrin) as a scaffold in regenerative endodontics: a case series, *J. Endod.* 43 (2017) 401–408.
- [106] N. Pinto, A. Harnish, C. Cabrera, C. Andrade, T. Druttman, C. Brizuela, An innovative regenerative endodontic procedure using leukocyte and platelet-rich fibrin associated with apical surgery: a case report, *J. Endod.* 43 (2017) 1828–1834.
- [107] M. Yoshpe, A.Y. Kaufman, S. Lin, M. Ashkenazi, Regenerative endodontics: a promising tool to promote periapical healing and root maturation of necrotic immature permanent molars with apical periodontitis using platelet-rich fibrin (PRF), *Eur. Arch. Paediatr. Dent.* 22 (2021) 527–534.
- [108] H. Lv, Y. Chen, Z. Cai, L. Lei, M. Zhang, R. Zhou, X. Huang, The efficacy of platelet-rich fibrin as a scaffold in regenerative endodontic treatment: a retrospective controlled cohort study, *BMC Oral Health* 18 (2018) 139–146.
- [109] R. Zhou, Y. Wang, Y. Chen, S. Chen, H. Lv, Z. Cai, X. Huang, Radiographic, histological, and biomechanical evaluation of combined application of platelet-rich fibrin with blood clot in regenerative endodontics, *J. Endod.* 43 (2017) 2034–2040.
- [110] H.D. Adhikari, A. Gupta, Report of a case of platelet-rich fibrin mediated revascularization of immature teeth with histopathological evaluation, *J. Conserv. Dent.* 21 (2018) 691–695.
- [111] L.H. El Kalla, N.M. Salama, A.H. Wahba, N.M. Sallam, Histological evaluation of platelet-rich fibrin for revascularization of immature permanent teeth in dogs, *Pediatr. Dent. J.* 29 (2019) 72–77.
- [112] J. Metlerska, I. Fagogeni, A. Nowicka, Efficacy of autologous platelet concentrates in regenerative endodontic treatment: A systematic review of human studies, *J. Endod.* 45 (2019) 20–30.
- [113] G. Meza, D. Urrejola, N. Saint Jean, C. Inostroza, V. López, M. Khoury, C. Brizuela, Personalized cell therapy for pulpitis using autologous dental pulp stem cells and leukocyte platelet-rich fibrin: a case report, *J. Endod.* 45 (2019) 144–149.
- [114] N. Meschi, M. EzEldeen, A.E. T Garcia, P. Lahoud, G. Gorp Van, W. Coucke, R. Jacobs, K. Vandamme, W. Teughels, P. Lambrechts, Regenerative endodontic procedure of immature permanent teeth with leukocyte and platelet rich fibrin: a multicenter controlled clinical trial, *J. Endod.* (2021), <https://doi.org/10.1016/j.joen.2021.08.003>. Epub ahead of print.
- [115] F. Xu, L. Qiao, Y. Zhao, W. Chen, S. Hong, J. Pan, B. Jiang, The potential application of concentrated growth factor in pulp regeneration: An in vitro and in vivo study, *Stem Cell Res. Ther.* 10 (2019) 134.
- [116] J.S. Song, K. Takimoto, M. Jeon, J. Vadakekalam, N.B. Ruparel, A. Diogenes, Decellularized human dental pulp as a scaffold for regenerative endodontics, *J. Dent. Res.* 96 (2017) 640–646.
- [117] M. Matoug-Elwerfelli, M.S. Duggal, H. Nazzal, F. Esteves, E. Raif, A biocompatible decellularized pulp scaffold for regenerative endodontics, *Int. Endod. J.* 51 (2018) 663–673.
- [118] S. Ravindran, C.C. Huang, A. George, Extracellular matrix of dental pulp stem cells: Applications in pulp tissue engineering using somatic MSCs, *Front. Physiol.* 4 (2014) 395.
- [119] Q. Alqahtani, S.H. Zaky, A. Patil, E. Beniash, H. Ray, C. Sfeir, Decellularized swine dental pulp tissue for regenerative root canal therapy, *J. Dent. Res.* 97 (2018) 1460–1467.
- [120] H. Bakhtiar, M. Pezeshki-Modaress, Z. Kiaipour, M. Shafiee, M.R. Ellini, A. Mazidi, S. Rajabi, S. Zamanlui Benisi, S.N. Ostad, K. Galler, P. Pakshir, A. Azarpazhooh, A. Kishen, Pulp ECM-derived macroporous scaffolds for stimulation of dental-pulp regeneration process, *Dent. Mater.* 36 (2020) 76–87.
- [121] H. Bakhtiar, S. Rajabi, M. Pezeshki-Modaress, M.R. Ellini, M. Panahinia, S. Alijani, A. Mazidi, A. Kamali, A. Azarpazhooh, A. Kishen, Optimizing methods for bovine dental pulp decellularization, *J. Endod.* 47 (2021) 62–68.
- [122] M.C. Wan, W. Qin, C. Lei, Q.H. Li, M. Meng, M. Fang, W. Song, J.H. Chen, F. Tay, L.N. Niu, Biomaterials from the sea: future building blocks for biomedical applications, *Bioact. Mater.* 6 (2021) 4255–4285.
- [123] K.Y. Tsang, M.C. Cheung, D. Chan, K.S. Cheah, The developmental roles of the extracellular matrix: beyond structure to regulation, *Cell Tissue Res.* 339 (2010) 93–110.
- [124] T. Rozario, D.W. DeSimone, The extracellular matrix in development and morphogenesis: A dynamic view, *Dev. Biol.* 341 (2010) 126–140.
- [125] C.J. Griffin, R. Harris, Ultrastructure of collagen fibrils and fibroblasts of the developing human dental pulp, *Arch. Oral Biol.* 11 (1966) 659–666.
- [126] M. Mochizuki, H. Sagara, T. Nakahara, Type I collagen facilitates safe and reliable expansion of human dental pulp stem cells in xenogeneic serum-free culture, *Stem Cell Res. Ther.* 11 (2020) 267–282.
- [127] Y. Sumita, M.J. Honda, T. Ohara, S. Tsuchiya, H. Sagara, H. Kagami, M. Ueda, Performance of collagen sponge as a 3-D scaffold for tooth-tissue engineering, *Biomaterials* 27 (2006) 3238–3248.
- [128] X. Jiang, H. Liu, C. Peng, Clinical and radiographic assessment of the efficacy of a collagen membrane in regenerative endodontics: a randomized, controlled clinical trial, *J. Endod.* 43 (2017) 1465–1471.
- [129] J.J. Cymerman, A. Nosrat, Regenerative endodontic treatment as a biologically based approach for non-surgical retreatment of immature teeth, *J. Endod.* 46 (2020) 44–50.
- [130] A. Nosrat, A. Kolahdouzan, A.H. Khatibi, P. Verma, D. Jamshidi, A.J. Nevins, M. Torabinejad, Clinical, radiographic, and histological outcome of regenerative endodontic treatment in human teeth using a novel collagen-hydroxyapatite scaffold, *J. Endod.* 45 (2019) 136–143.
- [131] A. Alexander, M. Torabinejad, S.A. Vahdati, A. Nosrat, P. Verma, A. Grandhi, S. Shabahang, Regenerative endodontic treatment in immature noninfected ferret teeth using blood clot or SynOss Putty as scaffolds, *J. Endod.* 46 (2020) 209–215.
- [132] W. Zhang, X.F. Walboomers, T.H. van Kuppevelt, W.F. Daamen, Z. Bian, J. A. Jansen, The performance of human dental pulp stem cells on different three-dimensional scaffold materials, *Biomaterials* 27 (2006) 5658–5668.

- [133] R.S. Prescott, R. Alsanea, M.I. Fayad, B.R. Johnson, C.S. Wenckus, J. Hao, A. S. John, A. George, In vivo generation of dental pulp-like tissue by using dental pulp stem cells, a collagen scaffold, and dentin matrix protein 1 after subcutaneous transplantation in mice, *J. Endod.* 34 (2008) 421–426.
- [134] V.T. Sakai, Z. Zhang, Z. Dong, K.G. Neiva, M.A. Machado, S. Shi, C.F. Santos, J. E. Nör, SHED differentiate into functional odontoblasts and endothelium, *J. Dent. Res.* 89 (2010) 791–796.
- [135] D.G. Moussa, C. Aparicio, Present and future of tissue engineering scaffolds for dentin-pulp complex regeneration, *J. Tissue Eng. Regen. Med.* 13 (2019) 58–75.
- [136] M. Murakami, H. Horibe, K. Iohara, Y. Hayashi, Y. Osako, Y. Takei, K. Nakata, N. Motoyama, K. Kurita, M. Nakashima, The use of granulocyte-colony stimulating factor induced mobilization for isolation of dental pulp stem cells with high regenerative potential, *Biomaterials* 34 (2013) 9036–9047.
- [137] K. Iohara, M. Murakami, N. Takeuchi, Y. Osako, M. Ito, R. Ishizaka, S. Utunomiya, H. Nakamura, K. Matsushita, M. Nakashima, A novel combinatorial therapy with pulp stem cells and granulocyte colony-stimulating factor for total pulp regeneration, *Stem Cells Transl. Med.* 2 (2013) 521–533.
- [138] K.Y. Lee, D.J. Mooney, Alginate: properties and biomedical applications, *Prog. Polym. Sci.* 37 (2012) 106–126.
- [139] K. Dobie, G. Smith, A.J. Sloan, A.J. Smith, Effects of alginate hydrogels and TGF- β 1 on human dental pulp repair in vitro, *Connect. Tissue Res* 43 (2002) 387–390.
- [140] S. Kumabe, M. Nakatsuka, G.S. Kim, S.S. Jue, F. Aikawa, J.W. Shin, Y. Iwai, Human dental pulp cell culture and cell transplantation with an alginate scaffold, *Okajimas Folia Anat. Jpn.* 82 (2006) 147–155.
- [141] L. Lambrecht, P. De Berdt, J. Vanacker, J. Leprince, A. Diogenes, H. Goldansaz, C. Bouzin, V. Pr at, C. Dupont-Gillain, A. des Rieux, The type and composition of alginate and hyaluronic-based hydrogels influence the viability of stem cells of the apical papilla, *Dent. Mater.* 30 (2014) e349–e361.
- [142] M. Bhoj, C. Zhang, D.W. Green, A first step in de novo synthesis of a living pulp tissue replacement using dental pulp MSCs and tissue growth factors, encapsulated within a bioinspired alginate hydrogel, *J. Endod.* 41 (2015) 1100–1107.
- [143] R. Zhang, L. Xie, H. Wu, T. Yang, Q. Zhang, Y. Tian, Y. Liu, X. Han, W. Guo, M. He, S. Liu, W. Tian, Alginate/laponite hydrogel microspheres co-encapsulating dental pulp stem cells and VEGF for endodontic regeneration, *Acta Biomater.* 113 (2020) 305–316.
- [144] S. Sancilio, M. Gallorini, C. Di Nisio, E. Marsich, R. Di Pietro, H. Schweikl, A. Cataldi, Alginate/hydroxyapatite-based nanocomposite scaffolds for bone tissue engineering improve dental pulp biomineralization and differentiation, *Stem Cell. Int.* 2 (2018), 9643721.
- [145] P. Rastogi, B. Kandasubramanian, Review of alginate-based hydrogel bioprinting for application in tissue engineering, *Biofabrication* 11 (2019), 042001.
- [146] H. Yu, X. Zhang, W. Song, T. Pan, H. Wang, T. Ning, Q. Wei, H.H.K. Xu, B. Wu, D. Ma, Effects of 3-dimensional bioprinting alginate/gelatin hydrogel scaffold extract on proliferation and differentiation of human dental pulp stem cells, *J. Endod.* 45 (2019) 706–715.
- [147] S.M. Ahsan, M. Thomas, K.K. Reddy, S.G. Sooraparaju, A. Asthana, I. Bhatnagar, Chitosan as biomaterial in drug delivery and tissue engineering, *Int. J. Biol. Macromol.* 110 (2018) 97–109.
- [148] P. Sahariah, M. M sson, Antimicrobial chitosan and chitosan derivatives: A review of the structure-activity relationship, *Biomacromolecules* 18 (2017) 846–886.
- [149] E. Fakhri, H. Eslami, P. Maroufi, F. Pakdel, S. Taghizadeh, K. Ganbarov, M. Yousefi, A. Tanomand, B. Yousefi, S. Mahmoudi, H.S. Kafil, Chitosan biomaterials application in dentistry, *Int. J. Biol. Macromol.* 162 (2020) 956–974.
- [150] N.R. Kim, D.H. Lee, P.H. Chung, H.C. Yang, Distinct differentiation properties of human dental pulp cells on collagen, gelatin, and chitosan scaffolds, *Oral Surg. Oral Med. Oral Pathol. Oral Radiol. Endod.* 108 (2009) e94–100.
- [151] X. Feng, X. Lu, D. Huang, J. Xing, G. Feng, G. Jin, X. Yi, L. Li, Y. Lu, D. Nie, X. Chen, L. Zhang, Z. Gu, X. Zhang, 3D porous chitosan scaffolds suit survival and neural differentiation of dental pulp stem cells, *Cell. Mol. Neurobiol.* 34 (2014) 859–870.
- [152] A. Bakopoulou, A. Georgopoulou, I. Grivas, C. Bekiari, O. Prymak, K. Loza, M. Epple, G.C. Papadopoulos, P. Koidis, M. Chatzinikolaidou, Dental pulp stem cells in chitosan/gelatin scaffolds for enhanced orofacial bone regeneration, *Dent. Mater.* 35 (2019) 310–327.
- [153] E.A. El Ashiry, N.M. Alamoudi, M.K. El Ashiry, H.A. Bastawy, D.A. El Derwi, H. M. Atta, Tissue engineering of necrotic dental pulp of immature teeth with apical periodontitis in dogs: radiographic and histological evaluation, *J. Clin. Pediatr. Dent* 42 (2018) 373–382.
- [154] P.J. Palma, J.C. Ramos, J.B. Martins, A. Diogenes, M.H. Figueiredo, P. Ferreira, C. Viegas, J.M. Santos, Histologic evaluation of regenerative endodontic procedures with the use of chitosan scaffolds in immature dog teeth with apical periodontitis, *J. Endod.* 43 (2017) 1279–1287.
- [155] M. Ducret, A. Montebault, J. Josse, M. Padeloup, A. Celle, R. Benchrih, F. Mallein-Gerin, B. Alliot-Licht, L. David, J.C. Farges, Design and characterization of a chitosan-enriched fibrin hydrogel for human dental pulp regeneration, *Dent. Mater.* 35 (2019) 523–533.
- [156] H. Aksef, F. Mahjour, F. Bosaid, S. Calamak, A.A. Azim, Antimicrobial activity and biocompatibility of antibiotic-loaded chitosan hydrogels as a potential scaffold in regenerative endodontic treatment, *J. Endod.* 46 (2020) 1867–1875.
- [157] C. Bellamy, S. Shrestha, C. Torneck, A. Kishen, Effects of a bioactive scaffold containing a sustained transforming growth factor- β 1-releasing nanoparticle system on the migration and differentiation of stem cells from the apical papilla, *J. Endod.* 42 (2016) 1385–1392.
- [158] S. Shrestha, A. Diogenes, A. Kishen, Temporal-controlled release of bovine serum albumin from chitosan nanoparticles: effect on the regulation of alkaline phosphatase activity in stem cells from apical papilla, *J. Endod.* 40 (2014) 1349–1354.
- [159] S. Shrestha, A. Diogenes, A. Kishen, Temporal-controlled dexamethasone releasing chitosan nanoparticle system enhances odontogenic differentiation of stem cells from apical papilla, *J. Endod.* 41 (2015) 1253–1258.
- [160] D.G. Soares, G. Anovazzi, E.A.F. Bordini, U.O. Zuta, M.L.A. Silva Leite, F.G. Basso, J. Hebling, C.A. de Souza Costa, Biological analysis of simvastatin-releasing chitosan scaffold as a cell-free system for pulp-dentin regeneration, *J. Endod.* 44 (2018) 971–976.
- [161] H. Sodhi, A. Panitch, Glycosaminoglycans in tissue engineering: a review, *Biomolecules* 29 (2020) 29.
- [162] R. Lu, Y. Zhang, H. Tao, L. Zhou, H. Li, T. Chen, P. Zhang, Y. Lu, S. Chen, Gadolinium-hyaluronic acid nanoparticles as an efficient and safe magnetic resonance imaging contrast agent for articular cartilage injury detection, *Bioact. Mater.* 21 (2020) 758–767.
- [163] C. Mangkornkarn, J.C. Steiner, In vivo and in vitro glycosaminoglycans from human dental pulp, *J. Endod.* 18 (1992) 327–331.
- [164] L. Lambrecht, P. De Berdt, J. Vanacker, J. Leprince, A. Diogenes, H. Goldansaz, C. Bouzin, V. Pr at, C. Dupont-Gillain, A. des Rieux, The type and composition of alginate and hyaluronic-based hydrogels influence the viability of stem cells of the apical papilla, *Dent. Mater.* 30 (2014) e349–e361.
- [165] V. Chrepa, O. Austah, A. Diogenes, Evaluation of a commercially available hyaluronic acid hydrogel (Restylane) as injectable scaffold for dental pulp regeneration: an in vitro evaluation, *J. Endod.* 43 (2017) 257–262.
- [166] L. Ferroni, C. Gardin, S. Sivoiella, G. Brunello, M. Berengo, A. Piattelli, E. Bressan, B. Zavan, A hyaluronan-based scaffold for the in vitro construction of dental pulp-like tissue, *Int. J. Mol. Sci.* 16 (2015) 4666–4681.
- [167] J. Ma, Y. Shen, S. Stojicic, M. Haapasalo, Biocompatibility of two novel root repair materials, *J. Endod.* 37 (2011) 793–798.
- [168] H.M. Zhou, Y. Shen, Z.J. Wang, L. Li, Y.F. Zheng, L. H kkinen, M. Haapasalo, In vitro cytotoxicity evaluation of a novel root repair material, *J. Endod.* 39 (2013) 478–483.
- [169] L.N. Niu, K. Jiao, T.D. Wang, W. Zhang, J. Camilleri, B.E. Bergeron, H.L. Feng, J. Mao, J.H. Chen, D.H. Pashley, F.R. Tay, A review of the bioactivity of hydraulic calcium silicate cements, *J. Dent.* 42 (2014) 517–533.
- [170] Z. Wang, Bioceramic materials in endodontics, *Endod. Top.* 32 (2015) 3–30.
- [171] M. Torabinejad, M. Parirokh, P.M.H. Dummer, Mineral trioxide aggregate and other bioactive endodontic cements: an updated overview - part II: other clinical applications and complications, *Int. Endod. J.* 51 (2018) 284–317.
- [172] M. Haapasalo, M. Parhar, X. Huang, X. Wei, J. Lin, Y. Shen, Clinical use of bioceramic materials, *Endod. Top.* 32 (2015) 97–117.
- [173] F. Banchs, M. Trope, Revascularization of immature permanent teeth with apical periodontitis: new treatment protocol? *J. Endod.* 30 (2004) 196–200.
- [174] N. Wongwatanasanti, J. Jantarat, H. Sritanaudomchai, K.M. Hargreaves, Effect of bioceramic materials on proliferation and odontoblast differentiation of human stem cells from the apical papilla, *J. Endod.* 44 (2018) 1270–1275.
- [175] M.S. Seo, K.G. Hwang, J. Lee, H. Kim, S.H. Baek, The effect of mineral trioxide aggregate on odontogenic differentiation in dental pulp stem cells, *J. Endod.* 39 (2013) 242–248.
- [176] J. Du, Y. Lu, M. Song, L. Yang, J. Liu, X. Chen, Y. Ma, Y. Wang, Effects of ERK/p38 MAPKs signaling pathways on MTA-mediated osteo/odontogenic differentiation of stem cells from apical papilla: a vitro study, *BMC Oral Health* 20 (2020) 50–58.
- [177] A. Chaniotis, The use of MTA/blood mixture to induce hard tissue healing in a root fractured maxillary central incisor. Case report and treatment considerations, *Int. Endod. J.* 47 (2014) 989–999.
- [178] R. Budiraharjo, K.G. Neoh, E.T. Kang, A. Kishen, Bioactivity of novel carboxymethyl chitosan scaffold incorporating MTA in a tooth model, *Int. Endod. J.* 43 (2010) 930–939.
- [179] C.C. Ho, H.Y. Fang, B. Wang, T.H. Huang, M.Y. Shie, The effects of Biodentine/polycaprolactone three-dimensional-scaffold with odontogenesis properties on human dental pulp cells, *Int. Endod. J.* 51 (2018) e291–300.
- [180] K.H. Huang, Y.W. Chen, C.Y. Wang, Y.H. Lin, Y.A. Wu, M.Y. Shie, C.P. Lin, Enhanced capability of bone morphogenetic protein 2-loaded mesoporous calcium silicate scaffolds to induce odontogenic differentiation of human dental pulp cells, *J. Endod.* 44 (2018) 1677–1685.
- [181] P. Sarraf, M.H. Nekoofar, M.S. Sheykhezadeh, P.M.H. Dummer, Fracture resistance of immature incisors following root filling with various bioactive endodontic cements using an experimental bovine tooth model, *Eur. J. Dermatol.* 13 (2019) 156–160.
- [182] M. Karapinar-Kazandag, B. Basrani, V. Tom-Kun Yamagishi, A. Azarpazhooh, S. Friedman, Fracture resistance of simulated immature tooth roots reinforced with MTA or restorative materials, *Dent. Traumatol.* 32 (2016) 146–152.
- [183] A. Demirel, T. Bezgin, S. Sari, Effects of root maturation and thickness variation in coronal MTA plugs under traumatic load on stress distribution in regenerative endodontic procedures: a 3D FEA study, *J. Endod.* 47 (2021) 492–499.
- [184] B. Kahler, G. Rossi-Fedeles, A Review of tooth discoloration after regenerative endodontic therapy, *J. Endod.* 42 (2016) 563–569.
- [185] L.V. Oliveira, G.R. da Silva, G.L. Souza, T.E.A. Magalh es, G.L.R. Barbosa, A. P. Turriioni, C.C.G. Moura, A laboratory evaluation of cell viability, radiopacity and tooth discoloration induced by regenerative endodontic materials, *Int. Endod. J.* 53 (2020) 1140–1152.
- [186] N.M. El-Kateb, R.N. El-Backly, W.M. Amin, A.M. Abdalla, Quantitative assessment of intracanal regenerated tissues after regenerative endodontic procedures in

- mature teeth using magnetic resonance imaging: a randomized controlled clinical trial, *J. Endod.* 46 (2020) 563–574.
- [187] A. Matichescu, L.C. Ardelean, L.C. Rusu, D. Craciun, E.A. Bratu, M. Babucea, M. Leretter, Advanced biomaterials and techniques for oral tissue engineering and regeneration: a review, *Materials (Basel)* 13 (2020) 5303.
- [188] M.F. Meek, J.H. Coert, US Food and Drug Administration/Conformit Europe-approved absorbable nerve conduits for clinical repair of peripheral and cranial nerves, *Ann. Plast. Surg.* 60 (2008) 110–116.
- [189] M. Gebhardt, P.E. Murray, K.N. Namerow, S. Kuttler, F. Garcia-Godoy, Cell survival within pulp and periodontal constructs, *J. Endod.* 35 (2009) 63–66.
- [190] S. Chandrhasa, P.E. Murray, K.N. Namerow, Proliferation of mature ex vivo human dental pulp using tissue engineering scaffolds, *J. Endod.* 37 (2011) 1236–1239.
- [191] K.C. Feng, A. Pinkas-Sarafava, V. Ricotta, M. Cuiffo, L. Zhang, Y. Guo, C.C. Chang, G.P. Halada, M. Simon, M. Rafailovich, The influence of roughness on stem cell differentiation using 3D printed polylactic acid scaffolds, *Soft Matter* 14 (2018) 9838–9846.
- [192] M. Alksne, E. Simoliunas, M. Kalvaityte, E. Skliutas, I. Rinkunaite, I. Gendviliene, D. Baltruikiene, V. Rutkunas, V. Bukelskiene, The effect of larger than cell diameter polylactic acid surface patterns on osteogenic differentiation of rat dental pulp stem cells, *J. Biomed. Mater. Res. A* 107 (2019) 174–186.
- [193] D. Hsiao, S.H. Hsu, R.S. Chen, M.H. Chen, Characterization of designed directional polylactic acid 3D scaffolds for neural differentiation of human dental pulp stem cells, *J. Formos. Med. Assoc.* 119 (2020) 268–275.
- [194] Y. Qi, T. Zou, W.L. Dissanayaka, H.M. Wong, L.E. Bertassoni, C. Zhang, Fabrication of tapered fluidic microchannels conducive to angiogenic sprouting within gelatin methacryloyl hydrogels, *J. Endod.* 47 (2021) 52–61.
- [195] X. Bai, M. Gao, S. Syed, J. Zhuang, X. Xu, X.Q. Zhang, Bioactive hydrogels for bone regeneration, *Bioact. Mater.* 26 (2018) 401–417.
- [196] K.A. Fukushima, M.M. Marques, T.K. Tedesco, G.L. Carvalho, F. Gonçalves, H. Caballero-Flores, S. Morimoto, M.S. Moreira, Screening of hydrogel-based scaffolds for dental pulp regeneration: a systematic review, *Arch. Oral Biol.* 98 (2019) 182–194.
- [197] A. Khayat, N. Monteiro, E.E. Smith, S. Pagni, W. Zhang, A. Khademhosseini, P. C. Yelick, GelMA-encapsulated hDPSCs and HUVECs for dental pulp regeneration, *J. Dent. Res.* 96 (2017) 192–199.
- [198] N. Monteiro, G. Thirivikraman, A. Athirasala, A. Tahayeri, C.M. França, J. L. Ferracane, L.E. Bertassoni, Photopolymerization of cell-laden gelatin methacryloyl hydrogels using a dental curing light for regenerative dentistry, *Dent. Mater.* 34 (2018) 389–399.
- [199] K.P. Krafts, Tissue repair: The hidden drama, *Organogenesis* 6 (2010) 225–233.
- [200] J.M. Reinke, H. Sorg, Wound repair and regeneration, *Eur. Surg. Res.* 49 (2012) 35–43.
- [201] M. Matoug-Elwerfelli, H. Nazzal, M. Duggal, R. El-Gendy, What the future holds for regenerative endodontics: novel antimicrobials and regenerative strategies, *Eur. Cell. Mater.* 41 (2021) 811–833.
- [202] A.F. Fouad, Contemporary microbial and antimicrobial considerations in regenerative endodontic therapy, *J. Endod.* 46 (2020) S105–S114.
- [203] J.S. Ribeiro, E.A. Münchow, E.A. Ferreira Bordini, W.L. de Oliveira da Rosa, M. C. Bottino, Antimicrobial therapeutics in regenerative endodontics: a scoping review, *J. Endod.* 46 (2020) S115–S127.
- [204] R.A. Gangolli, S.M. Devlin, J.A. Gerstenhaber, P.I. Lelkes, M. Yang, A bilayered poly (lactic-co-glycolic acid) scaffold provides differential cues for the differentiation of dental pulp stem cells, *Tissue Eng. Part A* 25 (2019) 224–233.
- [205] Y. Du, C. Montoya, S. Orrego, X. Wei, J. Ling, P.I. Lelkes, M. Yang, Topographic cues of a novel bilayered scaffold modulate dental pulp stem cells differentiation by regulating YAP signalling through cytoskeleton adjustments, *Cell Prolif* 52 (2019), e12676.
- [206] M. Widbiller, A. Eidt, S.R. Lindner, K.A. Hiller, H. Schweikl, W. Buchalla, K. M. Galler, Dentine matrix proteins: isolation and effects on human pulp cells, *Int. Endod. J.* 51 (2018) e278–e290.
- [207] M. Widbiller, R.B. Driesen, A. Eidt, I. Lambrichts, K.A. Hiller, W. Buchalla, G. Schmalz, K.M. Galler, Cell homing for pulp tissue engineering with endogenous dentin matrix proteins, *J. Endod.* 44 (2018) 956–962.
- [208] E.H.F. Duncan, Y. Kobayashi, E. Shimizu, Growth factors and cell homing in dental tissue regeneration, *Curr. Oral Health Rep.* 5 (2018) 276–285.
- [209] S. Shrestha, A. Kishen, Bioactive molecule delivery systems for dentin-pulp tissue engineering, *J. Endod.* 43 (2017) 733–744.
- [210] Y.J. Chen, M.C. Chung, C.C. Jane Yao, C.H. Huang, H.H. Chang, J.H. Jeng, T. H. Young, The effects of acellular amniotic membrane matrix on osteogenic differentiation and ERK1/2 signaling in human dental apical papilla cells, *Biomaterials* 33 (2012) 455–463.
- [211] N. Suresh, B. Arul, D. Kowsky, V. Natanasabapathy, Successful regenerative endodontic procedure of a nonvital immature permanent central incisor using amniotic membrane as a novel scaffold, *Dent. J. (Basel)* 6 (2018) 36.
- [212] E.J. Joseph, M.Y. Karuna, A. Rao, A. Rao, A.P. Nayak, A novel regenerative endodontic procedure in a traumatized immature tooth using amniotic membrane, *Dent. Res. J.* 18 (2021) 28.
- [213] S.G. Kim, C.S. Solomon, Regenerative endodontic therapy in mature teeth using human-derived composite amnion-chorion membrane as a bioactive scaffold: a pilot animal investigation, *J. Endod.* 47 (2021) 1101–1109.
- [214] J. Han, D.S. Kim, H. Jang, H. R. Kim, H.W. Kang, Bioprinting of three-dimensional dentin-pulp complex with local differentiation of human dental pulp stem cells, *J. Tissue Eng.* 10 (2019), 2041731419845849.
- [215] F. Obregon, C. Vaquette, S. Ivanovski, D.W. Huttmacher, L.E. Bertassoni, Three-dimensional bioprinting for regenerative dentistry and craniofacial tissue engineering, *J. Dent. Res.* 94 (2015) 435–525.
- [216] Y. Ma, L. Xie, B. Yang, W. Tian, Three-dimensional printing biotechnology for the regeneration of the tooth and tooth-supporting tissues, *Biotechnol. Bioeng.* 116 (2019) 452–468.
- [217] Y. Qi, T. Zou, W.L. Dissanayaka, H.M. Wong, L.E. Bertassoni, C. Zhang, Fabrication of tapered fluidic microchannels conducive to angiogenic sprouting within gelatin methacryloyl hydrogels, *J. Endod.* 47 (2021) 52–61.
- [218] L.E. Bertassoni, Progress and challenges in microengineering the dental pulp vascular microenvironment, *J. Endod.* 46 (2020) S90–S100.
- [219] A. Athirasala, F. Lins, A. Tahayeri, M. Hinds, A.J. Smith, C. Sedgley, J. Ferracane, L.E. Bertassoni, A novel strategy to engineer pre-vascularized full-length dental pulp-like tissue constructs, *Sci. Rep.* 7 (2017) 3323.
- [220] A. Kishen, Nanotechnology in Endodontics Current and Potential Clinical Applications, Springer Science+Business Media, Cham, Switzerland, 2015.
- [221] A. Shrestha, A. Kishen, Antibacterial nanoparticles in endodontics: A review, *J. Endod.* 10 (2016) 1417–1426.
- [222] A. Kishen, Z. Shi, A. Shrestha, K.G. Neoh, An investigation on the antibacterial and antibiofilm efficacy of cationic nanoparticulates for root canal disinfection, *J. Endod.* 34 (2008) 1515–1520.
- [223] A. Shrestha, S.W. Fong, B.C. Khoo, A. Kishen, Delivery of antibacterial nanoparticles into dentinal tubules using high-intensity focused ultrasound, *J. Endod.* 35 (2009) 1028–1033.
- [224] A. Shrestha, Z. Shi, K.G. Neoh, A. Kishen, Nanoparticulates for antibiofilm treatment and effect of aging on its antibacterial activity, *J. Endod.* 36 (2010) 1030–1035.
- [225] H. Hussein, A. Kishen, Engineered chitosan-based nanoparticles modulate macrophage-periodontal ligament fibroblast interactions in biofilm-mediated inflammation, *J. Endod.* 47 (2021) 1435–1444.
- [226] F.C. Li, E. Nicholson, C.V. Singh, A. Kishen, Microtissue engineering root dentin with photodynamically cross-linked nanoparticles improves fatigue resistance of endodontically treated teeth, *J. Endod.* 46 (2020) 668–674.
- [227] A. Kishen, H. Hussein, Bioactive molecule carrier systems in endodontics, *Expet Opin. Drug Deliv.* 17 (2020) 1093–1112.
- [228] M. C. Bottino, K. Kamocki, G.H. Yassen, J.A. Platt, M.M. Vail, Y. Ehrlich, K. J. Spolnik, R.L. Gregory, Bioactive nanofibrous scaffolds for regenerative endodontics, *J. Dent. Res.* 92 (2013) 963–969.
- [229] T.P. Sato, B.V. M Rodrigues, D.C. R. Mello, E.A. Münchow, J.S. Ribeiro, J.P. B. Machado, L.M.R. Vasconcelos, A.O. Lobo, M.C. Bottino, A.L.S. Borges, The role of nanohydroxyapatite on the morphological, physical, and biological properties of chitosan nanofibers, *Clin. Oral Invest.* 25 (2021) 3095–3103.
- [230] X. Li, C. Ma, X. Xie, H. Sun, X. Liu, Pulp regeneration in a full-length human tooth root using a hierarchical nanofibrous microsphere system, *Acta Biomater.* 35 (2016) 57–67.
- [231] P. Wang, Y. Sun, X. Shi, H. Shen, H. Ning, H. Liu, 3D printing of tissue engineering scaffolds: A focus on vascular regeneration, *Biodes. Manuf.* 4 (2021) 1–35.
- [232] X. Jiang, H. Liu, C. Peng, Continued root development of immature teeth after regenerative endodontics with or without a collagen membrane: a randomized, controlled clinical trial, *Int. J. Paediatr. Dent.* (2021), <https://doi.org/10.1111/ipd.12853>. Epub ahead of print.
- [233] A.S. ElSheshtawy, H. Nazzal, O.I. El Shahawy, A.A. El Baz, S.M. Ismail, J. Kang, K. M. Ezzat, The effect of platelet-rich plasma as a scaffold in regeneration/revitalization endodontics of immature permanent teeth assessed using 2-dimensional radiographs and cone beam computed tomography: a randomized controlled trial, *Int. Endod. J.* 53 (2020) 905–921.
- [234] H.M. Rizk, M.S.S. Al-Deen, A.A. Emam, Regenerative endodontic treatment of bilateral necrotic immature permanent maxillary central incisors with platelet-rich plasma versus blood clot: a split mouth double-blinded randomized controlled trial, *Int. J. Clin. Pediatr. Dent.* 12 (2019) 332–339.
- [235] P. Jha, M.S. Virdi, S. Nain, A regenerative approach for root canal treatment of mature permanent teeth: comparative evaluation with 18 months follow-up, *Int. J. Clin. Pediatr. Dent.* 12 (2019) 182–188.
- [236] M. Santhakumar, S. Yayathi, N. Retnakumari, A clinicoradiographic comparison of the effects of platelet-rich fibrin gel and platelet-rich fibrin membrane as scaffolds in the apexification treatment of young permanent teeth, *J. Indian Soc. Pedod. Prev. Dent.* 36 (2018) 65–70.
- [237] A. Alagil, S. Bedi, K. Hassan, J. AlHumaid, Use of platelet-rich plasma for regeneration in non-vital immature permanent teeth: clinical and cone-beam computed tomography evaluation, *J. Int. Med. Res.* 45 (2017) 583–593.
- [238] V.Y. Shivshankar, D.A. Johns, R.K. Maroli, M. Sekar, R. Chandrasekaran, S. Karthikeyan, S.K. Renganathan, Comparison of the effect of PRP, PRF and induced bleeding in the revascularization of teeth with necrotic pulp and open apex: a triple blind randomized clinical trial, *J. Clin. Diagn. Res.* 11 (2017) 34–39.
- [239] S. Sharma, N. Mittal, A comparative evaluation of natural and artificial scaffolds in regenerative endodontics: a clinical study, *Saudi Endod. J.* 6 (2016) 9–15.
- [240] I. Narang, N. Mittal, N. Mishra, A comparative evaluation of the blood clot, platelet-rich plasma, and platelet-rich fibrin in regeneration of necrotic immature permanent teeth: a clinical study, *Contemp. Clin. Dent.* 6 (2015) 63–68.
- [241] M.M. Nagy, H.E. Tawfik, A.A. Hashem, A.M. Abu-Seida, Regenerative potential of immature permanent teeth with necrotic pulps after different regenerative protocols, *J. Endod.* 40 (2014) 192–198.
- [242] A.S. Alrashidi, D. Sadaf, R.S. Alabdulrazzaq, A.S. Alrashidi, M.A. Alajlan, A. A. Aljuhani, Effectiveness of various scaffolds on the success of endodontic tissue regeneration: A systematic review and meta-analysis of randomized controlled trials, *Saudi. Endod. J.* 11 (2021) 129–141.

- [243] K. Iohara, K. Imabayashi, R. Ishizaka, A. Watanabe, J. Nabekura, M. Ito, K. Matsushita, H. Nakamura, M. Nakashima, Complete pulp regeneration after pulpectomy by transplantation of CD105+ stem cells with stromal cell-derived factor-1, *Tissue Eng. Part A* 17 (2011) 1911–1920.
- [244] X. Zhu, J. Liu, Z. Yu, C.A. Chen, H. Aksel, A.A. Azim, G.T. Huang, A miniature swine model for stem cell-based de novo regeneration of dental pulp and dentin-like tissue, *Tissue Eng. C Methods* 24 (2018) 108–120.
- [245] M. Nakashima, K. Iohara, M.C. Bottino, A.F. Fouad, J.E. Nör, G.T. Huang, Animal models for stem cell-based pulp regeneration: foundation for human clinical applications, *Tissue Eng. Part B Rev* 25 (2019) 100–113.