



## Review article

# Craniopharyngioma: A comprehensive review of the clinical presentation, radiological findings, management, and future Perspective

Maryam Nashi Alboqami<sup>a,b</sup>, Arwa Khalid S Albaiahy<sup>a,b</sup>, Bushra Hatim Bukhari<sup>a,b</sup>, Ali Alkhaibary<sup>a,b,c,\*</sup>, Ahoud Alharbi<sup>a,b,c</sup>, Sami Khairy<sup>a,b,c</sup>, Ali H. Alassiri<sup>a,b,d</sup>, Fahd AlSufiani<sup>b,d</sup>, Ahmed Alkhani<sup>b,c</sup>, Ahmed Aloraidi<sup>a,b,c</sup>

<sup>a</sup> College of Medicine, King Saud bin Abdulaziz University for Health Sciences, Riyadh, Saudi Arabia

<sup>b</sup> King Abdullah International Medical Research Center, Riyadh, Saudi Arabia

<sup>c</sup> Division of Neurosurgery, Department of Surgery, King Abdulaziz Medical City, Ministry of National Guard - Health Affairs, Riyadh, Saudi Arabia

<sup>d</sup> Department of Pathology and Laboratory Medicine, King Abdulaziz Medical City, Ministry of National Guard - Health Affairs, Riyadh, Saudi Arabia

## ARTICLE INFO

## Keywords:

Craniopharyngioma  
Hormone  
Endocrine  
Tumor  
Review

## ABSTRACT

Craniopharyngioma (CP) is a rare intracranial tumor arising from the epithelial remnants of Rathke's pouch, most frequently originating in the sellar/parasellar region. Histologically, CP is a benign low-grade tumor (WHO grade 1) with two distinct phenotypes: adamantinomatous CP (ACP) and papillary CP (PCP). Craniopharyngioma constitutes 1–3% of all primary intracranial tumors in adults and 5–10 % of intracranial tumors in children. The annual incidence ranges from 0.13 to 2 per 100,000 population per year with no gender predilection. Due to its unique anatomical locations, the most frequently reported clinical manifestations are headache, visual impairment, nausea/vomiting, and endocrine deficiencies resulting in sexual dysfunction in adults and growth failure in children. Growth hormone deficiency is the most predominant endocrinological disturbance associated with craniopharyngioma. Computed tomography (CT) is gold standard to detect calcifications in CP tissue (found in 90 % of these tumors). Magnetic Resonance Imaging (MRI) further characterizes craniopharyngiomas and helps to narrow down the differential diagnoses. In almost all craniopharyngioma cases, surgery is indicated to: establish the diagnosis, relieve mass-related symptoms, and remove as much tumor as is safely possible. Recent neurosurgical technical advances, including innovative surgical approaches, detailed radiotherapy protocols, targeted therapy, replacement of lost hormonal functions and quality of life all have the potential to improve the outcome of patients with craniopharyngioma. In this article, we present extensive literature on craniopharyngioma clinical presentation, radiological findings, management, and future prospective. The present article helps to identify further research areas that set the basis for the management of such a complex tumor.

\* Corresponding author. College of Medicine, King Saud bin Abdulaziz University for Health Sciences, Riyadh, Saudi Arabia. King Abdullah International Medical Research Center, Riyadh, Saudi Arabia. Division of Neurosurgery, Department of Surgery, Ministry of National Guard - Health Affairs, Riyadh, Saudi Arabia.

E-mail addresses: [maryamalboqami4@gmail.com](mailto:maryamalboqami4@gmail.com) (M.N. Alboqami), [Albaiahy055@gmail.com](mailto:Albaiahy055@gmail.com) (A. Khalid S Albaiahy), [Bushra.bukhari.94@gmail.com](mailto:Bushra.bukhari.94@gmail.com) (B.H. Bukhari), [AlkhaibaryA@hotmail.com](mailto:AlkhaibaryA@hotmail.com) (A. Alkhaibary), [Alharbi1ahoud@gmail.com](mailto:Alharbi1ahoud@gmail.com) (A. Alharbi), [Drsami2009@hotmail.com](mailto:Drsami2009@hotmail.com) (S. Khairy), [Assirial@ngha.med.sa](mailto:Assirial@ngha.med.sa) (A.H. Alassiri), [SufianiF@ngha.med.sa](mailto:SufianiF@ngha.med.sa) (F. AlSufiani), [Alkhaniah@ngha.med.sa](mailto:Alkhaniah@ngha.med.sa) (A. Alkhani), [Aloraidiah@ngha.med.sa](mailto:Aloraidiah@ngha.med.sa) (A. Aloraidi).

<https://doi.org/10.1016/j.heliyon.2024.e32112>

Received 23 December 2023; Received in revised form 24 May 2024; Accepted 28 May 2024

Available online 31 May 2024

2405-8440/© 2024 The Authors. Published by Elsevier Ltd. This is an open access article under the CC BY-NC license (<http://creativecommons.org/licenses/by-nc/4.0/>).

## 1. Introduction

Craniopharyngioma (CP) is a rare intracranial tumor arising from epithelial remnants of Rathke's pouch, most frequently originating in the sellar/parasellar region [1]. Histologically, CP is a benign low-grade tumor (WHO grade 1) with two distinct phenotypes: adamantinomatous CP (ACP) and papillary CP (PCP) [2,3]. The tumor may affect the adjacent neural structures and pituitary gland's growth hormone production due to its compressive effects, post-surgical treatment, or received radiosurgery [4]. As a consequence, growth hormone deficiency is the most predominant endocrinological disturbance associated with CP [5] (see Fig. 4).

## 2. Methodology

A narrative review was performed using the database Cochrane library, PubMed, LILACS, and Web of Science, excluding duplicate references at the end of the studies. Articles published between 1990 and 2022 were selected and refined. The key terms used were: clinical presentation, radiological diagnosis, histopathological features, management, prognosis, quality of life, complications, future prospective, and craniopharyngioma. Inclusion criteria were review or original articles published in the period mentioned above with an observational or experimental design performed on craniopharyngioma patients for diagnosis, management, and long-term prognosis. Complications, recurrence, prognosis, and hormonal function after treatment were the used outcomes.

## 3. History

In 1857, craniopharyngioma was first described by Friedrich Albert Von Zenker who identified a group of cells resembling squamous epithelium located in the pars tuberalis and pars distalis of the pituitary gland [6]. Two years later, Jacob Erdheim described the histopathological characteristics of craniopharyngioma in adults found mostly on the anterior surface of the infundibulum in groups or islets of variable size, shape, and number [7]. In 1932, Susman was the first to detect squamous epithelial cell nests in the pituitary glands of children [8].

The first successful surgical attempt of craniopharyngioma resection was performed by A. E. Halstead of Chicago in 1909 [9]. Harvey Cushing utilized the *trans*-sphenoidal approach for most of his pituitary gland surgeries but advocated the *trans*-cranial approach for craniopharyngioma [10]. The name Craniopharyngioma was first introduced by Cushing in 1932 [11].

## 4. Epidemiology

Craniopharyngioma constitutes 1–3% of all primary intracranial tumors in adults and 5–10 % of intracranial tumors in children [12,13]. The annual incidence ranges from 0.13 to 2 per 100,000 population per year with no gender predilection [14]. CP has a bimodal age distribution with one peak in children at ages 5–14 years and a second peak in adults at ages 50–74 years [15]. The Papillary CP subtype is more common in adults, while adamantinomatous CP predominates in the pediatric age group [16].

## 5. Pathophysiology

The pathogenesis of craniopharyngioma is not completely elucidated, however, there are two acknowledged theories of CP formation: the embryonic theory and the metaplastic theory [17,18].

The embryonic origin of CP arises from the ectodermal remnants of Rathke's pouch and/or the residual pharyngeal epithelium of the anterior pituitary gland [19]. The squamous cells undergo neoplastic transformations during the development of the pituitary gland, forming the ACP subtype, the most frequently diagnosed subtype in childhood populations [20].

The metaplastic theory proposes that the adenohypophyseal cells in the pars tuberalis of the adenohypophysis undergo metaplastic changes resulting in the formation of squamous cell nests containing hormones that increase with age in the gland [21]. This mechanism bolsters the formation of the PCP subtype, most commonly occurring among adults [22].

## 6. Clinical presentation

Symptoms of CP develop insidiously, and there is usually a delay in the diagnosis due to slow tumor growth [23]. The most frequently reported clinical manifestations are headache, visual impairments, nausea/vomiting, and endocrine deficiencies resulting in sexual dysfunction in adults and growth failure in children [3].

Endocrine abnormalities are caused by the tumor's direct effect and/or by the compression of the hypothalamic-pituitary axis, affecting the secretion of growth hormone (GH), gonadotropin (LH/FSH), thyroid-stimulating hormone (TSH), and adrenocorticotropic hormone (ACTH) [17]. Moreover, diabetes insipidus is also common if the infundibulum is involved [17]. Other less common features include motor deficits, mono-or hemiparesis, seizures, depression, hallucinations, and autonomic disturbances [3].

Visual abnormalities also occur through compression and/or direct extension of the tumor to the visual pathway. Patients with suprasellar CP may present with visual field deficits (usually bitemporal hemianopia) or decreased visual acuity as a result of optic chiasm compression. Parasellar CP can manifest as diplopia or strabismus due to cranial nerve palsies. The obstructive mass effect may lead to papilledema and optic disc atrophy, which eventually might result in vision loss [24].

## 7. Neuroradiological features

The diagnosis of CP is suggested by the presence of a cystic tumor in the intra- and/or suprasellar region. The most common location of CP is suprasellar, with an intrasellar portion [25]. The presence of solid, cystic, and calcified tumor components also serves as an important clue to the diagnosis [23].

### 7.1. Computed tomography

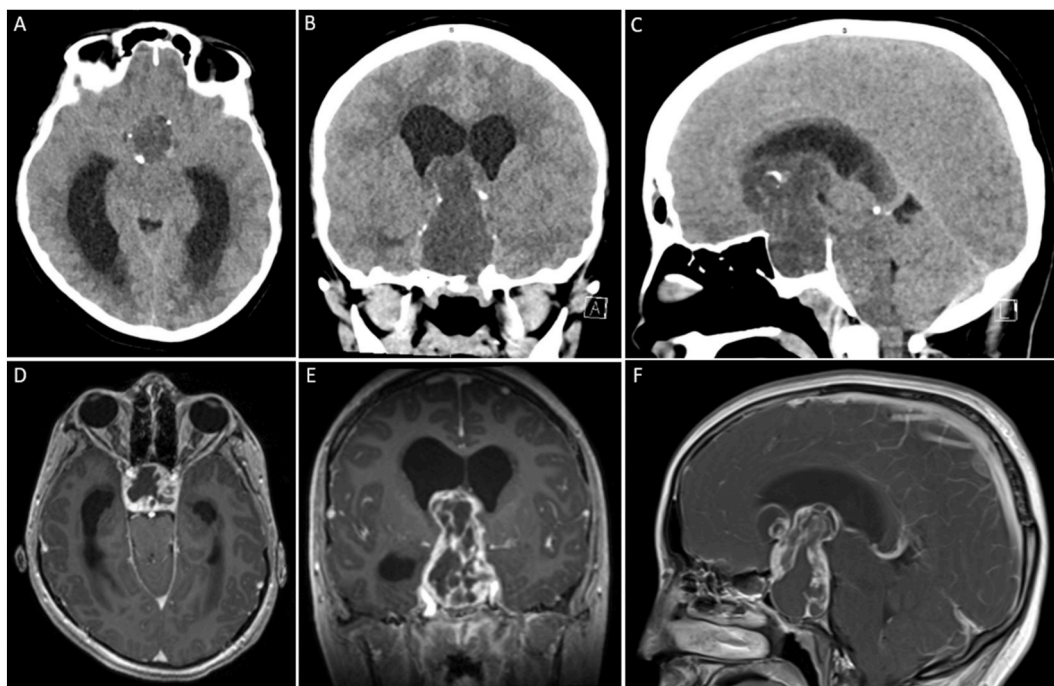
Computed tomography (CT) is gold standard to detect calcifications in CP tissue (found in 90 % of these tumors). On CT, ACP is frequently described as a hypodense cystic mass located in the suprasellar region. ACP tumor presents with a variable amount of calcifications inside the tumor and in the cyst wall [26]. PCP usually appears as an isodense suprasellar solid mass without any calcification [23].

### 7.2. Magnetic Resonance Imaging

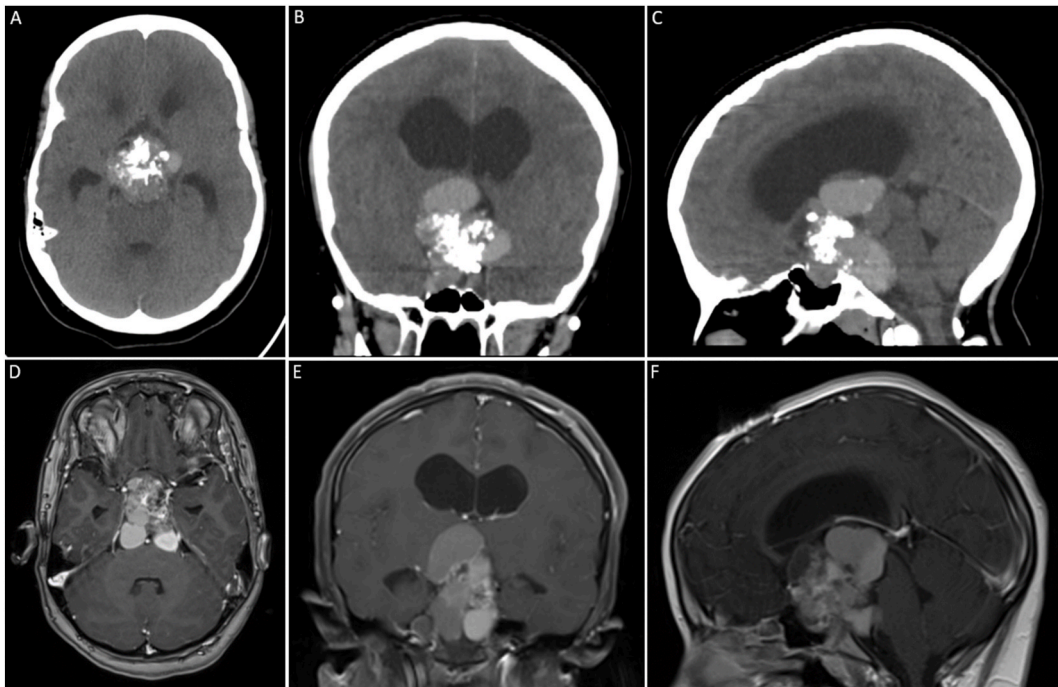
On MRI, ACP may present as an uni- or multilocular cyst, with small solid nodulation. On plain MRI, the solid tumor portions and the cyst membranes may show high variability of T1 signals. The tumor is typically hypo- and hyperintense on T2-weighted images; this variability is due to the heterogeneous distribution of the calcifications. PCP features an iso- to slightly hypointense T1 signal. On T2-weighted images, the signal is distinctly hyperintense; foci of less intensity may be present [23,26]. Figs. 1–2 show illustrative images of patients with craniopharyngioma (see Fig. 3).

## 8. Histopathological features

Histopathologically, craniopharyngioma is divided mainly into ACP and PCP subtypes. However, transitional and mixed variants have been reported [27,28]. ACP is characterized by the presence of cystic components potentially forming large, calcified concentrations. Tumor infiltration of the surrounding tissue is more frequent in ACP, and frequently forms wide and strong adhesions [28–30]. PCP presents as a noncalcified solid mass with loose adhesions and mainly having a sessile or pedicle attachment [28].



**Fig. 1.** A 16-year-old female with short stature, bi-temporal hemianopia, and pan-hypopituitarism. (A–C) Axial, coronal, and sagittal brain CT without contrast. (D–F) Axial, coronal, and sagittal brain MRI with contrast. (A–B) The images demonstrate a well-defined sellar/suprasellar hypodense lesion with areas of hyperdensities. It is oval-shaped and measures approximately 5.1 x 3.1 x 1.7 cm along its maximum dimensions. It is associated with peripheral calcification. The lesion is obstructing the third ventricle and causing subsequent supratentorial hydrocephalus, most evident on the lateral ventricles. (D–F) The lesion has peripheral solid component and central cystic component. The solid component demonstrates heterogeneous avid enhancement post Gadolinium administration. The mass is compressing and displacing the optic nerves and optic chiasm.



**Fig. 2.** A 14-year-old female with headache, visual disturbance, and new-onset syncope. (A–C) Axial, coronal, and sagittal brain CT without contrast. (D–F) Axial, coronal, and sagittal brain MRI with contrast. (A–C) The images demonstrate an extra-axial sellar/suprasellar heterogeneous hyperdense lesion. It is oval-shaped and measures approximately 4.1 X 4.5 × 5.2 cm along its maximum dimensions. It is showing areas of dense calcifications within the lesion. The lesion is compressing the hypothalamus and third ventricle causing obstructive supratentorial hydrocephalus. (D–F) The lesion demonstrates homogenous avid enhancement post Gadolinium administration.

## 9. Molecular features

In ACP, somatic mutations in the CTNNB1 gene (encoding  $\beta$ -catenin), mainly point mutations in exon 3, result in the overactivation of the WNT/ $\beta$ -catenin pathway. These alterations are present in 95 % of ACP [23,28,29]. Somatic BRAF (V600E) mutations are present in 81–100 % of PCP and result in the activation of the mitogen-activated protein kinase (MAPK) signaling pathway [28].

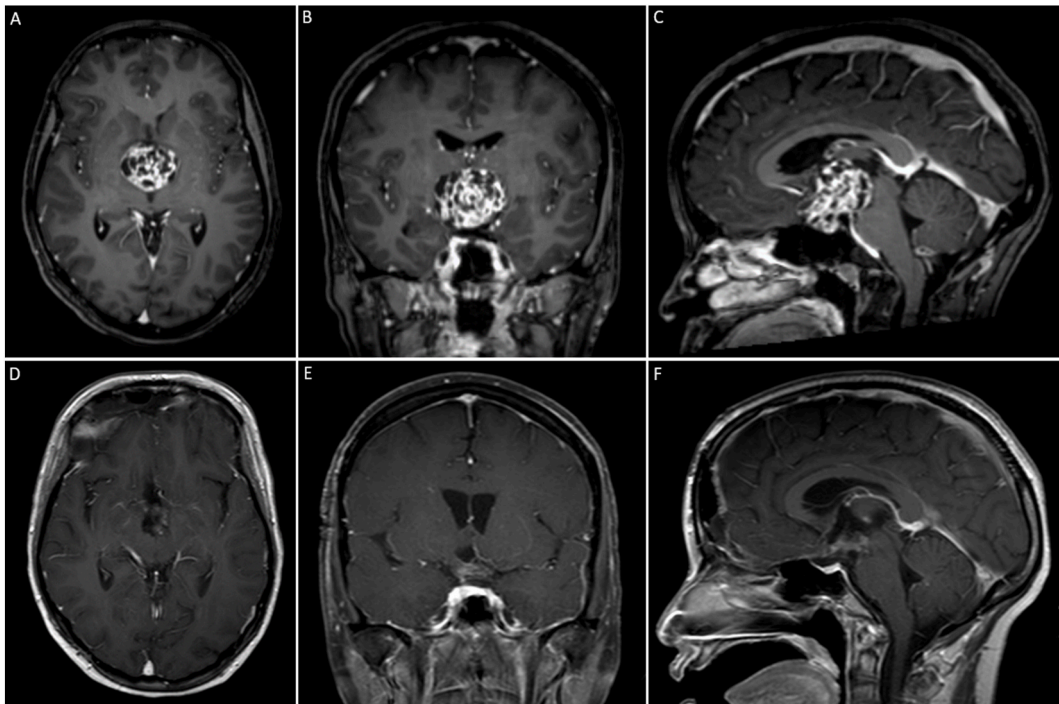
## 10. Management

Recent neurosurgical technical advances, including innovative surgical approaches, detailed radiotherapy protocols, targeted therapy, and replacement of lost hormonal functions all have the potential to enhance the outcome of patients with craniopharyngioma [31].

### 10.1. Surgery

In almost all craniopharyngioma cases, surgery is indicated in order to: establish the diagnosis, relieve mass-related symptoms, and remove as much tumor as is safely possible. Multiple strategies are suggested depending on the treating surgeon. In anticipation of irradiation of residual tumor, some advocate cyst drainage and minimal solid tumor resection for the reduction of neural compression. Others preface that complete resection can be accomplished with a low risk of neurologic injury at the initial operation [32]. The presence of disease-related complications can increase the risk associated with surgery and must be treated in preoperative management. They include endocrine function, peritumoral edema, hydrocephalus, and patients with a large cystic component of their tumor [33].

In pediatric craniopharyngioma, the benefit of gross total resection in terms of quality of life is debated [34,35]. Depending on the location of the tumor, an appropriate approach is taken, which includes an extended endonasal, endoscopic, or transphenoidal. These approaches are not limited to sellar tumors but extend to suprasellar tumors including some that reach into the third ventricle [32]. As the gap between the diaphragma sellae and optic chiasm is reduced, these approaches become more difficult and thus are contraindicated for tumors restricted to the third ventricle. In these cases, a third ventricle tumor can be exposed via craniotomy [36]. The surgeon should imperatively seek to recognize and preserve the pituitary stalk, refrain from manipulating the optic chiasm, and avoid dissecting tumors invading the hypothalamus. Although these precautions are followed in all cases, postoperative hypothalamic dysfunction can manifest, especially with retrochiasmatic tumors involving the posterior hypothalamus [37].



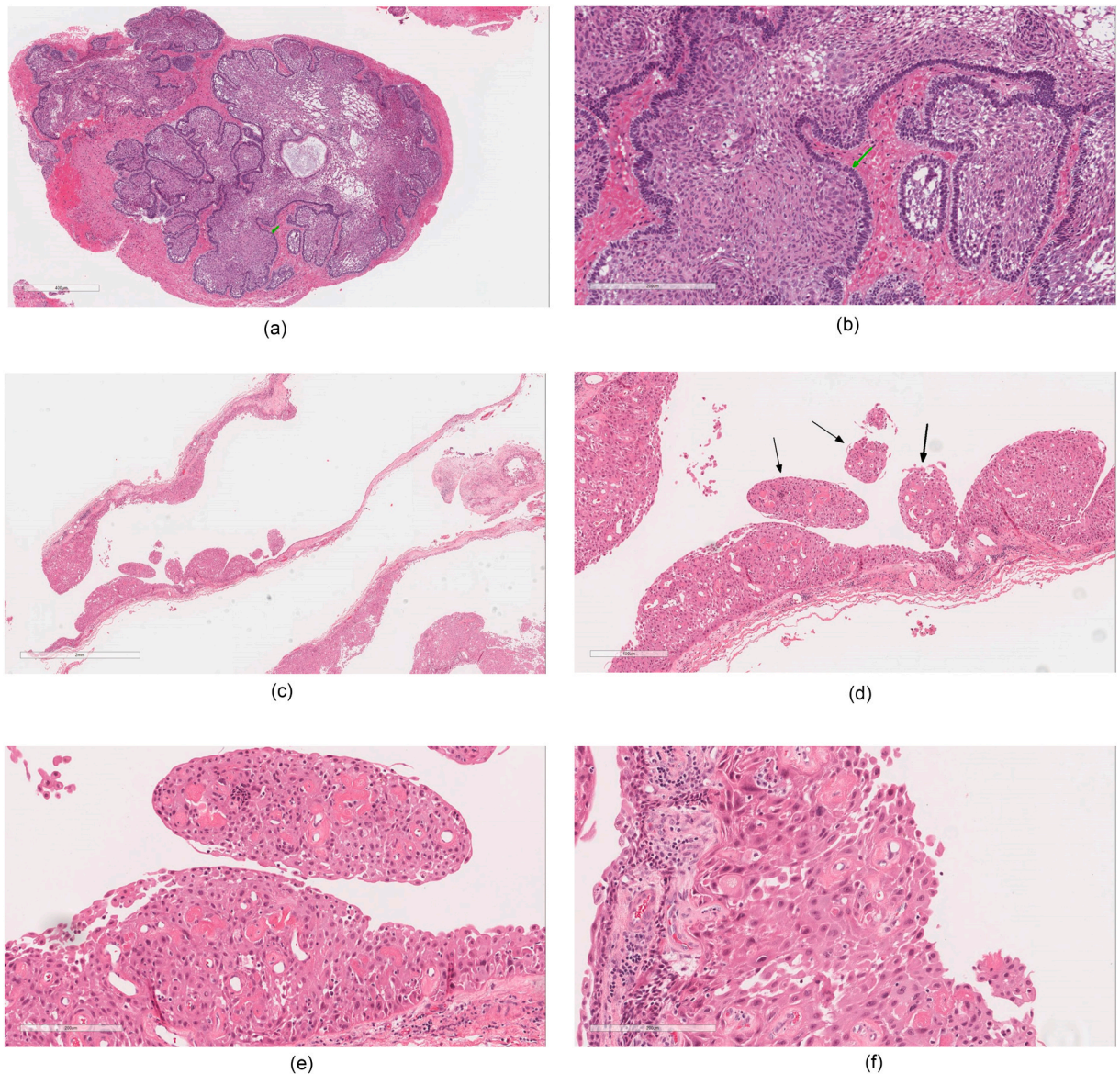
**Fig. 3.** A 36-year-old female with headache, short-term memory loss, and new-onset blurry vision. (A–C) Axial, coronal, and sagittal pre-operative brain MRI with contrast. (D–F) Axial, coronal, and sagittal post-operative brain MRI with contrast. (A–C) The images demonstrate an extra-axial sellar/suprasellar heterogeneously enhanced lesion. Multiple non-enhancing cystic changes as well as foci of calcifications are noted. The lesion is oval-shaped and measures approximately  $3.0 \times 3.7 \times 4.2$  cm along its maximum dimensions. The pituitary stalk is not visualized. The mass is significantly elevating the hypothalamus and the third ventricle. It is filling the interpeduncular fossa, splaying the cerebral peduncles and compressing the midbrain. However, there is no significant brainstem edema. The optic chiasm is also compressed and displaced superiorly. The vessels of the circle of Willis vessels are displaced rather than encased (D–F) Post-operative images demonstrating a complete resection of the lesion. Post-surgical changes, in the form of pneumocephalus and bifrontal subdural collections, are noted.

Surgery remains one of the most crucial therapeutic strategies to manage CP. Therefore, objectively navigating the multiple surgical approaches becomes critical for the patients' outcomes. Historically, Transcranial approaches have been the mainstay surgical management of craniopharyngioma. Recently, however, many different microsurgical and endoscopic approaches have been developed. Microscopic transsphenoidal approaches include sublabial, endonasal, transsphenoidal transsellar transdiaphragmatic, transsphenoidal transtuberulum sellae, endoscopic endonasal, anterior skull base endoscopic, endonasal transsphenoidal operative technique, and combined approaches. The orbitozygomatic, pterional, transpetrosal, transcortical-transventricular, and transcallosal-transventricular approaches are some of the suggested transcranial approaches. Previous literature showed a controversy in approach selection; in which, Surgeons preference and experience dominated the selection bias rather than objective measures.

General indications for transcranial approaches are cases of large intrasuprasellar dumbbell-shaped or exclusive suprasellar tumors, with extension toward the third ventricle and hypothalamus and the subfrontal, retrochiasmatic, and retrosellar regions. One indication for transsphenoidal surgery is patients with pituitary dysfunction [26].

A subclassification of CP was proposed by Morisako et al. to guide the surgical approach selection. The classification employs anatomical location, growth pattern, and origin of the CP. Four groups are defined including; the intrasellar, prechiasmatic, retrochiasmatic, and intra-third ventricle. The proposed indications for endoscopic transsphenoidal approach and extended transsphenoidal approach are intrasellar type, and prechiasmatic type without lateral extension, respectively. A transcranial approach such as the orbitozygomatic approach was indicated in cases of prechiasmatic type without lateral extension and small retrochiasmatic lesion type without extensive calcification. The mini-transpetrosal approach was proposed for the retrochiasmatic type with extensive calcification or a large diameter (>30 mm). For the intra-third ventricle type, however, the interhemispheric translamina terminalis approach was indicated [38].

In 2008, Kassam et al. discussed another four-type classification system which included; preinfundibular (Type I), transinfundibular (Type II), retroinfundibular (Type III), and isolated third ventricular or optic recess tumors (Type IV). Type III is further subdivided into; IIIa (extending into the third ventricle) and IIIb (extending into the interpeduncular cistern) [39]. Intrasellar craniopharyngiomas are added to this classification as Type 0 by Prevedello et al. According to Prevedello et al. classification, a standardized transplanum/transstuberulum endoscopic endonasal approach (EEA) is used for Types I, II, and III with or without a mild lateral extension or significant lateral extension of the cystic component. Moreover, in type IIIb lesions pituitary gland transposition should be minimized to hemi- or unilateral, in order to preserve the function [40].



**Fig. 4.** (A–B) Adamantinomatous craniopharyngioma at low power (A) surrounded by reactive brain parenchyma. At intermediate power (B) the palisading basal cells (green arrow) is recognized. (C–F) Papillary craniopharyngioma at low power (C–D) displaying cystic and papillary structures. The lining is comprised of a well-differentiated squamous epithelium as observed at intermediate power (E–F).

In type IV tumors, Prevedello et al., viewed expanded EEA as less favorable due to the narrow surgical corridor between the optic chiasm and pituitary gland. Thus, Type IV tumors approaches include; subfrontal/interhemispheric translamina terminalis, transcallosal transchoroidal, or transventricular transforaminal approach. The expanded EEA is recommended as an adjunct approach for residual lesions located caudally unattainable by previous transcranial approaches.

Morisako et al., on the other hand, propose that the EEA should be selected only for intrasellar (Type 0 Prevedello et al.'s classification) and prechiasmatic (without lateral extension) (Type I Kassam et al.'s classification). They also suggest orbitozygomatic or an anterior petrosal approach (when calcifications are present or tumor diameter is  $> 30$  mm) for "retrochiasmatic" craniopharyngioma. (Type II, and Type III Kassam et al.'s classification). The rationale behind selecting an endonasal approach for intrasellar and prechiasmatic tumors without lateral extension (Type 0 Prevedello et al.'s classification and Type I Kassam et al.'s classification), is due to the relative ease and safety of the procedure. Unlike the skills that are required to perform endoscopic retrochiasmatic (Type III Kassam et al.'s classification) tumor resection without complications [26,40].

## 10.2. Radiotherapy

The goal of radiotherapy (RT) is to treat residual disease after a partial surgical resection or to treat disease recurrence following a gross total resection [41]. Contemporary RT Treatment techniques include intensity-modulated RT (IMRT), image-guided radiation include stereotactic radiotherapy (SRT), and proton beam therapy (PBT). These techniques allow for better treatment precision and conformity, which lowers long-term toxicity by limiting ionized radiation exposure to surrounding normal tissues [41,42].

The popularity of Proton beam therapy as a management for malignancy has increased. PBT employs a linear accelerator to produce concentrated energy beams targeted at the malignant tissue [43]. Although clinical outcomes of PBT are comparable to IMRT, PBT has fewer complications and secondary cancer formation. This is attributable to PBT having potentially less brain and total body irradiation [44]. Intensity-modulated proton therapy (IMPT) is one of the most up-and-coming PBT for craniopharyngioma, however, the cost of IMPT is about double that of IMRT. IMPT utilizes variable proton energies and intensities to cover the target tissue. For patients with craniopharyngioma, the PBT 5-year local control rate ranges from 85 to 100 % [45].

Compared to lower doses, doses above 54–55 Gy markedly improve local tumor control [46]. Intracavitary irradiation has the added benefit of limited penetration of the emitted energy and relative ease of handling. Beta-emitting isotopes such as phosphorus-32 (P-32), yttrium-90 (Yt-90), rhenium-186 (Rh-186) and are preferred for the treatment of solitary or multi-cystic tumors [47,48]. The use of P-32 has reduced radiation delivery to the patient. Solo P-23, or in conjunction with other management, can successfully treat craniopharyngioma. Out of 129 craniopharyngioma managed with P-32 Brachytherapy, 56 cysts demonstrated resolution and/or non-recurrence [44]. According to Julow J et al. After Yt-90 treatment, the initial cyst volume reduction was 79 % on average. Moreover, in 27 of 60 patients, the cyst disappeared completely within a year. The mean survival after Yt-90 was 9.4 years and it ranged from 0.7 to 30 years. The anatomical location of the cyst was linked to the Yt-90 long-term complications. In 3.2 %, retrosellar location caused pontomesencephalothalamic and/or hypothalamic damage. A presellar location was related to neuro-ophthalmological consequence and internal carotid artery injury in 5.8 % and 1.6 %, respectively [49]. In the case of Rh-186, greater activity is required than that for P-32 and Yt-90. Moreover, Rh-186 emits an added dose outside the malignancy medium due to its gamma transition [50].

## 10.3. Chemotherapy

Chemotherapy is not a common management option for CP. In young patients, especially in cases with a single cyst and a small solid component, intracystic chemotherapy can be considered. Overall, chemotherapeutic agents like Bleomycin and Interferon alpha (IFN- $\alpha$ ) were used for temporary CP control but not considered a definitive management. Moreover, systemic chemotherapy is generally considered ineffective in cases of CP [51].

Intracavitary chemotherapy with Bleomycin and IFN- $\alpha$  is preferred in CP patients. Ensuring the patient had no previous history of leakage, they are administered via Ommaya reservoir [45,52,53]. Bleomycin has been observed to decrease tumor size in the majority of patients. However, due to its neurotoxicity and associated significant side effects such as sudden-onset cerebral edema and hypothalamic injury, its chemotherapeutic role has been limited [54,55]. According to Hukin, J. et al. the median progression-free survival for Bleomycin was 1.8 years (0.3–6.1 years) [56].

Recent results have demonstrated positive outcomes following IFN- $\alpha$  treatment for CP patients. It functions in the cystic craniopharyngioma by activating the Fas apoptotic pathway which reduces the cyst volume [57,58]. Bartels U et al. have shown that out of 60 patients treated with IFN- $\alpha$ , 78 % achieved disease control. In addition, 81 % of 37 patients had a greater than half cyst reduction [59]. The effective cyst fluid reduction in patients treated with IFN- $\alpha$  may delay the need for invasive surgical intervention and radiotherapy for several years, such delays allowing for neural and endocrine development in young patients [54].

### 10.3.1. Hormonal replacement

Endocrine abnormalities are usually due to the original tumor but they also can be aggravated by the treatment. In the majority of patients, panhypopituitarism is present, which can manifest as adrenal insufficiency, hypothyroidism, hypogonadism, and/or growth hormone deficiency [52]. Hypopituitarism is managed by substituting deficient hormones. According to the existing guidelines, Levothyroxine should be dosed sufficiently in order to achieve a mid-to-upper half free T4 range. Moreover, excessive replacement of Glucocorticoids should be avoided to decrease the chances of long-term sequelae [60,61]. Conversely, a daily dose of more than 25 mg of Hydrocortisone in patients with Adrenocorticotrophic Hormone deficiency has been linked to increased mortality compared to lower doses [62].

In childhood, GH replacement therapy is initiated in order to increase height without affecting overall survival [60]. The safety in regards to the risk of tumor recurrence, and the benefit of GH substitution on long-term body composition after craniopharyngioma are debated [60–63]. However, starting growth hormone therapy after one year of diagnosis may be linked to early improvement in quality of life [64].

In female pediatric patients, starting estrogen replacement therapy is recommended between the ages of 11 and 12 to simulate the average physiology, and it is increased at a 6-month interval until the patient reaches the adult replacement therapy. Due to a possible insufficient sex hormone supplementation, some female patients with craniopharyngioma have a lower bone mineral density than their counterparts [65]. In male pediatric patients, however, puberty is induced at age 12 to obtain a slow increase in serum steroids, and a monthly intramuscular injection of 25–50 mg of testosterone s increased every 6–12 months until the adult dose is achieved [23].

## 11. Prognosis

Tumor control and treatment-related complications have a tremendous effect on the long-term prognosis after treatment. An article found that out of 18 patients, 56 %, 33 %, and 11 % of the patients had a good outcome, poor outcome, and mortality, respectively [66]. In a series that measured the long-term outcomes and complications in patients with craniopharyngioma, the 10-year progression-free survival was 48 % and the overall survival rate was 80 % [60]. Despite this, patients without tumor progression, especially in childhood craniopharyngioma survivors, appear to have an increased late mortality and complications of treatment. One example is in a series composed of 41 craniopharyngioma patients managed over a 37-year period, there were nine overall deaths (22 %). The mortality in the four patients, out of nine, was not directly linked to tumor progression, three of the four occurred more than 20 years after the presentation, and one of them occurred between 10 and 20 years [67].

To date, long-term health related QoL in survivors of Craniopharyngioma has not been well established. Eveslage et al. observed the short-term QoL in survivors of CP. In the latter study, during the short-term follow up of 3 years after diagnosis of CP, patients who underwent gross total resection with injury to posterior hypothalamus found to have a significantly lower self and parent-assessed QoL. This outcome is attributable to decreased physical and emotional functioning due to disturbance of satiety regulation and energy expenditure following hypothalamic injury [68]. Poretti A et al. described the long-term quality of life in survivors of childhood-onset CP and reported that a reduction in emotional and social functioning is the most significant impairment affecting patients' quality of life [4]. Other behavioral studies mentioned that depression, anxiety and apathy are the most frequently observed psychopathological disorders in the long-term follow up of CP patients [69].

## 12. Complications

Multiple postoperative complications can occur following the management of craniopharyngioma which include cerebrospinal fluid (CSF) leak, hydrocephalus, meningitis, and cranial neuropathies. Hydrocephalus incident postoperatively is around 15 %–18 %, and meningitis is between 6 % and 12 %. One of the typically transient complications is cranial neuropathy, and it is seen in up to 20 % post-operatively [70–72].

Postoperative CSF leak rates range according to the approach utilized in craniopharyngioma resection. However, open transcranial approaches carry lower rates of postoperative CSF leaks [70].

Persistent postoperative visual disturbances in pediatric craniopharyngioma patients range from 48 to 75 %. Due to the transition towards an endonasal approach in recent years, the incidence of improvement in vision post-operatively is encouraging as they allow better visualization of the optic chiasm. However, reaching a complete normalization of vision remains challenging, with only 25–67 % of patients attaining normal vision postoperatively [70,73].

Endocrine complications follow craniopharyngioma treatment with both radiation and surgical approaches. New postoperative panhypopituitarism or new diabetes insipidus develop respectively in about 63.6 % and 46.7 % of patients, with a more significant effect in the pediatric population. In 64–80 % of pediatric patients, permanent diabetes insipidus is observed; however, in the immediate postoperative period, transient diabetes insipidus is the rule rather than the exception.

Another post-intervention endocrine complication is new hypothalamic obesity developing in 40–80 % of patients [70,72]. New hypothalamic obesity following craniopharyngioma resection is due to multiple factors that might be attributable to pituitary dysfunction, steroid replacement, or hypothalamic injury [70].

## 13. Recurrence

Factors affecting the recurrence rate (RR) of craniopharyngioma remain unclear. Šteňo et al. assessed the RR of 38 children and 63 adults. They found that the RR reached 39.5 % and 22.2 %, respectively [74]. A number of studies have shown that the 10-year RR following gross total resection is 0–50 % and 25–100 % with subtotal resection (STR). In comparison to STR solely, STR combined with radiation has demonstrated a decrease in tumor recurrence from 55 to 85 to 0–20 % [70].

## 14. Malignant transformation of craniopharyngioma

Malignant CP was first described in 1973 as a de novo squamous carcinoma arising from an intrasellar epidermal cyst [75]. Malignant transformation of CP is extremely rare and generally arises from an adamantinomatous subtype (73 %) [76,77]. Malignant CP appears to present the following features: (i) marked nuclear atypia; (ii) a high nucleus-to-cytoplasm ratio; (iii); robust mitotic activity; and (iv) other histologic features such as solid growth pattern, destruction of the basement membrane, infiltrative growth, microvascular proliferation and so on [77,78]. The etiology and pathogenesis of malignant CP are unclear, though some authors presumed a probable correlation with radiotherapy [78]. The patients' ages ranged from 2.7 to 66 years (31.11 years), with an equal incidence rate for females and males. There are no unique radiological features of malignant CP and can appear as a mixed solid and cystic component [77]. The few case reports published in the literature demonstrated high morbidity and mortality rates [78].

## 15. Future perspective

In the future, chemotherapeutic agents will be the preferred therapeutic tool in the management of craniopharyngioma [79]. The identification of a BRAF mutation in papillary craniopharyngioma has revealed that chemotherapeutic agents can be an effective



treatment option and part of the multimodal therapeutic management of this tumor. The chemotherapeutic approach helps to minimize the hypothalamic tissue damage during the surgical resection by shrinking the tumor size and isolating it away from the hypothalamus [80]. In one reported case, the molecularly targeted use of the BRAF inhibitor such as vemurafenib showed a prompt and excellent tumor response which supports the pathogenic role of the BRAFV600E mutation in papillary craniopharyngioma. The promising results of vemurafenib in this case necessitate further clinical trials on the long-term effects and represent a possible paradigm shift in the therapeutic management of craniopharyngioma [79]. Patients with the papillary craniopharyngioma subtype may immediately benefit from targeted therapy, whereas further studies are highly anticipated to provide more information about the molecular targeted therapies of the adamantinomatous craniopharyngioma subtype [81].

## 16. Our experience

Our center is a tertiary-care center receiving referral for complex craniopharyngioma cases from all over the country. A collaboration between Neurosurgeons, Endocrinologists, Radiotherapists, and Oncologists takes place to discuss craniopharyngioma cases, plan treatment, and predict their outcomes. Post-operatively, all patients are followed-up clinicoradiologically to assess for possible recurrence and/or malignant transformation. In our practice, craniopharyngioma is managed both endoscopically and micro-surgically, depending on the size of the tumor, extension to surrounding vascular structures, and possibility of residual post-operatively.

## 17. Conclusion

Craniopharyngioma is a rare intracranial tumor that requires case-tailored management strategies with minimal consequences for both the disease and its treatment. Multi-disciplinary care is required in order to provide optimal management to patients with craniopharyngioma. The present article helps to identify further research areas that set the basis for the management of such a complex tumor.

### Compliance with Ethical standards

Research involving Human Participants and/or Animals.

Not applicable. The present article is a comprehensive review that does not involve human participants and/or animals.

### Informed consent

Not applicable. The present article is a comprehensive review that does not require informed consent.

### Funding

The authors would like to acknowledge King >Abdullah International Medical Research Center for funding the article.

### CRedit authorship contribution statement

**Maryam Nashi Alboqami:** Writing – review & editing, Writing – original draft. **Arwa Khalid S Albaiahy:** Writing – review & editing, Writing – original draft. **Bushra Hatim Bukhari:** Writing – review & editing, Writing – original draft. **Ali Alkhaibary:** Writing – review & editing, Writing – original draft, Visualization, Project administration, Methodology, Investigation, Conceptualization. **Ahoud Alharbi:** Writing – review & editing, Writing – original draft. **Sami Khairy:** Writing – review & editing, Writing – original draft, Supervision, Conceptualization. **Ali H. Alassiri:** Writing – original draft, Visualization, Investigation. **Fahd ALSufiani:** Writing – original draft, Visualization, Investigation. **Ahmed Alkhani:** Writing – review & editing, Supervision. **Ahmed Aloraidi:** Writing – review & editing, Supervision.

### Declaration of competing interest

The authors declare that they have no known competing financial interests or personal relationships that could have appeared to influence the work reported in this paper.

### Acknowledgments

None.

### References

- [1] G.R. Bunin, T.S. Surawicz, P.A. Witman, S. Preston-Martin, F. Davis, J.M. Bruner, The descriptive epidemiology of craniopharyngioma, *J. Neurosurg.* 89 (4) (1998) 547–551, <https://doi.org/10.3171/jns.1998.89.4.0547>.

- [2] D. Figarella-Branger, R. Appay, A. Metais, A. Tauziède-Espariat, C. Colin, A. Rousseau, P. Varlet, The 2021 WHO classification of tumours of the central nervous system. *Annales de Pathologie*. <https://doi.org/10.1016/j.annpat.2021.11.005>, 2021.
- [3] N. Karavitaki, S. Cudlip, C.B. Adams, J.A. Wass, Craniopharyngiomas, *Endocr. Rev.* 27 (4) (2006) 371–397, <https://doi.org/10.1210/er.2006-0002>.
- [4] A. Poretti, M.A. Grotzer, K. Ribbi, E. Schönle, E. Boltshauser, Outcome of craniopharyngioma in children: long-term complications and quality of life, *Dev. Med. Child Neurol.* 46 (4) (2004) 220–229, <https://doi.org/10.1017/S0012162204000374>.
- [5] Z. Zhou, S. Zhang, F. Hu, Endocrine disorder in patients with craniopharyngioma, *Front. Neurol.* 12 (2021) 737743, <https://doi.org/10.3389/fneur.2021.737743>.
- [6] A.J. Raimondi, J. Rougerie, A critical review of personal experiences with craniopharyngioma: clinical history, surgical technique and operative results, *Pediatr. Neurosurg.* 21 (2) (2008) 134–154, <https://doi.org/10.1159/000120827>.
- [7] J. Erdheim, Über Hypophysenganggeschwulste und Hirncholesteatome, *Sitzungsber Akad Wiss Wien* 113 (1904) 537–726, [scholar.google.com/scholar\\_lookup?&title=Über%20hypophysenganggeschwulste%20und%20hirncholesteatome&publication\\_year=1904&author=Erdheim%20CJ](https://scholar.google.com/scholar_lookup?&title=Über%20hypophysenganggeschwulste%20und%20hirncholesteatome&publication_year=1904&author=Erdheim%20CJ).
- [8] W. Susman, Embryonic epithelial rests in the pituitary, *Br. J. Surg.* 19 (76) (1932) 571–576, <https://doi.org/10.1002/bjs.1800197607>.
- [9] A.E. Halstead, Remarks on the operative treatment of tumors of the hypophysis, *Surg. Gynecol. Obstet.* 10 (1910) 494–502, <https://cir.nii.ac.jp/crid/1571698599624541312>.
- [10] H. Cushing, Intracranial Tumors, Charles C Thomas, Baltimore, 1932. [https://journals.lww.com/jonmd/Citation/1932/11000/Intracranial\\_Tumours.86.aspx](https://journals.lww.com/jonmd/Citation/1932/11000/Intracranial_Tumours.86.aspx).
- [11] H. Cushing, The craniopharyngioma. Intracranial tumours, London: Bailliere, Tindall and Cox (1932) 93–98. <https://cir.nii.ac.jp/crid/1572261549577961600>.
- [12] E.H. Nielsen, U. Feldt-Rasmussen, L. Poulsgaard, L. Kristensen, J. Astrup, J.O. Jørgensen, P. Laurberg, Incidence of craniopharyngioma in Denmark (n = 189) and estimated world incidence of craniopharyngioma in children and adults, *J. Neuro Oncol.* 104 (3) (2011) 755–763, <https://doi.org/10.1007/s11060-011-0540-6>.
- [13] Q.T. Ostrom, H. Gittleman, P. Liao, T. Vecchione-Koval, Y. Wolinsky, C. Kruchko, J.S. Barnholtz-Sloan, CBRUS Statistical Report: primary brain and other central nervous system tumors diagnosed in the United States in 2010–2014, *Neuro Oncol.* 19 (5) (2017) v1–v88, <https://doi.org/10.1093/neuonc/nox158>.
- [14] R. Haupt, C. Magnani, M. Pavenello, S. Caruso, E. Dama, M.L. Garré, Epidemiological aspects of craniopharyngioma, *Journal of Pediatric Endocrinology and Metabolism* 19 (SUPPL. 1) (2006) 289–293. [https://www.academia.edu/download/40925621/haupt\\_et\\_al\\_Epidemiology\\_of\\_Craniopharyngioma.pdf](https://www.academia.edu/download/40925621/haupt_et_al_Epidemiology_of_Craniopharyngioma.pdf).
- [15] H.L. Müller, T.E. Merchant, M. Warmuth-Metz, J.P. Martinez-Barbera, S. Puget, Craniopharyngioma, *Nat. Rev. Dis. Prim.* 5 (1) (2019) 75, <https://doi.org/10.1038/s41572-019-0125-9>.
- [16] D.N. Louis, A. Perry, P. Wesseling, D.J. Brat, I.A. Cree, D. Figarella-Branger, D.W. Ellison, The 2021 WHO classification of tumors of the central nervous system: a summary, *Neuro Oncol.* 23 (8) (2021) 1231–1251, <https://doi.org/10.1093/neuonc/noab106>.
- [17] M.L. Garré, A. Cama, Craniopharyngioma: Modern concepts in pathogenesis and treatment, *Curr. Opin. Pediatr.* (2007, August), <https://doi.org/10.1097/MOP.0b013e3282495a22>.
- [18] P. Nozza, C. Gambini, Paediatric craniopharyngioma: a pathological review, *Journal of Pediatric Endocrinology and Metabolism* (2006). <https://moh-it.pure.elsevier.com/en/publications/paediatric-craniopharyngioma-a-pathological-review>.
- [19] D.C. Miller, Pathology of: clinical import of pathological findings, *Pediatr. Neurosurg.* 21 (1994) 11–17, <https://doi.org/10.1159/000120855>.
- [20] S. Sartoretti-Schefer, W. Wichmann, A. Aguzzi, A. Valavanis, MR differentiation of adamantinoid and squamous-papillary craniopharyngiomas, *Am. J. Neuroradiol.* 18 (1) (1997) 77–87. <http://www.ajnr.org/content/18/1/77.short>.
- [21] K. Sato, H. Oka, S. Utsuki, K. Kondo, A. Kurata, K. Fujii, Ciliated craniopharyngioma may arise from Rathke cleft cyst, *Clin. Neuropathol.* 25 (1) (2006) 25–28. <https://pubmed.ncbi.nlm.nih.gov/16465771/>.
- [22] G.R. Bunin, T.S. Surawicz, P.A. Witman, S. Preston-Martin, F. Davis, J.M. Bruner, The descriptive epidemiology of craniopharyngioma, *J. Neurosurg.* 89 (4) (1998) 547–551, <https://doi.org/10.3171/jns.1998.89.4.0547>.
- [23] H.L. Müller, The diagnosis and treatment of Craniopharyngioma, *Neuroendocrinology* 110 (9–10) (2019) 753–766, <https://doi.org/10.1159/000504512>.
- [24] M.A. Nuijts, N. Veldhuis, I. Stegeman, H.M. van Santen, G.L. Porro, S.M. Imhof, A.Y. Schouten-van Meeteren, Visual functions in children with craniopharyngioma at diagnosis: a systematic review, *PLoS One* 15 (10) (2020) e0240016, <https://doi.org/10.1371/journal.pone.0240016>.
- [25] H.L. Müller, Craniopharyngioma, *Endocr. Rev.* 35 (3) (2014) 513–543, <https://doi.org/10.1210/er.2013-1115>.
- [26] A. Lania, A. Spada, G. Lasio (Eds.), *Diagnosis and Management of Craniopharyngiomas*, Springer International Publishing, 2016, <https://doi.org/10.1007/978-3-319-22297-4>.
- [27] C.-C. Huang, K.-L. Lin, C.-T. Wu, S.-M. Jung, C.-J. Wang, Y.-C. Chen, F.-S. Lo, Clinical and endocrinological manifestations of childhood-onset craniopharyngioma before surgical removal: a report from one medical center in Taiwan, *Pediatrics & Neonatology* 62 (2) (2021) 181–186, <https://doi.org/10.1016/j.pedneo.2020.08.014>.
- [28] C. Dandurand, A.A. Sepehry, M.H. Asadi Lari, R. Akagami, P. Gooderham, Adult craniopharyngioma: case series, systematic review, and Meta-analysis, *Neurosurgery* 83 (4) (2017) 631–641, <https://doi.org/10.1093/neuros/nyx570>.
- [29] H.L. Müller, Management of endocrine disease: childhood-onset craniopharyngioma: state of the art of care in 2018, *Eur. J. Endocrinol.* 180 (4) (2019) R159–R174, <https://doi.org/10.1530/eje-18-1021>.
- [30] B.M. Lehrich, K. Goshtasbi, F.P.K. Hsu, E.C. Kuan, Characteristics and overall survival in pediatric versus adult craniopharyngioma: a population-based study, *Child's Nerv. Syst.* 37 (5) (2021) 1535–1545, <https://doi.org/10.1007/s00381-021-05094-y>.
- [31] H. Takami, C. Velásquez, M.J. Asha, S. Oswari, J.P. Almeida, F. Gentili, Creative and innovative methods and techniques for the Challenges in the management of adult craniopharyngioma, *World neurosurgery* 142 (2020) 601–610, <https://doi.org/10.1016/j.wneu.2020.05.173>.
- [32] S. Yamada, N. Fukuhara, M. Yamaguchi-Okada, H. Nishioka, A. Takeshita, Y. Takeuchi, N. Inoshita, J. Ito, Therapeutic outcomes of transsphenoidal surgery in pediatric patients with craniopharyngiomas: a single-center study, *J. Neurosurg. Pediatr.* 21 (6) (2018) 549–562, <https://doi.org/10.3171/2017.10.PEDS17254>.
- [33] K.W. Jo, H.J. Shin, D.S. Kong, H.J. Seol, D.H. Nam, J.I. Lee, Treatment outcomes of pediatric craniopharyngioma: a 15-year retrospective review of 35 cases, *Journal of Korean Neurosurgical Society* 52 (1) (2012) 37–41, <https://doi.org/10.3340/jkns.2012.52.1.37>.
- [34] E.T. Hidalgo, C. Orillac, S. Kvint, M.W. McQuinn, Y. Dastagirzada, S. Phillips, J.H. Wisoff, Quality of life, hypothalamic obesity, and sexual function in adulthood two decades after primary gross-total resection for childhood craniopharyngioma, *Child's nervous system: ChNS: official journal of the International Society for Pediatric Neurosurgery* 36 (2) (2020) 281–289, <https://doi.org/10.1007/s00381-019-04161-9>.
- [35] S. Fjalldal, C. Follin, S. Gabery, P.C. Sundgren, I.M. Björkman-Burtscher, J. Lätt, P. Mannfolk, C.H. Nordström, L. Rylander, B. Ekman, R. Cheong, A. Pålsson, Å. Petersén, E.M. Erfurth, Detailed assessment of hypothalamic damage in craniopharyngioma patients with obesity, *Int. J. Obes.* 43 (3) (2019) 533–544, <https://doi.org/10.1038/s41366-018-0185-z>.
- [36] M. Koutourousiou, J.C. Fernandez-Miranda, E.W. Wang, C.H. Snyderman, P.A. Gardner, The limits of transsellar/trans-tuberulum surgery for craniopharyngioma, *J. Neurosurg.* 122 (3) (2018) 301–309, <https://doi.org/10.23736/S0390-5616.18.04376-X>.
- [37] E. Elowe-Gruau, J. Beltrand, R. Brauner, G. Pinto, D. Samara-Boustani, C. Thalassinos, K. Busiah, K. Laborde, N. Bodaert, M. Zerah, C. Alapetite, J. Grill, P. Touraine, C. Sainte-Rose, M. Polak, S. Puget, Childhood craniopharyngioma: hypothalamus-sparing surgery decreases the risk of obesity, *The Journal of clinical endocrinology and metabolism* 98 (6) (2013) 2376–2382, <https://doi.org/10.1210/jc.2012-3928>.
- [38] H. Morisako, T. Goto, H. Goto, C.A. Bohoun, S. Tamrakar, K. Ohata, Aggressive surgery based on an anatomical subclassification of craniopharyngiomas, *Neurosurg. Focus* 41 (6) (2016) E10, <https://doi.org/10.3171/2016.9.FOCUS16211>.
- [39] A.B. Kassam, P.A. Gardner, C.H. Snyderman, R.L. Carrau, A.H. Mintz, D.M. Prevedello, Expanded endonasal approach, a fully endoscopic transnasal approach for the resection of midline suprasellar craniopharyngiomas: a new classification based on the infundibulum, *J. Neurosurg.* 108 (4) (2008) 715–728, <https://doi.org/10.3171/JNS/2008/108/4/0715>.
- [40] A. Beer-Furlan, A.O. Jamshidi, R.L. Carrau, D.M. Prevedello, Letter to the Editor. Surgical strategy for craniopharyngiomas and the tumor-infundibulum relationship, *Neurosurg. Focus* 43 (1) (2017) E8, <https://doi.org/10.3171/2017.3.FOCUS17180>.

- [41] G. Minniti, V. Esposito, M. Amichetti, R.M. Enrici, The role of fractionated radiotherapy and radiosurgery in the management of patients with craniopharyngioma, *Neurosurg. Rev.* 32 (2) (2009) 125–132, <https://doi.org/10.1007/s10143-009-0186-4>.
- [42] A.J. Bishop, B. Greenfield, A. Mahajan, A.C. Paulino, M.F. Okcu, P.K. Allen, M. Chintagumpala, L.S. Kahalley, M.F. McAleer, S.L. McGovern, W.E. Whitehead, D. R. Grosshans, Proton beam therapy versus conformal photon radiation therapy for childhood craniopharyngioma: multi-institutional analysis of outcomes, cyst dynamics, and toxicity, *Int. J. Radiat. Oncol. Biol. Phys.* 90 (2) (2014) 354–361, <https://doi.org/10.1016/j.ijrobp.2014.05.051>.
- [43] M. Hu, L. Jiang, X. Cui, et al., Proton beam therapy for cancer in the era of precision medicine, *J. Hematol. Oncol.* 11 (2018) 136, <https://doi.org/10.1186/s13045-018-0683-4>.
- [44] M. Lara-Velazquez, Y. Mehkri, E. Panther, J. Hernandez, D. Rao, P. Fiester, R. Makary, M. Rutenberg, D. Tavanaiepour, G. Rahmathulla, Current advances in the management of adult craniopharyngiomas, *Curr. Oncol.* 29 (3) (2022) 1645–1671, <https://doi.org/10.3390/curroncol29030138>.
- [45] L. O'steen, D.J. Indelicato, Advances in the management of craniopharyngioma, *F1000Research* 7 (2018), <https://doi.org/10.12688/f1000research.15834.1>. F1000 Faculty Rev-1632.
- [46] J.M. Varlotto, J.C. Flickinger, D. Kondziolka, L.D. Lunsford, M. Deutsch, External beam irradiation of craniopharyngiomas: long-term analysis of tumor control and morbidity, *Int. J. Radiat. Oncol. Biol. Phys.* 54 (2) (2002) 492–499, [https://doi.org/10.1016/s0360-3016\(02\)02965-6](https://doi.org/10.1016/s0360-3016(02)02965-6).
- [47] X. Yu, S.M. Christ, R. Liu, Y. Wang, C. Hu, B. Feng, A. Mahadevan, E.M. Kasper, Evaluation of long-term outcomes and toxicity after stereotactic phosphorus-32-based intracavitary brachytherapy in patients with cystic craniopharyngioma, *Int. J. Radiat. Oncol. Biol. Phys.* 111 (3) (2021) 773–784, <https://doi.org/10.1016/j.ijrobp.2021.05.123>.
- [48] R.B. Barriger, A. Chang, S.S. Lo, R.D. Timmerman, C. DesRosiers, J.C. Boaz, A.J. Fakiris, Phosphorus-32 therapy for cystic craniopharyngiomas, *Radiother. Oncol. : journal of the European Society for Therapeutic Radiology and Oncology* 98 (2) (2011) 207–212, <https://doi.org/10.1016/j.radonc.2010.12.001>.
- [49] J. Julow, E.O. Backlund, F. Lányi, M. Hajda, K. Bálint, I. Nyáry, G.T. Szeifert, Long-term results and late complications after intracavitary yttrium-90 colloid irradiation of recurrent cystic craniopharyngiomas, *Neurosurgery* 61 (2) (2007) 288–296, <https://doi.org/10.1227/01.NEU.0000255528.68963.EF>.
- [50] M. Sadeghi, E. Karimi, S.H. Hosseini, Dosimetric comparison of 90Y, 32P, and 186Re radiocolloids in craniopharyngioma treatments, *Medical physics* 36 (11) (2009) 5022–5026, <https://doi.org/10.1118/1.3243085>.
- [51] F. Zoicas, C. Schöfl, Craniopharyngioma in adults, *Front. Endocrinol.* 3 (2012) 46, <https://doi.org/10.3389/fendo.2012.00046>.
- [52] S. Zhang, Y. Fang, B.W. Cai, J.G. Xu, C. You, Intracystic bleomycin for cystic craniopharyngiomas in children, *Cochrane Database Syst. Rev.* 7 (7) (2016) CD008890, <https://doi.org/10.1002/14651858.CD008890.pub4>.
- [53] F. Frio, D. Solari, L.M. Cavallo, P. Cappabianca, G. Raverot, E. Jouanneau, Ommaya Reservoir system for the treatment of cystic craniopharyngiomas: surgical results in a series of 11 adult patients and review of the literature, *World Neurosurgery* 132 (2019), <https://doi.org/10.1016/j.wneu.2019.07.217>.
- [54] A.C. Hengartner, E. Prince, T. Vijmasi, T.C. Hankinson, Adamantinomatous craniopharyngioma: moving toward targeted therapies, *Neurosurg. Focus* 48 (1) (2020) E7, <https://doi.org/10.3171/2019.10.FOCUS19705>.
- [55] H. Takahashi, F. Yamaguchi, A. Teramoto, Long-term outcome and reconsideration of intracystic chemotherapy with bleomycin for craniopharyngioma in children, *Child's nervous system : ChNS : official journal of the International Society for Pediatric Neurosurgery* 21 (8–9) (2005) 701–704, <https://doi.org/10.1007/s00381-005-1208-3>.
- [56] J. Hukin, P. Steinbok, L. Lafay-Cousin, G. Henderson, D. Strother, C. Mercier, Y. Samson, W. Howes, E. Bouffet, Intracystic bleomycin therapy for craniopharyngioma in children, *Cancer* 109 (10) (2007) 2124–2131, <https://doi.org/10.1002/ncr.22633>.
- [57] P.A. Dastoli, J.M. Niciáo, N.S. Silva, A.M. Capellano, S.R. Toledo, D. Ierardi, S. Cavalheiro, Cystic craniopharyngioma: intratumoral chemotherapy with alpha interferon, *Arquivos de neuro-psiquiatria* 69 (1) (2011) 50–55, <https://doi.org/10.1590/s0004-282x2011000100011>.
- [58] J. Sharma, C.M. Bonfield, A. Singhal, J. Hukin, P. Steinbok, Intracystic interferon- $\alpha$  treatment leads to neurotoxicity in craniopharyngioma: case report, *J. Neurosurg. Pediatr.* 16 (3) (2015) 301–304, <https://doi.org/10.3171/2015.2.PEDS14656>.
- [59] U. Bartels, N. Laperriere, E. Bouffet, J. Drake, Intracystic therapies for cystic craniopharyngioma in childhood, *Front. Endocrinol.* 3 (2012 Mar 27) 39, <https://doi.org/10.3389/fendo.2012.00039>. PMID: 22654864; PMCID: PMC3356106.
- [60] S. Boekhoff, A. Bogusz, A.S. Sterkenburg, M. Eveslage, H.L. Müller, Long-term effects of growth hormone replacement therapy in childhood-onset craniopharyngioma: results of the German craniopharyngioma Registry (HIT-Endo), *Eur. J. Endocrinol.* 179 (5) (2018) 331–341.
- [61] M. Fleseriu, I.A. Hashim, N. Karavitaki, S. Melmed, M.H. Murad, R. Salvatori, M.H. Samuels, Hormonal replacement in hypopituitarism in adults: an endocrine Society clinical practice guideline, *The Journal of clinical endocrinology and metabolism* 101 (11) (2016) 3888–3921, <https://doi.org/10.1210/jc.2016-2118>.
- [62] M. Sherlock, R.C. Reulen, A.A. Alonso, J. Ayuk, R.N. Clayton, M.C. Sheppard, P.M. Stewart, A.C.T.H. deficiency, higher doses of hydrocortisone replacement, and radiotherapy are independent predictors of mortality in patients with acromegaly, *J. Clin. Endocrinol. Metab.* 94 (11) (2009) 4216–4223, <https://doi.org/10.1210/jc.2009-1097>.
- [63] K.C. Yuen, M. Koltowska-Häggström, D.M. Cook, J.L. Fox, P.J. Jönsson, M.E. Geffner, R. Abs, Clinical characteristics and effects of GH replacement therapy in adults with childhood-onset craniopharyngioma compared with those in adults with other causes of childhood-onset hypothalamic-pituitary dysfunction, *Eur. J. Endocrinol.* 169 (4) (2013) 511–519, <https://doi.org/10.1530/EJE-13-0280>.
- [64] K. Heinks, S. Boekhoff, M. Warmuth-Metz, M. Eveslage, J. Peng, G. Calaminus, H.L. Müller, CRAN-01. Quality OF life and growth after childhood craniopharyngioma: results OF the MULTINATIONAL TRIAL KRANIOPHARYNGEOM 2007, *Neuro Oncol.* 20 (Suppl 2) (2018) i36, <https://doi.org/10.1093/neuonc/ny059.038>.
- [65] H. Holmer, V. Popovic, B. Ekman, C. Follin, A.B. Siversson, E.M. Erfurth, Hypothalamic involvement and insufficient sex steroid supplementation are associated with low bone mineral density in women with childhood onset craniopharyngioma, *Eur. J. Endocrinol.* 165 (2011) 25–31, <https://doi.org/10.1530/EJE-11-0229>.
- [66] S.M. Elwatidy, Z.A. Jamjoom, A.B. Jamjoom, A.O. Yakoub, Craniopharyngioma: analysis of factors that affect the outcome, *Neurosciences* 7 (1) (2002) 27–31.
- [67] J. Visser, J. Hukin, M. Sargent, P. Steinbok, K. Goddard, C. Fryer, Late mortality in pediatric patients with craniopharyngioma, *Journal of neuro-oncology* 100 (1) (2010) 105–111, <https://doi.org/10.1007/s11060-010-0145-5>.
- [68] M. Eveslage, G. Calaminus, M. Warmuth-Metz, R.D. Kortmann, F. Pohl, B. Timmermann, M.U. Schuhmann, J. Flitsch, A. Faldum, H.L. Müller, The Postoperative quality of life in children and Adolescents with craniopharyngioma, *Deutsches Arzteblatt international* 116 (18) (2019) 321–328, <https://doi.org/10.3238/arztebl.2019.0321>.
- [69] A. Mehren, J. Özyurt, P. zu Klampen, S. Boekhoff, C.M. Thiel, H.L. Müller, Self- and informant-rated apathy in patients with childhood-onset craniopharyngioma, *J. Neuro Oncol.* 140 (1) (2018) 27–35, <https://doi.org/10.1007/s11060-018-2936-z>.
- [70] A. Drapeau, P.C. Walz, J.G. Eide, et al., Pediatric craniopharyngioma, *Childs Nerv Syst* 35 (2019) 2133–2145, <https://doi.org/10.1007/s00381-019-04300-2>.
- [71] S. Chivukula, M. Koutourousiou, C.H. Snyderman, J.C. Fernandez-Miranda, P.A. Gardner, E.C. Tyler-Kabara, Endoscopic endonasal skull base surgery in the pediatric population, *J. Neurosurg. Pediatr.* 11 (3) (2013) 227–241, <https://doi.org/10.3171/2012.10.PEDS12160>.
- [72] V.S. Patel, A. Thamboo, J. Quon, J.V. Nayak, P.H. Hwang, M. Edwards, Z.M. Patel, Outcomes after endoscopic endonasal resection of craniopharyngiomas in the pediatric population, *World Neurosurgery* 108 (2017) 6–14, <https://doi.org/10.1016/j.wneu.2017.08.058>.
- [73] H.L. Müller, Chapter 16 - craniopharyngioma, *Handb. Clin. Neurol.* 124 (2014) 235–253.
- [74] J. Šteňo, I. Bízík, A. Šteňo, V. Matejíček, Recurrent craniopharyngiomas in children and adults: long-term recurrence rate and management, *Acta neurochirurgica* 156 (1) (2014) 113–122, <https://doi.org/10.1007/s00701-013-1938-z>.
- [75] D. Salyer, D. Carter, Squamous carcinoma arising in the pituitary gland, *Cancer* 31 (3) (1973) 713–718.
- [76] T.S. Jeong, G.T. Yee, N.R. Kim, Malignant transformation of craniopharyngioma without radiation therapy: case report and review of the literature, *Journal of Korean Neurosurgical Society* 60 (1) (2017) 108–113, <https://doi.org/10.3340/jkns.2015.0707.022>.
- [77] T. Elarjani, M.R. Alhuthayl, H. Alhindi, I.N. Kanaan, The effect of radiation therapy and chemotherapy on malignant craniopharyngioma: a review, *Surg. Neurol. Int.* 12 (2021) 539, <https://doi.org/10.25259/sni.664.2021>.
- [78] W. Wang, X.D. Chen, H.M. Bai, Q.L. Liao, X.J. Dai, D.Y. Peng, H.X. Cao, Malignant transformation of craniopharyngioma with detailed follow-up, *Neuropathology* 35 (1) (2014) 50–55, <https://doi.org/10.1111/neup.12142>.

- [79] G.D. Reddy, D. Hansen, A. Patel, Y. Lin, A. Jea, S. Lam, Treatment options for pediatric craniopharyngioma, *Surg. Neurol. Int.* 7 (Suppl 6) (2016) S174–S178, <https://doi.org/10.4103/2152-7806.178570>.
- [80] P.K. Brastianos, A. Taylor-Weiner, P.E. Manley, R.T. Jones, D. Dias-Santagata, A.R. Thorner, S. Santagata, Exome sequencing identifies BRAF mutations in papillary craniopharyngiomas, *Nat. Genet.* 46 (2) (2014) 161–165, <https://doi.org/10.1038/ng.2868>.
- [81] E. Rostami, O. Casar-Borota, O. Gudjonsson, Molecular targets in craniopharyngioma, in: *Adult Craniopharyngiomas: Differences and Lessons from Paediatrics*, Springer International Publishing, 2020, pp. 209–221, [https://doi.org/10.1007/978-3-030-41176-3\\_12](https://doi.org/10.1007/978-3-030-41176-3_12).