



Contents lists available at ScienceDirect

International Journal of Surgery Case Reports

journal homepage: www.casereports.com

Rib osteochondroma causing cardiac compression in a pediatric patient

Abdulaziz Sami Alnassar*

Dar Al Uloom University, Al Falah, Riyadh 13314, Saudi Arabia

ARTICLE INFO

Article history:

Received 17 February 2021

Received in revised form 10 March 2021

Accepted 10 March 2021

Available online 14 March 2021

Keywords:

Osteochondroma

Rib exostosis

Video-assisted

Thoracoscopy

Cardiac compression

ABSTRACT

INTRODUCTION AND IMPORTANCE: Rib osteochondromas are rare genetic disorders, which can present as bony exostosis causing compression, impingement and damage to surrounding vessels, organs and structures within the thoracic cavity. The objective of this study was to clearly describe a rare presentation of rib osteochondromas in a pediatric patient along with managing techniques.

CASE: A 9-year-old girl was admitted to the hospital due to shortness of breath on exertion. Physical examination did not reveal any abnormalities except for small bony projections over the left 5th rib. Computed tomography (CT) scan showed a bony lesion on the left fifth rib causing cardiac compression. Video-assisted thoracoscopy (VAT) was done, which showed a bony exostosis compressing the left ventricle, the lesion was resected without any complications. Final pathology confirmed the diagnosis of osteochondroma measuring 2.0 cm × 2.0 cm × 1.5 cm, along with a thickness of 0.4 cm. Post-operative recovery was well, with no morbidities and the patient was discharged without any complications. On the post-operative follow up, the patient showed significant improvement in her symptoms.

CLINICAL DISCUSSION: Our reported case is a rare example of a solitary costal osteochondroma leading to serious complications because of its shape, size, and location. Previous reports have not addressed any significant traumatic event or impact prior to the occurrence of symptoms related to the cases, including the case of our patient. Cases of rib exostosis were surgically approached using different techniques most often through thoracotomy.

CONCLUSIONS: Rib osteochondromas are rare benign bony lesions which can cause cardiac symptoms secondary to direct compression. They can be resected safely via video assisted thoracoscopy (VAT) or limited thoracotomy.

© 2021 Published by Elsevier Ltd on behalf of IJS Publishing Group Ltd. This is an open access article under the CC BY-NC-ND license (<http://creativecommons.org/licenses/by-nc-nd/4.0/>).

1. Introduction

The work has been reported in line with the SCARE criteria. Costal osteochondroma (CO) is a benign growth within the rib characterized by an abnormal bony protrusion with a cartilaginous cap, which is usually asymptomatic [1,2]. Osteochondromas are rare genetic disorders involving Exostosin-1 (EXT1) and Exostosin-2 (EXT2) genes that have an incidence of nearly one in 50,000 [3,4]. They can occur either sporadically or as a part of Hereditary multiple osteochondromas (HMO). Many complications within the intra-thoracic region caused by CO have been reported, including diaphragmatic lacerations, pneumothorax, hemothorax, and visceral pleural damage. In some cases, the defect could progress to

chondrosarcoma [1,5,6]. A case of acute coronary syndrome secondary to extrinsic compression of the left anterior descending coronary artery, has also been reported [7].

This case report has been reported in line with the SCARE Criteria [12].

2. Report of the case

We present a rare case of a 9-year-old girl admitted to the hospital, complaining of intermittent shortness of breath (SOB) on exertion. The SOB started one year prior to admission and was progressively increasing.

Past medical history (according to the mother) revealed multiple lesions in different parts of her body. These included a scapular lesion, bilateral rib lesions, and lesions of lower extremities, that were painless and not increasing in size. Her mother reported that the patient was diagnosed earlier with a rare syndrome that she cannot exactly recall. No other pertinent family and past history were noted.

Abbreviations: CO, costal osteochondroma; SOB, shortness of breath; EXT 1, Exostosin -1; EXT 2, Exostosin -2; CT, computed tomography; VAT, video-assisted thoracoscopy; HMO, hereditary multiple osteochondromas.

* Corresponding author at: College of Medicine, Dar Al Uloom University, Riyadh, Saudi Arabia.

E-mail address: 1172075@du.edu.sa

<https://doi.org/10.1016/j.ijscr.2021.105762>

2210-2612/© 2021 Published by Elsevier Ltd on behalf of IJS Publishing Group Ltd. This is an open access article under the CC BY-NC-ND license (<http://creativecommons.org/licenses/by-nc-nd/4.0/>).

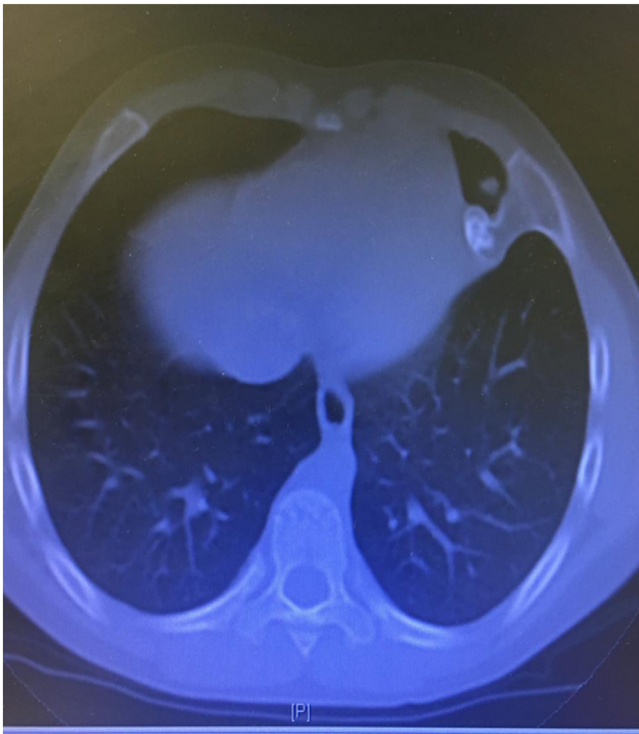


Fig. 1. Chest computed tomography scan (CT) showing a bony lesion on the medial aspect of the left fifth rib, in close contact with the ventricle of the heart.

Upon admission, there were no signs of chest pain, cyanosis, palpation, and cough. Chest examination showed normal vesicular breathing, with no added sounds. The skin over the chest was intact with no erythema nor tenderness. Small sized bony projections were noted on the area of the left 5th rib. Vital signs were normal. Chest x-ray along with a computed tomography (CT) scan were done, which showed a bony lesion on the left fifth rib, in close contact, with the left ventricle of the heart.

Video-assisted thoracoscopy (VAT) was performed under general anesthesia by a thoracic surgery consultant, to explore the intrathoracic cavity. A bony protrusion was revealed, spanning from the medial aspect of the left fifth rib towards the chest cavity, in close contact with the ventricles of the heart. The lesion was inspected from inside and marked by two needles. This was followed by resection of part of the affected rib with the mass en-bloc, which was sent for pathological investigations. VAT was selected due to the location of the lesion and the patient's symptomatic complaint. It was performed to avoid the risk of possible future complications and damage within the intra thoracic region, such as damage to adjacent structures. After the closure of wounds, a chest tube size 24 was inserted and left until the next day. Following proper investigations of the resected mass, the gross specimen consisted of part of a rib which measured 3.0 cm in length and a diameter of 1.2 cm. The specimen was sent to the laboratory. An attached bony protrusion with a cartilaginous cap measuring 2.0 cm × 2.0 cm × 1.5 cm, along with thickness of 0.4 cm was shown within the rib (Figs. 1 and 2).

Histological sections showed mature bone covered by a cartilaginous cap with benign appearing chondrocytes. In addition, no permeation of bone or extension into soft tissue was seen. Histological features were consistent with osteochondroma and the diagnosis was confirmed. Post-operatively, the patient was complication-free and was discharged asymptomatic with simple instructions such as wound care and safety netting.

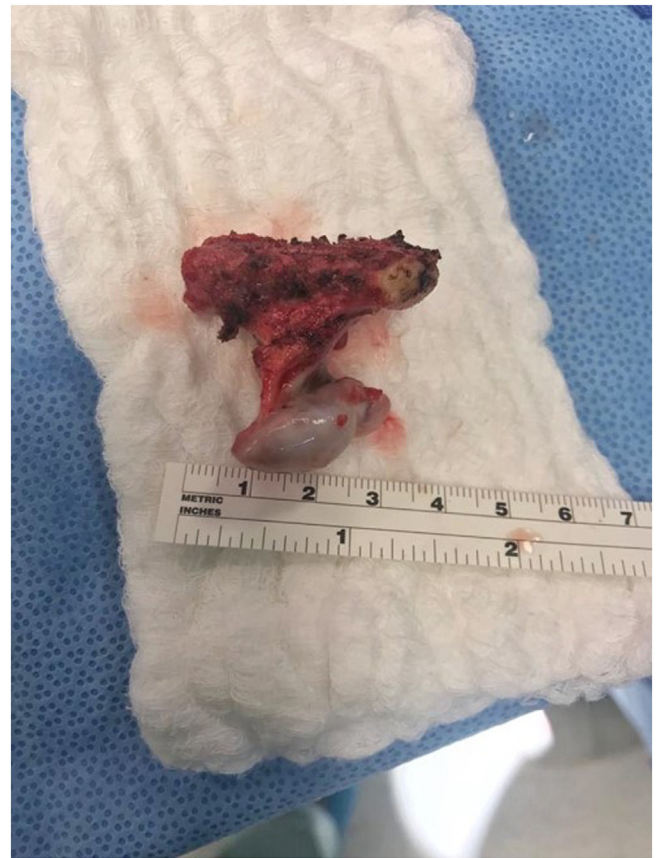

Fig. 2. Resected mass consisted of part of the left fifth rib along with an attached lesion of bony protrusion with a cartilaginous cap.

3. Discussion

Our reported case is a rare example of a solitary costal osteochondroma leading to serious complications because of its shape, size, and location. Osteochondromas are considered the most common benign tumors of bony origin. They arise usually from the metaphysis of the bone, mostly from the outer contour, which is characteristically capped by cartilage [2,8]. Osteochondromas affecting the upper extremities such as the clavicle and scapula are quite uncommon [9]. Exostosis are slow growing masses usually diagnosed before the third decade of life, occurring mainly in individuals without developing any symptoms of pain or tenderness [6,9]. These types of tumors affect adults or adolescents after puberty. They can increase in size and can produce various types of symptoms due to irritation, compression and damage to the surrounding structures such as peripheral nerves, spinal cord, blood vessels or adjacent tissues [6].

A computed tomography scan offers a more accurate tool in the diagnosis of this type of condition because some masses are not well shown on plain x-ray [5]. Contrary to previous reports, rib exostosis occurs more frequently in males than females with a ratio of 1.5:1 [8,10]. Costal osteochondromas mostly occur as a part of hereditary multiple osteochondromas (HMO). It is associated with heterozygous mutations in EXT1 or EXT2 genes, which are mostly familial in kind rather than sporadic [4]. Malignant transformation of osteochondromas to chondrosarcomas are rare (roughly 0.5–5%), however if a lesion continues to progress in size after puberty, malignant transformation should be considered [1,11].

Harmful effects of untreated cases of rib exostosis can result in visceral injury of internal structures, caused by force to structures adjacent to the lesion. These include the pleura, heart,

diaphragm, and the blood vessels which have been reported rarely in previous cases [1,2]. Previous reports have not addressed any significant traumatic event or impact prior to the occurrence of symptoms related to the cases, including the case of our patient. Our patient reported intermittent shortness of breath which was progressive with time and increasing on exertion. Underlying causes of lung disease along with other differentials were excluded upon history taking and investigations. Cases of rib exostosis were surgically approached using different techniques most often through thoracotomy. Mini-incision thoracotomy is needed depending on factors including dimension of the rib lesion and localization involving the rib [11]. A previous case of postoperative complication caused by chest drainage system impairment was recorded resulting in pneumothorax, but was managed later on without any obstacles [11]. In our case, VAT was opted to completely resect the lesion and to relieve the symptoms, in addition to avoiding further complications or damage to adjacent tissues.

In conclusion, Rib osteochondromas can impinge on the cardiac structures and present as cardiac compression of the surrounding vessels. Video-assisted thoracoscopy can be used to visualize the internal thoracic structures at locations that are hard to reach and inaccessible through other imaging modalities. This can lower the risk of possible damage to adjacent structures resulting in less postoperative complications.

Declaration of Competing Interest

The authors report no declarations of interest.

Funding

No funds have been received for the study.

Ethical approval

The study is exempt from ethical approval.

Consent

Written informed consent was obtained from the patients guardian for publication of this case report and accompanying images. A copy of the written consent is available for review by the Editor-in-Chief of this journal on request.

Author contribution

The author contributed to the conception and design of the study. He performed the collection and interpretation of data and writing the manuscript.

Registration of research studies

Not applicable.

Guarantor

I, as the author of the study, accept full responsibility for the work and/or the conduct of the study, had access to the data, and controlled the decision to publish.

Provenance and peer review

Not commissioned, externally peer-reviewed.

Availability of data and materials

The case history and reports used and/or analyzed during the current study are available from the corresponding author on reasonable request.

References

- [1] T. Kameda, T. Makino, T. Sakai, S. Koezuka, H. Otsuka, Y. Hata, N. Tochigi, K. Shibuya, A. Iyoda, Asymptomatic costal exostosis with thickening in the pericardium: a case report, *J. Cardiothorac. Surg.* 11 (December (1)) (2016) 36.
- [2] T. Nakano, S. Endo, H. Tsubochi, K. Tetsuka, Thoracoscopic findings of an asymptomatic solitary costal exostosis: is surgical intervention required? *Interact. Cardiovasc. Thorac. Surg.* 15 (August (5)) (2012) 933–934.
- [3] A. Dumazet, C. Launois, S. Dury, F. Sailhan, M. Alifano, M. Dewolf, F. Lebagry, G. Deslee, J.M. Perotin, Hereditary multiple exostoses of the ribs as an uncommon cause of pneumothorax: a case report, *Medicine* 97 (August (35)) (2018).
- [4] M. Pacifici, Hereditary multiple exostoses: new insights into pathogenesis, clinical complications, and potential treatments, *Curr. Osteoporos. Rep.* 15 (June (3)) (2017) 142–152.
- [5] K. Imai, Y. Suga, Y. Nagatsuka, J. Usuda, T. Ohira, H. Kato, N. Ikeda, Pneumothorax caused by costal exostosis, *Ann. Thorac. Cardiovasc. Surg.* 20 (2) (2014) 161–164.
- [6] J.S. Yoon, J.B. Kwon, C.B. Park, J.H. Suh, Costal exostoses as an unusual cause of spontaneous hemothorax, *J. Cardiothorac. Surg.* 10 (December (1)) (2015) 135.
- [7] J.C. Rodrigues, H.C. Mathias, S.M. Lyen, E. Mcalindon, C. Bucciarelli-Ducci, T.J. Batchelor, M.C. Hamilton, N.E. Manghat, A novel cause of acute coronary syndrome due to dynamic extrinsic coronary artery compression by a rib exostosis: multimodality imaging diagnosis, *Can. J. Cardiol.* 31 (October (10)) (2015) 1303–e9.
- [8] V.V. Kadu, K.A. Saindane, N. Goghate, N. Goghate, Osteochondroma of the Rib: a rare radiological appearance, *J. Orthop. Case Rep.* 5 (January (1)) (2015) 62.
- [9] K. Gökkuş, H. Atmaca, E. Sağtaş, M. Saylık, A.T. Aydin, Osteochondromas originating from unusual locations complicating orthopedic discipline: case series, *Eklemler Hastalıkları ve Cerrahisi* 26 (2) (2015) 100–109.
- [10] S. Alhames, K. Almhanna, Large rib osteochondroma in a child in Aleppo, Syria, *J. Surg. Case Rep.* 2018 (September (9)) (2018) rjy247.
- [11] D. Mazza, M. Fabbri, C. Calderaro, C. Iorio, L. Labianca, C. Poggi, F. Turturro, A. Montanaro, A. Ferretti, Chest pain caused by multiple exostoses of the ribs: a case report and a review of literature, *World J. Orthop.* 8 (May (5)) (2017) 436–440.
- [12] R.A. Agha, T. Franchi, C. Sohrabi, G. Mathew, for the SCARE Group, The SCARE 2020 guideline: updating consensus surgical CAse REport (SCARE) guidelines, *Int. J. Surg.* 84 (2020) 226–230.

Open Access

This article is published Open Access at [sciencedirect.com](https://www.sciencedirect.com). It is distributed under the [IJSCR Supplemental terms and conditions](#), which permits unrestricted non commercial use, distribution, and reproduction in any medium, provided the original authors and source are credited.