

Surgical fixation of a traumatic fracture through a congenitally anomalous sternum: a case report

Bradley Faliks ,¹ Evan Thomas,² Joseph D Forrester³

¹Department of Surgery, HonorHealth Scottsdale Osborn Medical Center, Scottsdale, Arizona, USA

²College of Medicine, Washington State University, Spokane, Washington, USA

³Departments of Surgery and Medicine, Stanford University, Stanford, California, USA

Correspondence to

Dr Bradley Faliks; bfaliks@gmail.com

CASE PRESENTATION

A man in his 20s with no medical history presented to our level 1 trauma center as a driver in a motor vehicle collision where his car hit a tree at unknown speed. He was extricated by bystanders. He was not ambulatory on scene. He remained hemodynamically normal on arrival and was taken to CT scan.

He was found to have an acute, displaced sternal body fracture with associated mediastinal hematoma superimposed on a congenitally fused sternum and manubrium with sternal foramen and bifid xiphoid process ([figure 1](#)). In addition, he was found to have non-displaced left first rib fracture, moderate left pneumothorax, right hepatic lobe contusion with trace perihepatic hemorrhage, T8 spinous process, T10 to T11 transverse process, and L1 to L5 right transverse process fractures.

On day 1 after injury, he had palpable chest wall instability, numerical pain scores consistently greater than 5, and an incentive spirometry volume of 750 mL (<50% predicted) despite oral and intravenous multimodal pain control therapy.

WHAT WOULD YOU DO?

- Bilateral erector spinae plane (ESP) blocks.
- Bilateral serratus anterior blocks.
- Surgical stabilization of the sternal fracture.
- Addition of a ketamine or lidocaine infusion to his medication regimen.

WHAT WE DID AND WHY

To address this patient's ongoing pain and sternal instability, we took him to the operating room for surgical stabilization of his sternal fracture. We felt that either ESP or serratus anterior blocks alone

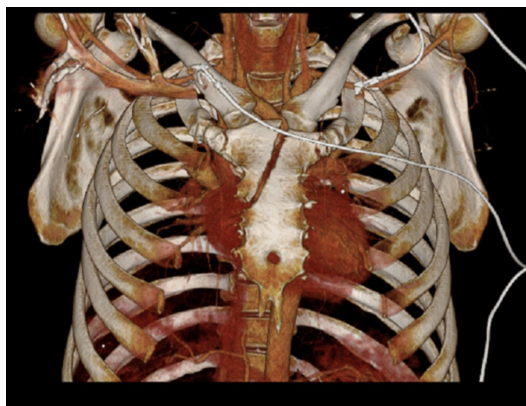


Figure 1 Three-dimensional reconstruction of chest CT showing oblique fracture through a congenitally fused sternum.

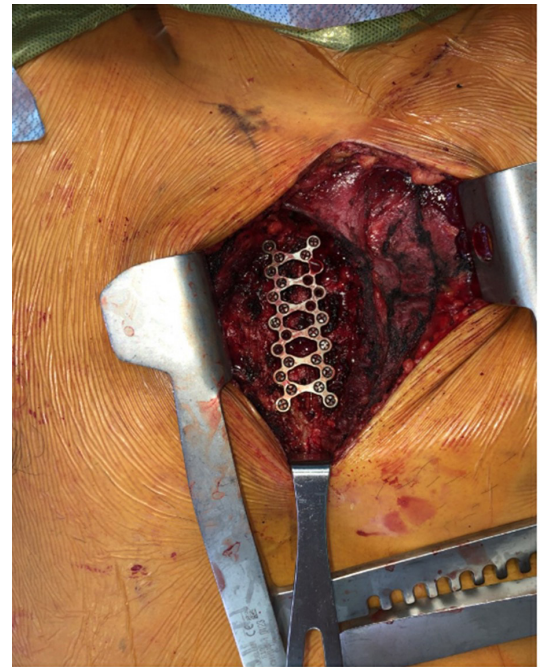


Figure 2 Intraoperative photo of 26-hole ladder plate securing reduction of the sternal fracture.

would not be reliable for pain control specifically for sternal fracture. Additionally, we thought that this young patient may be able to leave the hospital quickly after repair. Additional infusions would have required a higher level of care and potentially prolonged his hospitalization. Early operation and stabilization may have potential benefits including lowering his narcotic requirements and overall length of stay.

After exposure through a parasternal incision, the fracture was identified and was displaced, oblique and clearly unstable. We reduced the fracture with ankle reduction forceps. While our typical practice with sternal fractures is to achieve stability through longitudinal plates placed in “railroad track” fashion, given his congenitally fused sternum and the fracture characteristics, we elected to place a 26-hole ladder sternal plate using unicortical screws ([figure 2](#)). After stabilizing the plate and bone construct, we placed 15 mm locking screws superiorly and 13 mm locking screws on the inferior portion of the plate to account for variations in sternal depth. The patient recovered well without issue. His left pneumothorax resolved without intervention ([figure 3](#)). He was discharged to home on postoperative day 2 (day 3 after injury). At 6 weeks postoperatively, he was taking no narcotics, only acetaminophen as needed. He had no complaints of

© Author(s) (or their employer(s)) 2023. Re-use permitted under CC BY-NC. No commercial re-use. See rights and permissions. Published by BMJ.

To cite: Faliks B, Thomas E, Forrester JD. *Trauma Surg Acute Care Open* 2023;**8**:e001155.

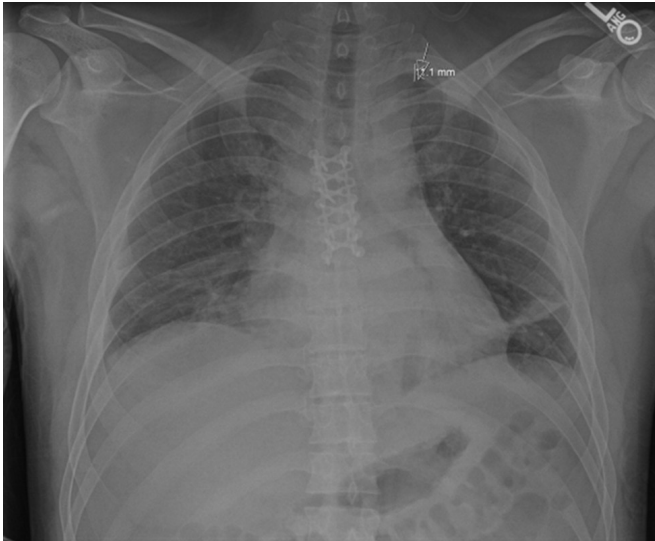


Figure 3 Postoperative chest radiograph showing plate placement and small left apical pneumothorax.

sternal instability and no clicking or popping on exam. He was able to pull 3000 mL on incentive spirometry and reported being able to walk up a flight of stairs without issue.

DISCUSSION

Traumatic sternal fracture occurs in 3% to 8% of blunt trauma patients.^{1,2} Despite operative management of chest wall injury becoming increasingly ubiquitous, only a small percentage of traumatic sternal fractures undergo operative fixation.^{1,3} Surgical stabilization of displaced sternal fractures (SSSF) may be associated with improved pain control and upper extremity range of motion.^{4,5} However, SSSF performed on patients with congenital abnormalities has only rarely been described.⁶

Sternal anomalies are common. A recent review of 1150 Greek patients who underwent chest CT scan found anomalies in 74.1% of patients.^{7,8} Sternal anomalies arise from embryological malfusion, and patients are commonly asymptomatic until discovered incidentally by radiological studies or procedures involving the sternum.^{9–11}

In pediatric patients, sternal abnormalities are often associated with congenital heart disease, although this is less frequently the case among adults.¹¹ One of the more common congenital sternal abnormalities is a fused manubriosternal joint (MSJ) representing 20% of all congenital sternal abnormalities.¹²

The MSJ is a synarthrosis that allows for minimal movement allowing the body of the sternum to move anteriorly and superiorly for expansion of intrathoracic volume. However, in the fused sternum, this opportunity for flexion or extension is reduced, which may impact the sternum's ability to respond to applied force, potentially leading to increased risk of sternal fracture after blunt injury.¹³ However, it is unknown if these

variations impact recovery from SSSF, and the optimal stabilization technique for these variations remains to be delineated.

Sternal variations are common. Chest wall surgeons should be familiar with common sternal abnormalities and their implications for the management and repair of chest wall injury. We present an unusual case of fracture through a sternum with fused MSJ, sternal foramen, and bifid xiphoid process, as well as our process of surgical fixation.

Contributors BF was responsible for planning, conceptualization, writing of the original draft, reviewing, and editing. ET was responsible for writing of the original draft, reviewing, editing, and figure preparation. JDF was responsible for conceptualization, reviewing, editing, and supervision.

Funding The authors have not declared a specific grant for this research from any funding agency in the public, commercial or not-for-profit sectors.

Competing interests None declared.

Patient consent for publication Not applicable.

Provenance and peer review Not commissioned; internally peer reviewed.

Open access This is an open access article distributed in accordance with the Creative Commons Attribution Non Commercial (CC BY-NC 4.0) license, which permits others to distribute, remix, adapt, build upon this work non-commercially, and license their derivative works on different terms, provided the original work is properly cited, appropriate credit is given, any changes made indicated, and the use is non-commercial. See: <http://creativecommons.org/licenses/by-nc/4.0/>.

ORCID iD

Bradley Faliks <http://orcid.org/0000-0003-1673-9881>

REFERENCES

- Christian AB, Grigorian A, Nahmias J, Duong WQ, Lekawa M, Joe V, Dolich M, Schubl SD. Comparison of surgical fixation and non-operative management in patients with traumatic sternum fracture. *Eur J Trauma Emerg Surg* 2022;48:219–24.
- Harston A, Roberts C. Fixation of sternal fractures: a systematic review. *J Trauma* 2011;71:1875–9.
- Choi J, Khan S, Syed M, Tennakoon L, Forrester JD. Early national landscape of surgical stabilization of sternal fractures. *World J Surg* 2021;45:1692–7.
- Zhao Y, Yang Y, Gao Z, Wu W, He W, Zhao T. Treatment of traumatic sternal fractures with titanium plate internal fixation: a retrospective study. *J Cardiothorac Surg* 2017;12:22.
- Bauman ZM, Yanala U, Waibel BH, Malhotra GK, Cemaj S, Evans CH, Schlitzkus LL. Sternal fixation for isolated traumatic sternal fractures improves pain and upper extremity range of motion. *Eur J Trauma Emerg Surg* 2022;48:225–30.
- Klei DS, de Jong MB, Öner FC, Leenen LPH, van Wessem KJP. Current treatment and outcomes of traumatic sternal fractures—a systematic review. *Int Orthop* 2019;43:1455–64.
- Vatzia K, Fanariotis M, Makridis KG, Vlychou M, Fezoulidis IV, Vassiou K. Frequency of sternal variations and anomalies in living individuals evaluated by MDCT. *Eur J Radiol* 2021;142:109828.
- Yekeler E, Tunaci M, Tunaci A, Dursun M, Acunas G. Frequency of sternal variations and anomalies evaluated by MDCT. *AJR Am J Roentgenol* 2006;186:956–60.
- McCormick WF. Sternal foramina in man. *Am J Forensic Medicine and Pathology* 1981;2:249–52.
- Choi PJ, Iwanaga J, Tubbs RS. A comprehensive review of the sternal foramina and its clinical significance. *Cureus* 2017;9:e1929e1929.
- Wattamwar K, Levin TL. Delayed sternal ossification in congenital heart disease: incidence using computed tomography. *Pediatr Radiol* 2021;51:1676–81.
- Cameron HU, Fornasier VL. The Manubriosternal joint—ananatomicoradiological survey. *Thorax* 1974;29:472–4.
- Kirum GG, Munabi IG, Kukiriza J, Tumusiime G, Kange M, Ibingira C, Buwembo W. Anatomical variations of the sternal angle and anomalies of adult human sterna from the Galloway osteological collection at Makerere University anatomy Department. *Folia Morphol (Warsz)* 2017;76:689–94.