

## Review Article

# Ligamentum flavum hematomas: Why does it mostly occur in old Asian males? Interesting point of reported cases: Review and case report

Bulent Ozdemir, Ayhan Kanat, Osman Ersegun Batcik, Hasan Gucer<sup>1</sup>, Coskun Yolas<sup>2</sup>

Department of Neurosurgery, <sup>1</sup>Department of Pathology, Recep Tayyip Erdogan University, Medical Faculty, Rize, <sup>2</sup>Neurosurgery Clinic, Erzurum Training and Research Hospital, Erzurum, Turkey

Corresponding author: Dr. Ayhan Kanat, Department of Neurosurgery, Medical Faculty, Recep Tayyip Erdogan University, Merkez, Rize - 53100, Turkey.  
E-mail: [ayhankanat@yahoo.com](mailto:ayhankanat@yahoo.com)

Journal of Craniovertebral Junction and Spine 2016, 7:3

## Abstract

Hematoma of the ligamentum flavum (LF) is a rare cause of neural compression and sciatica. Currently, the etiology and epidemiological characteristics of ligamentum flavum hematoma (LFH) are unknown and epidemiological investigations using reviewing of reported cases have not been performed. We report the case of a 63-year-old man with a LFH compressing the spinal canal at the left L2–L3 level, reviewed relevant literature. In Medline research, we found a total of 50 reported cases with LFHs, and the interesting point of these cases were analyzed. Many of cases were old males. Interestingly, 39 of the 50 cases were reported from Asian countries. The ages of 42 patients could be verified. The youngest age was 45 years, oldest age was 81 years, and mean age was 66.07 years. Thirty-three out of these 42 patients (78.53%) were older than 60 years. An important aspect of the present review is to bring attention for occurrence in older Asian males. With an increasing number of elderly people in the general population, there is a need to investigate risk factors such as sexual gender, age, and geographic location for LFH.

**Key words:** Hematoma, ligamentum, ligamentum flavum (LF)

## INTRODUCTION

The ligamentum flavum (LF) is an important structure from the axis to sacrum extending downward from the lamina of the respective anatomic segment, and extending laterally to blend with the facet capsule.<sup>[1]</sup> It helps to maintain an upright posture and resume an upright posture after bending,<sup>[1,2]</sup> and consists of elastic fibers and collagen and is poorly vascularized;<sup>[3]</sup> only a few small vessels pass

through it and intraligamentous bleeding is uncommon.<sup>[4]</sup> The pathogenesis of these hematomas is not clear. Ruptured irregular vessels of the degenerated and hypertrophic LF were assumed. Currently, the etiology and epidemiological characteristics of ligamentum flavum hematoma (LFH) are unknown and epidemiological investigations using reviewing of reported cases have not been performed. Here we report a

This is an open access article distributed under the terms of the Creative Commons Attribution-NonCommercial-ShareAlike 3.0 License, which allows others to remix, tweak, and build upon the work non-commercially, as long as the author is credited and the new creations are licensed under the identical terms.

**For reprints contact:** [reprints@medknow.com](mailto:reprints@medknow.com)

**How to cite this article:** Ozdemir B, Kanat A, Batcik OE, Gucer H, Yolas C. Ligamentum flavum hematomas: Why does it mostly occur in old Asian males? Interesting point of reported cases: Review and case report. *J Craniovert Jun Spine* 2016;7:7-12.

Access this article online	
Quick Response Code:	Website: <a href="http://www.jcvjs.com">www.jcvjs.com</a>
	DOI: 10.4103/0974-8237.176605

patient with hematoma of the LF and reviewing the relevant literature, found interesting points.

## CASE REPORT

### History and examination

A 63-year-old man presented with 6 weeks' history clinical history of spontaneous, subcontinuous, progressive lumbar, and severe burning pain radiating from the left buttock to the left posterior thigh. The pain became worse with activity and was alleviated by bed rest. The patient also complained of paresthesia on the lateral aspect of the left posterior thigh. There was no history of major trauma, lumbar surgery, antiplatelet/anticoagulant therapy, or lumbar puncture. On admission, fine touch sensation was decreased in the left L2, L3 dermatomes and a manual muscle test of the lower extremities revealed normal power. Deep tendon reflexes of the lower extremities were normal, as were bladder and bowel functions. There was no pain during the straight-leg raising test.

### Imaging

Magnetic resonance imaging demonstrated an epidural mass at the left side of L2-3 levels that exerted compression over the dural sac. It was located at the posterior aspect of the spinal canal and displaced the dural sac anteriorly, resulting in spinal canal stenosis. It was hyperintense on T2-weighted images [Figures 1 and 2]. Signals within the lesion on T1-weighted images were suggestive of chronic or subacute hemorrhage. Contrast-enhanced images were not obtained.

### Surgery

Under general anesthesia, the L2 spinous process was located by plain roentgenography and a midline incision of about 2.5 cm was made halfway between the L2 and L3 spinous processes. Then the left fascia was dissected, the muscles were displaced laterally, and a Taylor retractor, Olusum Medical, Number 21-598 was positioned. The inferior part of the left L2 lamina was removed under the operating microscope, Zeiss Vario, Germany. There were no cysts or tracks noted outside the ligamentous flavum and the mass did not originate from the facet joint. Accordingly, this joint could be preserved. Later, a nodular lesion embedded in the LF on the dorsal aspect of the dura mater was exposed. The LF was identified as a solid brownish mass, causing severe compression of the left L3 root. Figure 3 shows the operative view of LFH under the microscope. The LF was resected completely together with the cystic mass. During removal of the LF, hemorrhagic cystic fluid was expressed from it. After the ligament was removed, no disc herniation or bony encroachment on the nerve root was found, and there was also no evidence of tumor or infection. Then, the wound was closed. Because the facet joint remained intact, no fixation was added. Rapid improvement of the patient's symptomatology was noticed in the postoperative period, with complete recovery during the following month. Follow-up examinations of at least 20 months postoperatively were unremarkable without any residual symptom in all instances. There was no recurrence.

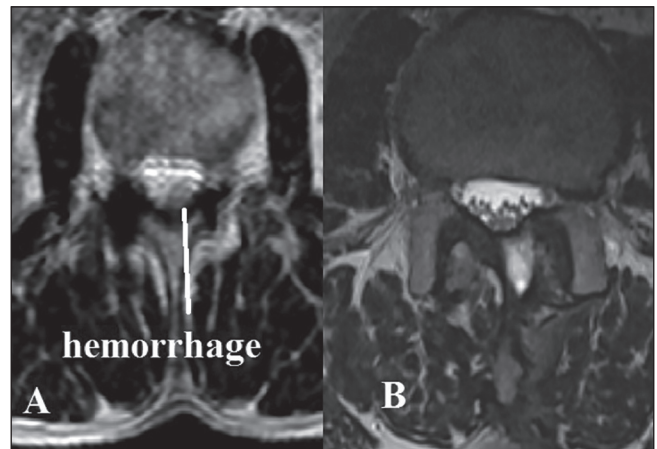


Figure 1: Shows preoperative and postoperative axial MR images of patient

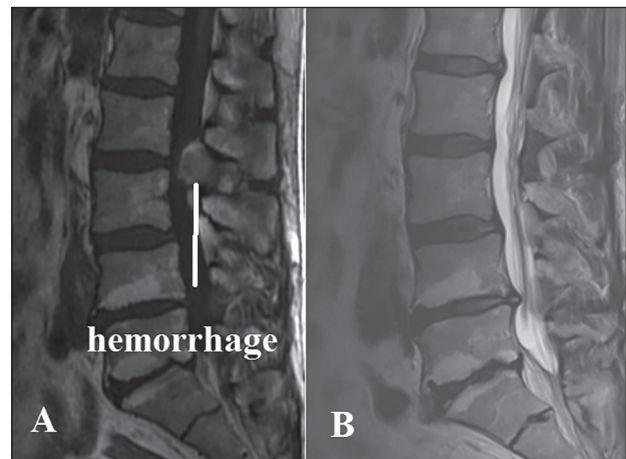


Figure 2: Shows preoperative and postoperative sagittal MR images of patient

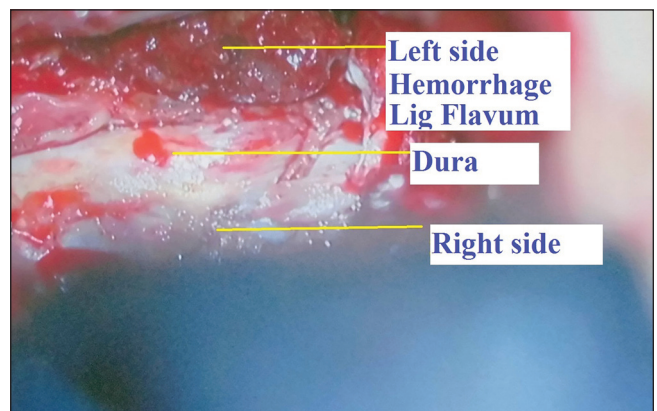


Figure 3: The operative view of LFH under microscope

### Pathological findings

Histological examination of the LF revealed a consolidated hematoma with granulomatous change, degenerative fibrous tissue surrounded by intact fibrous tissue [Figure 4], and accumulation of hemosiderin-laden macrophages. No evidence of infectious or neoplastic changes was found.

**Literature review**

In Medline research, 50 cases with LFH were found.<sup>[1-35]</sup> The cases hemorrhage of the LF cyst were excluded. In literature review, age and gender could be verified only in 42 patients. Table 1 shows the gender distribution of patients. There was a male dominance. Of the gender-verified cases, 31 were males (62%) and 11 were females (22%). The youngest age was 45 years, oldest age was 81 years, and mean age was 66.07 years. Thirty-three out of these 42 patients (78,53%) were older than 60 years. Interestingly, 39 of the 50 cases were reported from Asia, mostly from Japan [Tables 2 and 3]. If the cases with bilateral involvement, the predominant side of hematomas were the left side [Table 4] (28% left side versus 14% right side). The spinal location level, anatomic region, and reported years of cases are shown in Tables 5-7.

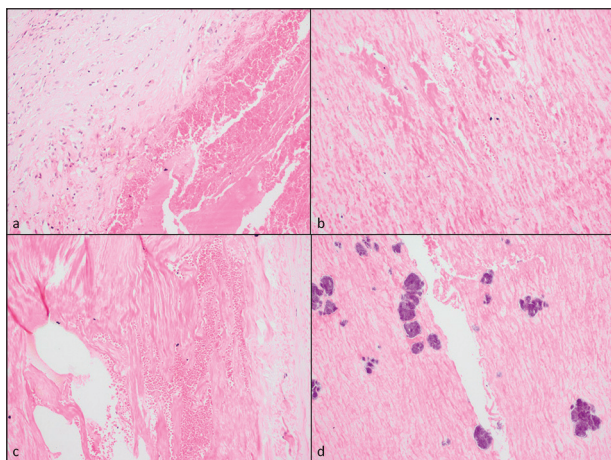
**DISCUSSION**

Generally, low back pain (LBP) is one of the most common problems.<sup>[4,36-38]</sup> One of the causes of LBP is LFH, which is a rare lesions.<sup>[5]</sup> The pathophysiological mechanism of LFH is still unclear but it is speculated that vessel rupture within the LF may cause the hematoma.<sup>[6-8]</sup> In our patient, magnetic resonance (MR) images at L2-3 level on the left side showed LF associated with a fluid component that was suggestive of hematoma. With the current case, a total of 50 patients with LFH have been reported in the English literature since the first report by Sweasey *et al.* in 1992, mostly in the form of single case reports 1-35.

**Interesting points of reported cases**

*Location*

LFH in our case was at lumbar L2-3 level. In the literature, the majority of reported cases of LFH have been seen in the mobile lumbar spine and cervical spine.<sup>[21,31]</sup> However, in these reported cases, the lumbar spine was the prominent involvement location [Table 6]. It is suggested that the reason for this is that the lumbar spine is stressed more often by load-bearing forces than the



**Figure 4: Histological examination revealed hemorrhage of the ligamentum flavum. The overall histological diagnosis was a hematoma in the degenerative LF. The hematoma is made up of poorly vascularized, dense tissue with elastic fibers and collagen**

thoracic spine and the cervical spine. As opposed to the thoracic spine, the lumbar spine is more mobile, which makes it more prone to shearing forces after minor trauma.<sup>[5]</sup> Another cause of stress of the lumbar spine is an erect posture. The evolution of bipedal posture and ambulation in humans has transformed the horizontal vertebral column of vertebrates into a load-bearing erect spine that is required to efficiently transfer weight, provide stability, and permit motion.<sup>[39]</sup> This transformation in the mechanics of locomotion leads to the lumbar spine being

**Table 1: Gender distribution of reported cases**

Gender	Frequency	Percent (%)
Valid		
Female	11	22.0
Male	31	62.0
NA	8	16.0
Total	50	100.0

NA: Not applicable may be unknown

**Table 2: Shows the reported number of cases according to continent**

Continent	Frequency	Percent (%)
Valid		
America	2	4.0
Asia	39	78.0
Europe	9	18.0
Total	50	100.0

**Table 3: The number of cases according to reported countries**

Country	Frequency	Percent (%)
Australia	1	2.0
England	1	2.0
Germany	6	12.0
Israil	1	2.0
Italy	1	2.0
Japan	23	46.0
Korea	2	4.0
Spain	1	2.0
Taiwan	2	4.0
Turkey	10	20.0
USA	2	4.0
Total	50	100.0

**Table 4: The involvement side of patients**

Side	Frequency	Percent (%)
Valid		
Bilateral	16	32.0
Left	14	28.0
Unknown	13	26.0
Right	7	14.0
Total	50	100.0

**Table 5: Involvement level of reported patients**

Level	Frequency	Percent (%)
C3-4	3	6.0
C4-5	2	4.0
C5-6	1	2.0
L1-2	1	2.0
L2-3	6	12.0
L3-4	9	18.0
L3-4, L4-5	1	2.0
L4-5	8	16.0
L5-S1	4	8.0
Th10-11	1	2.0
Th11-12	3	6.0
Th3-4	1	2.0
Th7-8	1	2.0
Th9-10	1	2.0
Unknown	8	16.0
Total	50	100.0

**Table 6: The involvement anatomic location of patients**

Anatomic site	Frequency	Percent (%)
Valid		
Cervical	5	10.0
Lumbar	35	70.0
Thoracal	8	16.0
Unknown	2	4.0
Total	50	100.0

**Table 7: The number of reported cases according to years**

year	Frequency	Percent (%)
1992	2	4.0
1995	1	2.0
1999	1	2.0
2000	2	4.0
2001	1	2.0
2004	1	2.0
2005	4	8.0
2006	7	14.0
2007	2	4.0
2008	3	6.0
2009	3	6.0
2010	2	4.0
2011	2	4.0
2012	5	10.0
2013	4	8.0
2014	4	8.0
2015	6	12.0
Total	50	100.0

susceptible to degenerative disease.<sup>[40]</sup> Recently, it was reported that cartilage end plate degeneration is usually accompanied by

loss of cellularity,<sup>[41]</sup> and this loss may be a crucial key factor in the occurrence of degeneration and LFH.

*Side*

The human body, which appears to be symmetrical grossly along the midline, is in fact, asymmetrical both morphologically and physiologically. This asymmetry has been explained as the result of differential mechanical loadings. More stress and strain on the dominant side may cause differences between the sides, often referred to as directional asymmetry.<sup>[40]</sup> Most humans have a strong preference for using the right hand in unimanual tasks, a minority prefers the left hand, and very few people do not exhibit a hand preference. Manual or foot asymmetries can be related to asymmetries of the brain. Lateralization and asymmetry secondary to cerebral dominance may be important for LFH. Table 4 shows involvement side of cases.

*Aging*

Aging is one of the most complex biological processes. A whole host of gross-level neuroanatomical changes take place as we get older.<sup>[42]</sup> Autopsy studies on a large number of subjects have found disc degeneration, facet joints osteoarthritis, or osteophytes in 90-100% of the subjects aged over 64 years.<sup>[43]</sup> The patients in this review were the elderly with a mean age of 66.07 years (range: 45-81 years); there were 36 males and 13 females. Of these 42 patients, 33 (78.53%) were older than 60 years. With the population aging, the global number of people suffering from degeneration of the LF will further increase. Continuous mechanical stress causes degeneration of the LF. The morphological change of LF is very important for reviewing the etiology of degeneration of the LF. Common pathological findings in the degenerated LF are dispersed ligament elastic fibers, increased collagen tissues, granulation of fibrous tissues, lymphocyte infiltration, and small capillary proliferations.<sup>[21]</sup> Although prior studies have been performed in this area, the pathophysiology of loss of elasticity and hypertrophy is not completely understood.<sup>[44]</sup> During LF hypertrophy, there are increases in the expression and activity of various molecules<sup>[6]</sup> including matrix metalloproteinases,<sup>[26,45-48]</sup> connective tissue growth factor,<sup>[49]</sup> bone morphogenetic protein,<sup>[50]</sup> and inflammatory cytokines.<sup>[51]</sup> Increase of these molecules may lead to hemorrhage of the LF. It is well-known that synovium is a highly vascular tissue.<sup>[6]</sup> In a degenerated joint cavity, the number and volume of vessels may also increase.<sup>[52]</sup> The interlaminar portion of the LF has a small arterial network and the capsular portion has a venule network.<sup>[34]</sup> When these networks are broken, blood may enter the preexisting facet cyst through fissures through the degenerating LF.<sup>[1,17]</sup> With an increasing number of elderly people in the general population, advanced patient age may be considered to be a risk factor for LFH. Seven cases were reported in 2006, which is the highest number, and the number of reported cases are increasing in recent years [Table 7]. This point should be kept in mind.

*Gender*

Gender could be verified in 42 reports. Thirty-one (62%) reported cases were males and 11 (22%) were females [Table 1].

The reported cases with LFH show that the human spine is sensitive to the effects of age and sex for LFH, and little is known about the interactive effects of these variables on occurrence on LFH.

#### Trauma

LFH is sometimes said to be the result of trauma; trauma may be mild, remote, and not remembered by the patient or family. In this review, the male preponderance of reported cases with LFH may be due to (a) the greater exposure of males to spinal injury. (b) estrogens may have a protective effect on the capillaries (c) spine degeneration may be different in males and females. Trauma may occur as a result of increased intraabdominal pressure transmitting excessive pressure to the very small, thin, and irregular blood vessels in the LF.<sup>[35]</sup> Kotil and Bilge<sup>[19]</sup> reported two similar cases in which L5 radiculopathy was attributed to LFH secondary to chronic lumbar strain without an acute inciting event. Chi *et al.* reported a case after trauma.<sup>[13]</sup> However, our patient had no trauma before the onset of their symptoms.

#### Continent

Interestingly, 39 out of 50 cases were reported from countries of Asia, mostly from Japan [Tables 2 and 3]. It has been previously reported that ossification of the LF occurs mainly in the Asian population.<sup>[53]</sup> There can be continent-related changes, degeneration or ossification of LF and LFH. This point should be investigated.

#### The value of the present study

At present, neurosurgical practice is confronted by an explosion of technology.<sup>[54,55]</sup> In the 1990s, the advent of magnetic resonance imaging and the progressive increase in definition of this modality of imaging have considerably contributed to the knowledge of the LFH and the first report published in 1992.<sup>[1]</sup> Some mechanisms have been proposed to explain the development of LFH. Cruz-Conde *et al.* proposed a mechanism of hematoma formation in which a partial tear occurs in a degenerative ligament and leads to intraligamentary bleeding.<sup>[14]</sup> Another possible mechanism is that the bleeding in the facet joint flows out into the degenerated LF and forms a hematoma in it.<sup>[56]</sup> But it is difficult to understand how the bleeding from the facet joint accumulates within the degenerative LF.<sup>[32]</sup> Increased abdominal pressure transmitted to the epidural space results in spinal epidural hypertension, which can cause a partial tear in the degenerated ligament that can result in an intraligamentous hemorrhage. An important aspect of the present review and case report is to bring attention for occurrence in Asian old males. The recognition of this fact may be important if indeed one is the first to report something and that something is of value.<sup>[57-59]</sup>

#### CONCLUSION

In the literature, patients reporting with LFH were mostly aged older than 60 years and had a degenerated spine. The male gender has a direct influence on the development of LFH. A thorough knowledge of the occurrence of LFH in mostly aged

Asian males is needed to aid in understanding the development mechanisms of hematoma. To the best of our knowledge, this is the first literature review of cases with LFH. With an increasing number of the elderly people in the general population, there is a need to investigate risk factors such as sexual gender and age for LFH. Further study is needed in this subject.

#### Abbreviations

LF: Ligamentum flavum.

LFH: Ligamentum flavum hematoma.

#### Financial support and sponsorship

Nil.

#### Conflicts of interest

There are no conflicts of interest.

#### REFERENCES

1. Sweasey TA, Coester HC, Rawal H, Blaivas M, McGillicuddy JE. Ligamentum flavum hematoma. Report of two cases. *J Neurosurg* 1992;76:534-7.
2. Kim HS, Kim SW, Lee SM, Shin H. Ligamentum flavum hematoma in the adjacent segment after a long level fusion. *J Korean Neurosurg Soc* 2011;49:58-60.
3. Hirakawa K, Hanakita J, Suwa H, Matsuoka N, Oda M, Muro H, *et al.* A post-traumatic ligamentum flavum progressive hematoma: A case report. *Spine (Phila Pa 1976)* 2000;25:1182-4.
4. Mizuno J, Nakagawa H, Inoue T, Hashizume Y. Ligamentum flavum hematoma in the lumbar spine. *Neurol Med Chir (Tokyo)* 2005;45:212-5.
5. Wild F, Tuettenberg J, Grau A, Weis J, Krauss JK. Ligamentum flavum hematomas of the cervical and thoracic spine. *Clin Neurol Neurosurg* 2014;116:24-7.
6. Kotil K. Severe neurologic deficit caused by chronic ligamentum flavum hematoma: The first case series. *J Neurol Sci* 2015;32:391-8.
7. Maezawa Y, Baba H, Uchida K, Kokubo Y, Kubota C, Noriki S. Ligamentum flavum hematoma in the thoracic spine. *Clin Imaging* 2001;25:265-7.
8. Spuck S, Stellmacher F, Wiesmann M, Kranz R. Case reports: A rare cause of radicular complaints: Ligamentum flavum hematoma. *Clin Orthop Relat Res* 2006;443:337-41.
9. Ak H, Sevinc S, Gulsen I, Akyuz Y, Seckin S. Ligamentum flavum hematoma as a rare cause of failed back surgery. *J Neurol Sci* 2013;30:836-41.
10. Albanese A, Braconi A, Anile C, Mannino S, Sabatino G, Mangiola A. Spontaneous haematoma of ligamentum flavum. Case report and literature review. *J Neurosurg Sci* 2006;50:59-61.
11. Chen HC, Hsu PW, Lin CY, Tzaan WC. Symptomatic hematoma of cervical ligamentum flavum: Case report. *Spine (Phila Pa 1976)* 2005;30:E489-91.
12. Chen J, Liu Z, Zhong G, Qian L, Li Z, Qiao Z, *et al.* Hypertrophy of ligamentum flavum in lumbar spine stenosis is associated with increased miR-155 level. *Dis Markers* 2014;2014:786543.
13. Chi TW, Li KT, Chieng PU. Post-traumatic ligamentum flavum hematoma: A case report. *Kaohsiung J Med Sci* 2004;20:41-4.
14. Cruz-Conde R, Berjano P, Buitron Z. Ligamentum flavum hematoma presenting as progressive root compression in the lumbar spine. *Spine (Phila Pa 1976)* 1995;20:1506-9.
15. Ghent F, Ye X, Yan M, Mobbs RJ. A contrast-enhancing lumbar ligamentum flavum haematoma. *BMJ Case Rep* 2014;2014.
16. Keynan O, Smorgick Y, Schwartz AJ, Ashkenazi E, Floman Y. Spontaneous ligamentum flavum hematoma in the lumbar spine. *Skelet Radiol* 2006;35:687-9.
17. Kono H, Nakamura H, Seki M, Motoda T. Foot drop of sudden onset caused by acute hematoma in the lumbar ligamentum flavum: A case report and review of the literature. *Spine (Phila Pa 1976)* 2008;33:E573-5.
18. Kotani Y, Sudo H, Abumi K, Ito M, Matsubara S, Minami A. Spinal cord compression by hematoma in the cervical ligamentum flavum: A case report. *Spine J* 2012;12:e18-21.
19. Kotil K, Bilge T. A ligamentum flavum hematoma presenting as an L5 radiculopathy. *J Clin Neurosci* 2007;14:994-7.

20. Lee HW, Song JH, Chang IB, Choi HC. Spontaneous ligamentum flavum hematoma in the rigid thoracic spine: A case report and review of the literature. *J Korean Neurosurg Soc* 2008;44:47-51.
21. Matsumoto Y, Fujiwara T, Imamura R, Okada Y, Harimaya K, Doi T, et al. Hematoma of the ligamentum flavum in the thoracic spine: Report of two cases and possible role of the transforming growth factor beta-vascular endothelial growth factor signaling axis in its pathogenesis. *J Orthop Sci* 2013;18:347-54.
22. Minamide A, Yoshida M, Tamaki T, Natsumi K. Ligamentum flavum hematoma in the lumbar spine. *J Orthop Sci* 1999;4:376-9.
23. Miyakoshi N, Kasukawa Y, Ando S, Shimada Y. Two-level ligamentum flavum hematoma in the lumbar spine. Case report. *Neurol Med Chir (Tokyo)* 2008;48:179-82.
24. Miyakoshi N, Shimada Y, Kasukawa Y, Ando S. Ligamentum flavum hematoma in the cervical spine — Case report. *Neurol Med Chir (Tokyo)* 2006;46:556-8.
25. Miyakoshi N, Shimada Y, Okada K, Hongo M, Kasukawa Y, Itoi E. Ligamentum flavum hematoma in the rigid thoracic spinal segments: Case report. *J Neurosurg Spine* 2005;2:495-7.
26. Ohba T, Ebata S, Ando T, Ichikawa J, Clinton D, Haro H. Lumbar ligamentum flavum hematoma treated with endoscopy. *Orthopedics* 2011;34:e324-7.
27. Rudd JW, Williams A, Sudhakar N, Shivane A. Thoraco-lumbar spontaneous ligamentum flavum haematoma. *Br J Neurosurg* 2013;27:543-4.
28. Shimada Y, Kasukawa Y, Miyakoshi N, Hongo M, Ando S, Itoi E. Chronic subdural hematoma coexisting with ligamentum flavum hematoma in the lumbar spine: A case report. *Tohoku J Exp Med* 2006;210:83-9.
29. Sudo H, Abumi K, Ito M, Kotani Y, Takahata M, Hojo Y, et al. Spinalcord compression by ligamentum flavum hematoma in the thoracic spine. *Spine (Phila Pa 1976)* 2009;34:E942-4.
30. Takahashi H, Wada A, Yokoyama Y, Fukushi S, Sakurai T, Shibuya K, et al. Ligamentum flavum haematoma: A report of two cases. *J Orthop Surg (Hong Kong)* 2009;17:212-5.
31. Takahashi M, Satomi K, Hasegawa A, Hasegawa M, Taki N, Ichimura S. Ligamentum flavum hematoma in the lumbar spine. *J Orthop Sci* 2012;17:308-12.
32. Takeno K, Kobayashi S, Miyazaki T, Yayama T, Baba H. Microsurgical excision of hematoma of the lumbar ligamentum flavum. *Joint Bone Spine* 2010;77:351-4.
33. Tamura T, Sakai T, Sairyo K, Takao S, Kagawa S, Katoh S, et al. Hematoma in the cervical ligamentum flavum: Report of a case and review of the literature. *Skeletal Radiol* 2010;39:289-93.
34. Yamaguchi S, Hida K, Akino M, Seki T, Yano S, Iwasaki Y. Ligamentum flavum hematoma in the lumbar spine. *Neurol Med Chir (Tokyo)* 2005;45:272-6.
35. Yuceer N, Başkaya MK, Smith P, Willis BK. Hematoma of the ligamentum flavum in the lumbar spine: Case report. *Surg Neurol* 2000;53:598-600.
36. Shemshaki H, Nourian SM, Fereidan-Esfahani M, Mokhtari M, Etemadifar MR. What is the source of low back pain? *J Craniovertebr Junction Spine* 2013;4:21-4.
37. Bajpai J, Saini S, Singh R. Clinical correlation of magnetic resonance imaging with symptom complex in prolapsed intervertebral disc disease: A cross-sectional double blind analysis. *J Craniovertebr Junction Spine* 2013;4:16-20.
38. Shete KM, Suryawanshi P, Gandhi N. Management of low back pain in computer users: A multidisciplinary approach. *J Craniovertebr Junction Spine* 2012;3:7-10.
39. Kanat A, Yazar U, Kazdal H, Sonmez OF. Introducing a new risk factor for lumbar disc herniation in females: Vertical angle of the sacral curvature. *J Korean Neurosurg Soc* 2012;52:447-51.
40. Kanat A, Yazar U, Ozdemir B, Kazdal H, Balik MS. Neglected knowledge: Asymmetric features of lumbar disc disease. *Asian J Neurosurg* 2015. DOI:10.4103/1793-5482.145573, 2015
41. Huang B, Liu LT, Li CQ, Zhuang Y, Luo G, Hu SY, et al. Study to determine the presence of progenitor cells in the degenerated human cartilage endplates. *Eur Spine J* 2012;21:613-22.
42. Kanat A, Kayaci S, Yazar U, Kazdal H, Terzi Y. Chronic subdural hematoma in adults: Why does it occur more often in males than females? Influence of patient's sexual gender on occurrence. *J Neurosurg Sci* 2010;54:99-103.
43. Miller JA, Schmatz C, Schultz AB. Lumbar disc degeneration: Correlation with age, sex, and spine levels in 600 autopsy specimens. *Spine (Phila Pa 1976)* 1988;13:173-8.
44. Lakemeier S, Schmid R, Foltz L, Rohlfes J, Fuchs-Winkelmann S, Efe T, et al. Increased expression of CD44 in hypertrophied ligamentum flavum and relevance of splice variants CD44v5 and CD44v6. *Acta Neurochir (Wien)* 2012;154:359-65.
45. Cui G, Watanabe K, Miyauchi Y, Hosogane N, Tsuji T, Ishii K, et al. Matrix metalloproteinase 13 in the ligamentum flavum from lumbar spinal canal stenosis patients with and without diabetes mellitus. *J Orthop Sci* 2011;16:785-90.
46. Oh IS, Ha KY. Matrix metalloproteinase-3 on ligamentum flavum in degenerative lumbar spondylolisthesis. *Spine (Phila Pa 1976)* 2009;34:E552-7.
47. Park JB, Kong CG, Suh KH, Chang ED, Riew KD. The increased expression of matrix metalloproteinases associated with elastin degradation and fibrosis of the ligamentum flavum in patients with lumbar spinal stenosis. *Clin Orthop Surg* 2009;1:81-9.
48. Park JB, Lee JK, Park SJ, Riew KD. Hypertrophy of ligamentum flavum in lumbar spinal stenosis associated with increased proteinase inhibitor concentration. *J Bone Joint Surg Am* 2005;87:2750-7.
49. Zhong ZM, Zha DS, Xiao WD, Wu SH, Wu Q, Zhang Y, et al. Hypertrophy of ligamentum flavum in lumbar spine stenosis associated with the increased expression of connective tissue growth factor. *J Orthop Res* 2011;29:1592-7.
50. Shafaq N, Suzuki A, Terai H, Wakitani S, Nakamura H. Cellularity and cartilage matrix increased in hypertrophied ligamentum flavum: Histopathological analysis focusing on the mechanical stress and bone morphogenetic protein signaling. *J Spinal Disord Tech* 2012;25:107-5.
51. Kosaka H, Sairyo K, Biyani A, Leaman D, Yeasting R, Higashino K, et al. Pathomechanism of loss of elasticity and hypertrophy of lumbar ligamentum flavum in elderly patients with lumbar spinal canal stenosis. *Spine (Phila Pa 1976)* 2007;32:2805-11.
52. Tatter SB, Cosgrove GR. Hemorrhage into a lumbar synovial cyst causing an acute cauda equina syndrome. Case report. *J Neurosurg* 1994;81:449-52.
53. He S, Hussain N, Li S, Hou T. Clinical and prognostic analysis of ossified ligamentum flavum in a Chinese population. *J Neurosurg Spine* 2005;3:348-54.
54. Kanat A, Yazar U, Ozdemir B, Coskun ZO, Erdivanli O. Frontal sinus asymmetry: Is it an effect of cranial asymmetry? X-ray analysis of 469 normal adult human frontal sinus. *J Neurosci Rural Pract* 2015;6:511-4.
55. Kazdal H, Kanat A, Findik H, Sen A, Ozdemir B, Batcik OE, et al. Transorbital ultra-sonographic measurement of optic nerve sheath diameter for intracranial midline shift in patients with head trauma *World Neurosurg* 2015. [Epub ahead of print].
56. Kurohata J, Yamada H, Motosuneya T, Maruyama T, Sakai H. Hematoma in the lumbar ligamentum flavum: A report of 4 cases. *Higashihon Seisai Kaishi J East Jpn Orthop Traumatol* 2009;21:38-43.
57. Akca N, Ozdemir B, Kanat A, Batcik OE, Yazar U, Zorba OU. Describing a new syndrome in L5-S1 disc herniation: Sexual and sphincter dysfunction without pain and muscle weakness. *J Craniovertebr Junction Spine* 2014;5:146-50.
58. Kazdal H, Kanat A, Sen A, Kirbas S, Ardic G, Tufekci A, et al. A novel clinical observation in neuroleptic malignant-like syndrome: First demonstration of early progression of hydrocephalus. *J Clin Psychopharmacol* 2015;35:211-2.
59. Turkmenoglu ON, Kanat A, Yolas C, Aydin MD, Ezirmik N, Gundogdu C. First report of important causal relationship between the Adamkiewicz artery vasospasm and dorsal root ganglion cell degeneration in spinal subarachnoid hemorrhage: An experimental study using a rabbit model. *Asian J Neurosurg* 2014.