

Case report

Open Access

Early distant relapse after optimal local control in locally advanced rectal cancer

Javier Gallego-Plazas*¹, Francisco Menarguez-Pina², Natividad Martinez-Banaclocha¹, Vanesa Pons-Sanz¹, Fernando Mingol-Navarro³, Jose A Ruiz-Macia⁴ and Sonia Macia-Escalante¹

Address: ¹Servicio de Oncología Médica, Hospital General Universitario de Elche, Elche, Alicante, Spain, ²Servicios de Cirugía, Hospital Vega Baja, Orihuela, Alicante, Spain, ³y Cirugía, Hospital General Universitario de Elche, Elche, Alicante, Spain and ⁴y Anatomía Patológica, Hospital Vega Baja, Orihuela, Alicante, Spain

Email: Javier Gallego-Plazas* - j.gallegoplazas@gmail.com; Francisco Menarguez-Pina - fmenarguez@coma.es; Natividad Martinez-Banaclocha - noe_mb_2000@yahoo.es; Vanesa Pons-Sanz - v.pons@hotmail.com; Fernando Mingol-Navarro - mingolnavarro_6@hotmail.com; Jose A Ruiz-Macia - josearui@gmail.com; Sonia Macia-Escalante - smacia@tiscali.es

* Corresponding author

Published: 14 July 2008

Received: 8 January 2008

International Seminars in Surgical Oncology 2008, **5**:18 doi:10.1186/1477-7800-5-18

Accepted: 14 July 2008

This article is available from: <http://www.issoonline.com/content/5/1/18>

© 2008 Gallego-Plazas et al; licensee BioMed Central Ltd.

This is an Open Access article distributed under the terms of the Creative Commons Attribution License (<http://creativecommons.org/licenses/by/2.0>), which permits unrestricted use, distribution, and reproduction in any medium, provided the original work is properly cited.

Abstract

We present a case of locally advanced rectal cancer with initial optimal local control after neoadjuvant concurrent chemoradiotherapy followed by surgery; early liver recurrence then occurred and was treated again with curative intent with neoadjuvant combination chemotherapy followed by liver surgery. We reflect on this difficult problem and discuss relevant topics to this case report.

Clinical case

A male of 56 years of age with clinical history of hyperuricemia and gout was hospitalised because of rectal bleeding. His symptoms had started two months prior, and he had been diagnosed with haemorrhoids.

On admission, he had mild anemia. Blood chemistry and coagulation were normal. A full colonoscopy was performed, which detected a 5 cm long, non stenosing rectal tumour, starting after the dentate line, in addition to a sigmoid polyp. Biopsies revealed a rectal adenocarcinoma and a non dysplastic adenomatous polyp in sigmoid colon. Staging studies were completed with tumour markers (CEA and CA 19.9) measurement, echoendoscopy and a thoracic-abdominal-pelvic CT. Tumour markers values were within normal range, echoendoscopy showed a 6 cm long uT3N0 rectal cancer, and CT detected an eccentric

thickening of the rectal wall, compatible with a rectal cancer with no lymph node or visceral involvement. Final diagnosis was a rectal adenocarcinoma located in the middle-inferior thirds, clinical stage T3 N0 M0 (Figures. 1, 2).

His clinical case was discussed shortly after in our Digestive Tumours Committee, and neoadjuvant combined chemoradiotherapy followed by surgery were planned. The patient received capecitabine 900 mg/m²/12h d1-5/7d concurrent with radiotherapy, 45 Gy (180 cGy/d) [1]. Treatment was generally well tolerated, with moderate cystitis and mild epithelitis as major adverse effects. Reassessment after neoadjuvant treatment showed neither blood analysis abnormalities, nor CT suspicion of residual disease (Figure. 3).

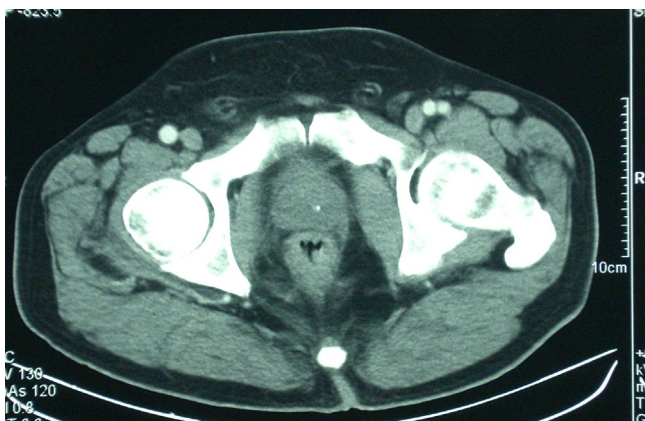

Figure 1
CT at diagnosis showing an eccentric thickening of the rectal wall, compatible with a rectal cancer with no lymph node or visceral involvement.

Fifty-three days after completing chemoradiotherapy patient underwent surgery. An abdominoperineal (AP) resection, including with mesorectal excision (TME), was performed with no surgical complications. Subsequent pathological analysis revealed a complete pathological response (TRG 1) [2] (Figure. 4); with none out of four isolated lymph nodes involved; mesorectal excision was complete and the circumferential margin was greater than 1 cm.

Five weeks after surgery the patient was again referred to Clinical Oncology, were, once we had confirmed the absence of disease by blood analysis and imaging, adju-

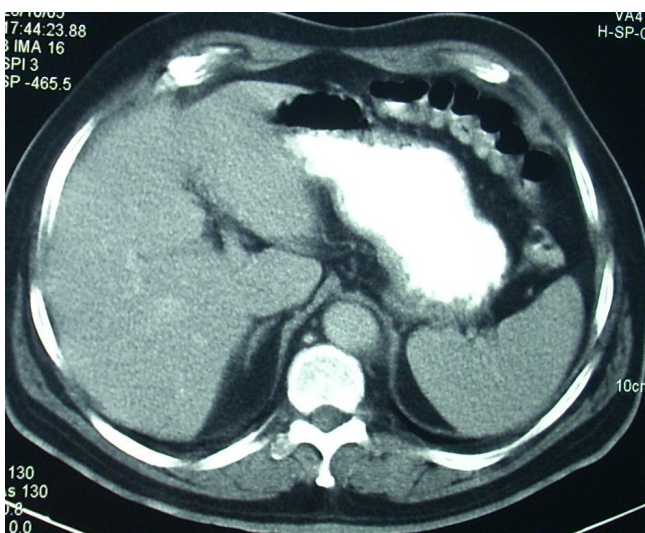


Figure 2
CT at initial diagnosis showing absence of liver involvement.

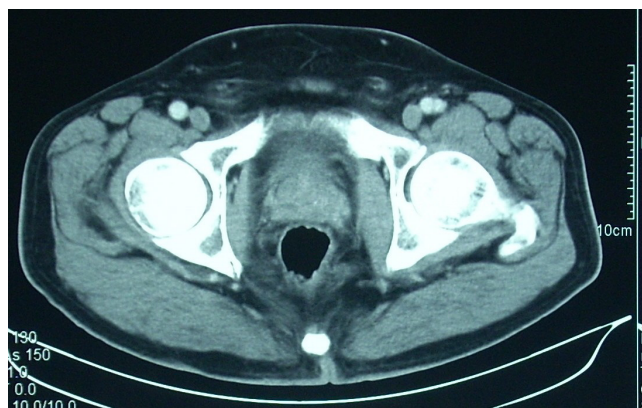


Figure 3
CT reassessment of primary rectal tumour after neoadjuvant treatment.

vant treatment was planned. Adjuvant fluorouracil-based chemotherapy was then administered in order to complete a total of six months neoadjuvant and adjuvant treatment [3,4]. Thoracic-abdominal-pelvic CT performed shortly after completing adjuvant chemotherapy, and this showed only surgical changes; colonoscopy through the end colostomy was normal, and blood analysis, including CEA and CA 19.9 levels, were also normal. The patient entered into our three-monthly periodic follow-up program [5].

Eighteen months after initial diagnosis, the patient was asymptomatic. Programmed review detected increased CEA value (25 u/ml, normal value < 10) associated with a left lobe liver metastatic lesion of size 6 cms. in thoracic-abdominal-pelvic CT (Figure. 5). PET scan performed showed no other metastatic sites [6]. The patient received neoadjuvant chemotherapy with combination of intravenous fluorouracil c.i., oxaliplatin [7]. After completing four cycles, reevaluation tests showed normalisation of CEA levels and complete disappearance of the liver lesion (Figure. 6). Patient was then referred to surgery. He subsequently had a liver trisegmentectomy, involving segments 1, 2 and 3 (Figure. 7). Pathological analysis revealed a 1 cm residual focus of metastatic non-expressing EGFR colorectal adenocarcinoma. Recently, six weeks after liver surgery, and in the absence of residual disease, patient has started adjuvant chemotherapy with FOLFOX-4, planned to last for four months.

Discussion

Concurrent preoperative chemoradiotherapy has proven superior to other treatment strategies against locally advanced rectal cancer. Neoadjuvant combined treatment reduces local relapse compared to adjuvant combined treatment [8] and exclusive preoperative radiotherapy [9,10]. Nevertheless, this benefit not always means an

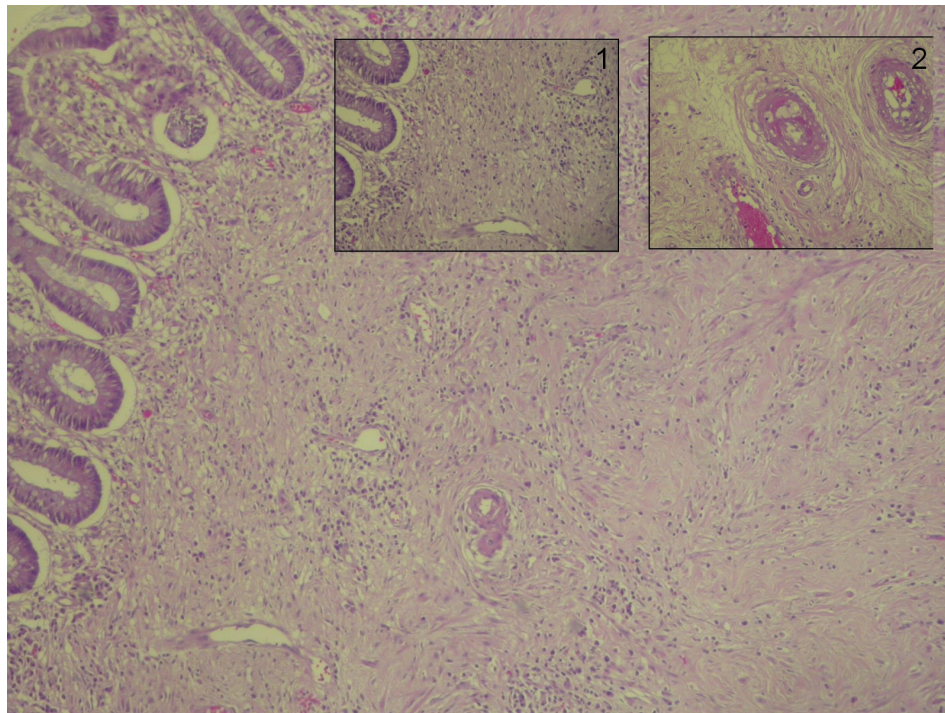


Figure 4
Submucosal fibrotic scarring. Detail of vertical vessels (1). Detail of radiotherapy induced obliterant vasculitis with foamy histiocytes in intima (2).

increase in terms of overall survival. Inadequate doses of chemotherapy, with radiosensitizer but without systemic effect, and sub-optimal chemotherapy strategies may both well explain this paradox. The clinical case previously commented is an example of what may occur in early stage rectal cancer patients. Far from presenting local

relapse, distant metastases may occur, and is being seen with increasing frequency.

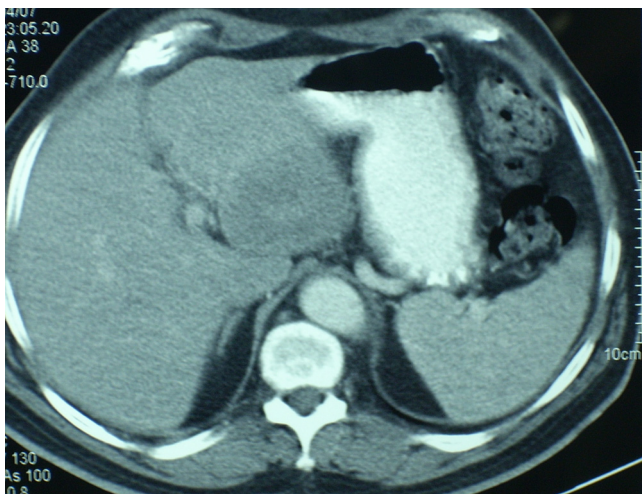


Figure 5
Left lobe liver metastatic lesion of size 6 cms. in thoracic-abdominal-pelvic CT performed in February 2007.

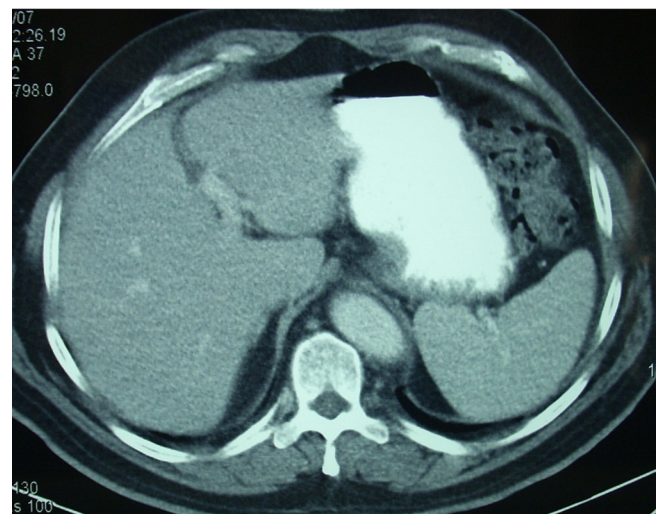


Figure 6
Clinical complete response assessed in thoracic-abdominal-pelvic CT performed in May 2007, after neoadjuvant systemic chemotherapy.

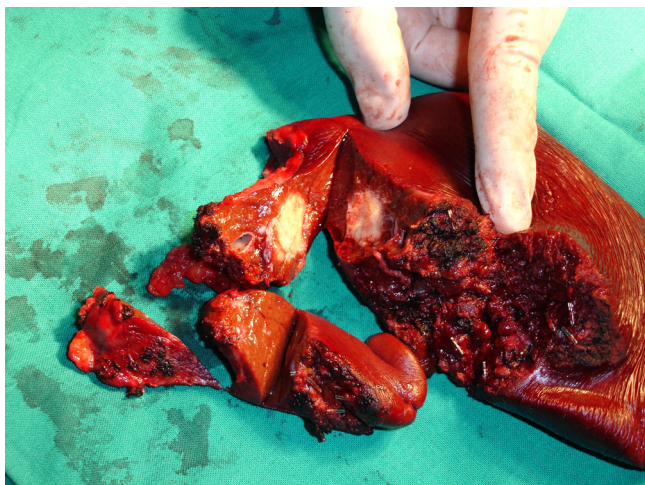


Figure 7
Trisegmentectomy (segments 1, 2, and 3) of the liver, showing residual disease after neoadjuvant chemotherapy.

By combined neoadjuvant chemoradiotherapy, followed by surgery including total mesorectal excision, it is clear that very good local control of rectal cancer can be achieved, with five-year local relapse rates of 6–8% [8-10]. This very good local control rate may be optimized when effectiveness of neoadjuvant treatment is demonstrated after surgery of regressive disease, and adjuvant chemotherapy with a similar regimen to that previously used in the neoadjuvant setting is completed [4]. The challenge on the horizon is then to reduce distant relapse, in order to prolong overall survival. The best way to accomplish this goal might be to divide preoperative treatment into two steps: neoadjuvant combined chemotherapy followed by neoadjuvant concurrent chemoradiotherapy. First step would include only combined chemotherapy, so that optimal doses and regimens with demonstrated systemic effect could be safely administered, within an attempt to control micrometastatic systemic disease. In a second stage treatment would focus on local control by concurrent administration of radiotherapy and chemotherapy, this time using adjusted doses in order to achieve synergistic effect avoiding excessive toxicity. This approach has already been partially successfully tested in phase II clinical trials [11], and is yet to be confirmed in on course phase III clinical trials.

Fortunately, continuous investigation-based advances have made potentially curative treatment strategies available to patients, as the one here reported, even in the case of distant relapse, and when no evidence of extrahepatic disease is found [6]. Combination chemotherapy with fluoropyrimidines (fluorouracil or capecitabine), oxaliplatin, or irinotecan, and more recently bevacizumab or cetuximab, has improved response rates, progression-free

survival and, in three trials, overall survival [12-15]. Combinations of three of these drugs have achieved best response rates so far in metastatic colorectal cancer, and so should be advised in the neoadjuvant setting of potentially resectable liver only metastatic disease [12-15]. Recent results favour, in case of resectable or potentially resectable liver only metastatic disease, combination systemic perioperative treatment in order to achieve best overall survival [7,16,17]. Eventhough complete clinical response to neoadjuvant chemotherapy may be achieved, resection of metastatic sites, when possible, is mandatory [18].

In conclusion, although recent improvements in treatment of advanced colorectal cancer make it possible to offer certain subsets of patients potential healing even in case of relapse after early disease, future treatment strategies in locally advanced rectal cancer need to focus not only in achieving optimal local control but in avoiding distant failure.

Authors' contributions

JG wrote the manuscript and was responsible for main decisions and assistency related to this patient, FM was responsible for rectal surgery, NM represented Clinical Oncology Department in multidisciplinary team sessions, VP was second assistant physician for this patient, FM was responsible for liver surgery, JAR was responsible for anatomopathology analysis, and SM was responsible for figures.

References

1. Yerushalmi R, Idelevich E, Dror Y, Stemmer SM, Figer A, Sulkes A, Brenner B, Loven D, Dreznik Z, Nudelman I, Shani A, Fenig E: **Pre-operative chemoradiation in rectal cancer: Retrospective comparison between capecitabine and continuous infusion of 5-fluorouracil.** *J Surg Oncol* 2006, **93**:529-533.
2. Mandard AM, Dalibard F, Mandard JC, Marnay J, Henry-Amar M, Petiot JF, Roussel A, Jacob JH, Segol P, Samama G: **Pathologic assessment of tumour regression after preoperative chemoradiotherapy of esophageal carcinoma. Clinicopathologic correlations.** *Cancer* 1994, **73**:2680-2686.
3. Wolmark N, Rockette H, Mamounas E, Jones J, Wieand S, Wickerham DL, Bear HD, Atkins JN, Dimitrov NV, Glass AG, Fisher ER, Fisher B: **Clinical trial to asses the relative efficacy of fluorouracil and leucovorin, fluorouracil and levamisole, and fluorouracil, leucovorin and levamisole in patients with Dukes B and C carcinoma of the colon: results from the NSABP C-04.** *J Clin Oncol* 1999, **17**(11):3553-3559.
4. Collette L, Bosset JF, den Dulk M, Nguyen F, Mineur L, Maingon P, Radosevic-Jelic L, Piérart M, Calais G, European Organisation for Research and Treatment of Cancer Radiation Oncology Group: **Patients with curative resection of cT3-4 rectal cancer after preoperative radiotherapy or chemoradiotherapy: Does anybody benefit from adjuvant fluorouracil-based chemotherapy? A trial of the European organisation for research and Treatment of cancer radiation oncology group.** *J Clin Oncol* 2007, **25**(28):4379-4386.
5. Locker GY, Hamilton S, Harris J, Jessup JM, Kemeny N, Macdonald JS, Somerfield MR, Hayes DF, Bast RC Jr, ASCO: **ASCO 2006 Update of recommendations for the use of tumor markers in gastrointestinal cancer.** *J Clin Oncol* 2006, **24**(33):5313-5327.
6. Joyce DL, Wahl RL, Patel PV, Schulick RD, Gearhart SL, Choti MA: **Preoperative positron emission tomography to evaluate**

- potentially respectable hepatic colorectal metastases. *Arch Surg* 2006, **141**(12):1220-1226.**
7. Nordlinger B, Sorbye H, Glimelius B, Poston GJ, Schlag PM, Rougier P, Bechstein WO, Primrose JN, Walpole ET, Finch-Jones M, Jaeck D, Mirza D, Parks RW, Collette L, Praet M, Bethe U, Van Cutsem E, Scheihauer W, Gruenberger T, for the EORTC Gastro-Intestinal Tract Cancer Group, Cancer Research UK, Arbeitsgruppe Lebermetastasen und-tumoren in der Chirurgischen Arbeitsgemeinschaft Onkologie (ALM-CAO), Australasian Gastro-Intestinal Trials Group (AGITG), and Fédération Francophone de Cancérologie Digestive (FFCD): **Perioperative chemotherapy with FOLFOX4 and surgery versus surgery alone for resectable liver metastases from colorectal cancer (EORTC Intergroup trial 40983): a randomised controlled trial.** *Lancet* 2008, **371**(9617):1007-1016.
 8. Sauer R, Becker H, Hohenberger W, Rödel C, Wittekind C, Fietkau R, Martus P, Tschmelitsch J, Hager E, Hess CF, Karstens JH, Liersch T, Schmidberger H, Raab R, German Rectal Cancer Study Group: **Preoperative versus postoperative chemoradiotherapy for rectal cancer.** *N Eng J Med* 2004, **351**:1731-1740.
 9. Bosset JF, Calais G, Mineur L, Maingon P, Radosevic-Jelic L, Daban A, Bardet E, Beny A, Ollier JC, Collette L: **Preoperative radiation in rectal cancer. Effect and timing of additional chemotherapy 5-year results of the EORTC 22291 trial.** *J Clin Oncol* 2005, **16S**:3505. (abstr)
 10. Gerard JP, Conroy T, Bonnetain F, Bouché O, Chapet O, Cluson-Dejardin MT, Untereiner M, Leduc B, Francois E, Maurel J, Seitz JF, Buecher B, Mackiewicz R, Ducreux M, Bedenne L: **Preoperative radiotherapy with or without fluorouracil and leucovorin in T3-4 rectal cancers. results of FFCD 9203 trial.** *J Clin Oncol* 2006, **24**(28):4620-4625.
 11. Chau I, Brown G, Cunningham D, Tait D, Wotherspoon A, Norman AR, Tebbut N, Hill M, Ross PJ, Massey A, Oates J: **Neoadjuvant capecitabine and oxaliplatin followed by synchronous chemoradiation and total mesorectal excision in magnetic resonance imaging-defined poor-risk rectal cancer.** *J Clin Oncol* 2006, **24**:668-674.
 12. Saunders M, Iveson T: **Management of advanced colorectal cancer: state of the art.** *Br J Cancer* 2006, **95**:131-138.
 13. Saltz L, Clarke S, Díaz-Rubio E, Schiethauer W, Figer A, Wong R, Koski S, Lichinitser M, Yang T, Cassidy J: **Bevacizumab in combination with XELOX or FOLFOX 4: Updated efficacy results from XELOX-1/N016966, a randomized phase III trial in first-line metastatic colorectal cancer.** *J Clin Oncol* 2007, **18S**(suppl):4028. (abstr)
 14. Van Cutsem E, Nowacki M, Lang I, Cascinu S, Schepotin I, Maurel J, Rougier P, Cunningham D, Nippgen J, Köhne C: **Randomized phase III study of irinotecan and fluorouracil/FA with or without cetuximab in the first-line treatment of patients with metastatic colorectal cancer: The CRYSTAL trial.** *J Clin Oncol* 2007, **18S**(suppl):4000. (abstr)
 15. Falcone A, Ricci S, Brunetti I, Pfanner E, Allegrini G, Barbara C, Crinò N, Benedetti G, Evangelista W, Fanchini L, Cortesi E, Picone V, Vitello S, Chiara S, Granetto C, Porcile G, Fioletto L, Orlandini C, Andreuccetti M, Masi G, Gruppo Oncologico Nord Ovest: **Phase III trial of infusional fluorouracil, leucovorin, oxaliplatin and irinotecan (FOLFOXIRI) compared with infusional fluorouracil, leucovorin, and irinotecan (FOLFIRI) as first line treatment for metastatic colorectal cancer: The Gruppo Oncologico Nord Ovest.** *J Clin Oncol* 2007, **25**(13):1670-1676.
 16. Leonard GD, Brenner B, Kemeny NE: **Neoadjuvant chemotherapy before liver resection for patients with unresectable liver metastases from colorectal carcinoma.** *J Clin Oncol* 2005, **23**:2038-2048.
 17. Bilchik AJ, Poston G, Curley SA, Strasberg S, Saltz L, Adam R, Nordlinger B, Rougier P, Rosen LS: **Neoadjuvant chemotherapy for metastatic colon cancer: A cautionary note.** *J Clin Oncol* 2005, **23**:9073-9078.
 18. Benoist S, Brouquet A, Penna C, Julié C, El Hajjam M, Chagnon S, Mitry E, Rougier P, Nordlinger B: **Complete response of colorectal liver metastases after chemotherapy: Does it mean cure?** *J Clin Oncol* 2006, **24**:3939-3945.

Publish with **BioMed Central** and every scientist can read your work free of charge

"BioMed Central will be the most significant development for disseminating the results of biomedical research in our lifetime."

Sir Paul Nurse, Cancer Research UK

Your research papers will be:

- available free of charge to the entire biomedical community
- peer reviewed and published immediately upon acceptance
- cited in PubMed and archived on PubMed Central
- yours — you keep the copyright

Submit your manuscript here:
http://www.biomedcentral.com/info/publishing_adv.asp

