

Received: 2016.06.03
Accepted: 2016.08.02
Published: 2017.02.26

A New Surgical Technique for Closure of Pilonidal Sinus Defects: Triangular Closure Technique

Authors' Contribution:
Study Design A
Data Collection B
Statistical Analysis C
Data Interpretation D
Manuscript Preparation E
Literature Search F
Funds Collection G

ABDEF 1 **Mehmet Mutaf**
ABCEFG 2 **Metin Temel**
DFG 3 **Mustafa Nihat Koç**

1 Division of Plastic Surgery, Bodrum Acibadem Hospital, Muğla, Turkey
2 Division of Plastic Surgery, Mustafa Kemal University, Hatay, Turkey
3 Division of Plastic Surgery, Gaziantep University, Gaziantep, Turkey

Corresponding Author:

Source of support:

This study was partially presented as an oral presentation at the XXXIII Annual Congress of the Turkish Society of Plastic, Reconstructive and Aesthetic Surgery, September 14–19, 2011, in İzmir, Turkey

Metin Temel, e-mail: drmetintemel@hotmail.com

Departmental sources

Background:

We present a clinical experience with a new local flap procedure, namely the triangular closure technique, for reconstruction of sacrococcygeal skin defects resulting from excision of the pilonidal sinus.

Material/Methods:

In this technique, the defect is surgically converted to a triangle in shape. Then, the triangular defect is closed by transposition of 2 skin flaps designed in an unequal z-plasty manner. Over 6 years, this technique has been used for closure of defects of chronic pilonidal sinus disease in 27 patients (6 females, 21 males). The size of the defect ranged between 3.5 cm and 12 cm in dimension.

Results:

A tension-free defect closure was obtained in all patients. All flaps except one healed with no complications. A mean follow-up of 3.62 ± 1.77 months revealed aesthetically and functionally acceptable results with the obliteration of the natal cleft in all patients. No recurrence was observed in the follow-up period.

Conclusions:

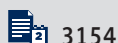
The triangular closure technique was found to be a useful technique for the treatment of pilonidal sinus with favorable results regarding the time before return to work.

MeSH Keywords:

Dermatologic Surgical Procedures • Pilonidal Sinus • Surgical Flaps

Full-text PDF:

<http://www.medscimonit.com/abstract/index/idArt/899879>



3154



1



6



38



Background

Pilonidal sinus (PS) was first described by Hodges in 1880 [1] and is diagnosed by the finding of a characteristic epithelial track situated in the skin of the natal cleft, a short distance behind the anus and generally containing hair.

The principles of PS treatment are total excision of the sinus tract, tension free and durable closure of the resultant defect with well-vascularized tissue, obliteration of the intergluteal sulcus, and prevention of recurrence. A close relationship exists between success of wound closure and postoperative morbidity and recurrence in the surgical treatment of PS. Although various surgical methods have been described for reconstruction of PS, including shaving [2], phenol application [3], unroofing and curettage [4], open treatment, repair with partial and primary suture [5], repair with a local flap [6–11], and repair with a local or distant faciocutaneous and musculocutaneous flap [12], most of these procedures fail to achieve the above-mentioned goals all together.

In this study, we present a new local flap alternative, namely Mutaf's triangular closure technique, for surgical treatment of PS.

Material and Methods

Patients and study design

All procedures were performed in accordance with the ethical standards of the Institutional Research Committee and with the guidelines set forth in the Declaration of Helsinki. Prior to enrollment, each patient provided written informed consent.

From May 2005 to July 2011, Mutaf's triangular closure procedure was successfully used in 27 (6 female, 21 male) cases of PS. During the study, the patient's age, gender, body mass index (BMI), duration of symptoms, disease exacerbations, previous history of surgical procedures, and history of abscess were recorded. Following the triangular closure procedure, the type of anesthesia utilized, duration of hospitalization, postoperative complications, and length of follow-up were recorded.

All of the patients who were operated on for sacrococcygeal pilonidal disease were included in this study. Patients who were lost to follow-up in the preoperative period were excluded from this study. In the case of acute suppurative PS, patients were treated with a second-generation cephalosporin antibiotic for 10 days with or without abscess drainage and were reevaluated for surgery following medical treatment. As soon as the cellulitis and acute inflammation resolved, an elective surgery was planned. All of the patients were re-examined the

day before the surgery. The surgical area was marked, and patients were advised to clean the area with depilatories and to take a bath. On the operative day, a rectal cleansing enema was given 4 h before surgery.

Exclusion criteria of the study were the following: American Society of Anesthesiologists (ASA) group higher than III, risk of malignant hyperthermia, obesity (body mass index, 35 kg/m²), insulin-dependent diabetes, and severe allergy to local anesthetics or other medications.

Surgical technique

The operation is performed with the patient in a prone position and under spinal anesthesia or local anesthesia. A single dose of first-generation cephalosporin group antibiotic (1 g IV) was administered to patients immediately before the skin incision was made. The surgical area was exposed by lateral traction of the buttocks with adhesive tapes and was cleaned with 10% povidone-iodine. To ensure complete resection of the PS, the lesion is stained with methylene blue, which is given to the fistulas before the operation. The Langer lines on the gluteal and back region were considered in flap design since better aesthetic outcomes would be obtained by camouflaging the scar tissue within these. The excision area was delineated according to the sinus orifice localizations and the expanse of natal cleft in order to excise all the diseased tissue and to achieve a flattened natal cleft. Following determination of the borders of the sinus, an acute triangle (ABC) is outlined as the sinus placed at the middle of the triangle (Figure 1). Then, the sinus is removed in an unblock manner with the overlying skin. By using a ruler and a sterile skin marker, the flaps are designed on the patient. Firstly, an imaginary point (x) is defined on the longest margin of the triangle as the distance from the corner to this imaginary point is almost equal to the base of the triangle. Then, using an unequal z-plasty (45°/60°) design, two triangular flaps (f1 and f2) are obtained. As required, the lateral limb of flap 2 is slightly extended (y) to equalize the limbs of the z-plasty. As an important point, while making a decision about surgical design of large flaps, locations of the perforators arising from gluteal muscles should be taken into consideration to provide a better blood supply for the flaps (Figure 2). Moreover, placements of the resultant scar lines should be planned carefully to avoid the midline scar formation and to achieve obliteration of the deep natal cleft in the sacrococcygeal region, thereby preventing subsequent late-term recurrence. Four different flaps may be designed using the perforators on the sacrococcygeal region (Figure 2). Once the flaps are designed and elevated from the gluteal fascia, the f1 is transposed over the defect area, while the f2 is used to cover the donor defect of the f1. Bipolar cautery is used to achieve dissection and hemostasis. Suction drains are placed under the flaps, and the skin is closed in two layers. The subcutaneous

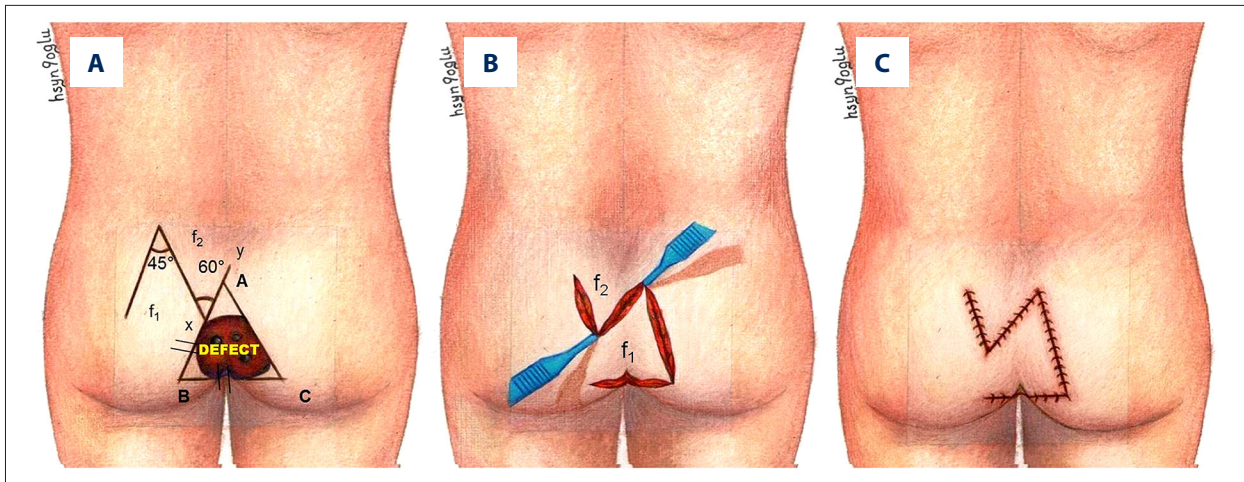


Figure 1. Illustration showing design of Mutaf's triangular closure technique. (A) In this procedure, following extirpation of the lesion, the shape of the skin defect is surgically converted to a triangle. An imaginary point (x) is defined on the longest margin of the triangle as the distance from the corner to this imaginary point is almost equal to the base of the triangle. Then, two triangular flaps identified as f1 and f2 are designed in an unequal z-plasty (45°/60°) manner. As required, the lateral limb of flap 2 is slightly extended (y) to equalize the limbs of the z-plasty. (B) After the flaps are elevated, the f1 is transposed over the defect area, while the f2 is used to cover the donor defect of the f1. (C) The view following closure.

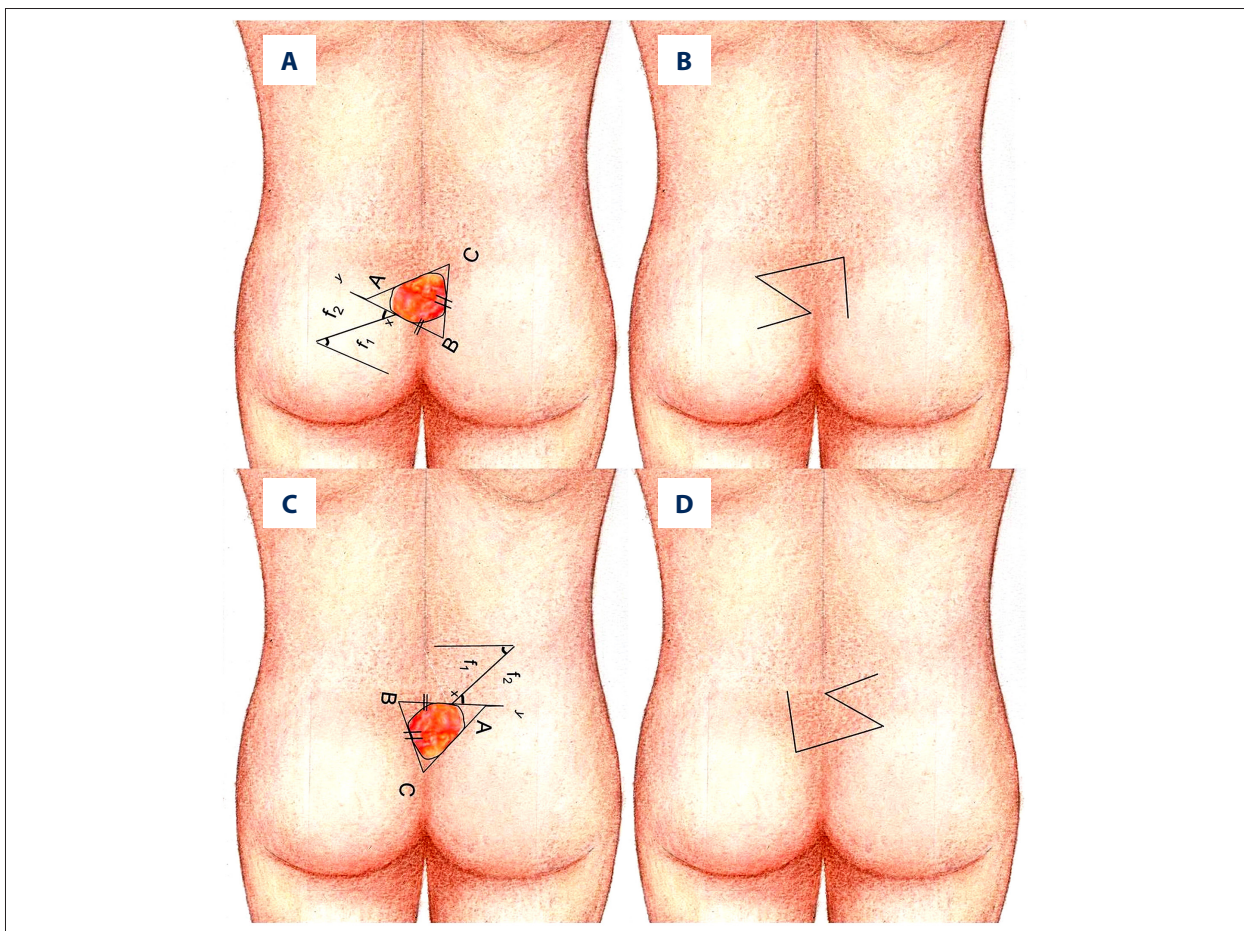


Figure 2. Illustration for the alternatives of the flap in different positions and the shape of the scar. (A, B) Inferior vertical design of the defect and the shape of the scar. (C, D) Superior vertical design of the defect and the shape of the scar.

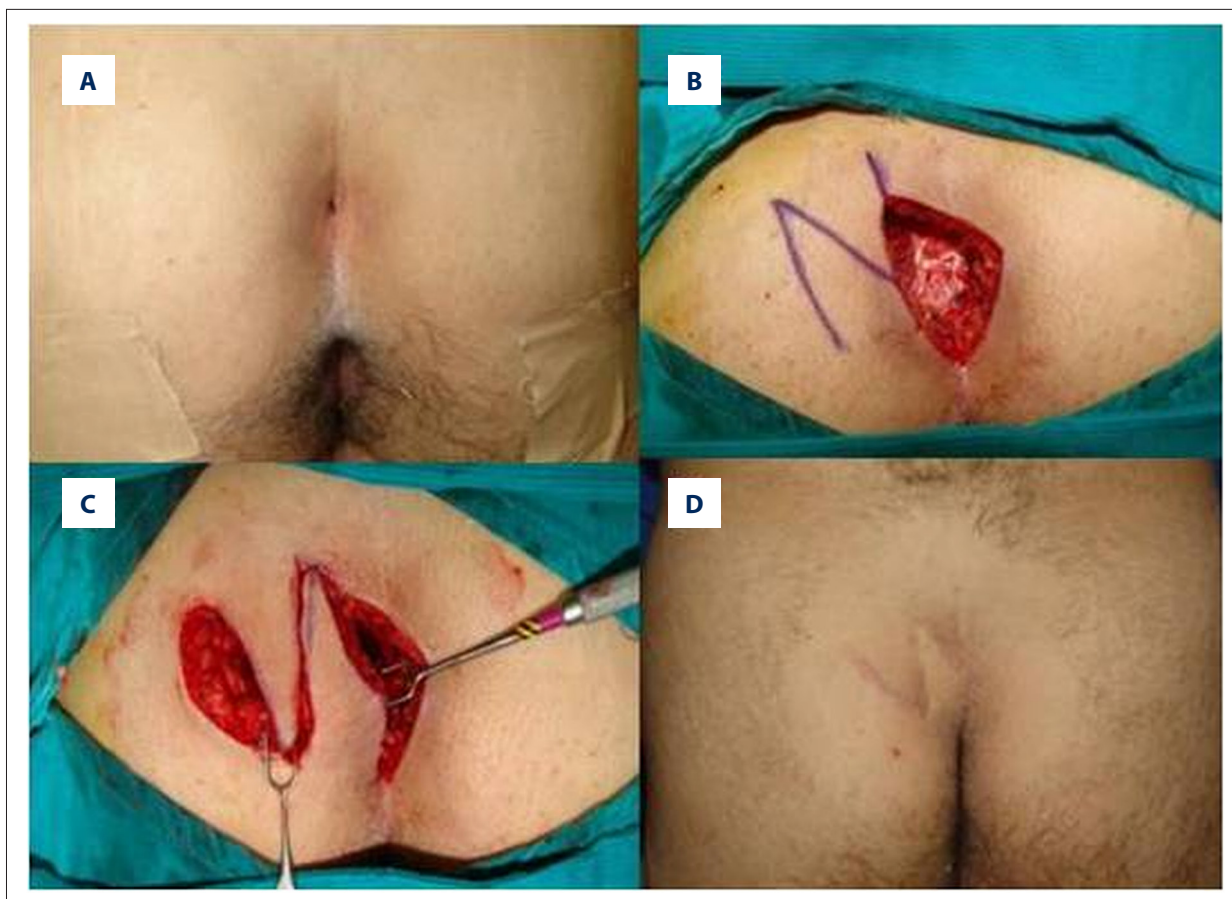

Figure 3. (A) A 31-year-old male patient was admitted to our clinic with a 6-month history of recurrent infection at the midline anal region. (B) After total excision of all sinus tracts was achieved, the size of the resultant defect was 8 cm wide. (C) Two flaps were elevated as pure cutaneous flaps in an unequal z-plasty manner. The first flap was transposed to the defect area, while the second flap was used to cover the donor site of the first flap. Skin closure was done in a 2-layered fashion. (D) The patient healed with no complications. It is seen that the natal cleft was obliterated, and scars did not remain in the midline. There was no recurrence during the 1-year follow-up period.

layer is approximated with 3-0 polyglactin interrupted sutures, and the skin is closed with 4-0 polypropylene sutures.

While applying the technique, we don't search the gluteal artery perforators especially via use of Doppler. Random flaps are applied using this technique. We try to conserve the perforators located near the flap pedicle during the operation.

It is suggested that the patient rest until the suction drains are removed 2 to 3 days after surgery. Thereafter, the patient is permitted to start walking step-by-step. The sutures are removed approximately 10 days after surgery. Additionally, patients are instructed on self-hygiene, avoiding contact sports for one month, and the use of depilatories for one month. Patients are called for monthly follow-up examinations in the first 3 months postoperation and for quarterly follow-up examinations thereafter until a year has passed.

Illustrative cases

Case 1

A 31-year-old male patient was admitted to our clinic with a 6-month history of recurrent infection at the midline anal region (Figure 3). Under spinal anesthesia with the patient in a prone position, after shaving off the hair and cleaning the area with povidone-iodine, methylene blue dye was injected in the external openings to visualize the tract and its branches. An elliptical midline incision including all sinus openings was done, and total excision of all sinus tracts was achieved. The resultant defect was 8 cm wide. Then, 2 flaps were elevated as pure cutaneous flaps in an unequal z-plasty manner, and the first flap was transposed to the defect area, while the second flap was used to cover the donor site of the first flap. Skin closure was done in a 2-layered fashion. The patient healed with no complications. There was no recurrence during the 4-year follow-up period.

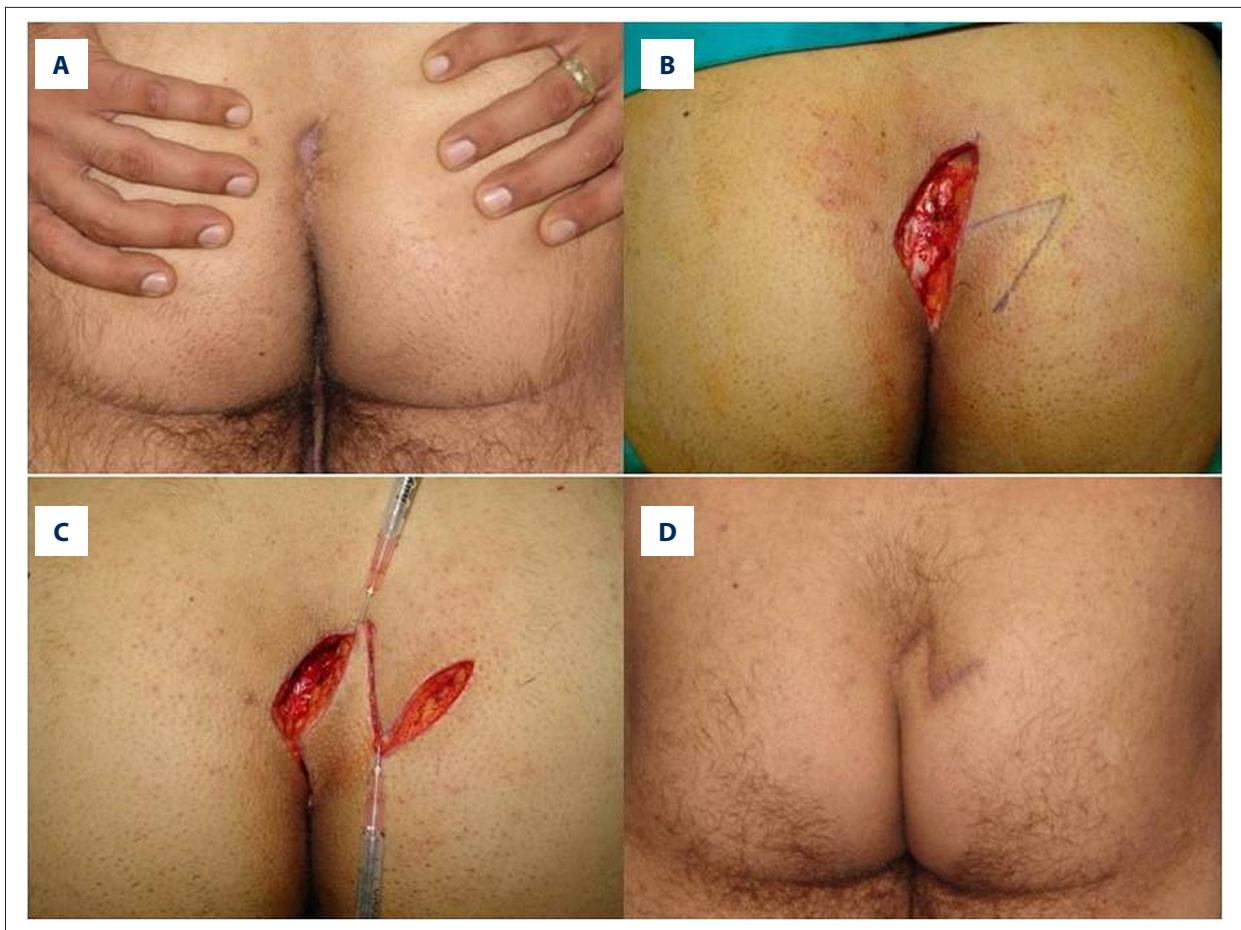


Figure 4. (A) A 25-year-old male patient presented with recurrent pilonidal sinus disease. He had been operated on with excision and primary closure of the defect. (B) The planning of the flaps. An ellipse of skin including all the pilonidal sinus was removed asymmetrically from the most affected side of the intergluteal cleft while sparing subcutaneous fat. The defect was 5×4 cm in size. (C) Elevation of the flap. (D) At the first postoperative year, it was seen that a satisfactory cosmetic and functional result was obtained with no recurrence.

Case 2

A 25-year-old male patient presented with recurrent PS disease. He had been operated on with excision and primary closure of the defect. He had a foul-smelling discharge despite 3 weeks of antibiotherapy. The patient was placed in a prone position with the buttocks taped apart to expose the deep intergluteal cleft. He was sedated by spinal anesthesia followed by intradermal and subcutaneous injection of local anesthesia with adrenaline. An ellipse of skin including all PS was removed asymmetrically from the most affected side of the intergluteal cleft while sparing subcutaneous fat. The defect of 5×4 cm in size was covered with Mutaf's triangular closure procedure (Figure 4). The patient healed uneventfully. At 2 years postoperatively, a satisfactory cosmetic and functional result was obtained with no recurrence.

Case 3

A 35-year-old man with PS disease was referred to us. On physical examination he had a fistula of 2 mm with surrounding hyperemia of cutaneous and subcutaneous tissue of 10 cm width. A foul-smelling discharge was evident after moderate pressure was applied to the lesion. A microbiological culture was obtained, and the patient was started on prophylactic antibiotherapy. The patient was operated on once findings of infection faded. Under spinal anesthesia with the patient in a prone position, methylene blue dye was injected in the external openings to visualize the tract and its branches, and a wide excision of all sinus tracts was achieved. The resultant defect was 15×12 cm in diameter. The defect was closed via the Mutaf's triangular flaps planned horizontally (Figure 5). Minimal flap necrosis occurred in the tip of flap 1. The revision was made under local anesthesia, and healing was achieved

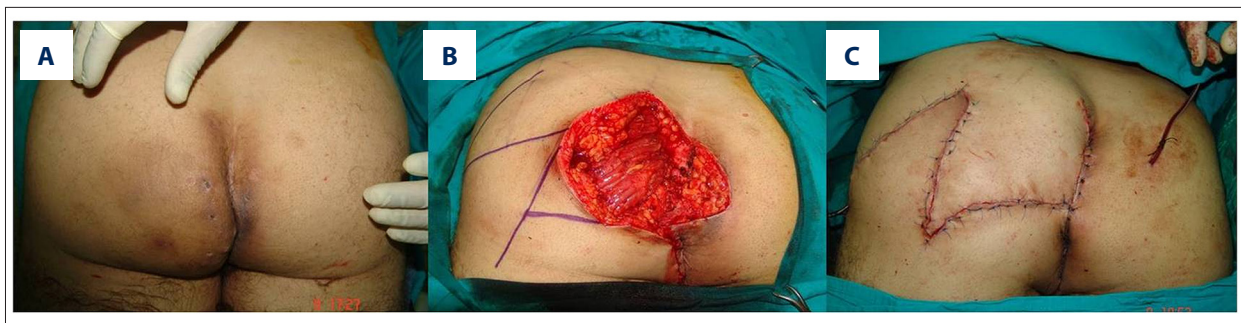


Figure 5. (A) A 35-year-old man was referred to us with recurrent pilonidal sinus disease. On physical examination he had a fistula of 2 mm with surrounding hyperemia of cutaneous and subcutaneous tissue of 8 cm in width. (B) A wide excision of all sinus tracts was achieved and resultant defect was 15×12 cm in diameter. The defect was closed via the Mutaf's triangular flaps planned horizontally. (C) Posterior view after suturation.

without any problems. There was no recurrence seen during 3 years of follow-up.

Results

A total of 27 patients, including 6 females (22.22%) and 21 males (77.77%), composed the study group. The age distribution of the patients ranged from 24 years to 38 years (mean \pm SD 31 \pm 4.49 years). The median BMI of the patients was 24.3 \pm 2.8 kg/m² (20–29 kg/m²). Of the patients, 66.66% (n=18, BMI=18.5–24.9 kg/m²) were normal weight, and 33.33% (n=9, BMI=25.0–29.9 kg/m²) were overweight.

Complaints of patients on admission were discharge, swelling, and pain. Mean duration of complaints was 22 months (1 month to 3 years). Of the patients, 18.51% (n=5) had one and 37.03% (n=10) had two episodes of pilonidal sinus disease exacerbation within the median period of 2 months (1–12 months) prior to surgery. Four patients (14.81%) had pilonidal abscess preoperatively, and the median time between abscess drainage and surgery was 24 days (range=14–60 days). *Staphylococcus aureus* (n=2) and *Streptococcus* strains (n=2) were encountered in the abscess cultures, and the remaining 23 patients had chronic infection. Nine patients had recurrent disease following treatment by primary closure (n=5, 18.51%), Karydakias flap and its modifications (n=3, 11.11%), and Limberg flap (n=1, 3.70%) in our hospital by the general surgeons. The patients were operated on before recurrent disease was observed within 1 month and two months after the previous surgery.

Twelve patients (44.44%) were operated on under local anesthesia, and 15 (55.55%) were operated on under general anesthesia. The median operative time was 41.03 \pm 11.11 min (range=30–70 min). The size of the resultant defects ranged from 3.5 to 12 cm in dimension (width mean \pm SD/length mean \pm SD: 7.33 \pm 2.40/5.14 \pm 2.10 cm). A midline sinus outlet was

detected in 23 patients, whereas in the remaining 4 patients, a lateral sinus outlet was detected. Hospital stay ranged from 1 to 3 days, and the suction drains were left for 1–3 days post-operatively. Patients were confined in bed for 2.37 \pm 1.69 (mean \pm SD) days; the mean \pm SD time before returning to work was 3.62 \pm 1.77 days (4–10 days).

In all patients, a successful tension-free and durable closure of the defect was obtained with reduction of the depth of the natal cleft. All patients healed uneventfully, except for one patient (3.7%) who had flap tip necrosis as a result of the considerably large defect (15×12 cm) and one patient who had maceration of the suture line as a result of immobilization. These patients were treated with wound care. In case 3, the revision of the wound was made under local anesthesia. Because the defects were closed with alike neighboring skin, an excellent skin match was obtained. A mean follow-up of 3.62 \pm 1.77 months (6 months to 3 years) revealed superior aesthetic results with fine scars in all patients. In the long term, there was no recurrence and no patients except one required secondary surgery.

Discussion

Although it has been reported on various regions of the body including the umbilical region [13], the interdigital region of the hands (hairdressers' disease) [14], and the axillar region [15], PS is most commonly seen in the midline of the sacrococcygeal region. Sacrococcygeal PS is a common and well-recognized entity. A critical predisposing factor for pilonidal disease is the existence of a deep natal cleft and the presence of hair within the cleft. As a rule, PS has been treated with the surgery, and many surgical approaches have been reported. The principles in treatment of PS are complete excision of the sinus tract, tension-free and durable closure of the resultant defect with a well-vascularized tissue, obliterating the natal cleft, prevention of recurrence, and also keeping the period of hospital care and the period before returning to work short.

Table 1. The demographics data of the patients.

		%
Age (year) (mean ±SD)	31±4.49	
Sex (female/male)	6/21	22.22/77.77
BMI (mean ±SD)	24.3±2.8	
Primary (n)	18	66.66
Secondary (recurrent disease)	9	33.33
Previous surgical techniques (n)	9	33.33
Excision and primary repair (n)	5	18.51
Karydakias flap and modifications(n)	3	11.11
Limberg flap (n)	1	3.70
Acute infection (n)	4	14.81
Chronic infection (n)	23	85.18
Defect size (cm) (width and length) (mean ±SD)	7.33±2.40	5.14±2.10
Defect localization (lateral/midline) (mean±SD)	4/23	14.81/85.18
Anesthesia methods		
Local anesthesia	12	44.44
General anesthesia	15	55.55
Operation time (mean ±SD)	41.03±11.11	
Postoperative complications		
Partial flap necrosis	1	3.70
Maceration	1	3.70
Days of confinement in bed (day) (mean ±SD)	2.37±1.69	
Time off work (day) (mean ±SD)	5.62±2.55	
Follow-up period (year) (mean ±SD)	3.62±1.77	
Recurrence of pilonidal sinus	0	

BMI – body mass index.

The methods of leaving the wound open until granulation tissue occurs, closing the wound with partial sutures, and covering the open wound secondarily with a skin graft are associated with low recurrence rates but long-term treatment modalities, and these techniques undoubtedly have high direct and indirect costs and require longer healing time (3–8 weeks) [13,16,17]. In a study done by Solla and Rothenberger, the mean healing time for 150 patients who underwent this procedure was shown to be four weeks with a recurrence rate of 6% [18]. In addition, high risk of infection and poor scar formation are the other disadvantages of these methods of management [19].

Closure of the wound is more cosmetically acceptable for some patients and is associated with a shorter healing time and less time off work. Wide local excision and primary closure have

been advocated for the treatment of PS by some researchers, but the resulting scar remains in the midline and is associated with a high incidence of recurrence [20,21]. In order to solve the problem of midline scar formation and reduce the depth of the natal cleft, the Karydakias technique uses an eccentric elliptical incision for sinus excision and a flap is mobilized from the medial side of the wound, leaving the final suture line at either side of the midline. Bascom [22] has proposed a method to incise, drain, and curette a chronic abscess through a lateral incision combined with excision of any midline pits. A section of the wall of the abscess cavity opposite the incision is raised as a flap and used to close the communication between the midline pits and the abscess cavity. Although both of these techniques aim to carry the resultant scar from the midline to laterally, they often fail to obliterate the natal cleft




Figure 6. Comparison of Limberg flap and triangular flap technique on a 60×60 cm sponge with 8 mm of thickness. (A) Closure design for a 4 cm circular defect with the Limberg flap. (B) Creation of the defect. (C) Top view of the Limberg flap following suturation. (D) Lateral view of the Limberg flap following suturation. (E) Triangular flap design for a 4 cm circular defect. (F) The excision of triangular surface. (G) Top view of closure with triangular closure technique. (H) Lateral view of closure with triangular closure.

completely; therefore, recurrence rates are high with these techniques [23,24]. Of our 27 patients, 9 were operated on previously. Of those 9 patients, 5 had primary closure, 3 were closed with the Karydakis flap, and 1 patient was closed with the Limberg flap following PS excision (Table 1).

In order to reshape and flatten the natal cleft to reduce friction, local warmth, moisture, and hair accumulation, several flap techniques have been used to cover the defect after radical excision of the sinus [8,25–29]. Most flap techniques prevent tension of the wound as well as midline scar tissue. Moreover, recurrence rates of 7% to 42% have been reported after a conventional primary closure, although a number of studies have reported a recurrence rate of 0% to 3% for excision and flap repair [30,31].

In 1984 Azab and colleagues described the use of a rhomboid excision and Limberg transposition flap in complex pilonidal disease [32], and several authors have reported low recurrence rates and a short period of hospital care when this technique was used [9,19]. Although the Limberg flap not only reduces the depth of the natal cleft but also transposes the midline incision scar laterally, since all the skin required for resurfacing of the rhombic defect is borrowed from one direction, this technique often results in extensive tension on the suture lines and is associated with poor scar formation in the closure of large excisional defects of the sacrococcygeal region (Figure 6).

V-Y advancement flap is reliable and effective in covering large pilonidal wounds [6,33,34], but this technique has limitations regarding transposition of the resultant vertical scar from

midline. Berkem et al. reported high recurrence rates when the PS was reconstructed using the V-Y advancement flaps and the vertical suture line remained in the midline [6]. Use of fasciocutaneous flaps and myocutaneous flaps is indicated in the case of extensive tissue defects with repeated infection and recurrence. These techniques aim at wide excision of all the diseased tissue and closing the resultant defect with a well-vascularized and bulky alike tissue; also, they provide a tension-free suture line. On the other hand, they are more complicated techniques requiring greater surgical expertise and are related to higher rates of morbidity and wound dehiscence, and a longer time of hospitalization [35,36].

Although various surgical procedures, as outlined above, have been reported to date, a definitive method of treatment of PS has yet to be established. In order to create a surgical alternative, we adapted the Mutaf's triangular closure technique, which was first described in 2003 for closure of a large meningomyelocele for the treatment of PS [37]. In our procedure, two fasciocutaneous flaps are elevated in an unequal z-plasty manner, and one of these flaps is used for the defect closure while the other one is used for the closure of the donor site of the primary flap. By transferring a thick and well-vascularized neighboring tissue to the defect area, our technique reduces the depth of the natal cleft, completely fills the dead space resulting from the wide excision of PS, and allows us to transpose the resultant scar from midline. These critical benefits of our technique minimize the recurrence rates of PS. Using 2 skin flaps designed in an unequal z-plasty manner, this procedure maximizes the amount of tissue relaxation, and the defect closure is achieved with remarkably less tension, which

is important for prevention of wound infection and poor scar formation [38]. This technique may be used for the defects in different regions following PS excision and in the regions that we described considering the perforators on the sacrococcygeal region; it may be predicted how the scar will be formed (Figure 2). Moreover, our technique borrows tissue from two directions during defect closure. Thus, it distributes tension and diminishes the risk of tissue distortion and displacement of the neighboring mobile anatomic landmarks (Figure 6). However, in Limberg flap closure, because the tissue is taken along one direction, the tension occurs on one line and the complication risk due to flap circulation in large defects increases (Figure 6).

Conclusions

The triangular closure technique was found to be a useful technique for the treatment of PS with favorable results regarding time before returning to work. It allows the surgeon (1) to obtain a tension-free and durable closure of considerably large

sacrococcygeal skin defects with a good vascularized local flap; (2) to achieve good aesthetic results by using alike skin; and (3) to decrease the risk of recurrence by reducing the depth of the natal cleft and transposing the incision scar from midline.

Ethical approval

All procedures performed in studies involving human participants were by the ethical standards of the institutional research committee and with the 1964 Helsinki Declaration and its later amendments or comparable ethical standards.

Conflict of interest

All authors declare that there is not any conflict of interest.

Acknowledgements

The authors thank Dr. Hüseyin Dokuzoğlu for his medical drawings.

References:

- Hodges RM: Pilonidal sinus. *Boston Med Surg J*, 1880; 103: 485–586
- Armstrong JH, Barcia PJ: Pilonidal sinus disease. The conservative approach. *Arch Surg*, 1994; 129(9): 914–17; discussion 917–19
- Schneider IH, Thaler K, Kockerling F: Treatment of pilonidal sinuses by phenol injections. *Int J Colorectal Dis*, 1994; 9(4): 200–2
- Kepenekci I, Demirkan A, Celasin H, Gecim IE: Unroofing and curettage for the treatment of acute and chronic pilonidal disease. *World J Surg*, 2010; 34(1): 153–57
- da Silva JH: Pilonidal cyst: cause and treatment. *Dis Colon Rectum*, 2000; 43(8): 1146–56
- Berkem H, Topaloglu S, Ozel H et al: V-Y advancement flap closures for complicated pilonidal sinus disease. *Int J Colorectal Dis*, 2005; 20(4): 343–48
- Bascom JU: Repeat pilonidal operations. *Am J Surg*, 1987; 154(1): 118–22
- Arumugam PJ, Chandrasekaran TV, Morgan AR et al: The rhomboid flap for pilonidal disease. *Colorectal Dis*, 2003; 5(3): 218–21
- Mentes BB, Leventoglu S, Cihan A et al: Modified Limberg transposition flap for sacrococcygeal pilonidal sinus. *Surg Today*, 2004; 34(5): 419–23
- Karydakos GE: New approach to the problem of pilonidal sinus. *Lancet*, 1973; 2(7843): 1414–15
- Bessa SS: Results of the lateral advancing flap operation (modified Karydakos procedure) for the management of pilonidal sinus disease. *Dis Colon Rectum*, 2007; 50(11): 1935–40
- Stroosma OC: Gluteal fascioplasty as a method of primary closure in the treatment of pilonidal sinus. *Arch Chir Neerl*, 1978; 30(1): 61–64
- Eryilmaz R, Sahin M, Okan I et al: Umbilical pilonidal sinus disease: Predisposing factors and treatment. *World J Surg*, 2005; 29(9): 1158–60
- Ballas K, Psarras K, Rafailidis S et al: Interdigital pilonidal sinus in a hairdresser. *J Hand Surg Br*, 2006; 31(3): 290–91
- Ohtsuka H, Arashiro K, Watanabe T: Pilonidal sinus of the axilla: Report of five patients and review of the literature. *Ann Plast Surg*, 1994; 33(3): 322–25
- Søndena K, Andersen E, Nesvik I, Søreide JA et al: Patient characteristics and symptoms in chronic pilonidal sinus disease. *Int J Colorectal Dis*, 1995; 10(1): 39–42
- Borges G, Maciel Júnior JA, Carelli EF et al: Pilonidal cyst on the vault. Case report. *Arq Neuropsiquiatr*, 1999; 57(2A): 273–76
- Solla JA, Rothenberger DA: Chronic pilonidal disease. An assessment of 150 cases. *Dis Colon Rectum*, 1990; 33(9): 758–61
- Dahmann S, Lebo PB, Meyer-Marcotty MV: [Comparison of treatments for an infected pilonidal sinus: Differences in scar quality and outcome between secondary wound healing and limberg flap in a prospective study]. *Handchir Mikrochir Plast Chir*, 2016; 48(2): 111–19 [in German]
- Søndena K, Diab R, Nesvik I et al: Influence of failure of primary wound healing on subsequent recurrence of pilonidal sinus. Combined prospective study and randomised controlled trial. *Eur J Surg*, 2002; 168(11): 614–18
- Muzi MG, Milito G, Cadeddu F et al: Randomized comparison of Limberg flap versus modified primary closure for the treatment of pilonidal disease. *Am J Surg*, 2010; 200(1): 9–14
- Bascom JU: Pilonidal care: Anaerobes as invisible villains. *Eur J Surg*, 1996; 162(4): 351
- Zimmerman CE: Outpatient excision and primary closure of pilonidal cysts and sinuses. Long-term follow-up. *Am J Surg*, 1984; 148(5): 658–59
- Khaira HS, Brown JH: Excision and primary suture of pilonidal sinus. *Ann R Coll Surg Engl*, 1995; 77(4): 242–44
- Manterola C, Barroso M, Araya JC, Fonseca L: Pilonidal disease: 25 cases treated by the Dufourmentel technique. *Dis Colon Rectum*, 1991; 34(8): 649–52
- Khatri VP, Espinosa MH, Amin AK: Management of recurrent pilonidal sinus by simple V-Y fasciocutaneous flap. *Dis Colon Rectum*, 1994; 37(12): 1232–35
- Ozgültekin R, Ersan Y, Ozcan M et al: [Therapy of pilonidal sinus with the Limberg transposition flap]. *Chirurg*, 1995; 66(3): 192–95 [in German]
- Bose B, Candy J: Radical cure of pilonidal sinus by Z-plasty. *Am J Surg*, 1970; 120(6): 783–86
- Yucel E, Tezcan L, Yilmaz OC, Akin ML: “Flag Excision and Flap” procedure: A novel modification for off-midline closure after pilonidal sinus excision. *Indian J Surg*, 2015; 77(Suppl. 3): 1191–95
- McCallum I, King PM, Bruce J: Healing by primary versus secondary intention after surgical treatment for pilonidal sinus. *Cochrane Database Syst Rev*, 2007; (4): CD006213
- Muzi MG, Milito G, Nigro C et al: A modification of primary closure for the treatment of pilonidal disease in day-care setting. *Colorectal Dis*, 2009; 11(1): 84–88
- Azab AS, Kamal MS, Saad RA et al: Radical cure of pilonidal sinus by a transposition rhomboid flap. *Br J Surg*, 1984; 71(2): 154–55

33. Schoeller T, Wechselberger G, Otto A, Papp C: Definite surgical treatment of complicated recurrent pilonidal disease with a modified fasciocutaneous V-Y advancement flap. *Surgery*, 1997; 121(3): 258–63
34. Oz, B., et al., A comparison of surgical outcome of fasciocutaneous V-Y advancement flap and Limberg transposition flap for recurrent sacrococcygeal pilonidal sinus disease. *Asian J Surg*, 2015 [Epub ahead of print]
35. Hull TL, Wu J: Pilonidal disease. *Surg Clin North Am*, 2002; 82(6): 1169–85
36. Elalfy K, Emile S, Lotfy A et al: Bilateral gluteal advancement flap for treatment of recurrent sacrococcygeal pilonidal disease: A prospective cohort study. *Int J Surg*, 2016; 29: 1–8
37. Mutaf M, Bekerecioğlu M, Erkutlu I, Bulut O: A new technique for closure of large meningomyelocele defects. *Ann Plast Surg*, 2007; 59(5): 538–43
38. Zorlu M, Şahiner İT, Zobacı E et al: Early results with the Mutaf technique: A novel off-midline approach in pilonidal sinus surgery. *Ann Surg Treat Res*, 2016; 90(5): 265–71