



A family history of Hermansky–Pudlak syndrome complicated with pulmonary fibrosis: a case series and review

Katuska Liendo Martinez¹ , Fernando Pedraza¹, Marta Fuentes Alonso¹, Luis Puente Maestu¹, Carla Rodriguez Naranjo² & Javier De Miguel-Diez¹ 

¹Servicio de Neumología, Hospital General Universitario Gregorio Marañón, Madrid, Spain.

²Servicio de Anatomía Patológica, Hospital Universitario Gregorio Marañón, Madrid, Spain.

Keywords

Albinism, Hermansky–Pudlak syndrome, pulmonary fibrosis.

Correspondence

Katuska Liendo Martinez, Servicio de Neumología, Hospital General Universitario Gregorio Marañón, Madrid 28007, Spain. E-mail: kati_552@hotmail.com

Received: 30 October 2020; Revised: 21 December 2020; Accepted: 8 January 2021; Associate Editor: Diego Castillo Villegas.

Respirology Case Reports, 9 (4), 2021, e00720

doi: 10.1002/rcr2.720

Abstract

The Hermansky–Pudlak syndrome (HPS) is a rare genetic disorder. We report three cases from a family of 12 siblings, with six albinos, of whom four and the father had pulmonary fibrosis (PF). Case 1 was admitted to our hospital due to increasing dyspnoea and history of gynaecological bleeding. Pulmonary function test showed a restrictive airflow pattern, high-resolution computed tomographic scan demonstrated interstitial lung disease (ILD), and platelet aggregation was compromised with a reduced number of platelet dense bodies. The family history revealed endogamy and 11 members with suspected HPS. One of the albino sisters and the father had passed away with unidentified ILD, an albino brother died 14 years earlier, his autopsy had shown collections of ceroid pigments in the lungs, consistent with HPS, and another brother was followed up at our hospital for ILD and compromised platelet aggregation. This family probably has the highest number of members affected by HPS in Spain.

Introduction

The Hermansky–Pudlak syndrome (HPS) is a rare genetic disorder with autosomal recessive inheritance characterized by oculocutaneous albinism and bleeding diathesis. Although rare, other organs can also be affected, the lung being the most frequent [1]. Albeit the real frequency of the syndrome is unknown, there are approximately 1200 cases worldwide [2,3]. This syndrome was first described at Czechoslovakia in 1959 [1]; however, more than 50% of the cases have been described in Puerto Rico or in Puerto Rican population [4].

To date, 10 subtypes have been described, each one with a different gene and protein complex affected [4,5]. HPS pathophysiology consists of several mutations that affect the functions of some lysosomal-related organelles, such as melanosomes, the platelet dense bodies, and the lamellar bodies of type II pneumocytes [5–8]. Impairment of these organelles may explain some of these disease manifestations such as bleeding, albinism, and the far less likely pulmonary fibrosis (PF) [2,4,8].

We report three cases from an albino family, originally from Asturias. Looking at the medical history of the family, we found reports up to 2003 of the presence of 11 family members with the disease, associated with endogamy, which may explain why this family had so many members with a recessive disease. Figure 1 is a family tree with the information the current living family could provide. We believe these are interesting cases to report, especially for the lack of cases registered in Spain.

This study was approved by Hospital Gregorio Marañón's ethics committee with approval number 17/2020.

Case Series

Case 1

A 66-year-old female, albino, was presented with a history of gynaecological bleeding and need of transfusion of blood cells during a surgical procedure a few years before the first consultation. She had a father and a sister

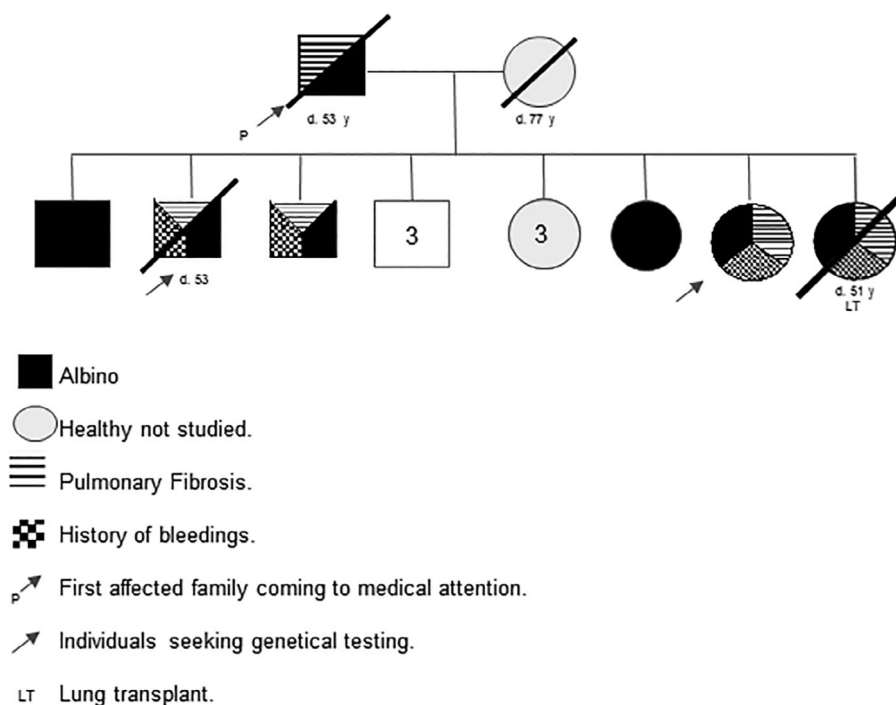


Figure 1. Family tree.

deceased by suspected PF and two siblings with diagnosis of PF secondary to HPS, one of them deceased. She was referred from primary care for a history of approximately 11 years with dyspnoea, which in the last year has worsened until reaching grade 2 of the modified Medical Research Council (mMRC) and cough with little expectoration.

On physical examination, she presented skin disorders compatible with albinism and velcro-type bibasal crackles in the lung auscultation. We requested pulmonary function tests, obtaining a restrictive airflow pattern. In a chest computed tomography (CT) with intravenous (IV) contrast, an interstitial lung disease (ILD) with marked parenchymal involvement was observed; extensive ground glass with predominance in mid and lower fields, and thickening of subpleural interlobular septa with signs of established fibrosis such as traction bronchiolectasis, predominantly in middle lobe and lingula, without clear honeycomb (Fig. 2). Diffusion test after multiple attempts did not achieve reproducible manoeuvres and in the 6-min walk test, the patient desaturated up to 86% in the basal test.

With these findings, we referred our patient to haematology and genetics to continue the study of possible HPS, evidencing results in platelet aggregation compatible with the existence of a reduced or non-existent number of platelet dense bodies. Considering the family background, the referred symptoms, and the findings of the complementary tests, a diagnosis of HPS with PF was made, currently pending the results of genetic tests.

Currently, this patient is being seen annually at our hospital. Through follow-up, we have seen worsening on forced vital capacity (FVC) in pulmonary function test as well as a need to start supplemental oxygen therapy. Therefore, last September, we decided to initiate compassionate treatment with pirfenidone. After three months of treatment initiation, she has not consulted to the emergency room for dyspnoea, being currently waiting for the six months check-up for her next pulmonary function tests.

Case 2

Case 2 is a male, albino, sibling of case 1, with a personal background of epistaxis and gingivorragia since childhood, gastrectomized at age 27 due to digestive bleeding, and followed up at our hospital since 2003 due to dyspnoea. In pulmonary function tests, a restrictive airflow pattern was observed, as well as ILD in high-resolution CT. In haemostasis tests, he had a bleeding time with a normal number of platelets, and compromise of platelet aggregation against adenosin diphosphate (ADP), collagen, and epinephrine inducers was also found, all of these compatible with a deficiency of platelet dense bodies. A genetic study was apparently performed on this patient and we have found a document that reports the presence until 2003 of the 11 other family members with the disease, associated with endogamy; however, the living family nowadays could not give more information about it. In 2005,

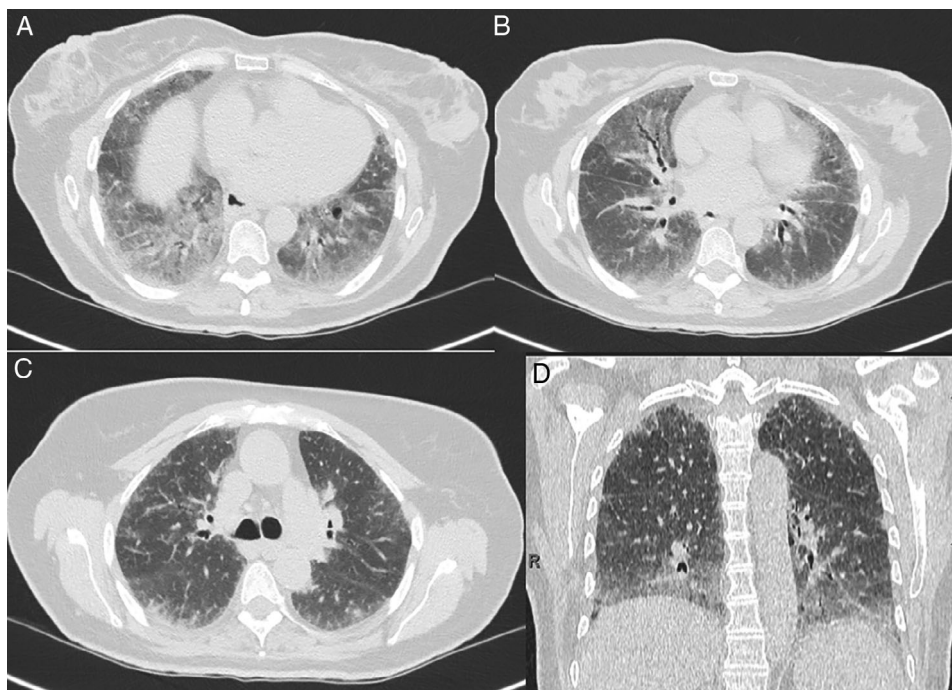


Figure 2. (A) Sagittal plane in chest computed tomography (CT) scan with pulmonary window: ground-glass opacities with predilection for middle and mainly lower lung zones. (B) Axial CT septal thickening more obvious in the upper zones. Sagittal (C) and axial (D) chest CT scan with pulmonary window and minimum intensity projection (MiniP): traction bronchiectasis in middle lobe (ML) and lingula.

due to worsening of PF the patient died, prior to his death he just had one CT scan control a year after the first one that did not have much progression but spirometry had a worsening on restrictive pattern. After his death, a necropsy was performed, which reported diffuse changes in the architecture of the lung parenchyma with generalized interstitial fibrosis (Fig. 3A, B) and diffuse foci of fibroblastic proliferation, likewise the histiocytes were loaded of an amber yellow pigment dispersed diffusely throughout the parenchyma; such ceroid pigment was also found deposited in the liver (Fig. 3C), spleen, gastrointestinal tract, kidney (Fig. 3D), heart, bone marrow, skin, and brain, thus allowing the definitive diagnosis of HPS.

Case 3

A 56-year-old male, smoker, albino, sibling of the two previous cases, with a background of primary tuberculosis was presented. At a medical control, incidentally on chest CT without IV contrast, a bilateral and diffuse interstitial pattern was found. Therefore, he was referred to our interstitial pathology consultation in 2002 where at that time we were already studying case 2.

Upon arrival at our hospital in November 2002, he reported a background of gastrointestinal bleeding, without respiratory symptoms. In pulmonary function tests, he had

preserved FVC and normal lung volumes on plethysmography. Platelet functionalism tests showed the existence of a defect in the release of dense bodies from platelet storage. At the time, genetic tests were apparently carried out, but we did not find them in the hospital files.

Currently, the patient continues being followed up annually in our hospital. Last spirometry control showed a slight decrease in FVC and forced expiratory volume in the first second (FEV₁), compared to the one in 2002, but still without meeting restrictive airflow pattern criteria and no change in CT scan.

Discussion

PF associated with HPS should be suspected in albino patients with bleeding, progressive dyspnoea, a restrictive airflow pattern in pulmonary function tests [2], and radiological findings consistent with ILD. Although several radiological patterns have been described, subpleural infiltrates, ground-glass reticular opacities, pleural thickening, and interstitial fibrosis, among others, can be highlighted [2,3,9].

Among the complementary tests useful to confirm the diagnosis, it is worth mentioning the study of platelets by electron microscopy, which allows confirming the reduced number or absence of platelet dense bodies [2]. Optionally,

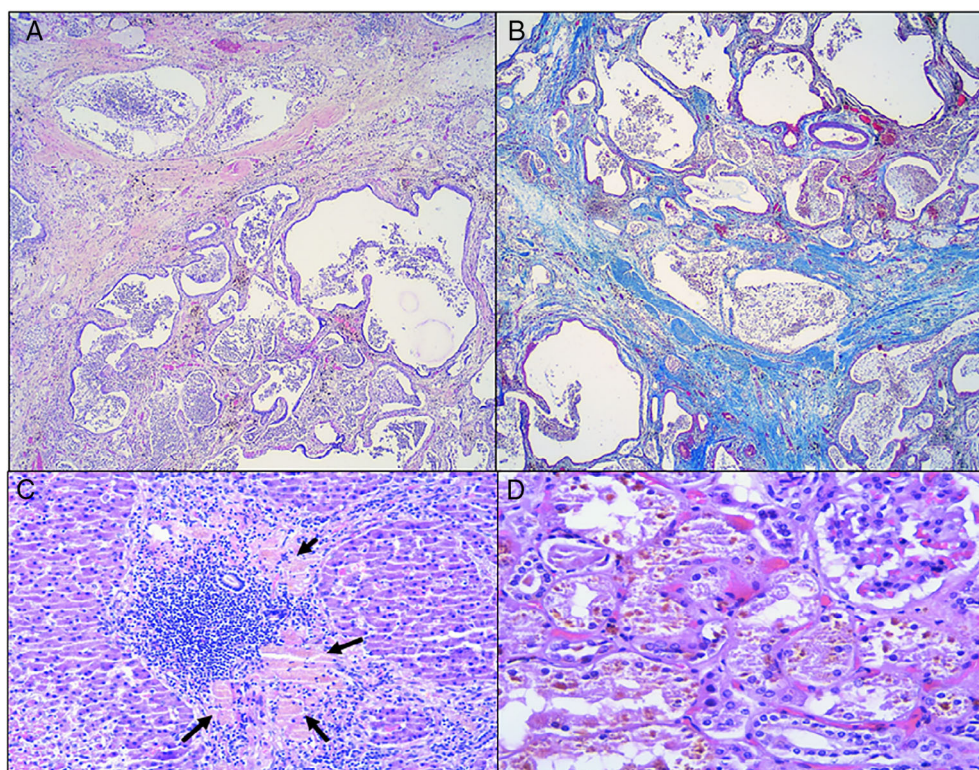


Figure 3. (A, B) Severe pulmonary fibrosis (honeycomb lung) (A, haematoxylin and eosin (H&E) 1.6 \times ; B, Masson's trichrome 1.6 \times). (C) Liver collection of ceroid pigment (H&E 20 \times). (D) Kidney collection of ceroid pigment (10 \times).

urine studies could also be performed to determine the presence of a ceroid–lipofuscin complex [10], or even the ceroid collection in the affected organs could be observed in autopsy studies [11].

Also, genetic tests are recommended to detect the specific mutation. Although they are not essential for diagnosis, they give an accurate diagnosis and will allow to classify the type of HPS due to prognostic implications for being able to make a correct follow-up, according to the typical extrapulmonary manifestations associated with each subtype. In addition, they are useful to provide genetic counselling, and to avoid invasive medical procedures such as lung biopsy [2,10].

The HPS-1 subtype is the most common, followed by HPS-3 [4,10]. PF is more commonly associated with HPS-1, although cases have also been described in HPS-2 and HPS-4 [4,10], and PF is the most serious complication, although rare, and the main cause of death [2].

The histological patterns shown in these patients have been described as indistinguishable from those seen in idiopathic PF (IPF), as well as in lung pathology associated with collagen diseases, drug damage, or even pneumonitis due to hypersensitivity [4,12].

However, some data could differentiate this entity from IPF, such as the onset age of symptoms, which in IPF is usually in patients older than 50 years and in HPS is around age 40 [3,9]. There are also differences regarding the average survival, so those patients with HPS live approximately 10 more years after diagnosis [2–4], while in those with IPF, classically, the survival before the boom of antifibrotic drugs was 50% at 3 years. On the other hand, although histological similarities have been described between IPF and PF associated with HPS, it is important to note that lung biopsy is contraindicated for the diagnosis of the HPS due to the presence of haemorrhagic diathesis and the consequent high risk of bleeding [3], which is also unnecessary as the final diagnosis is made with genetic tests.

To date, there is not an approved treatment for HPS, so the main treatment is to prevent secondary complications with a close follow-up, which includes annual ophthalmologic examination, skin protection to prevent premalignant or malignant skin lesions, avoid tobacco, and any treatment that increases bleedings. For PF, lung transplantation is the only therapeutic possibility, although it is a high-risk procedure due to the presence of haemorrhagic diathesis.

Nowadays, antifibrotic treatment could be an option in the management of these patients, similar to IPF [2,3]. Pirfenidone is the most widely studied drug as nintedanib is contraindicated due to the high bleeding risk [2].

In 2002, Gahl et al. conducted a double-blind randomized clinical trial with 21 patients and showed that people who received pirfenidone had a worsening of their FVC at a slower rate than those in the placebo group, but this was not statistically significant and the Food and Drug Administration (FDA) did not approve the drug [13]. Some years later, a second clinical trial was carried out, which in its first analysis was suspended due to uselessness [14].

More recently, a retrospective study studied the behaviour of three patients treated with open-label pirfenidone for a long time compared to historical controls treated with placebo. A slower decrease in FVC or even improvement in the three patients treated with pirfenidone was observed. More clinical trials are currently required to obtain approval of this drug; however, pirfenidone could have a compassionate use in these patients [15].

In conclusion, in albino subjects, the presence of bleeding should alert the existence of HPS. It is a diagnosis that should be made early in order to begin screening for other specific manifestations, such as ophthalmologic, dermatological, as well as for bleeding prevention.

In those with dyspnoea, it could be useful to carry out a screening with radiography or even CT scan, with the practice of pulmonary function tests, because PF is one of the worst complications for these patients. The aim is to establish a premature diagnosis, which is primarily important for a possible future inclusion of these patients as lung transplant candidates.

It is important to detect extrapulmonary manifestations to suspect this familial PF, with the aim of an early request of genetical tests, which will allow an accurate diagnosis and will let us avoid unnecessary medical procedures such as lung biopsy.

Disclosure Statement

Appropriate written informed consent was obtained for publication of this case series and accompanying images.

Acknowledgments

The authors thank John Ediberto Vanegas Rodriguez and Rafael Emilio Buongnermini.

References

- Hermansky F, and Pudlak P. 1959. Albinism associated with hemorrhagic diathesis and unusual pigment reticular cells in the bone marrow: report of two cases with histochemical studies. *Blood* 14:162–169.
- Rojas W, and Young L. 2020. Hermansky–Pudlak syndrome. *Semin. Respir. Crit. Care Med.* 41(2):238–246. <https://doi.org/10.1055/s-0040-1708088>.
- El-Chemaly S, and Young L. 2016. Hermansky–Pudlak syndrome. *Clin. Chest Med.* 37(3):505–511.
- Vicary G, Vergne Y, Santiago-Cornier A, et al. 2016. Pulmonary fibrosis in Hermansky–Pudlak syndrome. *Ann. Am. Thorac. Soc.* 13(10):1839–1846.
- Di Pietro S, and Dell'Angelica E. 2005. The cell biology of Hermansky–Pudlak syndrome: recent advances. *Traffic* 6:525–533.
- Osanai K. 2018. Rab 38 mutation and the lung phenotype. *Int. J. Mol. Sci.* 19(8):2203.
- Bultema JJ, Ambrosio AL, Burek CL, et al. 2012. BLOC-2, AP-3, and AP-1 proteins function in concert with Rab38 and Rab32 proteins to mediate protein trafficking to lysosome-related organelles. *J. Biol. Chem.* 287(23):19550–19563.
- Bowman SL, Bi-Karchin J, Le L, et al. 2019. The road to lysosome-related organelles: insights from Hermansky–Pudlak syndrome and other rare diseases. *Traffic.* 20(6):404–435.
- Kelil T, Shen J, O'Neill AC, et al. 2014. Hermansky–Pudlak syndrome complicated by pulmonary fibrosis: radiologic-pathologic correlation and review of pulmonary complications. *J. Clin. Imaging Sci.* 4:59.
- Pierson D, Ionescum D, Qing G, et al. 2006. Pulmonary fibrosis in Hermansky–Pudlak syndrome. *Respiration* 73:382–395.
- Harada T, Ishimatsu Y, Nakashima S, et al. 2014. An autopsy case of Hermansky–Pudlak syndrome: a case report and review of the literature on treatment. *Intern. Med.* 53:2705–2709.
- American Thoracic Society, and European Respiratory Society. 2002. American Thoracic Society/European Respiratory Society international multidisciplinary consensus classification of the idiopathic interstitial pneumonias. *Am. J. Respir. Crit. Care Med.* 165:277–304.
- Gahl WA, Brantly M, Troendle J, et al. 2002. Effect of pirfenidone on the pulmonary fibrosis of Hermansky–Pudlak syndrome. *Mol. Genet. Metab.* 76:234–242.
- O'Brien K, Troendle J, Gochuico BR, et al. 2011. Pirfenidone for the treatment of Hermansky–Pudlak syndrome pulmonary fibrosis. *Mol. Genet. Metab.* 103:128–134.
- O'Brien KJ, Introne WJ, Akal O, et al. 2018. Prolonged treatment with open-label pirfenidone in Hermansky–Pudlak syndrome pulmonary fibrosis. *Mol. Genet. Metab.* 125(1–2):168–173.