



Pre-Operative CT-Based Planning Integrated With Intra-Operative Navigation in Reverse Shoulder Arthroplasty: Data Acquisition and Analysis Protocol, and Preliminary Results of Navigated Versus Conventional Surgery

Fabio Moreschini^{1,2}, Giovanni Battista Colasanti^{1,2} , Carlo Cataldi^{1,2}, Lorenzo Mannelli³ , Nicola Mondanelli^{1,2} , and Stefano Giannotti^{1,2}

Abstract

Reverse total shoulder arthroplasty (RSA) successfully restores shoulder function in different conditions. Glenoid baseplate fixation and positioning seem to be the most important factors influencing RSA survival. When scapular anatomy is distorted (eccentric osteoarthritis, rotator cuff arthropathy), optimal baseplate positioning and secure screw purchase can be challenging. The aim of this study was to evaluate whether CT-based pre-operative planning, integrated with intra-operative navigation could improve glenoid baseplate fixation and positioning by increasing screw length, reducing number of screws required to obtain fixation and increasing the use of augmented baseplate to gain the desired positioning. Twenty patients who underwent navigated RSA were compared retrospectively with 20 patients operated on with a conventional technique. All the procedures were performed by the same surgeon, using the same implant. Mean screw length was significantly longer in the navigation group (35.5 ± 4.4 mm vs 29.9 ± 3.6 mm; $p = .001$). Significant higher rate of optimal fixation using 2 screws only (17 vs 3 cases, $p = .019$) and higher rate of augmented baseplate usage (13 vs 4 cases, $p = .009$) was also present in the navigation group. Pre-operative CT-based planning integrated with intra-operative navigation can improve glenoid component positioning and fixation, possibly leading to an improvement of RSA survival.

Keywords

preoperative planning, modeling, intraoperative navigation, acquisition, protocol, 3D virtual model

Introduction

Reverse total shoulder arthroplasty (RSA) is a successful surgical procedure for treating patients with end stage rotator cuff arthropathy, eccentric osteoarthritis (OA) with severe glenoid deformity, 3- and 4-part proximal humeral fractures over OA and revision arthroplasty surgery with severe bone deficiency.^{1,2} Nevertheless, the cumulative revision rate at 5 years is 4.6%. Instability and loosening represent the 2 most common reasons for revision (38.5% and 18.0%, respectively).³ Glenoid component failure is the main cause of long-term clinical failure for RSA,^{4,5} therefore accurate placement of the glenoid component is key to determine arthroplasty survival and preventing post-operative instability.^{4,6} Optimal version, inclination, and overhang are crucial to maximize the bone stock available for fixation. Several studies have shown a wide

variability in the placement of glenoid fixation screws in the limited bone available in the scapula.⁷ On the other side,

¹ Section of Orthopaedics, Department of Medicine, Surgery and Neurosciences, University of Siena, Siena, Italy

² Azienda Ospedaliero-Universitaria Senese, Policlinico Santa Maria alle Scotte, Siena, Italy

³ IRCCS SDN Istituto di Ricerca Diagnostica e Nucleare, Naples, Italy

Received 22 August 2020; received revised 24 September 2020; accepted 12 October 2020

Corresponding Author:

Nicola Mondanelli, Section of Orthopedics, Department of Medicine, Surgery and Neurosciences, University of Siena, Siena, Italy; Azienda Ospedaliero-Universitaria Senese, Viale Mario Bracci 16, 53100 Siena, Italy.
Email: nicola.mondanelli@unisi.it



several cadaveric studies have demonstrated considerable natural variability in anatomic parameters of the glenoid:^{8,9} this variability affects prosthesis design, instrumentation, and intra-operative implantation techniques. When the scapular anatomy is distorted, achieving secure purchase with each implanted screw may be even more difficult. Each single screw contributes to quality of the glenoid fixation. However, the inferior screw is thought to be the one with the largest contribution because it is nearest to the point of loading of the humeral component. RSA glenoid baseplate fixation is improved by maximizing implanted screw length and minimizing bone perforation.¹⁰⁻¹⁵ While the ideal position of the baseplate and screws has been largely studied,¹⁶⁻¹⁸ correct placement remains technically difficult due to the difficult joint exposure and complex geometry of the glenoid.⁸

The use of standard 2-dimensional (2D) imaging and currently available surgical instruments is imprecise for the correction of severe glenoid deformity.⁹ Therefore, 3-dimensional (3D) virtual planning based on computed tomography (CT), intra-operative CT-based navigation, and patient-specific instrumentation have been used to increased accuracy and repeatability in planning and execution arthroplasty in anatomic and RSA,¹⁹⁻²² as already in use in knee replacement.²³ In recent years, surgeons had benefitted from intra-operative navigation technology, already developed and implemented in hip and knee prosthetics, and which today in shoulder arthroplasty seems to offer great advantages, in consideration of the reduced bone surface to work on and the proximity to neurovascular structures (brachial plexus, subclavian and axillary vessels) that may be at risk. Intra-operative CT-based navigation accuracy in orthopedic surgery has been proven in several studies,¹⁹⁻²² but very few studies exist about navigation in shoulder arthroplasty, and those are mostly in experimental setups using cadaveric specimens.^{21,24,25}

The aim of this study was to determine whether intra-operative CT-based navigation could improve the glenoid baseplate position and fixation by increasing the length of screw, decreasing the number of screws needed to obtain primary fixation, and eventually increasing the use of augmented baseplate in patients undergoing RSA.

Materials and Methods

Study Design and Recruitment

We prospectively collect data of all RSA performed at our Institution. Navigation was introduced in clinical use at Our Institution in October 2018, and up to February 2019 we used to perform 2 cases (1 conventional and 1 navigated surgery) in the same operating session, without selecting cases based on severity of deformity. From then on, all elective RSAs were performed with the use of intra-operative navigation. For this study, we retrospectively compared 20 patients who underwent RSA with intra-operative navigation after 3D CT-based planning (navigated group, NAV) with 20 patients operated on of RSA with the conventional technique (pre-operative planning

on plain radiographs and CT-scan; conventional group, CON). Patients were picked up casually in both groups from our database, matching them for demographics; severity of OA or type of deformity were not matched, but all surgeries were performed by the senior Author for eccentric shoulder OA or rotator cuff arthropathy between January 2018 and December 2019. Adjunctive inclusion criterion for the CON group was the acquisition of pre-operative CT-scan. Exclusion criteria were: patients who underwent RSA with an implant other than Equinoxe[®] Reverse System (Exactech, Gainesville, FL, USA), patients operated on for diagnosis other than eccentric shoulder OA or rotator cuff arthropathy (proximal humeral fractures, post-traumatic OA previously treated operatively with hardware retention, revision shoulder arthroplasty), patients operated on by a surgeon different from the senior Author, deformity or bone defect requiring accessory gestures such osteotomies or a custom-made or an allograft-prosthesis composite implant. At our Institution, no Ethical Committee nor Institutional Review Board approval are needed for retrospective studies; all patients gave their written consent to treatment and anonymous use of data and images for research and academic purposes.

The RSA. The implant (Figure 1) presents a metallic baseplate to be implanted over the glena obtaining primary stability by means of press-fit fixation of the peg plus compression screws. The glenoid baseplate (also called metaglena) presents a central peg and 6 screw holes; available compression screws (4.5 mm in diameter) range in length from 18 to 46 mm with 4 mm increments. Secondary stability will rely on osteointegration of the baseplate, to favor such osteointegration an autologous bone cylinder (recovered from the resected humeral head) is inserted into the hollow plug. The humeral stem can be uncemented or cemented; up to date, this is not navigated but can be planned as well.

CT Scan Acquisition Protocol

Acquisition timing. Pre-operative CT scan should be acquired less than 6 months prior to surgery; this, to reduce the risk of anatomical changing between acquisition and the surgical procedure. CT scan (Figure 2A and B) can better visualized glenoid morphology and eventual bone defects with respect to plain radiographs (Figure 2C).

Patient's preparation. Patient lays supine on the scanner table with her/his head orientated toward the scanning tube. Patient's indicated arm is placed adducted along her/his side with neutral humeral rotation. Injectable contrast is contraindicated as it may hamper the visualization of bony anatomy. Patient must not move during the exam.

CT scanner settings. Images must be acquired in axial format with no rotation, modality must be set on CT and Hounsfield encoding must be used. The recommended peak kilovoltage is 120 kVp or higher, the recommended milliamperage is 240 mA or higher, and pitch is set to less than or equal to 1. The




Figure 1. An “exploded” reverse shoulder arthroplasty (RSA). The glenoid component is constituted by a metal baseplate (metaglena, A) that presents a central plug and holes for compression screws insertion, a metallic ball (glenosphere, B) that is impacted and screwed onto the metaglena. The plastic articulating “socket” (C) is on the humeral side and is impacted on a plate (D) that goes on the humeral stem (E). Ball and socket are inverted: that is the reason why it is called RSA.

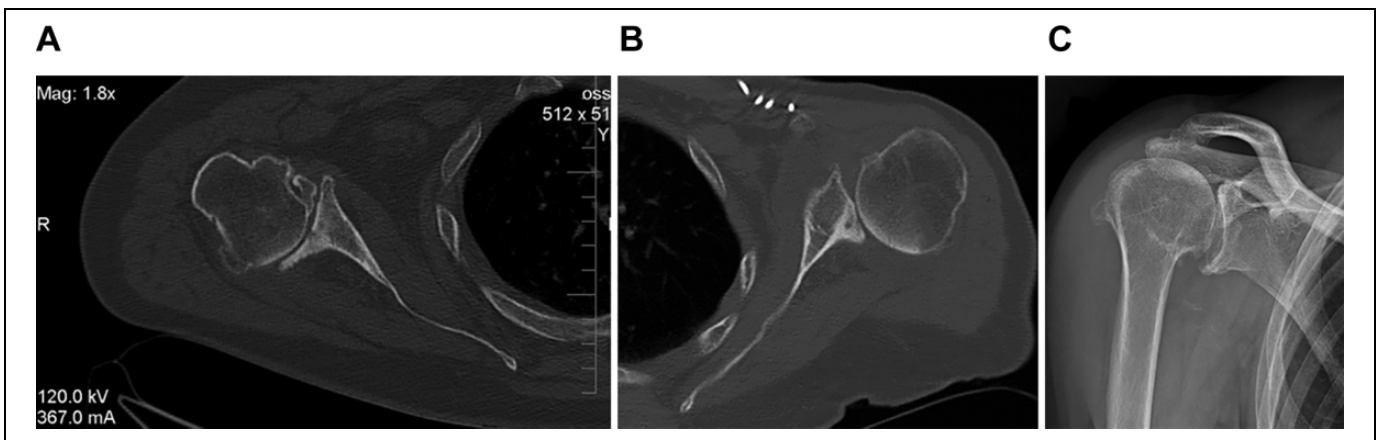


Figure 2. Two cases with a very different glenoid morphology and bone defect from each other. CT-scans are shown: in (A) the defect is central (the glena is very subtle) and large osteophytes are present that help in maintaining the humeral head centered; in (B) the defect is smaller but peripheral and the humeral head is subluxated posteriorly. Plain radiographs of case in A (C) would not permit thorough evaluation of the glenoid defect.

reconstruction kernel is Bone, with high definition acquisition setting if available; recommended settings depend on the manufacturer. Slice thickness (collimator/detector width) and slice spacing (slice increment or reconstruction interval) must be equal to or less than 1.25 mm. Both slice thickness and spacing must be kept equal and constant for the entire exam, with no overlap. Minimum distance should be 0.3 mm, maximum

distance allowed is 1.25 mm, while recommended distance is 0.625 mm. With a 1.25 mm distance between slices, the overall error can be maintained to less than $2^\circ / 2\text{mm}$, considering it as the sum of possible error of model plus error of camera plus error of the acquisition tool plus error of the operative tools during surgery (manufacturer’s data). With a 0.625 mm distance the CT can be more accurate as this allows the Engineer to

Table 1. Settings for CT-Scan Acquisition Protocol to be Used With the Exactechgps® Software for Pre-Operative Planning and Intra-Operative Navigation.

Axial format	No rotation	Gantry tilt 0°	Image orientation 0 0 0 0
Modality	CT		Hounsfield encoding
Recommended setting	Peak kilovoltage Milliamperage Pitch		120kVp or higher 240 mA or higher ≤ 1
Reconstruction kernel	Bone HD Acquisition if available		Built-in filter General Electrics: BONE Toshiba: FC30 Siemens: B41 Philips: L
Slice thickness (collimator/detector width)	≤ 1.25 mm	Equal and constant No overlap	Min distance 0.3 mm Max distance 1.25 mm
Slice spacing (slice increment or reconstruction interval)			Recommended distance 0.625 mm
Pixels square	Constant for all images		
DFOV	The entire indicated scapula (including medial border and distal tip) Bilateral acquisition to be acquired independently 25-30 cm (10-12 in) Min resolution 0.3 × 0.3 mm/pixel Max resolution 1.0 × 1.0 mm/pixel		Matrix size 512 × 512 pixel 512 pixels ≥ 15 cm / 6 in 512 pixels ≤ 50 cm / 20 in
MAR (only if metal hardware is present in the DFOV)	single energy CT		
	Peak kilovoltage Milliamperage	140 kVp 330 mA	Do not use auto-mA nor dose reduction protocol
	Available built-in algorithms are to be applied		General Electrics: SmartMAR Siemens: iMAR Toshiba: SEMAR Philips: O-MAR

CT: computed tomography; HD: high definition; DFOV: display field of view; MAR: Metal Artifact Reduction; iMAR: iterative MAR; SEMAR: single-energy MAR; O-MAR: MAR for orthopedic implants.

reduce part of the overall error by acting directly on the possible error of the model, even if it will mean more radiation dose to patients.

Pixels square also has to be kept constant for all images. As for resolution, the display field of view (DFOV) should contain the entire indicated scapula, including the medial border and distal tip. Bilateral acquisition should be acquired independently to reduce the dose, as the DFOV will be too large. The DFOV should be approximately 25 to 30 cm (i.e. 10 to 12 inches for a matrix size 512 × 512). The minimum resolution for image is 0.3 × 0.3 mm/pixel (i.e. 512 pixels represent at least 15 cm/6") and the maximum resolution for image is 1.0 × 1.0 mm/pixel (i.e. 512 pixels represent no more than 50 cm/20"). Some recommendations are to be adopted if metal hardware is present in the DFOV: all preventative measures both to reduce metal artifact in the scapula and to keep the dose low for the patient should be taken. Recommended settings for metal artifact reduction (MAR) are single energy CT, peak

kilovoltage 140 kVp, milliamperage 330 mA; also, available iterative MAR algorithms to the scan are to be applied. All settings are recapped in Table 1.

Images format. Images must be exported in uncompressed, non-encrypted DICOM Format. Raw data to be exported should contain only the axial series, with files named in sequential numerical order, with no gaps nor duplicates in the DICOM file names. No additional series (sagittal or coronal) nor reconstructions nor scout images must be included. Typically, the exported series contains between 200 and 450 images. Tags and included values as in Table 2 must be present in the exported files, in order to be used with the planning and navigation applications (Exactech Guided Personalized Surgery software; ExactechGPS®, BlueOrtho, Gières, France). Exam can be rejected if images quality is altered. This can be caused by patient motion during examination, metallic artifacts, and/or poor images quality, or missing data/tags.

Table 2. Tags and Included Values to be Present in the Exported Files to be Used With the ExactechGPS® Software for Pre-Operative Planning and Intra-Operative Navigation.

DICOM Tag	Name	Accepted values
(0002,0010)	Transfer syntax	1.2.840.10008.1.2 (Implicit VR Endian) 1.2.840.10008.1.2.1 (Explicit VR Little Endian) 1.2.840.10008.1.2.2 (Explicit VR Big Endian)
(0020,0037)	Image orientation patient	1/0/0/0/1/0

VR: value representation.

Pre-Operative Planning

After acquisition, the CT scan study is loaded into the online planning software. The study is manually segmented by engineers of the manufacturer to reconstruct the shoulder in a 3D model for pre-operative planning. Glenoid version, inclination, and any wear or deformity is accurately measured: after reconstruction, the virtual 3D model is ready for planning into the pre-operative application. Some landmarks and references are required to be confirmed by the surgeon (Figure 3A and B) to validate reconstruction before she/he could start with planning; some of these landmarks will be asked to be located intra-operative afterward. The surgeon can choose dimension of the

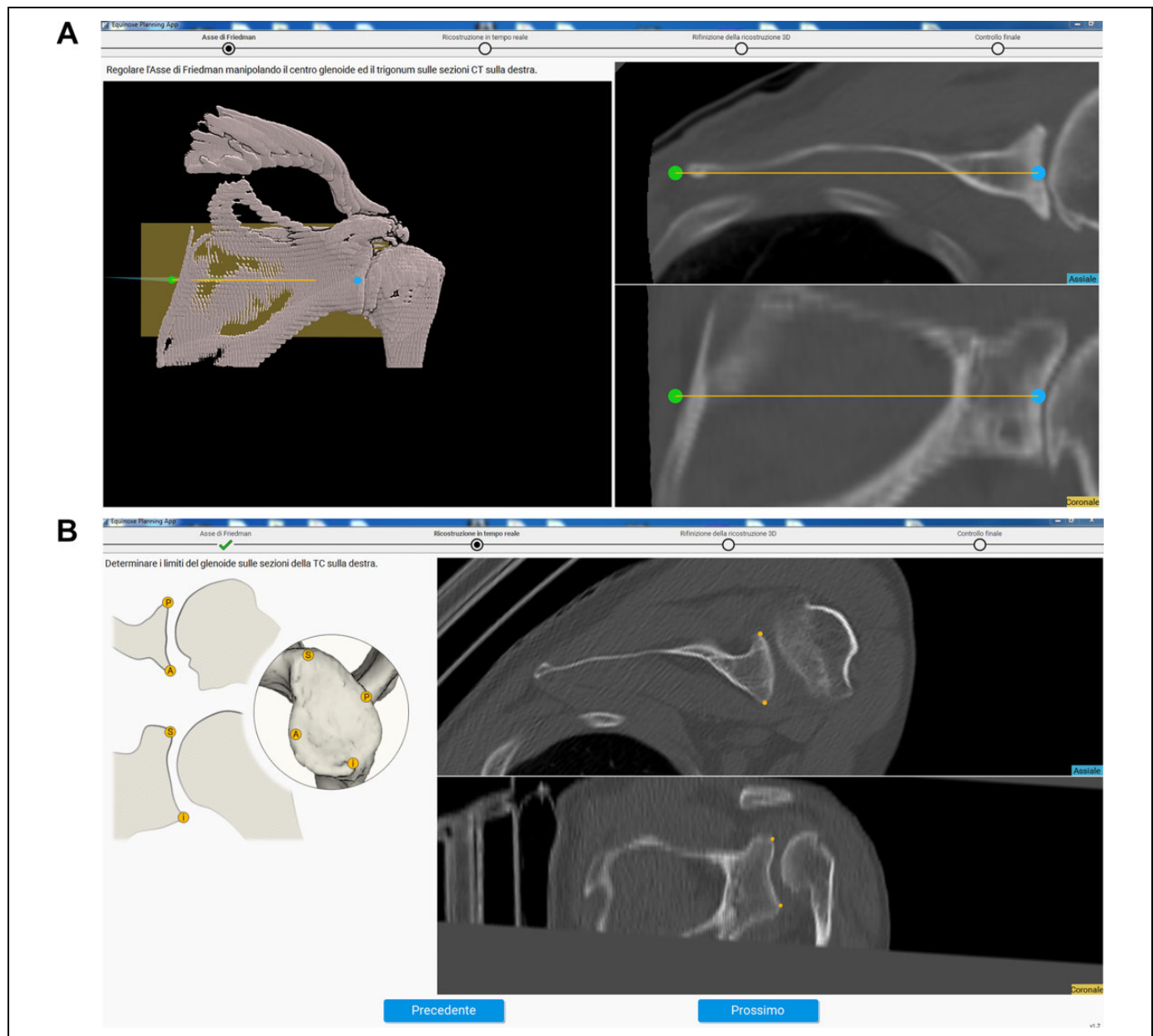


Figure 3. Over the 3D virtual model, surgeon must locate some landmarks: the Friedman's axis (A) that identifies of center of the glenoid and the margins of the glenoid (B) that will be asked to be located intra-operatively as well.

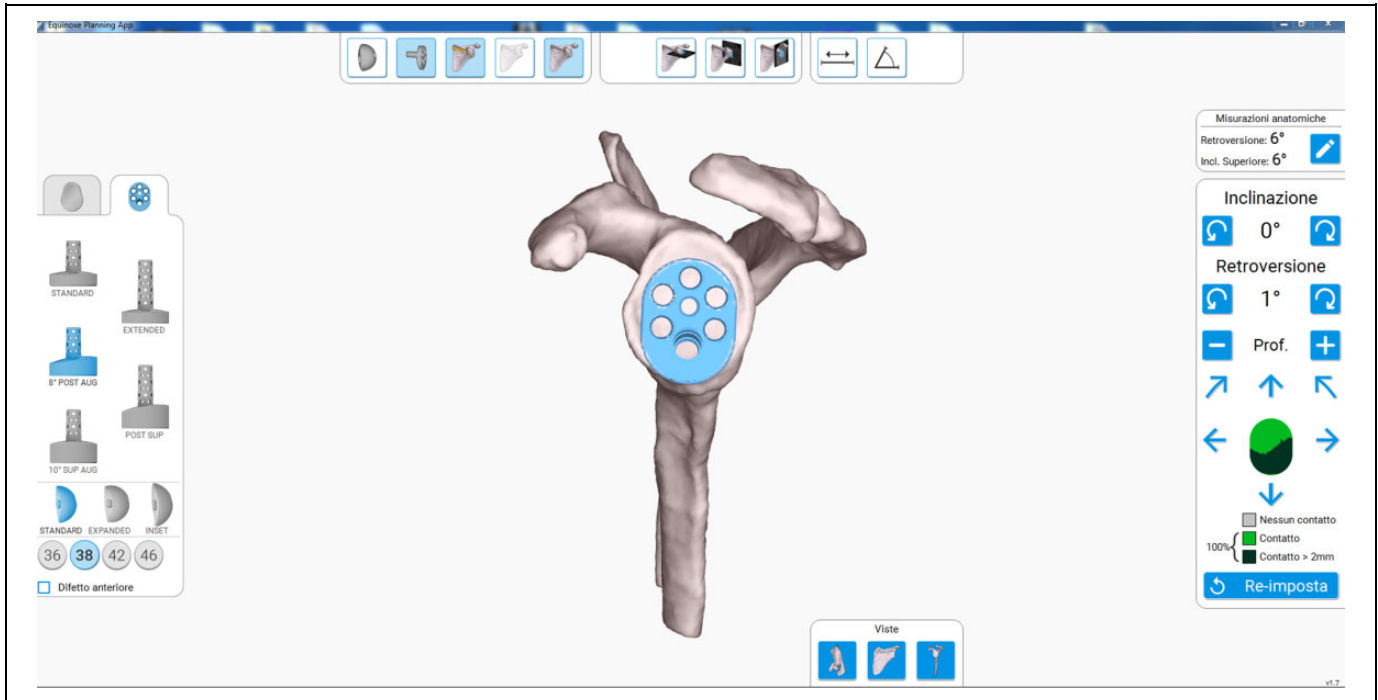


Figure 4. Surgeon can choose dimension and type of baseplate, and where to position it. Software gives colored and numeric feedback of the position of the baseplate, how many bone removal has been done, how much the prosthetic/bone contact is. Position can be “fine-tuned” degree per degree and millimeter per millimeter.

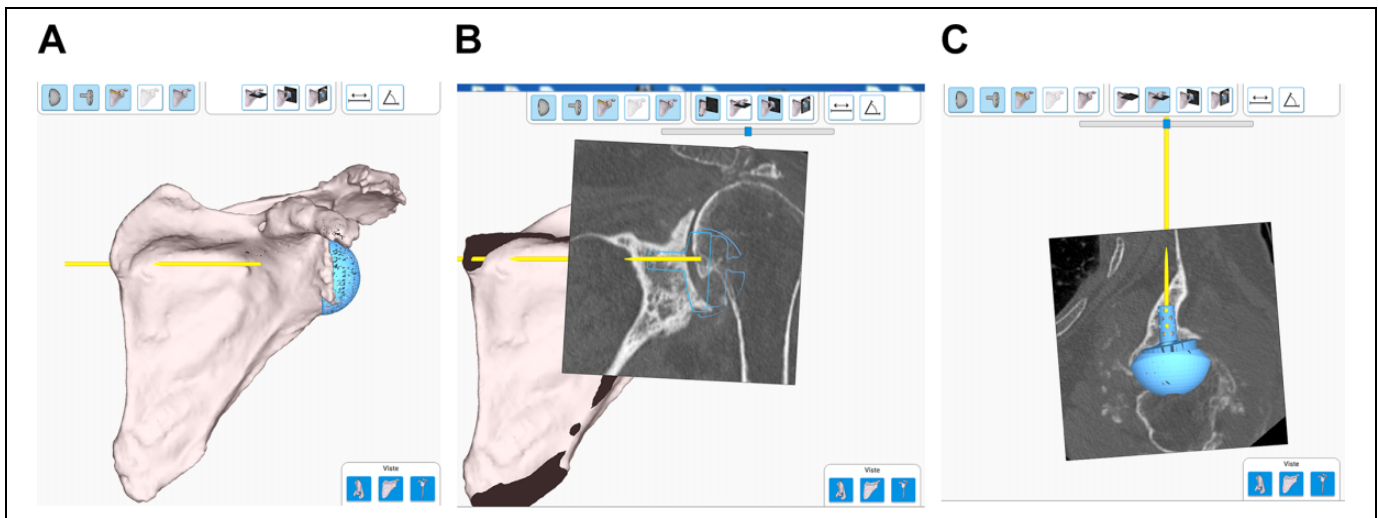


Figure 5. The virtual 3D scapula can be rotate on all planes and axes (A). Also, a 2D check is recommended, and superimposition of 3D model to 2D images is also possible (B, C).

baseplate, its position, if to use augments to reduce or to increase version and/or inclination. The software gives colored and numeric feedback about percentage of contact between the bony glenoid and the prosthetic baseplate, about position of the baseplate (version, height, anteroposterior translation), medialization or lateralization of the center of rotation (with respect to normal center of rotation and bony landmarks useful in RSA) (Figure 4). It is fundamental to rotate the virtual 3D scapula model on all planes and axes to make sure of the position of the

baseplate with respect to the peg as well (Figure 5A): primary stability would be better and less risk of peri-operative fracture exists if the peg is all inside the bone without perforating nor touching the cortices of the scapular neck; also, a 2D check is recommended (Figure 5B and C). During this positioning of the metaglena, the surgeon can evaluate how much bone has to be removed from the articular surface, which is the best inclination and version to obtain the greater contact between the baseplate and the bone. Desired bone-prosthesis contact is more

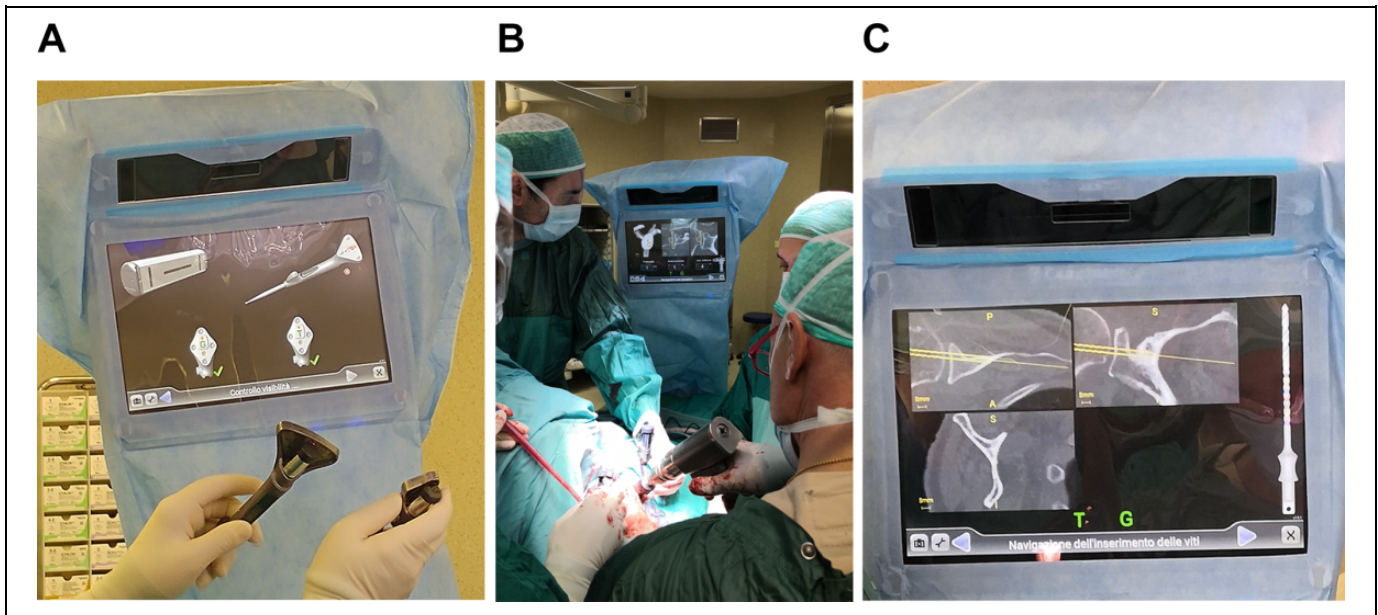


Figure 6. Intra-operative navigation: (A) trackers registration and calibration; (B) the navigation platform with the optical reader (top) and the screen with guidelines for the procedure, during reaming; (C) a close-up of the screen while preparing for screw drilling.

than 90% of the baseplate. After that, the software gives the opportunity to direct the screws to obtain maximal screw length into the bone, without exiting excessively the cortices. When the surgeon is satisfied with her/his planning, she/he sends to the manufacturer to be validated by engineers. If some concern exists, the engineers will report it to the surgeon before validation. Once the CT-based pre-operative planning is validated, raw data are uploaded to the intra-operative application.

Intra-Operative Navigation and Matching Procedure

The pre-operative planning is uploaded to the intra-operative application, and patient's data are checked. The navigation system hardware consists of a platform that is positioned in a sterile fashion at the feet of the patient, and in tracker-equipped surgical instruments that will be used by surgeons. First, the optical navigation trackers are registered and calibrated on the computer (Figure 6A). Then, the fixed scapular tracker is secured with threaded screws to the inferolateral surface at the base of the coracoid process; care must be taken not to loosen nor move the fixed tracker during surgery as it is the reference for all the procedure. A handheld tracker is used to register the anatomic landmarks (anterior and posterior surface and base line of the coracoid process; superior, inferior, anterior, and posterior margins of the glenoid surface; anterior, inferior and posterior rim lines of the glenoid, anterior and inferior neck line) to check and superimpose the patient's scapula with the CT-based model. Matching of registered data with patient's CT-based anatomy is shown with colored feedback (green: perfect match; yellow: acceptable coupling, red: unacceptable registration). After completing of the matching procedure, the pre-operative planning is shown on the screen of the platform. Surgeon can now prepare the glenoid, step-by-step as in

conventional technique, but with the use of tracker-equipped instruments and guided by the 2D and 3D feedback on the screen to achieve the pre-operative planning.

Surgical Technique

Patients were lying in the beach-chair position. After surgical prepping, a deltopectoral approach was used for all the procedures. After resection of the humeral head (needed to gain access and space around the glenoid), attention was focused on the scapular side.

In the CON group, glenoid preparation (instruments centering, reaming, holes for the central peg and screw insertion) was done freehand, based on pre-operative planning, intra-operative findings, and surgeon's experience and preferences. Once the glenoid surface was exposed, the center of the glenoid was found with templates and a pin was inserted as a guidewire. The glenoid was first prepared with convex reamer to remove cartilage and subchondral bone up to obtain a regular and bleeding bony surface. After that, a hole for the central peg was prepared with a cannulated drill. The peg is hollow and pierced to receive a cylinder of patient bone recovered from the humeral head; this would serve to promote osteointegration and secondary fixation for a durable stability of the implant. The metallic baseplate was implanted in a pressfit fashion; to increase primary stability, compression screws were placed as considered necessary through the holes; at least 2 screws are suggested, superiorly and inferiorly placed. Even with an accurate pre-operative 2D and 3D CT-based planning, at surgery it can be difficult to understand and completely evaluate eventual bony defects, that can be misestimated (more frequently underestimated): the glenoid surface can "face" differently than normal 30° of retroversion and 10° of superior

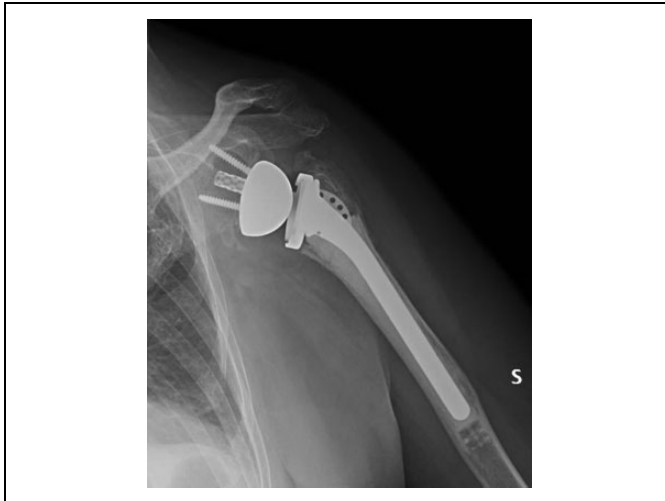

Figure 7. Post-operative radiographs showing reverse shoulder arthroplasty performed in a 72-years old female for eccentric osteoarthritis of her left shoulder.

inclination because of such defects, and this may deceive the surgeon in baseplate position. Also, after preparation of the glena and impaction of the metallic baseplate, freehand screw positioning is a challenging step: the neck and the body of the glena are very subtle, and the longest the screw, the better the purchase if into the bone, but also the worst if outside the bone.

In the NAV group, after developing the surgical approach, the matching procedure was performed as already mentioned. At this point, every next step from centering, reaming (Figure 6B), peg and screw drilling (Figure 6C) were performed under image-guided navigation using tracker-equipped instruments.

After that, both the NAV and the CON procedure continue in the same way: a glenosphere is impacted and screwed into the metaglena, and attention is turned on the humeral side and surgical procedure is then finished (Figure 7). Humeral stem fixation can be achieved both with bone cement or via pressfit fixation; choice depends on bone quality and shape, independently from the NAV or the CON glenoid procedure.

Peri-Operative Management

Antibiotic (AB) prophylaxis was the same in both groups: Cefazoline 2 g i.v. was administered 30 minutes before the procedure and after that 1 g i.v. every 8 hours for the first 48 hours from surgery. In case of allergies to beta-lactams, Vancomycin 1 g i.v. was administered before surgery and every 12 hours for 48 hours. Anti venous thromboembolism (VTE) prophylaxis was administered to all patients as well, in the same fashion for both groups: Enoxaparin 4000 UI s.c. was administered 12 hours after surgery and thereafter once a day for 12 days. Both AB and VTE prophylaxes were conformed to Hospital protocols based on scientific Literature and local (regional) guidelines that are based on national medico-legal issues, as well. Post-operative course was also the same in both

groups: immobilization in an abduction—neutral rotation shoulder brace for 2 weeks, and physical therapy with passive and active motion exercises after that.

Statistical Analysis

Patient age at surgery was assessed for normality (Anderson-Darling test) and compared between groups using an unpaired 2-sample t-test (Mann-Whitney U test). A paired 2-sample t-test (Student T test) was used to compare body mass index (BMI). Fisher's exact test was used to compare gender distribution, augmented baseplate utilization and usage of more than 2 screws between groups. Screw length were assessed for normality and compared between groups using unpaired 2-sample t-test (Mann-Whitney U test). Statistical analysis was performed using XlsStat 2020 software (Addinsoft, New York City, NY, USA) for Microsoft Excel (Microsoft, Seattle, WA, USA).

Results

No significant differences were observed between groups for demographics (age at surgery, gender, BMI). The NAV procedure (including coracoid exposure, scapular tracker fixation, and registration of landmarks) required mean 11 (range 7-16) minutes more to be performed than the CON procedure. Prepping of the NAV platform and optical trackers registration and calibration on the back-table were done by the scrub nurse while surgery had already begun, therefore not being time-consuming procedures. Total surgical time was not evaluated, depending also on the humeral side: cementing a stem usually requires a 15- to 20-minutes longer time than a cementless pressfit fixation, introducing a bias in total duration of the procedure. Same for bleeding: a cemented stem usually bleeds less than an uncemented stem (thermal cauterization during cement polymerization and mechanical closure of dead spaces and vessels), therefore another bias between the NAV and the CON groups in intra-, post-operative and total bleeding would occur. Number of cases requiring more than 2 screws to obtain stable primary fixation was significantly lesser in NAV group comparing to CON group (17 cases vs 9 cases, $p = .019$). Mean screw length was significantly longer in the NAV group in comparison to CON group (35.5 ± 4.4 mm vs 29.9 ± 3.6 mm; $p < .001$). Significant differences were observed also in the use of augmentation between the 2 groups (13 case vs 4 cases, $p = .009$). Results and comparison between groups are summarized in Table 3. Also, all planned data (dimension of the baseplate, augmentations, length of screws) were confirmed intra-operatively in the NAV group.

Discussion

The glenoid component positioning in RSA is crucial to prevent failure, loosening and biomechanical mismatch that affect the function and clinical result. Coverage by the baseplate of the glenoid surface, version, inclination, and offset, are all essential for implant survival.^{16,26} However, the glenoid

Table 3. Basic Characteristics and Comparative Analysis Between the Navigated and the Conventional Groups.

	NAV	CON	
	Results		<i>p</i>
Age (years) ^{a,§}	75 + 5.9 (58-84)	72 + 4.9 (64-80)	.057
Gender (M / F) ^{b,#}	3 / 17	4 / 16	1.00
BMI (kg/m ²) ^{c,§}	22.95 + 3.18 (18.63-29.75)	23.40 + 2.68 (19.22-28.89)	.66
Fixation with 2 screws ^{b,#}	17	3	.019*
Length of screws (mm) ^{a,§}	35.5 + 4.4 (26-42)	29.9 + 3.6 (22-38)	<.001*
Augmented baseplate ^{b,#}	13	4	.009*

Statistical analysis) a: Mann-Whitney U test; b: Fischer exact test; c: Student T test; *: statistically significant difference. Values shown) §: mean + SD (range min-max); #: absolute number of cases.

Significant differences are in bold.

NAV: navigated group; CON: conventional group; M: male; F: female; BMI: body mass index.

anatomy presents an extreme variability from one subject to another, without considering impaired bone quality and bone defects present in osteoarthritic and arthritic scapulohumeral joints. In addition, a difficult surgical exposure, the limited size of the glenoid and difficult visualization of anatomical reference landmarks make to get optimal placement and stable bone fixation of the base plate quite challenging. Lastly, mispositioned screws may be harmful to the surrounding soft tissues, such as the axillary (inferior screw) or suprascapular (superior screw) nerve and blood vessels.

This study confirms how intra-operative navigation based on pre-operative CT-based planning allows to implant a lesser number of longer screws to obtain primary stability. As highlighted by Hopkins et al.²⁷ longer screws provide greater stability, because they allow a greater effective surface area to remain well fixed to the bone than do shorter screws. Therefore, the possibility of obtaining longer screw during glenoid fixation using intra-operative navigation will improve fixation of the prosthesis.

Other factors as number of screws and their position (overall configuration) seem to be less important to obtain primary stability. Hoening et al.²⁸ in their cadaveric evaluation shown that a third posterior screw can reduce to a third the micromotion during movements hence it can decrease the possibility of loosening. However, the positive effect on baseplate fixation from increasing the number of screws has not been consistently reported. On the other hand, Dharia et al.²⁹ found that the combination of 2 screws (1 superior and 1 inferior) resulted in higher micromotion than a combination using 4 peripheral screws (superior, anterior, inferior and posterior). Roche et al.³⁰ found that the average displacement with 2 screws was significantly greater than that with 4 screws in both the antero-posterior and supero-inferior cyclic loading, while no differences were observed in displacement before and after cyclic loading between the 4- and 6-screw configurations in either the supero-inferior or antero-posterior direction. Conversely, James et al.³¹ compared the use of 2 (superior and inferior) and 4 screws and found no significant differences between these 2 groups in micromotion and displacement. Lung et al.³² found that increasing the number of screws from 2 to 4 did not

significantly improve initial baseplate fixation in uniform bone density. With such heterogeneous results, surgeons tend to use more than 2 screws only in cases where a satisfactory fixation is not obtained using superior and inferior screws as gold standard in our clinical practice. In fact, while theoretically 4 screws should provide better fixation than only 2 screws superiorly and inferiorly placed, other studies have shown as additional screws can reduce the amount of bone stock available for baseplate support and increase the possibility of soft tissue complications.³² For those reasons, in our opinion obtaining optimal fixation using the lesser number of screws is the best decision to decrease soft tissue damage and possible complications.

Navigated RSA, also, help in understanding defects due to eccentric bone loss. Augmented glenoid components were designed as an alternative to eccentric reaming and bone-grafting to compensate for posterior glenoid bone loss, thus reducing excessive bone removal and medialization of the baseplate. Sabesan et al.³³ demonstrated significantly less joint line medialization when they attempted to correct the position of the baseplate to both neutral (mean, 8.3 mm vs 3.8 mm) and 6° of retroversion (mean, 7.2 mm vs 3.36 mm). Posterior augmented metaglena also provided up to 18° of more correction of the version when the amount of bone removal was held constant. Kersten et al.³⁴ demonstrated that posterior augmented designs (both stepped and wedged designs) resulted in statistically significant improvements over a standard implant in decreasing mean reaming depth, decreasing mean bone volume removal and increasing percentage of back surface supported by cortical bone. Furthermore, the wedged glenoid component was more bone preserving than the stepped component. The statistically higher rate of augmented baseplate in the NAV group compared to the CON group demonstrated how CT planning can better improve surgeons understanding of glenoid deformities, thus reducing excessive bone loss and medialization.

In a cadaveric study, we recently demonstrated that pre-operative CT-based planning associated to intra-operative navigation are successful in avoid cortices perforation by the central peg of the baseplate and in correct positioning and length of screws.²⁵ We also tried to study *in vivo* positioning by means of post-operative low-dose CT scan in this same

groups of patients (both NAV and CON), but metal artifact were too high and the few cases performed were unreadable; this stays as an interesting research topic to be studied.

Although this study revealed promising results regarding the use of computed navigation in RSA, its findings should be interpreted in light of its limitations. The most important is the risk of bias due to the nonrandomized retrospective study design as well as the overall low sample size. To reduce the risk of picking-up easier cases in the CON group, we added as inclusion criterion for the CON group to have had acquired pre-operative CT-scan. On the other hand, this same criterion could introduce the opposite bias: being not strictly necessary a CT-scan for pre-operative planning in the conventional technique, we may have selected more difficult cases in the CON group (those requiring pre-operative CT-scan, precisely) while all patients undergoing navigation had pre-operative CT-scan and planning regardless of the severity of deformity. Further studies such as randomized case-control trials are needed to assess if intra-operative navigation can reduce bone loss comparing to standard procedure while using augmented baseplate, if this can lead to better clinical outcomes and if it can lead to a higher survival of these implants.

Conclusion

This study showed how useful 3D CT-based planning helps in identifying the best position of the metaglena and the usefulness of receiving directly in the operating theater real-time feedback on the change in position (medialization, version, inclination) of the glenoid component and it improves the accuracy of its positioning. This intra-operative real-time guide allows for going beyond all the problems of surgical exposure of the glenoid, anatomical variability and safety in the positioning of the components. Intra-operative navigation can lead surgeons to better understand and treat glenoid deformities. This study shows promising results, suggesting that improved baseplate and screw positioning and fixation is possible when computer-assisted implantation is used in RSA comparing to a conventional procedure. Further analysis is required to determine the biomechanical implications of fixation differences relative to conventional techniques, and ultimately the effect on patient clinical outcomes.

Authors' Note

Fabio Moreschini and Nicola Mondanelli contribute equally to the work.

Acknowledgments

We would thank Eng. Nicolas Hohl from OrthoBlue for the technical data regarding CT scan settings required for 3D reconstruction and planning.

Declaration of Conflicting Interests


The author(s) declared no potential conflicts of interest with respect to the research, authorship, and/or publication of this article.


Funding

The author(s) received no financial support for the research, authorship, and/or publication of this article.

ORCID iD

Giovanni Battista Colasanti  <https://orcid.org/0000-0002-5561-8612>

Lorenzo Mannelli  <https://orcid.org/0000-0002-9102-4176>

Nicola Mondanelli  <https://orcid.org/0000-0002-0684-4197>

References

1. Samitier G, Alentorn-Geli E, Torrens C, Wright TW. Reverse shoulder arthroplasty. Part 1: Systematic review of clinical and functional outcomes. *Int J Shoulder Surg.* 2015;9(1):24-31. doi: 10.4103/0973-6042.150226
2. Ceri L, Mondanelli N, Sangaletti R, Bottai V, Muratori F, Giannotti S. Simultaneous bilateral reverse shoulder arthroplasty for bilateral four-part fracture of the proximal humerus in an elderly patient: a case report. *Trauma Case Rep.* 2019;23:100242. doi:10.1016/j.tcr.2019.100242
3. Graves SE, Davidson D, Ingerson L, et al. The Australian Orthopaedic Association National Joint Replacement Registry. *Med J Aust.* 2004;180(5):31-34. doi:10.5694/j.1326-5377.2004.tb05911.x
4. Papadonikolakis A, Neradilek MB, Matsen FA. Failure of the glenoid component in anatomic total shoulder arthroplasty. *J Bone Jt Surgery-American Vol.* 2013;95(24):2205-2212. doi: 10.2106/jbjs.l.00552
5. Bohsali KI, Bois AJ, Wirth MA. Complications of shoulder arthroplasty. *J Bone Jt Surg Am Vol.* 2017;99(3):256-269. doi: 10.2106/JBJS.16.00935
6. Iannotti JP, Weiner S, Rodriguez E, et al. Three-dimensional imaging and templating improve glenoid implant positioning. *J Bone Jt Surg Am Vol.* 2015;97(8):651-658. doi:10.2106/JBJS.N.00493
7. Giannotti S, Bottai V, Dell'Osso G, et al. Thirty-six consecutive reverse shoulder arthroplasties in cuff arthropathy: our experience with the anterosuperior approach. *Eur Orthop Traumatol.* 2014; 5(3):293-298. doi:10.1007/s12570-014-0248-0
8. Middernacht B, De Roo PJ, Van Maele G, De Wilde LF. Consequences of scapular anatomy for reversed total shoulder arthroplasty. *Clin Orthop Relat Res.* 2008;466(6):1410-1418. doi:10.1007/s11999-008-0187-6
9. Iannotti JP, Greeson C, Downing D, Sabesan V, Bryan JA. Effect of glenoid deformity on glenoid component placement in primary shoulder arthroplasty. *J Shoulder Elb Surg.* 2012;21(1):48-55. doi:10.1016/j.jse.2011.02.011
10. Scalise J. Protesi inversa di Spalla. *Minerva Ortop e Traumatol.* 2009;60(1):53-59. Accessed July 26, 2020. <https://www.minerva-medica.it/it/riviste/minerva-ortopedica-traumatol/articolo.php?cod=R14Y2009N01A0053>
11. Chebli C, Huber P, Watling J, Bertelsen A, Bicknell RT, Matsen F. Factors affecting fixation of the glenoid component of a reverse total shoulder prosthesis. *J Shoulder Elb Surg.* 2008;17(2): 323-327. doi:10.1016/j.jse.2007.07.015

12. Farshad M, Gerber C. Reverse total shoulder arthroplasty-from the most to the least common complication. *Int Orthop*. 2010; 34(8):1075-1082. doi:10.1007/s00264-010-1125-2
13. Nyffeler RW, Werner CML, Gerber C. Biomechanical relevance of glenoid component positioning in the reverse Delta III total shoulder prosthesis. *J Shoulder Elb Surg*. 2005;14(5):524-528. doi:10.1016/j.jse.2004.09.010
14. Venne G, Rasquinha BJ, Pichora D, Ellis RE, Bicknell R. Comparing conventional and computer-assisted surgery baseplate and screw placement in reverse shoulder arthroplasty. *J Shoulder Elb Surg*. 2015;24(7):1112-1119. doi:10.1016/j.jse.2014.10.012
15. DiStefano JG, Park AY, Nguyen TQD, Diederichs G, Buckley JM, Montgomery WH. Optimal screw placement for base plate fixation in reverse total shoulder arthroplasty. *J Shoulder Elb Surg*. 2011;20(3):467-476. doi:10.1016/j.jse.2010.06.001
16. Codsi MJ, Iannotti JP. The effect of screw position on the initial fixation of a reverse total shoulder prosthesis in a glenoid with a cavitory bone defect. *J Shoulder Elb Surg*. 2008;17(3):479-486. doi:10.1016/j.jse.2007.09.002
17. Humphrey CS, Kelly JD, Norris TR. Optimizing glenosphere position and fixation in reverse shoulder arthroplasty, part two: the three-column concept. *J Shoulder Elb Surg*. 2008;17(4):595-601. doi:10.1016/j.jse.2008.05.038
18. Gutiérrez S, Comiskey CA IV, Luo ZP, Pupello DR, Frankle MA. Range of impingement-free abduction and adduction deficit after reverse shoulder arthroplasty. Hierarchy of surgical and implant-design-related factors. *J Bone Jt Surg Ser A*. 2008;90(12):2606-2615. doi:10.2106/JBJS.H.00012
19. Hendel MD, Bryan JA, Barsoum WK, et al. Comparison of patient-specific instruments with standard surgical instruments in determining glenoid component position: a randomized prospective clinical trial. *J Bone Jt Surg Ser A*. 2012;94(23):2167-2175. doi:10.2106/JBJS.K.01209
20. Kircher J, Wiedemann M, Magosch P, Lichtenberg S, Habermeyer P. Improved accuracy of glenoid positioning in total shoulder arthroplasty with intraoperative navigation: a prospective-randomized clinical study. *J Shoulder Elb Surg*. 2009;18(4):515-520. doi:10.1016/j.jse.2009.03.014
21. Nguyen D, Ferreira LM, Brownhill JR, et al. Improved accuracy of computer assisted glenoid implantation in total shoulder arthroplasty: an in-vitro randomized controlled trial. *J Shoulder Elb Surg*. 2009;18(6):907-914. doi:10.1016/j.jse.2009.02.022
22. Verbort O, De Smedt T, Vanhees M, Clockaerts S, Parizel PM, Van Glabbeek F. Accuracy of placement of the glenoid component in reversed shoulder arthroplasty with and without navigation. *J Shoulder Elb Surg*. 2011;20(1):21-26. doi:10.1016/j.jse.2010.07.014
23. Giannotti S, Sacchetti F, Citarelli C, et al. Single-use, patient-specific instrumentation technology in knee arthroplasty: a comparative study between standard instrumentation and PSI efficiency system. *Musculoskelet Surg*. 2020;104(2):195-200. doi:10.1007/s12306-019-00612-3
24. Barrett I, Ramakrishnan A, Cheung E. Safety and efficacy of intraoperative computer-navigated versus non-navigated shoulder arthroplasty at a tertiary referral. *Orthop Clin North Am*. 2019; 50(1):95-101. doi:10.1016/j.ocl.2018.08.004
25. Colasanti GB, Moreschini F, Cataldi C, Mondanelli N, Giannotti S. GPS guided reverse shoulder arthroplasty. *Acta Biomed*. 2020; 91(4 S):204-208. doi:10.23750/abm.v91i4-S.9377
26. Harman M, Frankle M, Vasey M, Banks S. Initial glenoid component fixation in "reverse" total shoulder arthroplasty: a biomechanical evaluation. *J Shoulder Elb Surg*. 2005;14(1):S162-S167. doi:10.1016/j.jse.2004.09.030
27. Hopkins AR, Hansen UN, Bull AMJ, Emery R, Amis AA. Fixation of the reversed shoulder prosthesis. *J Shoulder Elb Surg*. 2008;17(6):974-980. doi:10.1016/j.jse.2008.04.012
28. Hoenig MP, Loeffler B, Brown S, et al. Reverse glenoid component fixation: is a posterior screw necessary? *J Shoulder Elb Surg*. 2010;19(4):544-549. doi:10.1016/j.jse.2009.10.006
29. Dharia MA, Bischoff JE, Schneider D. Impact of modeling assumptions on stability predictions in reverse total shoulder arthroplasty. *Front Physiol*. 2018;9(AUG):1-12. doi:10.3389/fphys.2018.01116
30. Roche C, DiGeorgio C, Yegres J, et al. Impact of screw length and screw quantity on reverse total shoulder arthroplasty glenoid fixation for 2 different sizes of glenoid baseplates. *JSES Open Access*. 2019;3(4):296-303. doi:10.1016/j.jses.2019.08.006
31. James J, Allison MA, Werner FW, et al. Reverse shoulder arthroplasty glenoid fixation: is there a benefit in using four instead of two screws? *J Shoulder Elb Surg*. 2013;22(8):1030-1036. doi:10.1016/j.jse.2012.11.006
32. Lung TS, Cruickshank D, Grant HJ, Rainbow MJ, Bryant TJ, Bicknell RT. Factors contributing to glenoid baseplate micromotion in reverse shoulder arthroplasty: a biomechanical study. *J Shoulder Elb Surg*. 2019;28(4):648-653. doi:10.1016/j.jse.2018.09.012
33. Sabesan V, Callanan M, Sharma V, Iannotti JP. Correction of acquired glenoid bone loss in osteoarthritis with a standard versus an augmented glenoid component. *J Shoulder Elb Surg*. 2014; 23(7):964-973. doi:10.1016/j.jse.2013.09.019
34. Kersten AD, Flores-Hernandez C, Hoenecke HR, D'Lima DD. Posterior augmented glenoid designs preserve more bone in biconcave glenoids. *J Shoulder Elb Surg*. 2015;24(7):1135-1141. doi:10.1016/j.jse.2014.12.007