

## Research Article



# Alveolar ridge preservation with a collagen material: a randomized controlled trial

Sigmar Schnutenhaus <sup>1,2,\*</sup>, Isabel Doering <sup>1</sup>, Jens Dreyhaupt <sup>3</sup>,  
Heike Rudolph <sup>2</sup>, Ralph G. Luthardt <sup>2</sup>

<sup>1</sup>Private Practice, Hilzingen, Germany

<sup>2</sup>Department of Prosthetic Dentistry, Center of Dentistry, Ulm University, Ulm, Germany

<sup>3</sup>Institute of Epidemiology and Medical Biometry, Ulm University, Ulm, Germany



Received: Jul 19, 2018

Accepted: Aug 19, 2018

### \*Correspondence:

**Sigmar Schnutenhaus**

Private Practice, Breiter Wasmen 10, Hilzingen  
78247, Germany.

E-mail: info@schnutenhaus.de

Tel: +49-7731-182755

Fax: +49-7731-182766


Copyright © 2018. Korean Academy of  
Periodontology

This is an Open Access article distributed  
under the terms of the Creative Commons  
Attribution Non-Commercial License ([https://  
creativecommons.org/licenses/by-nc/4.0/](https://creativecommons.org/licenses/by-nc/4.0/)).

### ORCID iDs

Sigmar Schnutenhaus 


<https://orcid.org/0000-0003-3593-7074>

Isabel Doering 


<https://orcid.org/0000-0001-7161-792X>

Jens Dreyhaupt 

<https://orcid.org/0000-0001-8057-161X>

Heike Rudolph 

<https://orcid.org/0000-0002-0746-3003>

Ralph G. Luthardt 

<https://orcid.org/0000-0001-7588-3547>

### Funding

The trial received financial support and  
support in kind of materials from Resorba  
Medical GmbH, Nuremberg, Germany, and  
from the Oral Reconstruction Foundation,  
Basel, Switzerland, Grant No. CF41305.

### Author Contributions

Conceptualization: Sigmar Schnutenhaus,  
Heike Rudolph, Ralph G. Luthardt;

Data curation: Sigmar Schnutenhaus,

## ABSTRACT

**Purpose:** Resorption of the alveolar bone is an unavoidable consequence of tooth extraction when appropriate alveolar ridge preservation (ARP) measures are not taken. The objective of this trial was to test the hypothesis that dimensional changes in the alveolar bone after tooth extraction would be reduced by inserting an equine collagen membrane and a collagen cone to fill and seal the alveolus (as ARP), in comparison to extraction with untreated alveoli.

**Methods:** In this randomized clinical trial, 31 patients were directly treated with the collagen material after extraction of a tooth from the maxilla (the ARP group). Twenty-nine patients served as the control group. After extraction, no further treatment (i.e., no socket preservation measures) was performed in the control group. Changes in the alveolar process immediately after extraction and after an 8 ( $\pm 1$ )-week healing period were evaluated 3-dimensionally. Blinded analyses were performed after superimposing the data from the digitalized impressions and surfaces generated by cone-beam computed tomography.

**Results:** Both the ARP and control groups showed a reduction of bone in the alveolar area after tooth extraction. However, significantly less bone resorption was detected in the clinically relevant buccal region in the ARP group. The median bone reduction was 1.18 mm in the ARP group and 5.06 mm in the control group ( $P=0.03$ ).

**Conclusions:** The proposed hypothesis that inserting a combination material comprising a collagen cone and membrane would lead to a difference in alveolar bone preservation can be accepted for the clinically relevant buccal distance. In this area, implantation of the collagen material led to significantly less alveolar bone resorption. German Clinical Trials Register at [www.drks.de](http://www.drks.de), DRKS00004769.

**Keywords:** Alveolar bone loss; Alveolar ridge augmentation; Bone regeneration; Biocompatible materials; Tooth extraction

## INTRODUCTION

After tooth extraction, changes take place in the resorption characteristics of the alveolar process [1]. In particular, significant resorption of the buccal portion of the empty cavity can be detected [2]. The basis for natural regeneration and bone regeneration is that the defect fills with blood. A stable blood clot is overgrown by epithelium, which seals the wound. Within the blood clot,

Heike Rudolph; Formal analysis: Sigmar Schnutenhaus; Jens Dreyhaupt, Heike Rudolph, Ralph G. Luthardt; Investigation: Sigmar Schnutenhaus Isabel Doering; Methodology: Sigmar Schnutenhaus, Heike Rudolph, Ralph G. Luthardt; Software: Jens Dreyhaupt; Project administration: Sigmar Schnutenhaus, Heike Rudolph; Writing - original draft: Sigmar Schnutenhaus; Writing - review & editing: Isabel Doering, Jens Dreyhaupt, Heike Rudolph, Ralph G. Luthardt.

#### Conflict of Interest

Dr. Sigmar Schnutenhaus gives lectures sponsored by both funding companies. Isabel Doering, Dr. Jens Dreyhaupt, Dr. Heike Rudolph and Prof. Dr. Ralph G. Luthardt declare that no conflicts of interest exist as per the guidelines of the International Committee of Medical Journal Editors. No potential conflict of interest relevant to this article was reported.

fibrin forms a natural support structure and scaffold, which facilitates the formation of osteoid and its subsequent calcification [3]. Bone regeneration is complete after approximately 120 days, and the periosteum fully stabilizes after approximately 180 days [4,5]. These regeneration processes, which start from the empty alveolus and result in mature, mineralized bone, occur over intervals that vary widely among individuals and are not predictable [6]. However, bone regeneration does not lead to complete replacement of the alveolar bone. A recent review showed that the above-described defect healing process results in a mean horizontal degeneration of the alveolar process of 3.8 mm in the vestibular-oral direction and a mean vertical degeneration of 1.2 mm over the first 6 months after tooth extraction [7,8]. During this process, vestibular/buccal degeneration is significantly more pronounced, which could be due to a reduced blood supply to the thin vestibular bone [9]. Methods of stabilizing the bone, thereby reducing the extent of the resorption process, include the insertion of different materials into the alveolar cavity for alveolar ridge preservation (ARP) [10-12]. Apart from autologous bone, allogenic, xenogeneic, and synthetic bone replacement materials are available for ARP [1,7,8]. It has been shown that the various ARP materials result in a reduction of the dimensional change in the hard and soft tissue, but cannot entirely prevent resorption [8]. Adequate bone regeneration is significant for the functional and aesthetic prognosis of an implant [13].

A procedure for reducing bone resorption by applying a fully resorbable material would therefore be of interest.

A systematic literature search regarding the use of pure collagen materials for ARP using the search terms (clinical AND (trial OR study OR systematic review) AND (ARP OR “alveolar ridge preservation” OR “socket preservation” OR (tooth OR teeth AND (ridge preservation OR socket preservation) AND collagen\*)) revealed no studies describing the clinical efficacy of ARP with a collagen material compared with untreated post-extraction alveoli.

The objective of this trial was to investigate the clinical application of a combination material comprising a collagen cone and membrane for bone preservation and to compare its results to those observed in untreated post-extraction alveoli. At present, no adequate clinical human studies of this combination material have been conducted [14,15]. The proposed hypothesis was that using a collagen material for ARP might reduce the dimensional changes of the alveolar bone after tooth extraction to a significant extent in comparison with sites untreated after extraction.

## MATERIALS AND METHODS

### Trial design

The trial was performed as a monocentric, parallel-group randomized human clinical trial in accordance with the Declaration of Helsinki. It is reported according to the CONSORT guidelines [16-18]. No modifications of the method were made after the trial began. Recruitment and enrollment of patients were performed from February 2013 to March 2015. The trial was designed in accordance with the following:

- The World Medical Association's Declaration of Helsinki
- Clinical Investigation of Medical Devices for Human Subjects-Good Clinical Practice (ISO 4155:2011)
- Guidelines of Good Clinical Practice (2001/20/EC).

The study protocol was approved by the Ethical Committee of Ulm University (application No. 337/12, approval on February 13, 2013) and registered in the German Clinical Trials Register as DRKS00004769 (International Clinical Trials Registry Platform of the World Health Organization).

After receiving oral and written information about the study and before participating, all patients eligible for the study and willing to take part provided written consent.

### Participants

Sixty patients took part in the study, each requiring the extraction of a maxillary tooth. The indication for the extraction was severe periodontal disease or destruction due to caries or trauma. All patients visited the first author's office (Private Practice, Hilzingen, Germany) for a routine check-up or with need for treatment. If the clinical examination showed that a tooth needed to be extracted, patients were first verbally informed by the clinical investigator about the possibility of taking part in the trial. The written information for patients was handed out afterwards. Patients provided informed consent at the next appointment, if they wanted to take part in the study.

Only patients who opted for an implant-based restoration after tooth extraction were enrolled.

Participation in the trial was also subject to the following conditions:

- Age over 18 years, as the participants had to be legally competent.
- The presence of a tooth or existing implant directly adjacent to the tooth to be extracted.
- The absence of a detectable primary need for additional augmentation due to advanced vertical bone defects.
- Adequate mouth opening to permit the future insertion of the implant with an implant drilling template.
- Non-smoker status or smoking fewer than 10 cigarettes/day.
- No administration of bisphosphonates.
- No pregnancy.
- No alcohol or drug abuse.
- No infectious disease, such as hepatitis or human immunodeficiency virus (HIV) and/or acquired immunodeficiency syndrome (AIDS).
- No uncontrolled severe diabetes mellitus. In patients with diabetes, the long-term hemoglobin A1c level was required to be below 6.7%.

All patients were recruited at the first author's private practice. All interventions and follow-up assessments were performed at this office by the first author who was the single clinical investigator and the only dentist who treated all participating patients.

### Interventions

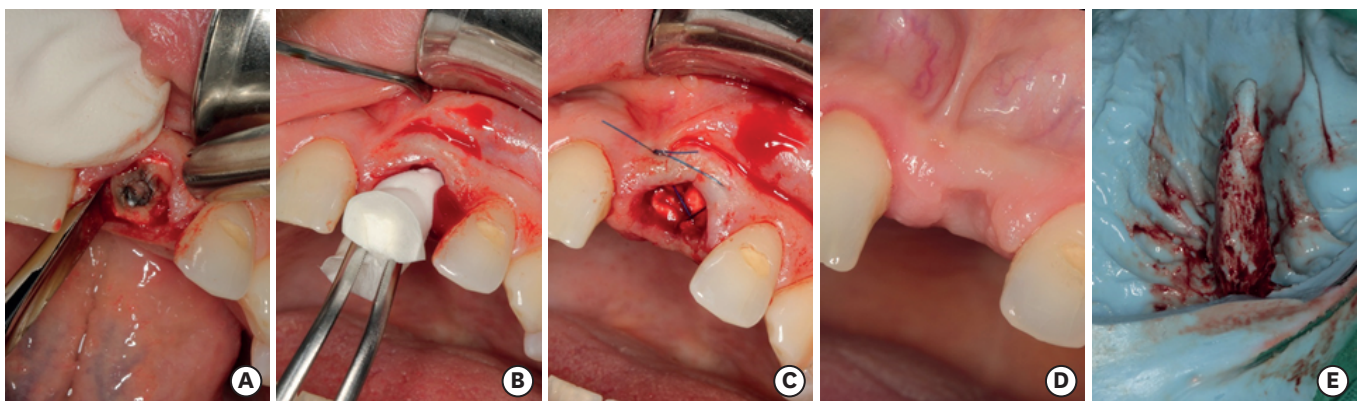
All patients were treated under local anesthesia (Ultracain DS 1:200,000, Sanofi Aventis, Frankfurt, Germany). When molars were extracted, the crown was decapitated and the roots separated using a dental turbine with a diamond bur. Periostomes were then used for atraumatic extraction and removal of the teeth after complete mobilization. The alveolus in the area of extraction was then carefully curettaged. An impression with alginate was made immediately after tooth extraction in order to document the condition of the alveolus and the existing bone. The alveolus was searched thoroughly for any residues of the impression material. It was once again curettaged and rinsed with sterile sodium chloride solution. No

further measures were taken in the control group. In the ARP group, a collagen membrane and a collagen cone (PARASORB Sombrero®, Resorba, Nuremberg, Germany) were inserted in accordance with the manufacturer's instructions. This combination material consisted of a collagen cone and an equine collagen membrane. It contained 31.2 mg of absorbable native equine collagen fibrils. The collagen cone had a very open porous structure with low density (17.6 mg/cm<sup>3</sup>) and pores approximately 120 µm in diameter to support vascularization; in contrast, the higher-density membrane (141.9 mg/cm<sup>3</sup>) prevented the passage of fibroblasts. The 2 materials were combined into a single product to facilitate simple and fast application. A circular suprapariosteal pocket of coronal soft tissue was prepared. The soft tissue was not mobilized during this process; therefore, the alveolus was not primarily closed by mucosa. The collagen cone, which was trimmed to the size of the alveolus, and the trimmed membrane were then inserted into the alveolus without pressure. If the tooth had multiple roots, the collagen cone was divided into sections that matched the anatomy of the root. A cross mattress suture was applied to stabilize the position of the collagen material in the alveolus using monofilament polyamide-6 suture material (Figure 1A-D). The wounds were visually inspected after 1 week. At that time, the suture was removed from the patients in the ARP group.

After extraction, all patients received the following instructions for care for the next 24 hours:

- Avoid eating until the anesthetic effect subsides.
- Abstain completely from alcohol, coffee, and caffeinated drinks and cigarettes or other smoking products.
- Avoid rinsing the extraction wound to keep the blood clot in place.
- Avoid manual manipulation of the wound (e.g., pulling the lip, rigorous cleaning of the wound, etc.).

The patients were prescribed 600 mg of ibuprofen for pain reduction, to be self-administered as needed. No prophylactic antibiotics were prescribed. A provisional interim prosthesis was applied in exceptional cases only (e.g., for aesthetics when the front teeth were involved or for function where multiple teeth were lost) and only at the patient's request. The implant was fitted after 11 (±1) weeks.



**Figure 1.** (A) Atraumatic tooth extraction with periosteal reflection and forceps. (B) Introduction of the collagen cone with the membrane. (C) Temporary sutures to stabilize the combination material. (D) Status 3 months after implantation. (E) Impression of the alveolar cavity immediately after tooth extraction.

### Outcomes

The objective of this study was to determine the extent of resorption of the alveolar bone in the area of the post-extraction alveolus. The bone was inspected at the time of the extraction ( $T_0$ ) and after a healing time of 8 ( $\pm 1$ ) weeks ( $T_1$ ). An alginate impression was taken immediately after curettage of the alveolar cavity (Blueprint cremix, Dentsply DeTrey, Constance, Germany). The alginate was mixed according to the manufacturer's instructions and added to prefabricated closed metal impression trays, which had been coated with an adhesive. The alveolus was filled with alginate using a 2-mL disposable syringe cut open at the tip to the full diameter prior to the insertion of the impression trays (Figure 1E).

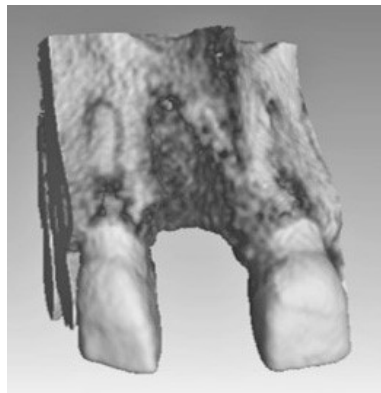
A cone-beam computed tomography (CBCT) image (Gendex CB500, Gendex Dental Systems, Des Plaines, IL, USA) with a resolution of 0.2 voxels was produced at time  $T_1$ . This image was used for implant planning and was the basis for the template-guided implantation, which was performed at 11 ( $\pm 1$ ) weeks after tooth extraction. Additionally, the surface data for the bone obtained from these images provided the basis for the data analysis.

#### *Digitalization of the impression*

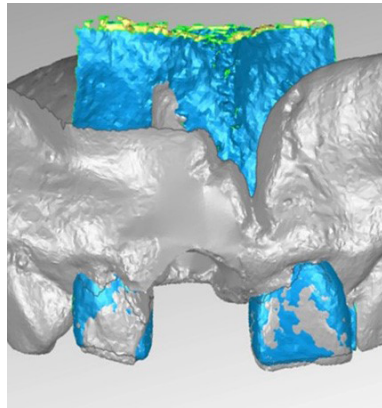
The impression was digitalized immediately after tooth extraction and disinfection, using a model scanner (3Shape Scanner D 700, 3Shape A/S, Copenhagen, Denmark) with a measurement uncertainty of  $\pm 16 \mu\text{m}$  according to a standardized measurement plan. The resulting data are represented as STL surfaces.

#### *Creation of surface models and reprocessing and matching of the data*

To analyze changes in the bone at 8 ( $\pm 1$ ) weeks post extraction, the CBCT images used to plan the implant were examined. The CBCT images were processed using a semi-automated procedure and software that can convert voxels into a surface (VGStudio MAX 2.2.5, Volume Graphics, Heidelberg, Germany) (Figure 2). The surface was calculated during this process by labeling known structures (soft tissue and bones) with their grayscale values. The suggested surface was then verified by the analyst, using clearly recognizable anatomical structures and a specified control plan, and corrected if necessary. The surface datasets from  $T_0$  and  $T_1$  were then superimposed using reference structures that were largely unchanged over the 8-week period (adjoining teeth on CBCT images that had few artifacts and/or the air/mucosal boundary in CBCT images with numerous artifacts). The datasets were superimposed using specialized software (Geomagic Studio, Version 9, Geomagic, Cary, NC, USA) (Figure 3).



**Figure 2.** Cone-beam computed tomography image of the alveolus at 8 ( $\pm 1$ ) weeks after extraction.



**Figure 3.** Matching of the models at time  $T_0$  and  $T_1$  via the hard tooth tissues.

In a further step, data for the bony alveoli were extracted from the dataset of the digitalized impressions (Figure 4A). Qualitative and quantitative measurements were performed with software (Surfacer Software, Version 10.6, SDRC Imageware, Neu-Isenburg, Germany) (Figure 4B). A clearly identifiable structure, a 6-pointed star, was superimposed over the alveolus to create unambiguous measurement paths for determining the distances of the bone remodeling (Figure 4C). By means of the intersections of the diagonal of the measuring aid and the 2 boundary curves, corner points were defined to create 2 individual hexagons. (Figure 4D). Between the superimposed hexagons constructed in this way, clearly defined vertices could be generated as measuring points (mesio-buccal, buccal, disto-buccal, disto-palatinal, palatinal, and mesio-palatinal). The distances between these corner points were measured in the vertical direction (Figure 4E). These paths were chosen according to their clinical relevance and followed analogical measurement procedures described elsewhere.

#### *Boundary curve analysis*

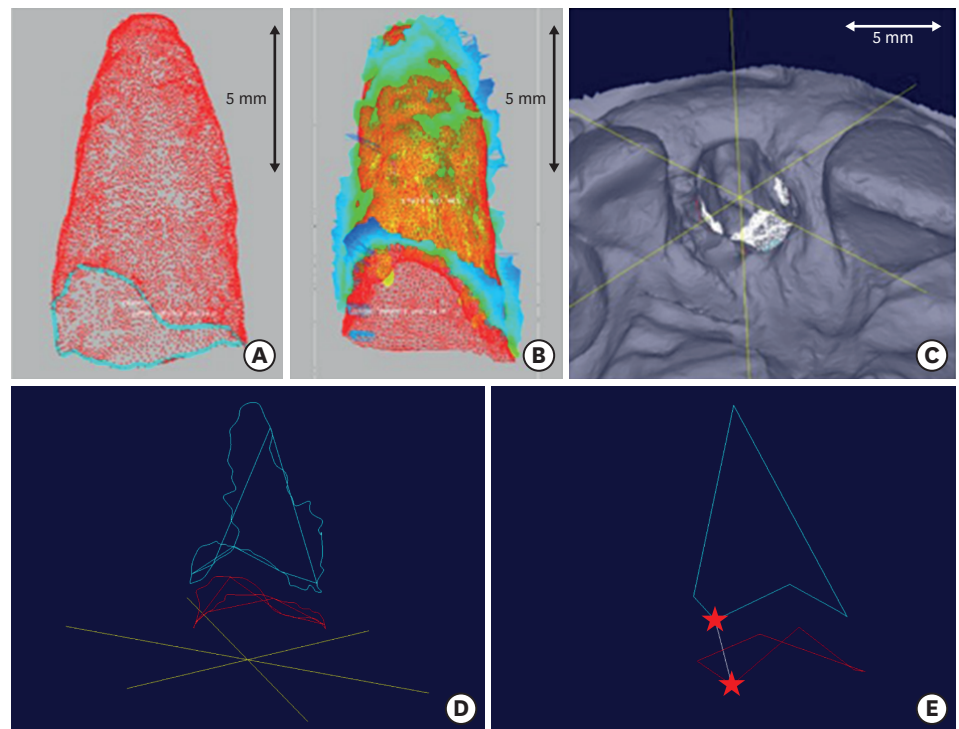
In addition to linear distance measurements at the 6 defined measurement points, the matched model datasets were measured in 3 dimensions (3D) using specialized software (Geomagic Studio, Geomagic Qualify 9, Geomagic, Research Triangle Park, NC, USA). For this purpose, boundary curves of the marginal bone were applied to both datasets. Based on the 2 applied boundary curves, the maximum path deviation and the mean across the entire crestal alveolar course could be determined (Figure 5).

#### **Sample size**

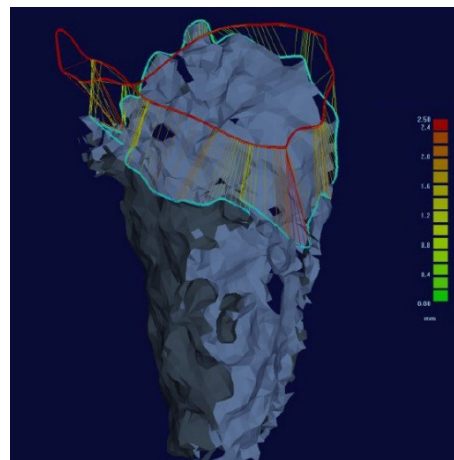
Due to a lack of clinical data, case numbers could not be estimated in advance. To achieve high clinical significance, 60 patients (30 ARP and 30 control) who required the extraction of a tooth from the maxilla participated in the trial. The determination of the number of cases was based on similar studies, which, however, investigated the feasibility of other materials for ARP [8,19]. From the biostatistical point of view, the trial was of an exploratory nature. Thus, all outcomes from the statistical tests must be interpreted as generating hypotheses and not as a proof of efficacy. We performed a *post hoc* power analysis to provide a basis for future comparative studies.

#### **Randomization**

A randomization list was produced for the entire trial, in which 60 patients (Institute of Epidemiology and Medical Biometry, Ulm University, Ulm, Germany) were assigned to groups in 6 strata. The data were stratified by sex (male/female), and region of the studied tooth (anterior tooth, pre-molar, and molar).



**Figure 4.** (A) Exposed surface of the post-extraction alveolus at time  $T_0$ , immediately after tooth extraction. (B) Exposed surfaces from the impression at time  $T_0$  superimposed on the cone-beam computed tomography image ( $T_1$ ) at 8 ( $\pm 1$ ) weeks post extraction. (C) Specification of measurement points for the sextant measurements. (D) By using the intersections of the diagonal of the measuring aid and the 2 boundary curves, corner points were defined for the creation of 2 individual hexagons. (E) The distance of these constructed corner points was measured in the vertical direction. (★ to ★).



**Figure 5.** Three-dimensional measurements of the distances using boundary curves. Based on the 2 applied edge curves, the boundary curve difference was calculated. In each case, a lot was cut from the edge curve of alveolar impression at  $T_0$  on the edge curve of the cone-beam computed tomography image of the alveolus at  $T_1$ . The resulting quantitative results provided the maximum deviation of 2 boundary curves, the mean, and the standard deviation.

Patient information (gender, region) was submitted to the principal investigator (RGL) or an authorized individual (HR), who had blinded access to the randomization list. The random assignment information was sent to the treatment center by fax according to the randomization list.

### Blinding

Blinding of the socket treatment was not possible. However, the digital datasets acquired from the alginate impression and the CBCT images taken at T<sub>0</sub> and T<sub>1</sub> were forwarded to the analyst (ID) in blinded and anonymized form. Deblinding was performed only after completion of the analysis, documentation, and statistical analysis. The deblinding was performed locally and by individuals who were not involved in the analysis.

### Statistical methods

The maxima, medians, and 25th and 75th percentiles are reported for the metric target parameters. Missing values were not replaced. This affected patients in whom the bone boundaries could not be clearly detected due to artifacts in the CBCT images.

The differences between the ARP and control groups were analyzed using the Wilcoxon rank-sum test. Due to the exploratory nature of the trial, all outcomes of statistical tests must be interpreted as generating hypotheses and not as proof. All statistical tests were performed at a significance level of  $\alpha=0.05$  (2-tailed) (SAS version 9.4; SAS Institute, Cary, NC, USA). There was no adjustment for multiple testing. The power analysis and calculation of the sample size were carried out using the *Proc Power* feature of SAS® version 9.4. For sample size calculation, a power of 80% and a 2-sided type 1 error of  $\alpha=0.05$  were assumed. For the *post hoc* power analysis, a 2-sided type 1 error of  $\alpha=0.05$  was assumed. All calculations were based on means and standard deviations.

## RESULTS

All patients were treated according to the clinical protocol (Figure 6). There were no postoperative complications. All enrolled patients completed the trial. Thirty-one patients were assigned to the collagen material group as a result of stratified randomization by sex and tooth region. Twenty-nine patients formed the control group and underwent extraction without further concomitant measures. Thirty-one females and 29 males participated in the trial. The ARP group included 15 male and 16 female patients; the control group comprised 14 male and 15 female subjects. The mean patient age was 52.3 years (range, 24–78 years). The randomized distribution of the teeth was as follows: 29 anterior teeth (14 ARP, 15 control), 25 premolars (13 ARP, 12 control) and 6 molars (4 ARP, 2 control) (**Supplementary Table 1**).

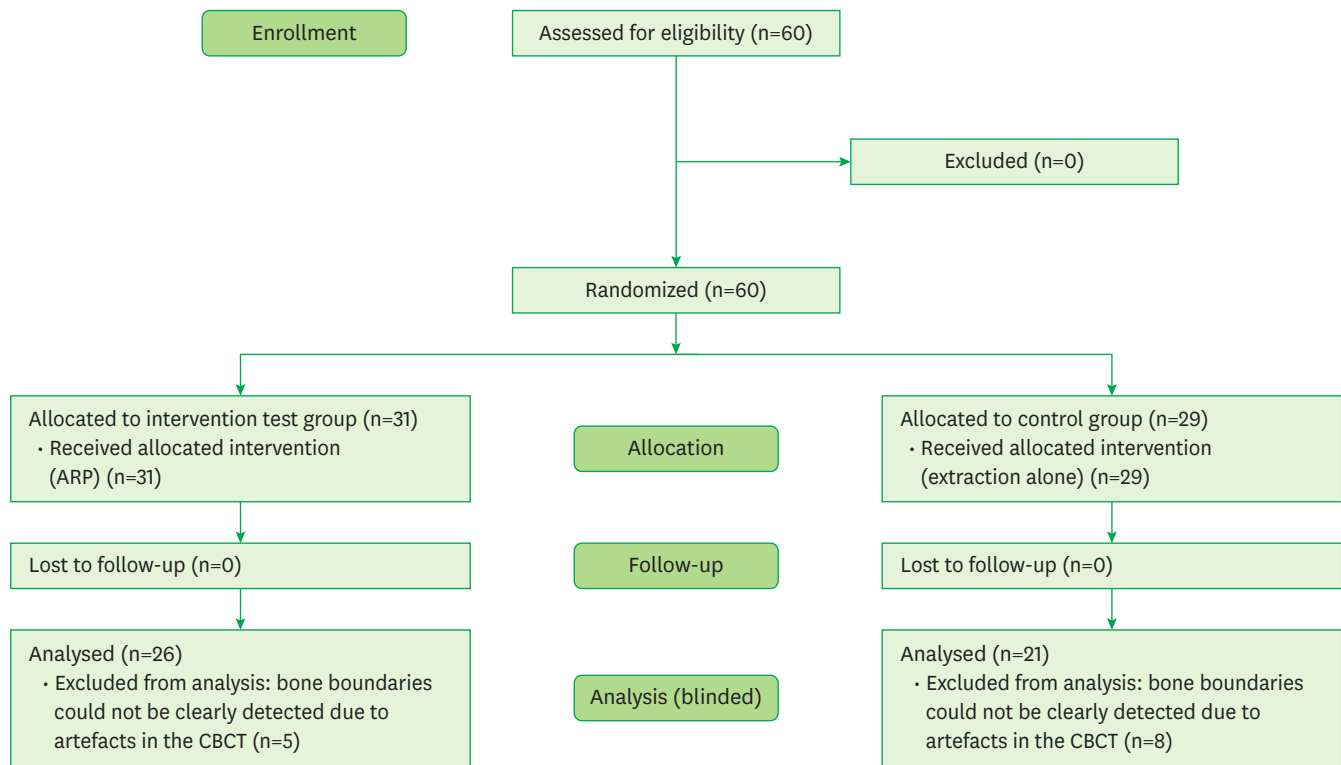
Thirteen cases could not be included in the blinded analysis because it was not possible to clearly detect the bone boundaries due to artifacts on CBCT. This affected 5 cases in the ARP group and 8 cases in the control group.

Table 1 presents the important bone degeneration variables linked to the location of the measurement path.

The analysis revealed significantly less bone degeneration along the buccal distance in the ARP group ( $P=0.031$ ; Figure 7). The remaining distances showed no significant differences between the 2 groups.

Specific tooth groups were also analyzed. Due to the small sample size, the molars were not considered.





**Figure 6.** Flow diagram of this randomized trial comparing extraction alone to a ridge-preserving procedure for the treatment of alveolar bone after tooth removal. ARP: alveolar ridge preservation, CBCT: cone-beam computed tomography.

**Table 1.** Bone degeneration after tooth extraction in the ARP group and control group, including the maxima, medians, and 25th and 75th percentiles

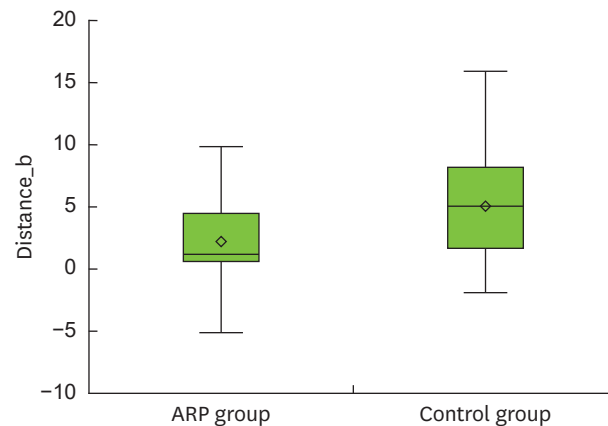
Parameter	Group	Valid datasets	Minimum	25th percentile	Median	75th percentile	Maximum	P value
Mesio-buccal distance	ARP	26	-4.09	-0.33	1.34	2.46	5.32	0.36
	Control	21	-1.48	1.24	2.03	2.27	4.00	
Buccal distance	ARP	26	-5.15	0.59	1.18	4.44	9.85	0.03 <sup>a)</sup>
	Control	21	-1.88	1.68	5.06	8.17	15.9	
Disto-buccal distance	ARP	26	-2.50	1.06	2.56	3.18	6.38	0.45
	Control	21	-0.89	0.27	2.00	3.25	3.81	
Disto-palatinal distance	ARP	26	-2.44	0.73	2.11	2.99	4.75	0.24
	Control	21	-1.50	0.87	1.69	2.18	3.28	
Palatinal distance	ARP	26	-3.36	1.45	2.92	3.76	7.49	0.43
	Control	21	-1.41	1.63	2.29	3.24	6.84	
Mesio-palatinal distance	ARP	26	-3.00	0.78	1.81	2.99	4.53	0.99
	Control	21	-1.92	0.64	1.75	2.83	4.80	

The distances are reported in millimeters (mm). The total sample size was 54 patients (27 ARP and 27 control), and molars were excluded.

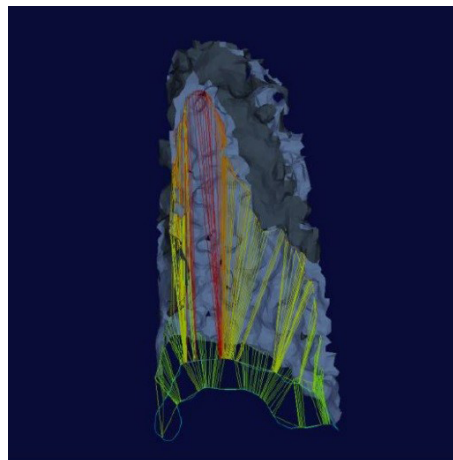
ARP: alveolar ridge preservation.

<sup>a)</sup>Statistically significant differences at  $P < 0.05$ , Wilcoxon rank-sum test.

A significant reduction in the buccal bone degeneration of the anterior teeth was observed in the ARP group (Table 2). The pre-molar group had no significant reduction of bone loss. However, the examination of the tooth regions highlighted a massive reduction of the buccal bone in the anterior teeth in the control group, with a median value of 7.64 mm (ARP group: 2.57 mm) (Figure 8). This group had the largest defect formations, sometimes with almost complete loss of the buccal alveolar wall. The loss of buccal bone was significantly less pronounced in the pre-molars (control: 1.35 mm, ARP: 1.10 mm). The subjects' sex had no effect on bone degeneration after tooth extraction.



**Figure 7.** Significantly less bone degeneration was found along the buccal distance in the ARP group (mm). ARP: alveolar ridge preservation.



**Figure 8.** Almost complete destruction of the buccal bone was noted at 8 weeks after tooth extraction.

The 3D measurements of the boundary curves of the alveoli ( $T_0$  versus  $T_1$ ) also revealed significantly less bone degeneration in the anterior teeth of the ARP group. Both the maximum values and the mean values of the change across the entire curvature of the alveolus were significantly different (Table 3).

The highest statistical power identified in the linear measurements of the samples was 69.7% for the buccal distance (Table 4). In the 3D measurements, we detected a statistical power of

**Table 2.** Bone degradation after tooth extraction in the ARP group and control group

Parameter	Group	Valid datasets	Minimum	25th percentile	Median	75th percentile	Maximum	P value
Anterior teeth	ARP	11	0.00	0.89	2.57	5.28	9.85	0.03 <sup>a)</sup>
	Control	12	2.05	5.37	7.64	8.99	15.90	
Pre-molars	ARP	11	-5.15	-0.40	1.10	3.01	4.65	0.84
	Control	12	-1.88	0.53	1.35	2.14	8.17	

Analysis of the anterior teeth and pre-molars with maxima, medians, and 25th and 75th percentiles. The distances are reported in millimeters (mm). The total sample size was 29 patients (14 ARP/15 control) in the anterior teeth group and 25 patients (13 ARP/12 control) in the pre-molar group.

ARP: alveolar ridge preservation.

<sup>a)</sup>Statistically significant differences at  $P < 0.05$ , Wilcoxon rank-sum test.

**Table 3.** Bone degradation after tooth extraction in the ARP group and control group

Parameter	Group	Valid datasets	Minimum	25th percentile	Median	75th percentile	Maximum	P value
Curve maximum values	ARP	11	1.34	2.28	3.23	6.43	11.05	0.03 <sup>a)</sup>
	Control	12	1.82	5.25	7.56	9.22	15.68	
Curve mean values	ARP	11	0.60	0.94	1.59	2.99	4.66	0.05 <sup>a)</sup>
	Control	12	0.75	2.28	3.05	3.70	6.73	

The 3-dimensional analysis of the anterior teeth subgroup was based on the coronal bony boundary curves of the post-extraction alveoli. Maxima, medians, 25th and 75th percentiles and standard deviations are reported. The deviations are reported in millimeters (mm). The total sample size was 29 patients (14 ARP, 15 control). ARP: alveolar ridge preservation.

<sup>a)</sup>Statistically significant differences at  $P < 0.05$ , Wilcoxon rank-sum test.

**Table 4.** Post hoc power analysis and sample size calculation for the parameters

Parameter	Effect size (d)	Power (1-β)	Total sample size
Mesio-buccal distance	0.296	0.166	362
Buccal distance	0.697	0.638	68
Disto-buccal distance	0.250	0.132	506
Disto-palatinal distance	0.313	0.180	322
Palatinal distance	0.161	0.083	1,214
Mesio-palatinal distance	0.022	0.051	64,288

Parameters from Table 1 (linear measurements of bone degeneration).

**Table 5.** Post hoc power analysis and sample size calculation for the parameters

Parameter	Effect size (d)	Power (1-β)	Total sample size
Maximum values of the curve	0.903	0.522	42
Mean values of the curve	0.833	0.460	48

Parameters from Table 3 (3-dimensional measurements of bone degeneration based on the coronal boundaries).

90.3% for the curve maximum values (Table 5). The *post hoc* sample size estimate exhibited a considerable spread among the parameters. For the linear measurements, sample sizes of 68-64,288 patients were calculated (Table 4). Using the 3D measurement methods, *post hoc* sample sizes of 42-48 patients were calculated (Table 5).

## DISCUSSION

This trial was designed in such a way that post-extraction changes in the maxillary alveolus were compared to a healing process without external influences as a baseline. Moreover, a non-invasive procedure was implemented for data acquisition, which also permitted independent review and testing of the outcomes.

The outcomes in this trial revealed a significant difference in the alveolar bone reduction at 8 (±1) weeks post-surgery between alveoli treated with the insertion of collagen material and untreated alveoli. Buccal bone degeneration differed significantly between the control and ARP groups (5.06 mm and 1.18 mm, respectively;  $P=0.031$ ). A significant reduction in bone degeneration was also confirmed in the 3D analysis of the boundary curves of the anterior teeth sub-group. Using mean values calculated across the boundary curves, the median reduction in bone degeneration was 1.46 mm. The median of the maximum reduction values was 4.33 mm in the ARP group and 7.56 mm in the control group.

Buccal bone reduction after tooth extraction appeared more pronounced on the CBCT images than in clinical measurements using periodontal probes or similar measurement devices. For example, the mean buccal bone degeneration in control patients, measured as the difference between CBCT-based measurements before extraction and at 3 months post-extraction, has been reported as 5.36 mm for single-rooted teeth and 5.89 mm for multi-rooted teeth [10].

A further trial based on the analysis of CBCT images revealed comparable results: the mean reduction of buccal bone 8 weeks after tooth extraction was 5.2 mm (range, 0.7–12.2) [2]. The magnitude of buccal bone loss was also confirmed in this trial. Conversely, a meta-analysis based primarily on clinical measurement outcomes reported buccal bone reductions of -1.1 to -3.5 mm in the test groups and -1.0 to -4.2 mm in the control groups [20].

The hypothesis that the application of the collagen material would lead to a reduction in bone degeneration after tooth extraction was therefore confirmed.

The power analysis calculated in this study showed that a sample size of 68 patients, using the linear measurement method, would be needed to detect differences in clinically relevant buccal bone degeneration. In the 3D-measurement method used in this study, fewer cases (42–48) would be needed. The number of cases used in this study can therefore be regarded as sufficient.

Numerous clinical studies have used different clinical or radiological measurement methods in addition to diverse materials and surgical methods for ARP [5,8,19]. Consequently, standardized measurement protocols in trial designs have been called for [1]. The protocol used in this trial, which involved the measurement of alveolar changes immediately after tooth extraction and at 8 ( $\pm 1$ ) weeks after surgery using CBCT, appears to be appropriate. A possible source of error with the use of CBCT data for bone modeling may be the detectability of incompletely mineralized bone. However, it was possible to demonstrate that marginal bone was visible in CBCT images with an accuracy of 0.6 mm, and that this measurement exhibited high reliability [21]. The ability to validate and reproduce the measurements and the 3D analyses must also be regarded as strengths of this method [13].

A further limitation of the procedure is that it is not possible to model bone in CBCT images that are rich in artifacts due to superimposed metallic structures [22]; 21.6% of the cases in this trial could not be analyzed for this reason. However, in the authors' opinion, methods involving digitalization and semi-automated software analysis offer significant benefits in terms of reproducibility, and they facilitate higher comparability than clinical measurement with probes. The method described in this study appears to offer lower rates of error and deviation due to measurement errors.

Moreover, the heterogeneity of the results of clinical studies is improved by various other external factors.

The choice of measurement time ( $T_1$ ) and the condition of the healed alveolar bone have a significant effect on the assessment of the outcomes. It was expected that after 8 ( $\pm 1$ ) weeks, bone healing would not be complete [3]. The 8 ( $\pm 1$ )-week time point was chosen in the present trial to allow early implantation (11 ( $\pm 1$ ) weeks post extraction), which would allow patients to benefit from the potential advantages of this timing [13].

In addition, differences in surgical methods affect bone resorption outcomes. For example, even the choice to close the alveolus using primary wound closure or by covering the alveolus with a membrane has a significant effect on wound healing [11].

A further external factor is the type of defect, which further complicates comparability. Classifications into defined defect classes after tooth extraction (for example, according to the number and state of the alveolar walls or the defect size itself) would be useful [23]. The

thickness of the alveolar walls or the interradicular bone septum, in cases of molar extraction, could also have a major effect on healing and regeneration and/or the ARP procedures [4]. However, under clinical conditions, the ability to determine the extent of the defect before surgery is limited. In the same way, it is almost impossible to reproduce the assessment of the alveolus in the context of a clinical trial. A CBCT image taken before tooth extraction could supply this information, but such imaging is generally ruled out for ethical reasons and to minimize radiation exposure. Appropriate modeling of the alveolus using the impression method described in this report may provide indications for intra-alveolar bone defects or dehiscences and may be useful in future studies. In such cases, it would be suitable to use the relevant recommendations to improve trial quality for future research [24,25].

Currently, it must be assumed that ARP measures cannot entirely prevent the loss of bone tissue; however, it appears that appropriate measures can reduce it. Minimizing bone resorption requires further research, and there is a need for procedures that match patients' individual situations with materials that are appropriate to the indication. One of the main indications for ARP is the potential prevention of the need for additional interventions in the form of augmentations. In addition to preventing the risks and side effects of additional surgery, ARP might also lead to improvements in the cost-to-benefit ratio and patient comfort.

In conclusion, the proposed hypothesis, according to which there would be a difference in bone reduction between alveoli treated with a combination material consisting of a collagen cone and a collagen membrane and untreated alveoli, can be accepted based on the outcomes of this trial. This hypothesis predicted improved bone preservation as a result of the implantation of the collagen combination material. Significantly less bone resorption was detected in the buccal region of the ARP group. The tooth region has a major effect on the degeneration of the alveolar bone. For example, the buccal bone degeneration after tooth extraction procedures without concomitant treatment measures was 5.7 times more pronounced in anterior teeth than in pre-molars. The insertion of the collagen material reduced this effect by a factor of 2.3. Therefore, the use of the combined treatment material can be recommended based on the available data.

## ACKNOWLEDGEMENTS

The trial was conducted as an investigator-initiated, non-profit trial (IIT) based on the German law regarding medicinal products and the professional statutes for the medical professions. It was carried out as a collaboration between the University of Ulm, Germany, Center for Dentistry, Clinic for Prosthetics Dentistry and the private practice of Dr. Schnutenhaus, Hilzingen, Germany.

## SUPPLEMENTARY MATERIAL

### Supplementary Table 1

Distribution of the teeth by region

[Click here to view](#)

## REFERENCES

1. Tan WL, Wong TL, Wong MC, Lang NP. A systematic review of post-extraction alveolar hard and soft tissue dimensional changes in humans. *Clin Oral Implants Res* 2012;23 Suppl 5:1-21.  
[PUBMED](#) | [CROSSREF](#)
2. Chappuis V, Engel O, Reyes M, Shahim K, Nolte LP, Buser D. Ridge alterations post-extraction in the esthetic zone: a 3D analysis with CBCT. *J Dent Res* 2013;92:195S-201S.  
[PUBMED](#) | [CROSSREF](#)
3. Schmidlin PR, Jung RE, Schug J. Prevention of alveolar ridge resorption after tooth extraction--a review. *Schweiz Monatsschr Zahnmed* 2004;114:328-36.  
[PUBMED](#) | [CROSSREF](#)
4. Iyer S, Haribabu PK, Xing Y. Part II. Minimizing alveolar bone loss during and after extractions. Protocol and techniques for alveolar bone preservation. *Alpha Omegan* 2014;107:14-25.  
[PUBMED](#)
5. Mardas N, Chadha V, Donos N. Alveolar ridge preservation with guided bone regeneration and a synthetic bone substitute or a bovine-derived xenograft: a randomized, controlled clinical trial. *Clin Oral Implants Res* 2010;21:688-98.  
[PUBMED](#) | [CROSSREF](#)
6. Trombelli L, Farina R, Marzola A, Bozzi L, Liljenberg B, Lindhe J. Modeling and remodeling of human extraction sockets. *J Clin Periodontol* 2008;35:630-9.  
[PUBMED](#) | [CROSSREF](#)
7. Sanz I, Garcia-Gargallo M, Herrera D, Martin C, Figuero E, Sanz M. Surgical protocols for early implant placement in post-extraction sockets: a systematic review. *Clin Oral Implants Res* 2012;23 Suppl 5:67-79.  
[PUBMED](#) | [CROSSREF](#)
8. Ten Heggeler JM, Slot DE, Van der Weijden GA. Effect of socket preservation therapies following tooth extraction in non-molar regions in humans: a systematic review. *Clin Oral Implants Res* 2011;22:779-88.  
[PUBMED](#) | [CROSSREF](#)
9. Misch CE, Dietsch-Misch F, Misch CM. A modified socket seal surgery with composite graft approach. *J Oral Implantol* 1999;25:244-50.  
[PUBMED](#) | [CROSSREF](#)
10. Crespi R, Cappare P, Gherlone EF. Bone recontouring in fresh sockets with buccal bone loss: a cone beam computed tomography study. *Int J Oral Maxillofac Implants* 2014;29:863-8.  
[PUBMED](#) | [CROSSREF](#)
11. Vittorini Orgeas G, Clementini M, De Risi V, de Sanctis M. Surgical techniques for alveolar socket preservation: a systematic review. *Int J Oral Maxillofac Implants* 2013;28:1049-61.  
[PUBMED](#) | [CROSSREF](#)
12. Pagni G, Pellegrini G, Giannobile WV, Rasperini G. Postextraction alveolar ridge preservation: biological basis and treatments. *Int J Dent* 2012;2012:151030.  
[PUBMED](#) | [CROSSREF](#)
13. Lambert F, Vincent K, Vanhoutte V, Seidel L, Lecloux G, Rompen E. A methodological approach to assessing alveolar ridge preservation procedures in humans: hard tissue profile. *J Clin Periodontol* 2012;39:887-94.  
[PUBMED](#) | [CROSSREF](#)
14. Annen BM, Schneider D, Schmidlin PR. Ridge preservation after tooth extraction using collagen cones with integrated membranes: a case series and volumetric analysis. *Implantologie* 2014;22:341-51.
15. Kunert-Keil C, Gredes T, Heinemann F, Dominiak M, Botzenhart U, Gedrange T. Socket augmentation using a commercial collagen-based product--an animal study in pigs. *Mater Sci Eng C* 2015;46:177-83.  
[PUBMED](#) | [CROSSREF](#)
16. Moher D, Schulz KF, Altman DG CONSORT. The CONSORT statement: revised recommendations for improving the quality of reports of parallel group randomized trials. *BMC Med Res Methodol* 2001;1:2.  
[PUBMED](#) | [CROSSREF](#)
17. Schulz KF, Altman DG, Moher D, Group C CONSORT Group. CONSORT 2010 Statement: Updated guidelines for reporting parallel group randomised trials. *J Clin Epidemiol* 2010;63:834-40.  
[PUBMED](#) | [CROSSREF](#)
18. Moher D, Hopewell S, Schulz KF, Montori V, Gøtzsche PC, Devereaux PJ, et al. CONSORT 2010 Explanation and Elaboration: Updated guidelines for reporting parallel group randomised trials. *J Clin Epidemiol* 2010;63:e1-37.  
[PUBMED](#) | [CROSSREF](#)

19. Fickl S, Zuhr O, Wachtel H, Stappert CF, Stein JM, Hürzeler MB. Dimensional changes of the alveolar ridge contour after different socket preservation techniques. *J Clin Periodontol* 2008;35:906-13.  
[PUBMED](#) | [CROSSREF](#)
20. de Avila ED, Filho JS, de Oliveira Ramalho LT, Real Gabrielli MF, Pereira Filho VA. Alveolar ridge augmentation with the perforated and nonperforated bone grafts. *J Periodontal Implant Sci* 2014;44:33-8.  
[PUBMED](#) | [CROSSREF](#)
21. Leung CC, Palomo L, Griffith R, Hans MG. Accuracy and reliability of cone-beam computed tomography for measuring alveolar bone height and detecting bony dehiscences and fenestrations. *Am J Orthod Dentofacial Orthop* 2010;137:S109-19.  
[PUBMED](#) | [CROSSREF](#)
22. Schulze R, Heil U, Gross D, Bruellmann DD, Dranischnikow E, Schwanecke U, et al. Artefacts in CBCT: a review. *Dentomaxillofac Radiol* 2011;40:265-73.  
[PUBMED](#) | [CROSSREF](#)
23. Seibert JS, Cohen DW. Periodontal considerations in preparation for fixed and removable prosthodontics. *Dent Clin North Am* 1987;31:529-55.  
[PUBMED](#)
24. De Buitrago JG, Avila-Ortiz G, Elangovan S. Quality assessment of systematic reviews on alveolar ridge preservation. *J Am Dent Assoc* 2013;144:1349-57.  
[PUBMED](#) | [CROSSREF](#)
25. Hämmerle CH, Araújo MG, Simion MOsteology Consensus Group 2011. Evidence-based knowledge on the biology and treatment of extraction sockets. *Clin Oral Implants Res* 2012;23 Suppl 5:80-2.  
[PUBMED](#) | [CROSSREF](#)