

Spinal capillary hemangiomas: Two cases reports and review of the literature

Thara Tunthanathip, Sanguansin Rattanalert, Thakul Oearsakul, Kanet Kanjanapradit¹

Department of Surgery, Neurosurgical Unit, ¹Department of Pathology, Faculty of Medicine, Prince of Songkla University, Songkhla, Thailand

ABSTRACT

Hemangiomas have rarely been found in the spinal cord. A few cases of spinal capillary hemangioma have been reported since 1987. The authors reported the two cases of capillary hemangioma including the tumor at conus medullaris and the another mimicked von Hippel-Lindau disease. A 15-year-old man was presented with coccydynia and left leg pain. A magnetic resonance imaging (MRI) revealed an intradural extramedullary enhancing mass at conus medullaris. Another case, a 31-year-old man was presented with a history of familial history of brain tumor, retinal hemangioma both eyes, multiple pancreatic cyst and syringobulbia with syringohydromyelia. On MRI, a well-circumscribed intramedullary nodule was detected at C5-6 level and multiple subpial nodule along cervicothoracic spinal cord. All patients underwent surgery, and the histological diagnosis confirmed capillary hemangioma. Although rare and indistinguishable from other tumors, capillary hemangioma should be in the differential diagnosis of the spinal cord tumor.

Key words: Capillary hemangioma, spinal cord tumor, vascular tumor, von Hippel-Lindau disease

Introduction

Spinal capillary hemangioma is a rare tumor. A few cases have been reported in the literature. This report describes the clinicopathological findings in two cases of spinal capillary hemangiomas, including a capillary hemangioma at the conus medullaris in an adolescent and the another mimicked von Hippel-Lindau disease (VHL) disease which have never been reported before in a middle-aged adult.

Case Reports

Case 1

A 15-year-old boy presented a 4 month history of coccydynia, associated with left leg pain, both of which had been progressively worsening. The previous medical history and family history were unremarkable, and an a neurological

examination was normal. There were no motor or sensory deficits, the deep-tendon reflexes were normal, and a straight leg raising test was negative on both sides. Bowel and bladder functions and digital rectal examination were all normal. Various laboratory tests showed no abnormalities, but magnetic resonance imaging (MRI) showed a round 2 cm intradural extramedullary mass at the conus medullaris. On T1-weighted images, the signal of the lesion was isointense, and T2-weighted images revealed a hyperintense and homogeneous, strong enhancement on contrast-enhanced T1-weighted images. A spinal angiography with embolization demonstrated a hypervascular mass at the L1 level, just right at the tip of the conus medullaris, arising from an enlarged anterior spinal artery [Figure 1].

After embolization, a T12-L1 laminectomy with total tumor removal was performed with insignificant blood loss. The tumor was found emerging from the anterior spinal artery and attached to the nerve root. After the operation, the patient's pain decrease, but the postoperative course was complicated by urinary retention. 3 month following the operation the patient recovered his ability to urinate normally. Grossly, the surgical specimen was a lobular, sharp bordered, reddish mass, measuring 2.0 cm in maximum diameter. Microscopically, the capillary hemangioma featured a lobular architecture, with the lobules being composed of tightly packed capillary-sized vessels lined by a single layer of endothelial cells. Diagnosis was confirmed by immunohistochemical staining that positive for CD34 and factor 8 [Figure 2].

Access this article online	
Quick Response Code:	Website: www.asianjns.org
	DOI: 10.4103/1793-5482.148793

Address for correspondence:

Dr. Thara Tunthanathip, Department of Surgery, Neurosurgical Unit, Faculty of Medicine, Prince of Songkla University, Hat Yai, Songkhla, 90112, Thailand.
E-mail: tsus4@hotmail.com

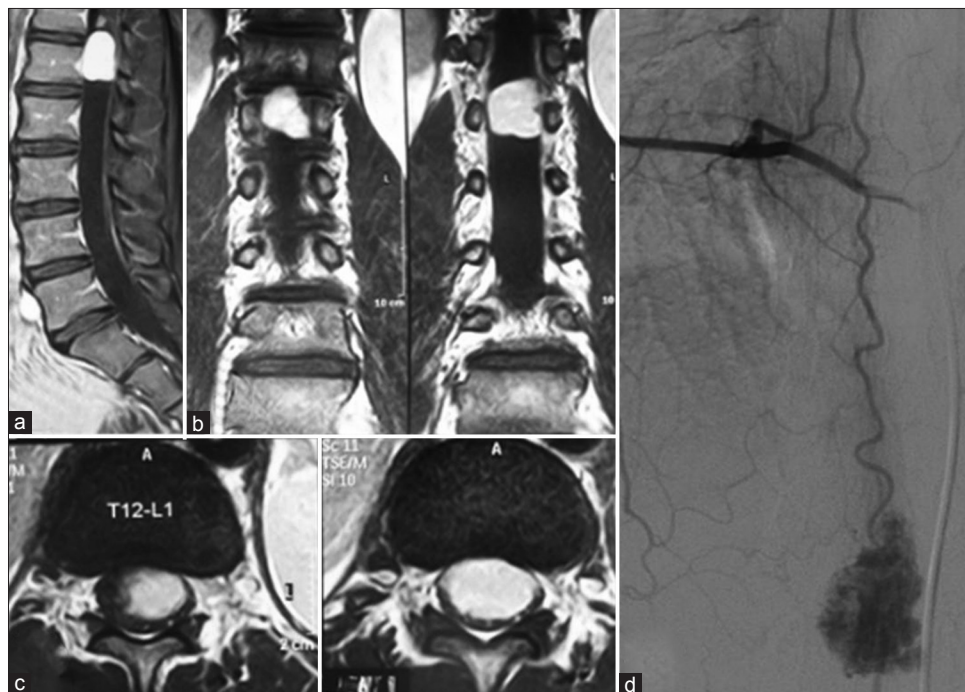


Figure 1: Preoperative imaging from case 1. (a) Sagittal view, (b) Coronal view, (c) Axial view, (d) Preoperative spinal angiogram

Case 2

A 31-year-old man presented with a 1-month history of left hemiparesis, with aspiration pneumonia associated with dysphagia. He had retinal hemangioma in both eyes and a familial history of his first-degree relatives dying from brain tumors. A neurologic examination revealed left hemiparesis and impairment of cerebellar signs on the left side. A computerized tomography (CT) scan of his brain found a cystic lesion at the fourth ventricle. From the pertinent data, the differential diagnosis in this case was cerebellar hemangioblastoma, syringobulbia and an arachnoid cyst. An MRI brain showed syringobulbia with syringohydromyelia at the upper cervical cord, without Chiari malformation, and a CT scan of the whole abdomen showed multiple pancreatic cysts. An MRI of the whole spine that showed multiple innumerable enhanced nodules along cervicothoracic spinal cord with syringobulbia with syringohydromyelia involving almost the entire spinal cord from the T7 level extending superiorly to involving the brainstem. The intramedullary lesion at C5-6 level evidently the cause of syringobulbia with syringohydromyelia [Figure 3].

Following these investigations, our preoperative diagnosis was VHL. A laminectomy of C4-6 was performed. Intradural exploration revealed a reddish tumor, which was subpial tumor at C4. A posterior midline myelotomy was performed at the C5-6 level which found an intramedullary tumor which was removed completely. After the operation, the patient's dysphagia improved. A postoperative MRI of the brain and whole spine revealed decreased syringobulbia and syringohydromyelia. Histological microscopy showed

circumscribed vascular tumor with fibrous connective tissue capsule. The vessels were small, and dilated capillary lined by homogeneous endothelial cell. The vessels separated by fibrous tissue without stromal cell. In this case, a definite diagnosis was considered carefully because the preoperative presentations indicated probable spinal hemangioblastoma with VHL disease. Immunohistochemistry showed positive reactions for the endothelial cell markers. histology and immunohistochemical staining confirmed the diagnosis of capillary hemangioma in this case [Figure 4].

Discussion

Capillary hemangioma is a benign vascular lesion, most often found in the skin and other soft tissues of children. Within the spine, this tumor is commonly found in the vertebral bodies^[1] but only a few cases of intradural capillary hemangioma have been reported [Table 1].^[2-35] The tumor's characteristics are common in males, located at the thoraco-lumbar level, and clustered in the fourth to sixth decades of life [Table 2]. Thus, based on case series of 64 patients, authors propose a classification scheme for the spinal capillary hemangioma classification into five types [Figure 5].

- Pediatric type has the cutaneous hemangioma following to the intradural extramedullary mass via sinus tract and usually form to the intradural extramedullary mass. This type is found in 5%
- Epidural type is extradural mass that usually extend into neural foramen. This type is found 8% and 80% of this type are dumbbell shaped tumors
- Intradural extramedullary type is found in 70% that is the most common type of spinal capillary hemangioma

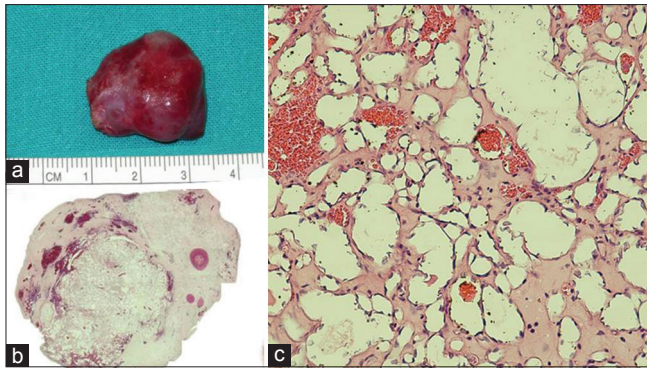


Figure 2: The characteristic histological features were found from case 1. (a) Grossly, the surgical specimen was a lobular, sharp-bordered, reddish mass, (b) The microphotograph shows many well-circumscribed lobules, (c) A high power magnification microphotograph showing the lobules pattern of vessels, separated by a myxoid, occasionally hyalinized stroma. Composed of tightly packed blood-filled, variably dilated, well-formed capillaries lined by endothelial cells (H and E, $\times 400$)

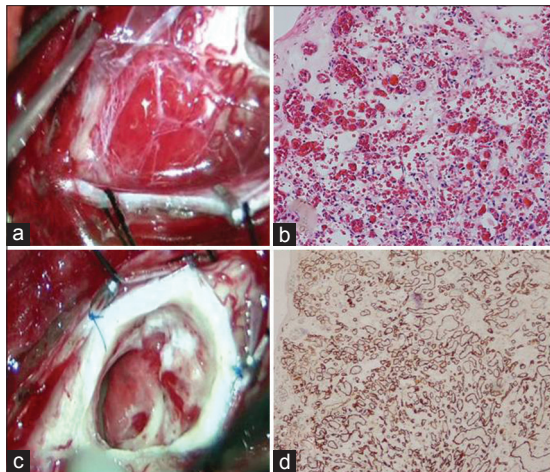


Figure 4: The characteristic histological features were found from case 2. (a) Intraoperative findings showed a reddish subpial hemangioma which derived its blood from the radicular vessels, (b) Intraoperative findings showed a lobular, sharp bordered, reddish intramedullary hemangioma, (c) Histological finding showed the tumor composed of thin and irregular capillary-sized blood vessels separated by connective tissue (H and E $\times 100$), (d) Staining for the endothelial marker CD34 disclosed a strong positivity of endothelial cells, compatible with capillary hemangioma (CD34 $\times 100$)

- Intramedullary type is found in 14%
- Hemangiomatosis is found in 3%. Roncaroli *et al.* defined “hemangiomatosis” since 2000.^[10] This type is disseminated tumor along entire spinal cord including subpial nodules and intramedullary mass.

The pathogenesis of this disease is still poorly understood. Several hypotheses have been proposed many factors starting hemangioma growth. Some of the key angiogenic factors are highly specific for endothelial cells. Basic fibroblast growth factor and vascular endothelial growth factor (VEGF) are proangiogenic molecules and are often produced by tumor

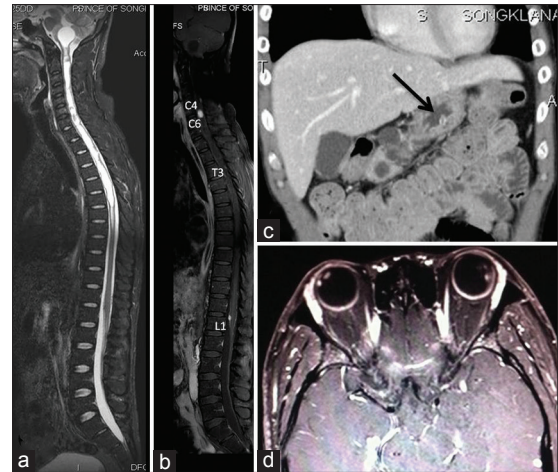


Figure 3: Preoperative imaging from case 2. (a) T2-weighted sagittal magnetic resonance imaging (MRI) images of the whole spine showing extensive syringobulbia with syringohydromyelia, (b) Postcontrast T1-weighted sagittal MRI images of the whole spine showing multiple subpial tumor along cervicothoracic spinal cord and an intramedullary tumor at the C5-6 level, (c) Computerized tomography abdomen revealed multiple pancreatic cysts (arrow), (d) MRI brain showing an enhancing nodules at the both globes

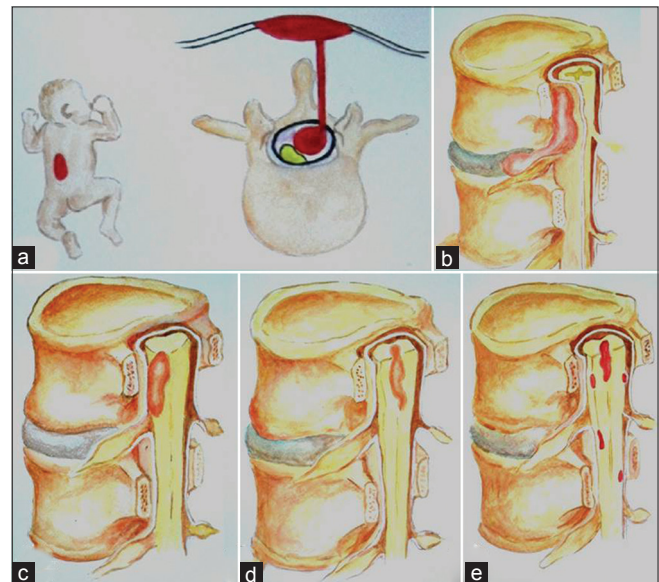


Figure 5: The classification of spinal capillary hemangiomas (a) Pediatric type, (b) Epidural type, (c) Intradural extramedullary type, (d) Intramedullary type, (e) Hemangiomatosis

cells.^[36] Concurrently, VHL disease is an autosomal dominantly inherited neoplastic syndrome which is associated with various vascular tumors and cysts. The most frequent tumors are retinal and central nervous system hemangioblastomas, clear cell renal cell carcinoma, pheochromocytoma, pancreatic islet tumors, and endolymphatic sac tumors. This syndrome associates with mutation of the VHL gene. The Inactivation of the VHL tumor suppressor protein with loss of function of the VHL protein, and Elongin B, C complex high level of

hypoxia-inducible factors causes increased transcription of VEGF, platelet-derived growth factor and transforming growth factor- α which is an important step in the development of highly vascular tumors.^[37] The hypothesis of VHL disease that associated with capillary hemangioma is a high level of VEGF. This signal protein is an angiogenic factor with critical roles in tumor formation disseminated in multiple organs.

The surgical goal should be total complete tumor removal to decrease proangiogenic factors. Surgical standard procedures consists of a posterior midline approach to the spine, a one- or two-level laminectomy or laminectomy in children, and a midline durotomy. In an intramedullary tumor, a

posterior midline myelotomy can avoid a major neurological deficit. This spinal tumor has multiple feeding arteries. The devascularization of the feeding arteries may be required to tumor resection in some situations. Perioperative embolization is an option to avoid massive surgical blood loss, especially in children.^[38,39] After total resection, tumor recurrence has rarely been reported.^[32] However, Abe *et al.* reported no recurrence at 13 years after complete resection.^[19]

Conclusion

We experienced a rare spinal cord tumor with a curious presentation. These lesions pose a challenging diagnostic

Table 1: Review of cases of spinal capillary hemangiomas previously reported in the English literature

Authors/year	Age (year)/sex	Symptoms (n)	Location	Level of involvement	Foraminal extension
Mawk <i>et al.</i> , 1987 ^[2]	7 months/ female	Lower extremity apraxia	Cutaneous hemangioma extended to follow through the fascia, laminar defect at L5 level, the epidural space into the intradural space at conus medullaris	Conus medullaris (L2)	No
Hanakita <i>et al.</i> , 1991 ^[3]	58/male	Back and leg pain with sensory deficit at left L5 and bilateral S1 dermatome	Intradural extramedullary	Cauda equina (L1-L2)	No
Hida <i>et al.</i> , 1993 ^[4]	50/male	Leg weakness, numbness, bladder and bowel dysfunctions	Intramedullary	C3-T1	No
Gupta <i>et al.</i> , 1996 ^[5]	50/male	Back pain, progressive weakness at left lower extremity, burning pain at right lower extremity, loss of proprioception and vibrator sensation	Epidural	T8-10	No
Mastronardi <i>et al.</i> , 1997 ^[6]	41/male	Low back and leg pain	Intradural extramedullary	L5	No
Zander <i>et al.</i> , 1998 ^[7]	51/female	Back and leg pain	Intradural extramedullary	L4-L5	No
Holtzman <i>et al.</i> , 1999 ^[8]	56/female	Back and leg pain	Intradural extramedullary	Cauda equina (L4)	No
Roncaroli <i>et al.</i> , 1999* ^[9]	40-62 Male (6) and female (4)	Leg pain (7) leg weakness (6) bowel and bladder symptoms (1), SLRT (3), paresthesia (2), hyperreflexia (2)	Intradural extramedullary	Cauda equina (8), T5 (1), T1 nerve root (1)	No
Nowak <i>et al.</i> , 2000 ^[10]	63/female	Back pain	Intradural extramedullary	T12-L1	No
Roncaroli <i>et al.</i> , 2000 ^[11]	74/male	Weakness of both legs	Multiple enhancing lesion at pial surface of lower thoracic spinal cord and conus medullaris (innumerable)	Lower thoracic spinal cord and conus medullaris	No
Roncaroli <i>et al.</i> , 2000 ^[12]	42/female	Leg weakness	Intradural extramedullary	T11	No
	50/male	Back pain, leg weakness	Intradural extramedullary	T11	No
	53/male	Leg pain	Intradural extramedullary	Conus medullaris	No
	64/male	Leg pain, leg weakness	Intradural extramedullary	T10	No
Shin <i>et al.</i> , 2000 ^[13]	66/female	Back pain, leg weakness	Intradural extramedullary	T8-T9	No
Choi <i>et al.</i> , 2001 ^[14]	28/male	Back and leg pain	Intradural extramedullary	Cauda equina (L1)	No
	52/male	Leg weakness	Intradural extramedullary	T5-T6	No
	51/male	Leg pain, weakness of both legs	Intradural extramedullary	T4-T5	No
Andaluz <i>et al.</i> , 2002 ^[15]	41/male	Back pain and weakness of both legs	Intradural extramedullary	Conus medullaris	No
Bozkus <i>et al.</i> , 2003 ^[16]	37/female	Bilateral leg numbness (2) and leg weakness (1)	Intradural extramedullary (2)	Thoracic spinal cord	No
	55/male				
Badinand <i>et al.</i> , 2003 ^[17]	40/female	Leg pain, paraparesis, hypoesthesia	Epidural	T2-T4	Yes
Abdullah <i>et al.</i> , 2004 ^[18]	32/female	Paraparesis, progressive lower back pain and pareswthesia	Intradural extramedullary	T10	No

Contd...

Table 1: Contd...

Authors/Year	Age (year)/Sex	Symptoms (n)	Location	Level of involvement	Foraminal extension
Abe <i>et al.</i> , 2004 ^[29]	59/male	Paraparesis, hypesthesia of both legs	Intradural extramedullary	T11	No
	51/male	Paraparesis, hypoesthesia of both legs	Intradural extramedullary	T11	No
	64/male	Paraparesis, hypoesthesia of both legs	Intradural extramedullary	T7	No
	71/male	Paraparesis, hypoesthesia of both legs	Intradural extramedullary	T11	No
	65/male	Weakness of both legs	Intramedullary	T5	No
	80/male	Paraparesis, hypoesthesia of both legs	Intradural extramedullary	T9	No
	43/male	Paraparesis, hypoesthesia of both legs	Intramedullary with extramedullary component	T7	No
Crispino <i>et al.</i> , 2005 ^[20]	65/male	Progressive paraparesis, upper-thoracic back pain	Intradural extramedullary	T1-2 T12-L1	No
Kelleher <i>et al.</i> , 2005 ^[21]	57/male	Progressive thoracic pain, paraparesis	Intramedullary	T9-10	No
Kim <i>et al.</i> , 2006 ^[22]	59/male	Low back pain, leg pain, paresthesia	Intradural extramedullary	Cauda equine (L1-L2)	No
Ghazi <i>et al.</i> , 2006 ^[23]	42/male	Low back pain with sciatica. Increased ICP	Intradural extramedullary	Cauda equine (L3-L4)	No
Kang <i>et al.</i> , 2006 ^[24]	56/male	Right radiating chest wall pain	Epidural	T2-T4	Yes
Karikari <i>et al.</i> , 2007 ^[25]	6 month/female	Lumbar dimple with an overlying raised purple-red hemangioma	Cutaneous hemangioma extended to follow through the fascia, the epidural space into the intradural space at L4 level with a fatty filum terminale	L4	No
	1-month/female	Lumbar cutaneous hemangioma associated with a dermal sinus tract	Cutaneous hemangioma extended to follow through the fascia, the epidural space into the intradural space at L3-L4 level with a fatty filum terminale	L3-L4	No
Ganapathy <i>et al.</i> , 2008 ^[26]	17/male	Low back pain with S1 radiculopathy	Intradural extramedullary	Cauda equina (L2-L3)	No
Miri <i>et al.</i> , 2009 ^[27]	20/male	Low back pain radiating to legs, paraparesis, hyperesthesia, bladder dysfunction and erectile dysfunction	Intradural extramedullary	Cauda equina (L3)	No
Chung <i>et al.</i> , 2010 ^[28]	47/male	Back pain on lower thoracic with leg pain, paresthesia at T7 dermatome and hyperreflexia	Intradural extramedullary	T6-T7	No
Hasan <i>et al.</i> , 2011 ^[29]	57/male	Back pain, right leg motor weakness, numbness of left leg, band of numbness at the level of the umbilicus on the right	Epidural	T10-12	Yes
Vassal <i>et al.</i> , 2011 ^[30]	59/female	Back pain, Rt intercostals neuralgia, motor weakness of lower limbs	Epidural	T5-7	Yes
Sonawane <i>et al.</i> , 2012 ^[31]	35/male	Mid back pain, progressive weakness in both lower limbs	Intradural extramedullary	T12	No
Kaneko <i>et al.</i> , 2012 ^[32]	48/male	Low back pain, motor weakness of lower limbs, loss of proprioception with positive of Romberg's sign	Intradural extramedullary	T10-11	No
Babu <i>et al.</i> , 2013 ^[33]	Mean age 53.5	Pain (3), motor weakness (1), bladder symptoms (1)	Intradural extramedullary (4)	NA	No
Wu <i>et al.</i> , 2013 ^[34]	49/male	Rt lower limb numbness	Intramedullary	T1-2	No
	63/female	Low back pain, bilateral lower limbs numbness, weakness, dysuria	Intramedullary	T11	No
	18/male	Low back pain, bilateral lower limbs weakness, dysuria	Intramedullary	T7-8	No
	47/male	Rt lower limb numbness and weakness	Intramedullary	C7-T1	No
Ganazalez <i>et al.</i> , 2014 ^[35]	59/male	Back pain, bilateral lower limbs numbness and weakness	Intramedullary with extramedullary component	T3-4	No
	59/male	Progressive numbness of both legs and low back pain	Intramedullary with extramedullary component	T7-T8	No

Contd...

Table 1: Contd...

Authors/year	Age (year)/sex	Symptoms (n)	Location	Level of involvement	Foraminal extension
Present cases	15/male	Coccygodynia, leg pain	Intradural extramedullary	Conus medullaris (L1)	No
	31/male	Left hemiparesis, positive cerebellar signs on the left, cranial nerve palsy from syringobulbia, retinal hemangioma with multiple pancreatic cyst (mimicking VHL disease)	Intramedullary Intradural extramedullary (multiple enhancing lesion at pial surface and innumerable)	C5-6 C4, T3 and L1	No

SLRT – Straight leg raising test; ICP – Intracranial pressure; VHL – Von Hippel-Lindau; NA – Not available. *Roncaroli *et al.* reported 10 case including 9 case of capillary type and 1 case of spindle cell hemangioendothelioma, but could not explore in detail each patient

Table 2: Clinical characteristics of spinal capillary hemangiomas

Clinical characteristics	Percentage
Age*	
0-20	14
21-40	14
41-60	57
61-80	15
Sex*	
Male	75
Female	25
Signs and symptoms*	
Paraparesis	57
Back pain	51
Leg pain	24
Sensory deficit	30
Hyperalgesia	20
Bladder symptom	8
Skin stigmata	6
Locations**	
Cervical	4
Thoracic	60
Conus medullaris (T12-L2)	18
Lumbar	18

*Number of patients are 51 Roncaroli *et al.*, 1999 and Babu *et al.*, 2013 were excluded. **Number of lesions are 50 Roncaroli *et al.*, 1999, Babu *et al.*, 2013 and innumeral cases were excluded

problem, because variable types of this tumor can mimic other spinal tumors. For over 25 years, the tumor has been reported since 1987. It's important to concern in the differential diagnosis of spinal cord tumor, and surgical resection is the treatment of choice for a definite diagnosis.

Acknowledgment

The authors thank Kittipong Riabroi, MD and Associate Prof. Dr. Kogkun Tungsinmunkong for assistance.

References

- Pastushyn AI, Slin'ko EI, Mirzoyeva GM. Vertebral hemangiomas: Diagnosis, management, natural history and clinicopathological correlates in 86 patients. *Surg Neurol* 1998;50:535-47.
- Mawk JR, Leibrock LG, McComb RD, Trembath EJ. Metameric capillary hemangioma is producing a complete myelographic block in an infant. Case report. *J Neurosurg* 1987;67:456-9.
- Hanakita J, Suwa H, Nagayasu S, Suzuki H. Capillary hemangioma in the cauda equina: Neuroradiological findings. *Neuroradiology* 1991;33:458-61.
- Hida K, Tada M, Iwasaki Y, Abe H. Intramedullary disseminated capillary hemangioma with localized spinal cord swelling: Case report. *Neurosurgery* 1993;33:1099-101.
- Gupta S, Kumar S, Banerji D, Pandey R, Gujral R. Magnetic resonance imaging features of an epidural spinal haemangioma. *Australas Radiol* 1996;40:342-4.
- Mastronardi L, Guiducci A, Frondizi D, Carletti S, Spera C, Maira G. Intraneural capillary hemangioma of the cauda equina. *Eur Spine J* 1997;6:278-80.
- Zander DR, Lander P, Just N, Albrecht S, Mohr G. Magnetic resonance imaging features of a nerve root capillary hemangioma of the spinal cord: Case report. *Can Assoc Radiol J* 1998;49:398-400.
- Holtzman RN, Brisson PM, Pearl RE, Gruber ML. Lobular capillary hemangioma of the cauda equina. Case report. *J Neurosurg* 1999;90:239-41.
- Roncaroli F, Scheithauer BW, Krauss WE. Hemangioma of spinal nerve root. *J Neurosurg* 1999;91:175-80.
- Nowak DA, Gumprecht H, Stölzle A, Lumenta CB. Intraneural growth of a capillary haemangioma of the cauda equina. *Acta Neurochir (Wien)* 2000;142:463-7; discussion 467.
- Roncaroli F, Scheithauer BW, Deen HG Jr. Multiple hemangiomas (hemangiomatosis) of the cauda equina and spinal cord. Case report. *J Neurosurg* 2000;92:229-32.
- Roncaroli F, Scheithauer BW, Krauss WE. Capillary hemangioma of the spinal cord. Report of four cases. *J Neurosurg* 2000;93:148-51.
- Shin JH, Lee HK, Jeon SR, Park SH. Spinal intradural capillary hemangioma: MR findings. *AJNR Am J Neuroradiol* 2000;21:954-6.
- Choi BY, Chang KH, Choe G, Han MH, Park SW, Yu IK, *et al.* Spinal intradural extramedullary capillary hemangioma: MR imaging findings. *AJNR Am J Neuroradiol* 2001;22:799-802.
- Andaluz N, Balko MG, Stanek J, Morgan C, Schwetschenau PR. Lobular capillary hemangioma of the spinal cord: Case report and review of the literature. *J Neurooncol* 2002;56:261-4.
- Bozkus H, Tanriverdi T, Kizilkiliç O, Türeci E, Oz B, Hanci M. Capillary haemangiomas of the spinal cord: Report of two cases. *Minim Invasive Neurosurg* 2003;46:41-6.
- Badinand B, Morel C, Kopp N, Tran Min VA, Cotton F. Dumbbell-shaped epidural capillary hemangioma. *AJNR Am J Neuroradiol* 2003;24:190-2.
- Abdullah DC, Raghuram K, Phillips CD, Jane JA Jr, Miller B. Thoracic intradural extramedullary capillary hemangioma. *AJNR Am J Neuroradiol* 2004;25:1294-6.
- Abe M, Tabuchi K, Tanaka S, Hodozuka A, Kunishio K, Kubo N, *et al.* Capillary hemangioma of the central nervous system. *J Neurosurg* 2004;101:73-81.
- Crispino M, Vecchioni S, Galli G, Olivetti L. Spinal intradural extramedullary haemangioma: MRI and neurosurgical findings. *Acta Neurochir (Wien)* 2005;147:1195-8.
- Kelleher T, Aquilina K, Keohane C, O'Sullivan MG. Intramedullary

- capillary haemangioma. *Br J Neurosurg* 2005;19:345-8.
22. Kim KJ, Lee JY, Lee SH. Spinal intradural capillary hemangioma. *Surg Neurol* 2006;66:212-4.
 23. Ghazi NG, Jane JA, Lopes MB, Newman SA. Capillary hemangioma of the cauda equina presenting with radiculopathy and papilledema. *J Neuroophthalmol* 2006;26:98-102.
 24. Kang JS, Lillehei KO, Kleinschmidt-Demasters BK. Proximal nerve root capillary hemangioma presenting as a lung mass with bandlike chest pain: Case report and review of literature. *Surg Neurol* 2006;65:584-9.
 25. Karikari IO, Selznick LA, Cummings TJ, George TM. Spinal capillary hemangioma in infants: Report of two cases and review of the literature. *Pediatr Neurosurg* 2007;43:125-9.
 26. Ganapathy S, Kleiner LI, Mirkin LD, Hall L. Intradural capillary hemangioma of the cauda equina. *Pediatr Radiol* 2008;38:1235-8.
 27. Miri SM, Habibi Z, Hashemi M, Meybodi AT, Tabatabai SA. Capillary hemangioma of cauda equina: A case report. *Cases J* 2009;2:80.
 28. Chung SK, Nam TK, Park SW, wang SN. Capillary hemangioma of the thoracic spinal cord. *J Korean Neurosurg Soc* 2010;48:272-5.
 29. Hasan A, Guiot MC, Torres C, Marcoux J. A case of a spinal epidural capillary hemangioma: Case report. *Neurosurgery* 2011;68:E850-3.
 30. Vassal F, Péoc'h M, Nuti C. Epidural capillary hemangioma of the thoracic spine with proximal nerve root involvement and extraforaminal extension. *Acta Neurochir (Wien)* 2011;153:2279-81.
 31. Sonawane DV, Jagtap SA, Mathesul AA. Intradural extramedullary capillary hemangioma of lower thoracic spinal cord. *Indian J Orthop* 2012;46:475-8.
 32. Kaneko Y, Yamabe K, Abe M. Rapid regrowth of a capillary hemangioma of the thoracic spinal cord. *Neurol Med Chir (Tokyo)* 2012;52:665-9.
 33. Babu R, Owens TR, Karikari IO, Moreno J, Cummings TJ, Gottfried ON, *et al.* Spinal cavernous and capillary hemangiomas in adults. *Spine (Phila Pa 1976)* 2013;38:E423-30.
 34. Wu L, Deng X, Yang C, Xu Y. Intramedullary spinal capillary hemangiomas: Clinical features and surgical outcomes: Clinical article. *J Neurosurg Spine* 2013;19:477-84.
 35. Gonzalez R, Spears J, Bharatha A, Munoz DG. Spinal lobular capillary hemangioma with an intramedullary component. *Clin Neuropathol* 2014;33:38-41.
 36. Hamlat A, Adn M, Pasqualini E, Brassier G, Askar B. Pathophysiology of capillary haemangioma growth after birth. *Med Hypotheses* 2005;64:1093-6.
 37. Shuin T, Yamasaki I, Tamura K, Okuda H, Furihata M, Ashida S. Von Hippel-Lindau disease: Molecular pathological basis, clinical criteria, genetic testing, clinical features of tumors and treatment. *Jpn J Clin Oncol* 2006;36:337-43.
 38. Berkefeld J, Scale D, Kirchner J, Heinrich T, Kollath J. Hypervascular spinal tumors: Influence of the embolization technique on perioperative hemorrhage. *AJNR Am J Neuroradiol* 1999;20:757-63.
 39. Manke C, Bretschneider T, Lenhart M, Strotzer M, Neumann C, Gmeinwieser J, *et al.* Spinal metastases from renal cell carcinoma: Effect of preoperative particle embolization on intraoperative blood loss. *AJNR Am J Neuroradiol* 2001;22:997-1003.

How to cite this article: Tunthanathip T, Rattanalert S, Oearsakul T, Kanjanapradit K. Spinal capillary hemangiomas: Two cases reports and review of the literature. *Asian J Neurosurg* 2017;12:556-62.

Source of Support: Nil, **Conflict of Interest:** None declared.