

Minimally Invasive Redo Mitral Valve Replacement under Fibrillatory Arrest in a Patient with a Calcified Aorta and Patent Previous Bypass Grafts

Seung Hyun Kim, M.D., Hak Ju Kim, M.D., Ho Young Hwang, M.D., Ph.D.

*Department of Thoracic and Cardiovascular Surgery, Seoul National University Hospital,
Seoul National University College of Medicine*

A 73-year-old woman who underwent combined bioprosthetic mitral valve replacement, tricuspid ring annuloplasty, and coronary artery bypass grafting 12 years previously visited our clinic due to aggravated dyspnea caused by structural valve deterioration of the mitral prosthesis. Because aortic or femoral artery cannulation and cross-clamping would have a high risk of stroke owing to severe calcification of the ascending aorta and ilio-femoral vessels, and because there was a risk of redo sternotomy due to the patent bypass grafts, a comprehensive approach including axillary artery cannulation, a minimally invasive right thoracotomy approach, and a clampless hypothermic fibrillatory arrest technique was used during redo mitral valve replacement.

Key words: 1. Minimally invasive surgical procedures
2. Mitral valve, replacement
3. Aortic cross-clamping
4. Reoperation
5. Stroke

Case report

A 73-year-old woman was referred to outpatient clinic of Seoul National University Hospital for aggravated dyspnea. The patient had undergone combined cardiac surgery 12 years earlier at another hospital; that operation included coronary artery bypass grafting with in situ left internal thoracic artery (LITA), aorto-coronary saphenous vein (SV), and radial artery grafts (LITA to the left anterior descending coronary artery, SV to the diagonal branch, radial to the left circumflex artery, and SV to the posterior descending coronary artery), bioprosthetic mitral valve

replacement (MVR), and tricuspid annuloplasty with a prosthetic ring. Her comorbidities included diabetes mellitus and acute renal failure, with a creatinine level of 4.09 mg/dL in the setting of pre-existing stage II chronic kidney disease, which may have been due to cardiorenal syndrome. Transthoracic echocardiography demonstrated structural valve deterioration of the mitral bioprosthesis with severe steno-insufficiency, mild to moderate tricuspid regurgitation, and resting pulmonary hypertension with a systolic pulmonary artery pressure of 78 mm Hg. Although coronary angiography showed an occluded SV graft anastomosed to the posterior descending coronary

[†]This paper was presented at the 296th Monthly Case Conference of Seoul-Kyeongki District Chamber of The Korean Society for Thoracic and Cardiovascular Surgery.

Received: March 28, 2018, Revised: April 29, 2018, Accepted: May 2, 2018, Published online: August 5, 2018

Corresponding author: Ho Young Hwang, Department of Thoracic and Cardiovascular Surgery, Seoul National University Hospital, Seoul National University College of Medicine, 101 Daehak-ro, Jongno-gu, Seoul 03080, Korea (Tel) 82-2-2072-3020 (Fax) 82-2-764-3664 (E-mail) scalpel@hanmail.net

© The Korean Society for Thoracic and Cardiovascular Surgery. 2018. All right reserved.

© This is an open access article distributed under the terms of the Creative Commons Attribution Non-Commercial License (<http://creativecommons.org/licenses/by-nc/4.0>) which permits unrestricted non-commercial use, distribution, and reproduction in any medium, provided the original work is properly cited.

artery, this finding had already been demonstrated 8 years before, and no other signs of disease progression were shown in the other bypass grafts or native coronary artery. Computed tomographic angiography demonstrated a heavily calcified ascending aorta. The abdominal aorta and both ilio-femoral vessels were also diffusely calcified, with multiple atheromatous plaques (Fig. 1). A redo MVR via a right mini-thoracotomy under fibrillating arrest without aortic cross-clamping (ACC) was planned for this patient.

A 10-cm right submammary incision was made and the fourth intercostal space was entered. Cardiopulmonary bypass (CPB) was initiated through the right axillary artery (using an 8-mm vascular graft) and percutaneous right internal jugular (21F) and femoral vein (23F) cannulations. CO₂ insufflation into the thoracic cavity was initiated using a 10F silicon tube with multiple sideholes, and it was maintained while the left heart was opened. Pericardial opening and intrapericardial adhesiolysis were limited to the area around the interatrial groove (Fig. 2A). A left atriotomy was made following ventricular fibrillatory arrest under moderate hypothermia (30°C), and the deteriorated valve was removed (Fig. 2B). Another type of bioprosthesis was implanted using multiple-pledgetted mattress sutures. Intracardiac suction was controlled throughout the procedure in order to avoid emptying the left ventricle and creating an air embolism. When all procedures were completed, a vent cannula was inserted between the leaflets of the new prosthetic valve in order to keep the valve open. Before completely closing the left atriotomy, the patient's position was changed to left-side down and reverse Trendelenburg so that any air compacted in the left ventricular apex could be removed through

the left atrium. The patient was smoothly weaned from cardiopulmonary artery bypass without any abnormal findings on brain oximetry or electrocardiographic monitoring. The total CPB time was 228 minutes, and the fibrillatory arrest time was 170 minutes.

The patient recovered well without stroke or respiratory complications; she was extubated on the first postoperative day, and the total chest tube drainage during the 3 days before removal was 150 mL. Transthoracic echocardiography on the third postoperative day showed a well-functioning bioprosthesis mitral valve, without any paravalvular

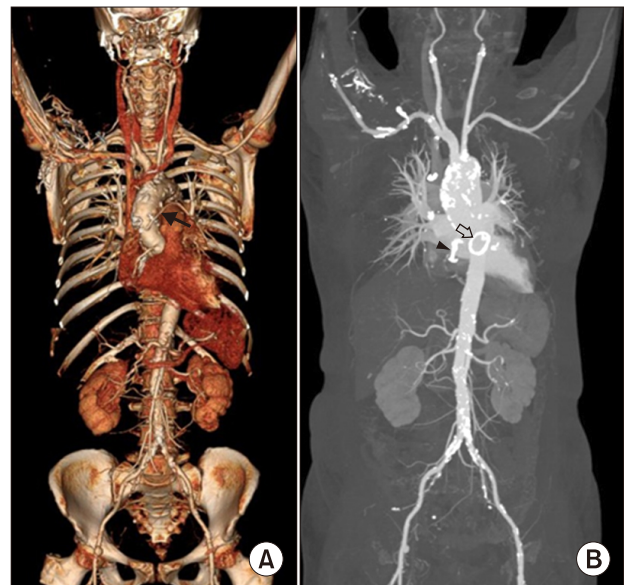


Fig. 1. (A, B) Preoperative computed tomography demonstrating diffuse and heavy calcification of the ascending aorta, abdominal aorta, and ilio-femoral vessels (black arrow, patent aorto-coronary graft; black arrowhead, tricuspid annular ring; empty arrow, bioprosthesis mitral valve).

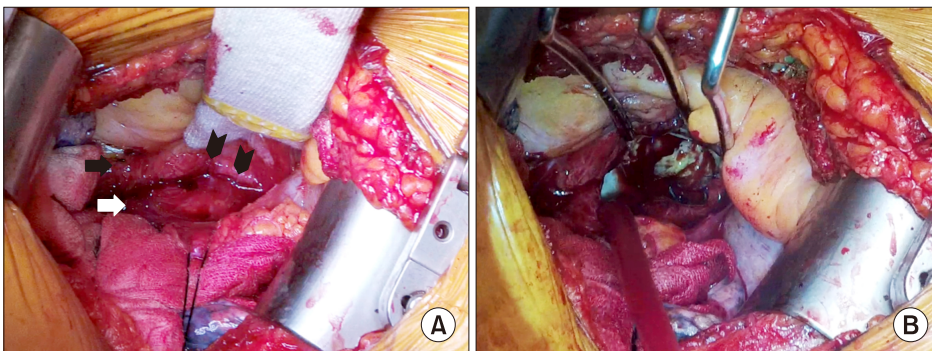


Fig. 2. (A) The interatrial groove was exposed with minimal intrapericardial dissection via a right mini-thoracotomy (black arrow, right atrium; white arrow, left atrial wall; black arrowhead, previous suture for left atrial closure), and (B) the left atrium was entered under ventricular fibrillatory arrest and the deteriorated bioprosthesis was seen.

leakage and with mild tricuspid valve regurgitation. Although her discharge was delayed due to uncontrolled hyperglycemic and hypoglycemic events, she was discharged on the 14th postoperative day.

Discussion

Although the outcomes of reoperative cardiac surgery have improved, reoperative mitral valve surgery still poses a higher risk of mortality and postoperative complications, such as stroke, prolonged ventilation, and reoperation for bleeding, than first-time mitral valve surgery [1].

Previous studies have demonstrated that a minimally invasive approach via a right thoracotomy is safe and effective compared to the conventional median sternotomy approach, even in reoperative patients [2]. For patients who undergo a mitral valve reoperation, the minimally invasive thoracotomy approach has several theoretical advantages, such as (1) avoiding the risk of redo sternotomy, (2) requiring minimal intrapericardial dissection, and (3) providing good exposure of the mitral valve [2].

The present case had several risk factors for redo MVR. First, there was a high risk of stroke due to the heavily calcified ascending aorta, which prohibited us from performing routine ascending aortic cannulation and ACC. Second, the patent bypass grafts increased the risk of reoperation due to the possibility of injury during reentry and during exposure of the internal thoracic artery grafts, which should be clamped during cardioplegic arrest. Third, the patient had diffuse atherosclerosis with heavy calcification of the abdominal aorta and ilio-femoral vessels, potentially increasing the risk of retrograde perfusion via the femoral artery.

Due to these concerns, clampless surgery under ventricular fibrillatory arrest was planned. In addition, to avoid the risks of redo sternotomy and intrapericardial adhesiolysis of the whole heart, a right thoracotomy approach was performed, in which only minimal intrapericardial dissection around the in-

teratrial groove was needed. Finally, right axillary arterial cannulation was performed to prevent embolic stroke from femoral artery perfusion [3].

Although we performed redo MVR under fibrillatory arrest to prevent stroke from occurring as a complication and to avoid risk related to exposure of the previous bypass grafts, surgery under fibrillatory arrest itself has been reported to pose an increased risk of stroke [4]. To avoid this, CO₂ was continuously insufflated into the chest cavity until the left atrium was completely closed, and intracardiac suction was carefully performed. With this comprehensive approach, the patient recovered well without any cerebrovascular complications.

In conclusion, a minimally invasive approach with a clampless technique combined with right axillary cannulation might be a viable option for patients who need valve surgery, have a porcelain ascending aorta, and are at risk of embolic stroke from retrograde femoral perfusion.

Conflict of interest

No potential conflict of interest relevant to this article was reported.

References

1. Mehaffey HJ, Hawkins RB, Schubert S, et al. *Contemporary outcomes in reoperative mitral valve surgery*. Heart 2018;104:652-6.
2. Vallabhajosyula P, Wallen T, Pulsipher A, et al. *Minimally invasive port access approach for reoperations on the mitral valve*. Ann Thorac Surg 2015;100:68-73.
3. Croke GA, Schwartz CF, Ribakove GH, et al. *Retrograde arterial perfusion, not incision location, significantly increases the risk of stroke in reoperative mitral valve procedures*. Ann Thorac Surg 2010;89:723-9.
4. Gammie JS, Zhao Y, Peterson ED, O'Brien SM, Rankin JS, Griffith BP. *J. Maxwell Chamberlain Memorial Paper for adult cardiac surgery: less-invasive mitral valve operations: trends and outcomes from the Society of Thoracic Surgeons Adult Cardiac Surgery Database*. Ann Thorac Surg 2010;90:1401-10.