

## Case Report

## Ambiguity in the Dural Tail Sign on MRI

Ramesh S. Doddamani, Rajesh K. Meena, Dattaraj Sawarkar

Department of Neurosurgery, All India Institute of Medical Sciences, New Delhi, India

E-mail: \*Ramesh S. Doddamani - drsdramesh@gmail.com; Rajesh K. Meena - drrajeshmeena165@gmail.com; Dattaraj Sawarkar - dattaraja@gmail.com

\*Corresponding author

Received: 02 September 17 Accepted: 30 January 18 Published: 19 March 18

**Abstract**

**Background:** Meningiomas give rise to the dural tail sign (DTS) on contrast-enhanced magnetic resonance imaging (CEMRI). The presence of DTS does not always qualify for a meningioma, as it is seen in only 60-72% of cases. This sign has been described in various other lesions like lymphomas, metastasis, hemangiopericytomas, schwannomas and very rarely glioblastoma multiforme (GBM). The characteristics of dural-based GBMs are discussed here, as only eleven such cases are reported in the literature till date. Here we discuss the unique features of this rare presentation.

**Case Description:** A 17-year-old male presented to the emergency department (ED) with, complaints of headache, recurrent vomiting, vision loss in right eye and altered sensorium. On examination patient was drowsy with right hemiparesis, secondary optic atrophy in the right eye and papilledema in the left eye. MRI brain showed, heterogeneous predominantly solid cystic lesion with central hypo-intense core suggestive of necrosis with heterogeneous enhancement and a positive DTS. Patient underwent emergency left parasagittal parieto-occipital craniotomy and gross total tumor excision including the involved dura and the falx. On opening the dura, tumor was surfacing, invading the superior sagittal sinus and the falx, greyish, soft to firm in consistency with central necrosis and highly vascular suggesting a high-grade lesion. Postoperative computed tomography (CT) of the brain showed evidence of gross total tumor (GTR) excision. The postoperative course of the patient was uneventful. Histopathological analysis revealed GBM with PNET like components. The dura as well as the falx were involved by the tumor.

**Conclusion:** GBMs can arise in typical locations along with DTS mimicking meningiomas. Excision of the involved dura and the falx becomes important in this scenario, so as to achieve GTR. Hence high index of suspicion preoperatively aided by Magnetic Resonance Imaging (MRS) can help distinguish GBMs from meningioma, thereby impacting upon the prognosis.

**Key Words:** Dural tail sign, glioblastoma multiforme, meningioma, posterior third parasagittal

**Access this article online****Website:**[www.surgicalneurologyint.com](http://www.surgicalneurologyint.com)**DOI:**

10.4103/sni.sni\_328\_17

**Quick Response Code:**

This is an open access journal, and articles are distributed under the terms of the Creative Commons Attribution-NonCommercial-ShareAlike 4.0 License, which allows others to remix, tweak, and build upon the work non-commercially, as long as appropriate credit is given and the new creations are licensed under the identical terms.

For reprints contact: [reprints@medknow.com](mailto:reprints@medknow.com)

**How to cite this article:** Doddamani RS, Meena RK, Sawarkar D. Ambiguity in the Dural Tail Sign on MRI. Surg Neurol Int 2018;9:62.  
<http://surgicalneurologyint.com/Ambiguity-in-the-Dural-Tail-Sign-on-MRI/>

## INTRODUCTION

Dural tail sign (DTS) is considered the hallmark for the radiological diagnosis of a meningioma. It is seen in 60–72% cases of meningiomas and would represent either direct tumor invasion or reactive changes surrounding the tumor itself.<sup>[1,2,4,6,10-12]</sup> Dural tail has been reported in the literature in nonmeningiomas pathologies such as lymphomas/chloromas, dural-based metastasis, hemangiopericytomas, schwannoma, chordomas, pleomorphic xantho-astrocytomas, and very rarely glioblastoma multiforme (GBM).<sup>[3]</sup> Literature regarding GBMs presenting with dural tail mimicking meningiomas is sparse. Here, we report a rare case of GBM with dural tail mimicking a posterior one-third parasagittal meningioma and review the relevant literature.

## CASE REPORT

A 17-year-old male with no comorbidities presented to the emergency department (ED) with complaints of headache and recurrent vomiting for 2 weeks, vision loss in right eye for 1 week, and altered sensorium for 2 days. On examination, the patient was drowsy but arousable, right hemiparesis grade 4/5, right-sided secondary optic atrophy, and left-sided papilledema (pseudofoster Kennedy syndrome). Magnetic resonance imaging (MRI) of the brain showed, T1-weighted images heterogeneous predominantly solid (iso-intense) cystic with central hypo-intense core suggestive of necrosis [Figure 1]. T2-weighted images showed, solid (iso-intense) cystic (hyper-intense) with hyper-intense central core suggestive

of necrosis [Figure 1]. On contrast administration, the lesion demonstrated heterogeneous enhancement with central necrosis with a positive DTS [Figure 2].

Patient was taken up for emergency surgery, and left parasagittal parieto-occipital craniotomy fashioned and gross total tumor excision was done. On opening the dura, tumor was seen surfacing and invading the superior sagittal sinus as well as the falx, with infiltration into the adjacent brain parenchyma. Tumor was greyish soft to firm in consistency with central necrosis and highly vascular suggestive of a high-grade lesion. Per-operatively patient had a transient episode of hypotension, which was managed. Approximate blood loss was 2 liters. Postoperative computed tomography scans showed complete tumor removal [Figure 3]. Postoperative recovery was uneventful and patient was discharged in a stable condition. Final biopsy revealed GBM with primitive neuro-ectodermal (PNET) like components.

## DISCUSSION

The presence of dural tail sign on MRI is highly suggestive of a meningioma but not a pathognomonic sign. The presence of a dural tail in GBM is very rare, and a thorough review of English literature revealed 10 cases of GBM exhibiting DTS mimicking meningioma. The demographic and clinical data are listed in Table 1. All except 2 patients including the index case were elderly, suggesting its common occurrence in that age group. Meningiomas are extra-axial tumors, arising from arachnoid cap cells and parasitize on the dural blood supply with subsequent invasion. Approximately 60–72%

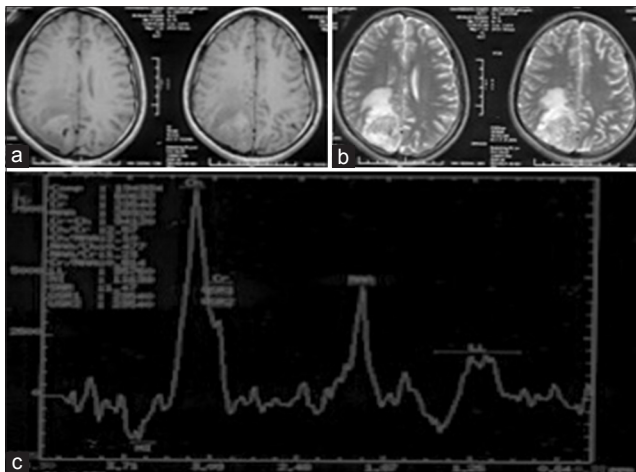
**Table 1: Demographic and clinical features of all the cases reported in literature**

Authors, year <sup>[ref.]</sup>	Age/sex	Signs/symptoms	Treatment	Follow-up
Wilms <i>et al.</i> 1991 <sup>[11]</sup>	NA	NA	NA	NA
	NA	NA	NA	NA
	NA	NA	NA	NA
	NA	NA	NA	NA
	NA	NA	NA	NA
Gupta <i>et al.</i> 1993 <sup>[4]</sup>	48/M	Seizures Left hemiparesis Left 7 <sup>th</sup> palsy	NA	NA
Hsieh <i>et al.</i> 2009 <sup>[5]</sup>	85/F	Memory disturbances Agnosia	Concurrent WBRT + TMZ	Died at 3 months of septic shock following aspiration
Wu <i>et al.</i> 2011 <sup>[12]</sup>	60/M	Left 5 <sup>th</sup> , 7 <sup>th</sup> , 8 <sup>th</sup> and lower cranial nerves involvement, gait disturbance, and cachexia	Patient refused further treatment	Died after 2 months due to severe cachexia
Kayaci <i>et al.</i> 2014 <sup>[6]</sup>	19/M	Headache and seizure	Not mentioned	Not mentioned
Patel <i>et al.</i> 2016 <sup>[8]</sup>	57/M	Headache, ataxia, and memory disturbances	Undergoing concurrent WBRT and TMZ therapy	Alive
	60/M	Right-sided weakness	Concurrent WBRT and TMZ + Bevacizumab	Died at 28 months of initial diagnosis
Present	17/M	Headache and visual problems with right optic atrophy and left papilledema	Undergoing concurrent WBRT and TMZ therapy	Alive at 3 months

TMZ: Temozolomide, WBRT: Whole brain radiotherapy

of meningiomas show classical DTS.<sup>[2]</sup> Controversy exists regarding the nature of the dura showing the tail sign, with majority of the published studies claiming it to be reactive changes, whereas few studies have shown it to be due to actual tumoral involvement.<sup>[1,2,4,6,10-12]</sup> GBMs are intra-axial lesions exhibiting ring-like contrast enhancement with areas of central necrosis and gross perilesional edema. GBMs presenting as extra-axial mass and DTS is unusual, thereby leading to a diagnostic dilemma in the preoperative period. The criteria for the diagnosis of dural tail was given by Aoki *et al.*<sup>[1]</sup> which included:

- Linear enhancement was present along the duramater originating from and extending outward from the tumor margin
- Enhancement was greater than elsewhere along the dura



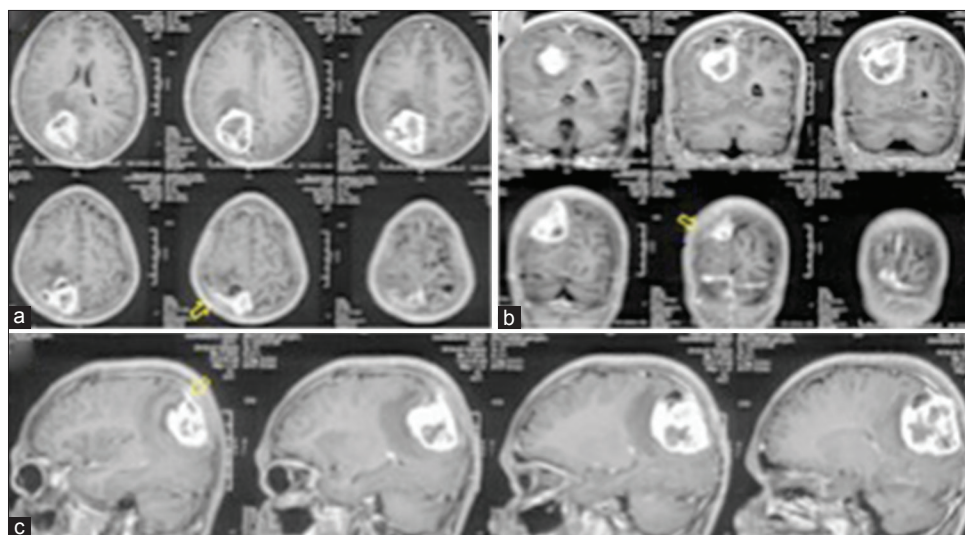
**Figure 1: MRI brain. (a) T1-weighted images: Posterior one-third iso-to-hypointense lesion abutting the falx and the convexity dura. (b) T2-weighted images: iso-to-hyperintense lesion with perilesional edema. (c) MRS showing choline and lipid lactate peak**

- Findings were present in the two different imaging planes
- There was agreement among three observers.

All the criteria were fulfilled in our case, thereby confirming DTS leading to the provisional diagnosis of a meningioma.

Wilms *et al.*<sup>[11]</sup> first reported the significance of the DTS in GBMs through histopathological confirmation of the involved dura. None of the five patients with the final biopsy of GBM reported in their series showed invasion of the dural tail by the tumor. Hence, they concluded that the dural tail to be just a reactive change rather than actual infiltration of the tumor. Ten cases of GBMs with a DTS have been reported in the literature till date, except Wilms *et al.*<sup>[11]</sup> none of the other reports included dural biopsy. In the index case reported here, we have histological confirmation of the involvement of both the falx and the dura by the tumor beyond attachment. There were lytic changes on the inner table of the overlying bone, which were drilled away.

Unlike meningiomas, GBMs are highly vascular and aggressive lesions invading normal brain, deriving their blood supply from pial vasculature. The vessels of duramater rarely feed GBMs, the enhanced dural tail sign is likely to develop from vascular congestion or proliferation.<sup>[3]</sup> On the other hand, meningiomas derive their blood supply from dural vessels, mostly external carotid circulation (ECA) with few exceptions. Patel *et al.*<sup>[8]</sup> demonstrated tumor blush and ECA supply in both their cases on angiography, and thereby misleading the preoperative diagnosis as meningioma. They subjected both the patients for angio-embolization followed by surgery. Blood loss was less than 500 ml in both their cases. Similarly, in one of the cases reported by



**Figure 2: Contrast-enhanced MRI in all three planes. (a) Axial images exhibiting heterogeneous enhancement with DTS (open arrow). (b) Coronal images: parasagittal location with DTS (open arrow). (c) Sagittal images demonstrating DTS (open arrow)**

**Table 2: Imaging, operative, and pathological findings of all the cases reported in the literature**

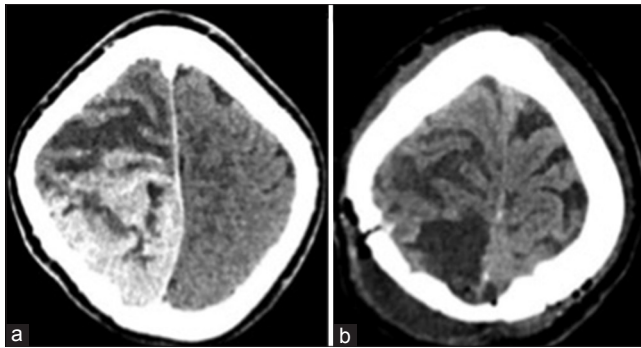
Authors/year <sup>[ref.]</sup>	CT	MRI	Angiogram	Operative findings	Biopsy
Wilms <i>et al.</i> 1991 <sup>[11]</sup>	Not specified	DTS +	Not done	Normal dura and LM	GBM, no dural involvement
	Not specified	DTS +	Not done	Normal dura and LM	GBM, no dural involvement
	Not specified	DTS +	Not done	Normal dura but with extensive LM involvement	GBM, no dural involvement
	Not specified	DTS +	Not done	Abutting dura but with extensive LM involvement	GBM, no dural involvement
	Not specified	DTS +	ECA supply from MMA	Abutting dura but with extensive LM involvement	GBM, no dural involvement
Gupta <i>et al.</i> 1993 <sup>[4]</sup>	Not specified	T1W: HE↓ T2W: ↑ Gad: HE++ DTS +	Not done	Large intra-axial mass coming up to brain surface without dural attachment, with areas of necrosis.	Gr III Astrocytoma, dural specimen not sent
Hsieh <i>et al.</i> 2009 <sup>[5]</sup>	Left. temporal High density Hypodense core (necrosis)	T1W: HE↑ T2W: HE ↑, cleft sign+, Gad: HE++ MRS- lipid/lactate peak + DTS +	Not done	Dura external surface - normal Inner surface - invaded Hypervascularity present	GBM, dural involvement not specified
Wu <i>et al.</i> 2011 <sup>[12]</sup>	Left CPA predominantly hyper-dense lesion with mixed density Extending and enlarging IAC	T1W - ↓ T2W - ↑± Gad-HE++ DTS +	Not done	Grey white gelatinous moderate vascular lesion, adherent to petrous dura, invading proximal 7 <sup>th</sup> -8 <sup>th</sup> nerves	GBM, dural specimen not sent
Kayaci <i>et al.</i> 2014 <sup>[6]</sup>	Not specified	Mid 1/3 <sup>rd</sup> falx T1W - ↑ T2W - ↑± Gad- HE++	Not done	Tumor adherent to falx and sagittal sinus which was coagulated, subtotal excision done.	GBM MIB-10%
Patel <i>et al.</i> 2016 <sup>[8]</sup>	Not specified	Right Temporo-parietal mass with broad contact along rt. tentorium DTS+ CSF cleft sign +	Petrosquamous branch of the right middle meningeal artery (MMA) and Right Occipital artery	Necrotic tumor, status of dura not mentioned	GBM
	Not specified	Heterogeneous-enhancing left parasagittal, mass abutting the falx. DTS +	Left MMA supply	Necrotic tumor, status of dura not mentioned	GBM
Present	Hyper-dense lesion, predominantly solid with cystic components in Right Posterior 1/3 <sup>rd</sup> parasagittal location	T1W - HE predominantly solid (isointense) cystic with central hypointense core. T2W - solid (isointense) cystic (hyperintense) with hyperintense central core s/o necrosis. Gad - HE++ with central necrosis, DTS+MRS- choline and lipid lactate peaks +	Not done	Inner table of the overlying bone lytic changes, overlying dura hypervascular, Grayish tumor with areas of necrosis invading the inner surface of dura and the sinodural angle and SSS, along with proximal falx. Highly vascular	GBM with PNET like components MIB1 - 50-55% Dura and falx involved by tumor

CPA: Cerebellopontine angle, DTS: Dural tail sign, Gad: Gadolinium, GBM: Glioblastoma multiforme, LM: Leptomeninges, SSS: Superior sagittal Ssinus

Wilms *et al.*<sup>[11]</sup> angiogram was performed demonstrating feeders from middle meningeal artery (MMA) similar to meningiomas [Table 2]. Angiogram was not performed in our case in view of the emergency setting, but the tumor had parasitized the falx and the convexity dura for its nutrition, as noted during the surgery. The massive blood loss encountered during the surgery would have been reduced, by prior angio-embolization, as was the case with Patel *et al.*,<sup>[8]</sup> but for the emergency situation.

Magnetic resonance spectroscopy (MRS) is a useful adjunct in differentiating preoperatively meningiomas from GBMs. Majos *et al.*<sup>[7]</sup> studied the role of proton MRS in differentiating various tumors and found large lipid/lactate resonance to be characteristic of GBMs and large alanine peaks to be characteristically seen in meningiomas. Heish *et al.*<sup>[5]</sup> reported a case of GBM mimicking meningioma with the classical dural tail, where MRS revealed characteristic lipid/lactate peak strongly





**Figure 3: CT brain. (a) Preoperative contrast CT brain showing heterogeneously enhancing parasagittal lesion. (b) Postoperative plain CT brain showing gross total tumor excision**

suggesting GBM, which was subsequently confirmed on histopathology.

The origin of extra-axial GBMs has been a matter of debate. Various authors have proposed two mechanisms by which these lesions develop. One hypothesis involving GBM of the cranial nerves (CN) states that, GBM arise primarily from the CNS tissue that lay within the proximal parts of the CN itself. CNS tissue may extend well into the CN, and isolated islands of CNS tissue may even be found within the CN at a considerable distance from its exit point. The second hypothesis is that the tumor originated as primary in the heterotopic neuroglial cell nests in the leptomeninges of the adjacent brain.<sup>[9]</sup> In the index case, considering the dural and falx invasion can be possibly explained by the second hypothesis.

## CONCLUSION

Lesions arising in typical locations for meningiomas but with atypical appearances, GBM should be considered in the differential diagnosis. MRS is a very valuable method of differentiating GBMs from meningiomas. Preoperative angiography appears to have a role in reducing the blood loss although not performed in the present case. High index of suspicion prior to surgery and excision of the involved dural elements would lead to a better outcome.

## Declaration of patient consent

The authors certify that they have obtained all appropriate patient consent forms. In the form the patient(s) has/have given his/her/their consent for his/her/their images and other clinical information to be reported in the journal. The patients understand that their names and initials will not be published and due efforts will be made to conceal their identity, but anonymity cannot be guaranteed.

## Financial support and sponsorship

Nil.

## Conflicts of interest

There are no conflicts of interest.

## REFERENCES

1. Aoki S, Sasaki Y, Machida T, Tanioka H. Contrast-enhanced MR images in patients with meningioma: Importance of enhancement of the dura adjacent to the tumor. *AJNR Am J Neuroradiol* 1990;11:935-8.
2. Goldsher D, Litt AW, Pinto RS, Bannon KR, Kricheff II. Dural "tail" associated with meningiomas on Gd-DTPA-enhanced MR images: Characteristics, differential diagnostic value, and possible implications for treatment. *Radiology* 1990;176:447-50.
3. Guermazi A, Lafitte F, Miaux Y, Adem C, Bonneville JF, Chiras J. The dural tail sign beyond meningioma. *Clin Radiol* 2005;60:171-88.
4. Gupta S, Gupta RK, Banerjee D, Gujral RB. Problems with the "dural tail" sign. *Neuroradiology* 1993;35:541-2.
5. Hsieh CT, Liu MY, Tang CT, Sun JM, Tsai WC, Hsia CC. Problem of dural tail sign in glioblastoma multiforme? *Acta Neurol Belg* 2009;109:310-3.
6. Kayaci S, Şengöz A, Köksal V, Gunver F, Kiliç K. Glioblastoma multiforme mimicking falx meningioma with achondroplasia. *Neurosurgery Quarterly* 2014;24:53-5.
7. Majos C, Alonso J, Aguilera C, Serrallonga M, Perez- Martin J, et al. Proton magnetic resonance spectroscopy ((1) H MRS) of human brain tumours: Assessment of differences between tumour types and its applicability in brain tumour categorization. *Eur Radiol* 2003;13:582-91.
8. Patel M, Nguyen HS, Doan N, Gelsomino M, Shabani S, Mueller W. Glioblastoma Mimicking Meningioma: Report of 2 Cases. *World Neurosurg* 2016;95:624.e9-624.e13.
9. Reifenberger G, Boström J, Bettag M, Bock WJ, Wechsler W, Kepes J. Primary glioblastoma multiforme of the oculomotor nerve. Case report. *J Neurosurg* 1996;84:1062-6.
10. Tokumaru A, O'uchi T, Eguchi T, Kawamoti S, Kokubo T, Suzuki M, et al. Prominent meningeal enhancement adjacent to meningioma on Gd-DTPA-enhanced MR images: Histopathologic correlation. *Radiology* 1990;175:431-3.
11. Wilms G, Lammens M, Marchal G, Van Calenbergh F, Plets C, Van Fraeyenhoven L, et al. Thickening of dura surrounding meningiomas: MR features. *J Comput Assist Tomogr* 1989;13:763-8.
12. Wu B, Liu W, Zhu H, Feng H, Liu J. Primary glioblastoma of the cerebellopontine angle in adults. *J Neurosurg* 2011;114:1288-93.