



Since January 2020 Elsevier has created a COVID-19 resource centre with free information in English and Mandarin on the novel coronavirus COVID-19. The COVID-19 resource centre is hosted on Elsevier Connect, the company's public news and information website.

Elsevier hereby grants permission to make all its COVID-19-related research that is available on the COVID-19 resource centre - including this research content - immediately available in PubMed Central and other publicly funded repositories, such as the WHO COVID database with rights for unrestricted research re-use and analyses in any form or by any means with acknowledgement of the original source. These permissions are granted for free by Elsevier for as long as the COVID-19 resource centre remains active.

# Emerging Concepts in Gastrointestinal Aspects of HIV-1 Pathogenesis and Management

EDWARD N. JANOFF\* and PHILLIP D. SMITH†

\*Mucosal and Vaccine Research Center, Infectious Disease Section, Department of Medicine, Veterans Affairs Medical Center and University of Minnesota School of Medicine, Minneapolis, Minnesota; and †Division of Gastroenterology and Hepatology, Department of Medicine, University of Alabama at Birmingham and Veterans Affairs Medical Center, Birmingham, Alabama

In the 2 decades since the first reports of the acquired immunodeficiency syndrome (AIDS), the human immunodeficiency virus (HIV)-1 pandemic has surpassed the European-centered bubonic plague of the 14th century in magnitude and number of deaths. Originating in chimpanzees in central Africa,<sup>1</sup> AIDS reached epidemic proportions in the 1980s in the United States and Europe, where the vast majority of infections were acquired through homosexual contact. Subsequently, the epidemic spread to heterosexual populations, and by 1998, 35 million people were estimated to be infected with HIV-1 and 20 million to have died of the consequences of HIV-1 infection worldwide. In contrast to the initial focus of the epidemic in developed countries, today 70% of infected persons live in sub-Saharan Africa; in some countries, an astonishing 25% of the population is infected with HIV-1.<sup>2</sup> Today, the virus is transmitted by heterosexual contact in 75%–85% of cases.<sup>3</sup> As a consequence of heterosexual transmission, the passage of HIV-1 from mother to fetus, neonate, and nursing infant (vertical transmission) has emerged as a devastating public health problem, particularly in developing countries.

Coinciding with these changes in the epidemiology of HIV-1 infection, important new information has emerged regarding the role of the gastrointestinal tract in HIV-1 infection. This information is derived from an array of epidemiologic, basic, and clinical investigations. Here, we review the key findings from these investigations and present the emerging concepts regarding the role of the gastrointestinal tract mucosa in HIV-1 transmission and pathophysiology and the effect of highly active antiretroviral therapy (HAART) on the epidemiology, morbidity, and treatment of gastrointestinal infections.

## Role of the Gastrointestinal Tract Mucosa in HIV-1 Transmission

Excluding infections acquired parenterally, virtually all HIV-1 infections are acquired via the mucosal surfaces of the gastrointestinal and genital tracts.<sup>4</sup> For most heterosexual transmissions, the genital tract mucosa is the site of viral entry, whereas for vertical transmissions and infections re-

sulting from oral–genital and anal–genital contact, the gastrointestinal tract mucosa is the portal of HIV-1 entry. During vertical transmission, the upper gastrointestinal tract mucosa is the site of viral entry as a consequence of the swallowing of infected amniotic fluid in utero, infected blood and cervical secretions intrapartum, and infected breast milk postpartum.<sup>5</sup> In homosexual transmission, oral–genital contact has recently been shown to be more common than anal–genital contact,<sup>6–8</sup> suggesting that the upper gastrointestinal tract mucosa is a more common site of HIV-1 entry than rectal mucosa. Indeed, up to a quarter of primary HIV-1 infections in one series in the United States resulted exclusively from receptive oral–genital exposure.<sup>8</sup>

## Infectiousness

New information on the infectiousness of HIV-1 from persons who carry the virus is based largely on studies of heterosexual transmission. Nevertheless, many factors that promote transmission across the vaginal mucosa probably also enhance transmission across the gastrointestinal mucosa (Table 1). For example, infectiousness, defined as the probability of transmitting HIV-1 from one person to another, is greatest when the index partner has primary HIV-1 infection, which corresponds to the period of infection between exposure to the virus and development of circulating anti-HIV-1 antibodies.<sup>9</sup> Primary infection is associated with the highest plasma levels of HIV-1.<sup>10,11</sup> Although the levels of HIV-1 in genital secretions during primary infection have not been reported, virus has been

---

*Abbreviations used in this paper:* AIDS, acquired immunodeficiency syndrome; CMV, cytomegalovirus; HAART, highly active antiretroviral therapy; HIV, human immunodeficiency virus; IFN- $\alpha$ , interferon  $\alpha$ ; MAC, *Mycobacterium avium* complex; NNRTI, nonnucleoside reverse-transcriptase inhibitor; NRTI, nucleoside reverse-transcriptase inhibitor; PI, protease inhibitor; RTI, reverse-transcriptase inhibitor; SIV, simian immunodeficiency virus; TMP-SMX, trimethoprim-sulfamethoxazole; ZDV, zidovudine.

© 2001 by the American Gastroenterological Association

0016-5085/01/\$35.00

doi:10.1053/gast.2001.22427

**Table 1.** Factors That Increase HIV-1 Transmission Across the Mucosa

High viral load during primary HIV-1 infection in the index partner
High viral load during end-stage HIV-1 disease in the index partner
Mucosal trauma, inflammation, erosion, or ulcer in the recipient partner
Mucosal infection in the recipient partner
Increased frequency of sexual contacts
Unprotected sexual contact
Receptive anal intercourse
Absence of circumcision in a male index partner

detected in genital secretions in all stages of disease. Thus, the presence of cell-free and cell-associated virus in genital secretions probably contributes to its increased infectiousness during this stage of the disease.<sup>12</sup>

Late-stage disease is also associated with increased levels of HIV-1 in the blood and semen of many<sup>12–14</sup> but not all<sup>15,16</sup> infected men and is associated with an increased risk of HIV-1 transmission.<sup>17</sup> The presence of reproductive tract inflammation and infections, such as urethritis, gonorrhea, and cytomegalovirus infection, also increase the infectiousness of the donor,<sup>18–20</sup> likely because of increased HIV-1 shedding into semen.<sup>3</sup> Genotypic differences in virus isolated from semen and blood in up to 40% of subjects argue for local production of virus in the genital tract of some infected men.<sup>21,22</sup> In summary, viral load in the blood is a key predictor of the risk of heterosexual transmission of HIV-1,<sup>23</sup> and the blood viral load generally correlates with that of genital secretions. Thus, the amount of virus inoculated onto a mucosal surface, including the gastrointestinal mucosa, is an important factor in HIV-1 transmission.

### Susceptibility

The susceptibility of the recipient partner is also an important factor in assessing the probability of HIV-1 transmission across the gastrointestinal tract mucosa. Normally, an intact mucosa prevents mucosal penetration of many luminal pathogens. In persons at risk for HIV-1 infection, trauma-induced disruption of the rectal mucosa provides inoculated virus direct access to the mucosal microcirculation and contributes to the high rate of HIV-1 transmission in receptive anal intercourse. Similarly, infection-associated mucosal inflammation and erosions probably provide virus access to lymphoid cells in the lamina propria. Supporting the latter notion are clinical observations that certain gastrointestinal tract infections that cause mucosal ulcers or deep erosions, including herpes simplex proctitis and syphilis, are associated with higher rates of HIV-1 transmission. In addition, certain mucosal infections enhance the susceptibility of lymphoid cells to HIV-1 infection. For example, *Mycobacterium avium* complex (MAC) enhances macrophage expression of CCR5, the chemokine

coreceptor for macrophage-tropic HIV-1, and up-regulates HIV-1 expression by macrophages coinfecting with MAC and HIV-1.<sup>24</sup>

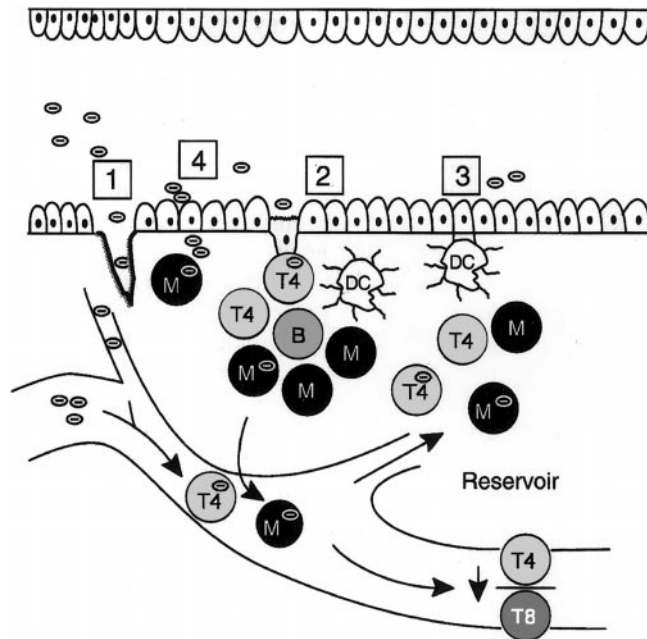
Genetics also plays a role in susceptibility to HIV-1 infection in certain populations. Approximately 1% of white individuals have a 32-nucleotide deletion allele in the gene that encodes CCR5, the chemokine receptor that serves as a coreceptor for macrophage-tropic HIV-1 entry into CD4<sup>+</sup> mononuclear cells.<sup>25,26</sup> The homozygous expression of this defective allele ( $\Delta 32/\Delta 32$ ) leads to the absence of functional CCR5 coreceptor; consequently, mononuclear cells are resistant to infection by macrophage-tropic HIV-1.<sup>25–28</sup> Because the predominant transmitting strains of HIV-1 are macrophage-tropic, persons homozygous for the allele are not susceptible to infection with most HIV-1 isolates.

Finally, a spectrum of behavioral and sociologic factors, including increased frequency of sexual contacts,<sup>29</sup> unprotected sexual contact,<sup>30</sup> receptive anal intercourse, and the absence of circumcision in men<sup>31</sup> are associated with increased HIV-1 transmission among persons in whom the gastrointestinal tract is the route of entry.

## Role of the Gastrointestinal Tract Mucosa in HIV-1 Pathophysiology

### HIV-1 Entry

In the absence of mucosal disruption from trauma or infection, proposed routes of HIV-1 entry into the mononuclear cell-rich lamina propria include M cells, dendritic cells, and epithelial cells (Figure 1). M cells are specialized epithelial cells present in the dome overlying Peyer's patches in the small intestine and lymphoid follicles in the rectum. M cells transport macromolecules and microorganisms, including viruses such as poliovirus and reovirus, by a nondegradative pathway to interdigitating mononuclear cells or possibly dendritic cells in the underlying lymphoid structure. In an ex vivo system, mouse and rabbit M cells are capable of transporting HIV-1 to mononuclear cells.<sup>32</sup> In the simian immunodeficiency virus (SIV) model, atraumatic inoculation of SIV into the oral cavity leads to rapid infection of the tonsils, which are a rich source of M cells,<sup>33</sup> suggesting M cell uptake and transport of the virus.<sup>34</sup> However, human M cells have not yet been reported to take up and transport HIV-1, probably reflecting the rapidity of the transport process and the unavailability of tissue specimens from subjects shortly after virus inoculation. Nevertheless, the high prevalence of M cells in the rectum<sup>35</sup> and tonsils strategically positions these cells for a potential role in HIV-1 transport in vertical and anal-genital transmission.



**Figure 1.** HIV-1 entry in the gastrointestinal mucosa. Potential sites for HIV-1 entry include (1) disrupted epithelium caused by trauma or infection, (2) M cells, (3) dendritic cells, and (4) epithelial cells. Modified and reprinted with permission.<sup>4</sup>

Dendritic cells are highly efficient antigen-presenting cells that express CD4. Dendritic cells, which assume a characteristic stellate morphology in the tissue, have been identified in rat small and large intestine,<sup>36</sup> mouse Peyer's patches,<sup>37</sup> macaque cervicovaginal mucosa and foreskin,<sup>38</sup> and human tonsil and adenoid.<sup>39</sup> Tonsillar dendritic cells form conjugates with T cells, resulting in high levels of viral replication by HIV-1-infected T cells *in vitro*.<sup>39</sup> Recent evidence indicates that dendritic cells bind HIV-1 envelope gp120 through a C-type lectin,<sup>40</sup> allowing HIV-1 capture (but not infection) for subsequent delivery to T cells and dissemination to secondary lymphoid organs.<sup>40,41</sup> Whether dendritic cells are involved in the pathogenesis of HIV-1 infection in the human small intestine is unclear because we have been unable to identify dendritic cells in human small intestinal lamina propria.<sup>42,43</sup> In these studies, lamina propria mononuclear cells isolated from normal jejunum did not express dendritic cell markers, including CD11b, CD11c, CD21, CD34, CD83, or CD123, or display ultrastructural characteristics of dendritic cells. In addition, treatment of purified lamina propria macrophages with optimal concentrations of glomerulocyte-macrophage colony-stimulating factor, tumor necrosis factor  $\alpha$ , and interleukin 4 did not induce dendritic cells. However, cells thought to be dendritic cells have been identified morphologically in colon lamina propria (<1% of mononuclear cells)<sup>44</sup>; newly available dendritic cell-specific antibodies will facilitate confirmation of this observation. Whether

dendritic cells in the colon participate in HIV-1 entry and pathogenesis awaits further study.

Epithelial cells are the most abundant cell type lining the mucosa of the intestine and colon and are a potentially important conduit for HIV-1 entry. A recent study of the mucosal translocation of HIV-1 using epithelial cell lines showed that the virus could be translocated across a tight epithelial cell monolayer by a transcytotic pathway.<sup>45</sup> However, the phenotype of epithelial tumor cell lines differs from that of primary intestinal epithelial cells. Therefore, using a modification of the technique that we developed to isolate and purify human intestinal macrophages and lymphocytes,<sup>46</sup> we purified human intestinal epithelial cells and studied their HIV-1 receptor and coreceptor expression.<sup>47</sup> Primary intestinal epithelial cells expressed galactosyl ceramide (GalCer), an alternative primary receptor for HIV-1 on neural<sup>48</sup> and epithelial lines.<sup>45,49</sup> In addition, the primary intestinal epithelial cells expressed CCR5, the coreceptor for macrophage-tropic HIV-1 isolates (referred to as R5 viruses because they use CCR5 for cell entry).<sup>47</sup> In contrast to their expression of CCR5, primary intestinal epithelial cells did not express CXCR4, the chemokine coreceptor for lymphocyte-tropic HIV-1 isolates (referred to as X4 viruses because they use CXCR4 for entry), or CD4, the primary receptor for HIV-1 on mononuclear cells. This GalCer<sup>+</sup>CCR5<sup>+</sup>CXCR4<sup>-</sup> phenotype distinguishes primary intestinal epithelial cells from epithelial cell lines and indicates that cells equipped for the selection and uptake of R5 HIV-1 are present in the upper gastrointestinal tract mucosa. The phenotype of purified rectal epithelial cells has not yet been reported, although immunohistochemical staining of colon biopsy specimens suggests that CXCR4 may be present on rectal epithelium,<sup>50,51</sup> indicating that intestinal epithelium may differ from colonic epithelium in coreceptor expression.

### Selective Transfer of R5 HIV-1 by Intestinal Epithelial Cells

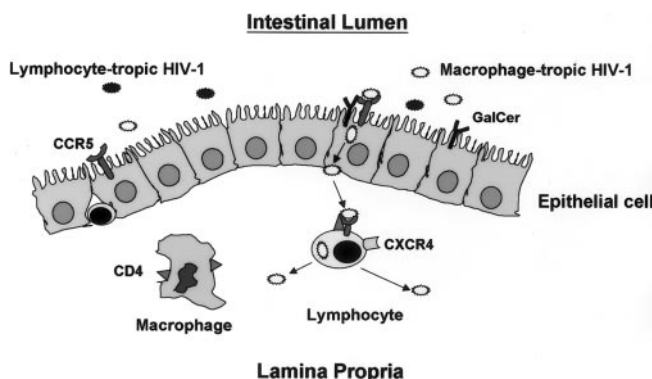
HIV-1 isolated from acutely infected persons is predominantly R5.<sup>52-56</sup> Over time, mutations lead to the emergence of X4 viruses, resulting in the presence of a mixture of R5 and X4 viruses in most chronically infected persons. Because most HIV-1 infections are acquired across a mucosal surface, mucosal cells could conceivably select the R5 viruses that are initially acquired by the recipient from the mixture of HIV-1 viruses inoculated onto the mucosa by a chronically infected donor. Having shown that intestinal epithelial cells express CCR5, but not CXCR4, we investigated whether the cells could selectively transfer R5 HIV-1 to target cells. We found that intestinal epithelial cells selected and transferred R5, but not X4, HIV-1 to

CCR5<sup>+</sup> target cells, which replicated and amplified virus expression.<sup>47</sup> In addition, our studies supported Bomsel's observation in cell lines that HIV-1 transfer was accomplished by microtubule-dependent transcytosis. Our finding that CCR5<sup>+</sup> intestinal epithelial cells select and transfer exclusively R5 viruses offers a mechanism for the selective transmission of R5 HIV-1 in primary infection acquired through the upper gastrointestinal tract (Figure 2).

Once HIV-1 has crossed the epithelium and entered the lamina propria, the virus encounters the largest reservoir of macrophages and lymphocytes in the body. In studies of the biologic parameters of HIV-1 infection of these cells, we showed that lamina propria macrophages surprisingly do not express CCR5 and are not permissive to R5 HIV-1 in vitro.<sup>42,43,57,58</sup> This observation may explain the very low prevalence of HIV-1-infected macrophages in the upper gastrointestinal tract mucosa in vivo<sup>59</sup> and indicates that intestinal macrophages probably do not participate in the selection of R5 viruses in primary infection. Intestinal lymphocytes, on the other hand, express both CCR5 and CXCR4 and support replication by both R5 and X4 HIV-1 in vitro,<sup>43</sup> indicating that intestinal lymphocytes also probably do not participate in the selective acquisition of R5 viruses during primary infection (Figure 2). Thus, epithelial cells, rather than resident macrophages or lymphocytes, appear to be the mucosal cell capable of selecting R5 HIV-1 in primary infection.

### Local HIV-1 Replication and Depletion of Lamina Propria CD4<sup>+</sup> T Cells

A series of insightful in vivo studies of HIV-1 infection in humans<sup>60,61</sup> and SIV infection in rhesus ma-



**Figure 2.** Schematic representation of HIV-1 translocation across the intestinal epithelium. Although both lymphocyte-tropic and macrophage-tropic HIV-1 are inoculated onto the mucosa, CCR5-mediated endocytosis, possibly in association with GalCer, initiates the transcytosis of macrophage-tropic virus from the apical surface of the epithelial cell to the basal surface. Released macrophage-tropic HIV-1 then infects CCR5<sup>+</sup> lamina propria lymphocytes but not HIV-1. During early infection, virus replicates predominantly, if not exclusively, in lamina propria lymphocytes.

caques<sup>62,63</sup> have sought to dissect the early events in mucosal HIV-1 infection. Consistent with our finding that human intestinal lymphocytes, not macrophages, are a target cell for HIV-1 infection in vitro, Veazey et al.<sup>62</sup> showed that during the first few days of SIV infection of macaques, infected macrophages were rare, and more virus-infected T cells were present in the intestinal mucosa than in the blood. Because the virus replicates more efficiently in activated T cells, the greater abundance of activated CD4<sup>+</sup> T cells in the lamina propria than in the blood<sup>64,65</sup> probably accounts for the initial higher frequency of virus-infected lymphocytes in the gastrointestinal mucosa than in the blood.

Coincident with the early local accumulation of SIV-infected lymphocytes is the presence of a high viral load in the intestinal mucosa.<sup>63</sup> Importantly, the early and high viral load in the intestinal mucosa in SIV-infected macaques is associated with villous atrophy and malabsorption, consistent with SIV-induced enteropathy.<sup>63</sup> However, after 7–14 days of infection, CD4<sup>+</sup> T cells in the intestinal and colonic mucosa became rapidly and profoundly depleted, probably as a consequence of cell lysis and apoptosis. This profound depletion of mucosal CD4<sup>+</sup> T cells, occurring predominantly in the lamina propria, precedes the depletion of such cells in the blood in both humans and macaques.<sup>60–63</sup>

### Sequence of Mucosal Events in Early HIV-1 Infection

Taken together, the studies discussed above suggest the following sequence of events in the intestinal mucosa during early HIV-1 infection acquired by vertical transmission or homosexual contact. A mixture of R5 and X4 viruses, typically present in the blood of chronically infected donors, are released into the milk or semen and then enter the recipient through inoculation into the oral cavity. In the oral cavity, virus that reaches the tonsils encounters M cells in the overlying epithelium, and these cells deliver the virus to the dendritic cell-rich lymphoid tissue of the tonsils. Although dendritic cells alone do not support HIV-1 replication, dendritic cell–T cell conjugates support high levels of viral replication. Dendritic cells, which normally migrate through the lymphatics to secondary lymphoid organs, contain a C-type lectin that traps virus and thus may participate in the dissemination of HIV-1 from the gastrointestinal tract to lymphoid tissues.

In the oral cavity, virus mixes with saliva, which contains antiviral factors, including secretory leukocyte protease, a potent inhibitor of HIV-1 activity.<sup>66,67</sup> These factors may prevent local (tonsillar) infection, allowing swallowed virus to pass through the oral cavity. Passage through the stomach would be facilitated by the absence of gastric acid

production in the fetus and neonate. In the adult, gastric acid could limit the amount of viable virus that reaches the intestine, but this issue requires further study. Thus, a mixture of inoculated viruses reaches the recipient's upper gastrointestinal tract mucosa. There, GalCer<sup>+</sup>CCR5<sup>+</sup>CXCR4<sup>-</sup> epithelial cells bind and then selectively transfer R5 viruses from the cells' apical to basolateral surface, probably by microtubule-dependent, nondegradative transcytosis. Virus translocated across the epithelium encounters lamina propria macrophages and T cells, but only the lymphocytes express CCR5, the coreceptor that mediates R5 HIV-1 entry. Because the lamina propria contains the largest reservoir of activated T cells in the body and because HIV-1 replicates most efficiently in activated T cells, the lamina propria becomes the initial major site of HIV-1 replication and amplification. Virus that infects activated T cells in the organized lymphoid structures, possibly via M cell uptake and transport, could then disseminate HIV-1 to distant mucosal sites through normal receptor-mediated homing. Soon, HIV-1-induced T cell death by cell lysis, apoptosis, and cytotoxic lymphocyte-induced killing, leads to rapid depletion of lamina propria CD4<sup>+</sup> T cells long before the decrease in circulating CD4<sup>+</sup> T cells.

Eventually, local immunosuppression induced by T cell depletion predisposes the gastrointestinal tract mucosa to an array of opportunistic infections, leading to mucosal inflammation and the release of chemoattractant peptides. These peptides recruit to the mucosa CCR5<sup>+</sup> and CXCR4<sup>+</sup> monocytes and lymphocytes, which serve as new target cells for the perpetuation of local HIV-1 replication. As a consequence of this inflammation or possibly local HIV infection, mucosal function is compromised and malabsorption ensues, even before opportunistic infections induce clinical symptoms. Thus, besides serving as a site of opportunistic infections in late-stage HIV-1 disease, the gastrointestinal tract also plays a fundamental role in early HIV-1 disease by serving as the site for virus entry, the initial site of virus replication and amplification, and the initial site of CD4<sup>+</sup> T cell depletion. As Veazey et al.<sup>62</sup> aptly suggested, the gastrointestinal tract mucosa, not the peripheral lymphoid tissue, is the initial tissue site of HIV-1 disease.

### Sequelae of Mucosal HIV-1 Infection

After these initial events and as a consequence of such extensive infection of intestinal T cells, HIV-1-infected patients show a rapid, dramatic, and persistent decrease in the numbers of CD4<sup>+</sup> cells in the lamina propria, which precedes that in peripheral sites.<sup>61,68-70</sup> These immunologic insults to the mucosae are associated with a range of physiologic and morphologic perturbations that lead to remarkably increased rates of oral, esophageal, and gastrointestinal symptoms.<sup>71-77</sup> Rates of secondary oppor-

tunistic infections correlate with the number of peripheral CD4<sup>+</sup> T cells and presumably with those in the mucosa.<sup>78-80</sup> Prominent among these syndromes is chronic diarrhea.

Chronic diarrhea affects most HIV-1-infected adults in resource-poor nations and, until relatively recently, 25%–50% of those in the United States and Western Europe.<sup>72,81-84</sup> A number of excellent primary investigations and reviews have revealed that with a sequential and comprehensive approach, a specific organism can be identified in 50%–85% of HIV-1-infected patients with diarrhea, and most of these infections can be effectively treated or suppressed (Table 2).<sup>72,85-98</sup> The diagnostic algorithms and specifics of therapy are now conveniently outlined.<sup>99-101</sup> However, perhaps the most effective approach to prevention and treatment of mucosal infections and many opportunistic infections among patients with HIV-1 disease has been the recent introduction of HAART.

## Role of Antiretroviral Therapy HAART

Results of therapy with the first antiretroviral agent available, zidovudine (ZDV; AZT), showed in 1987 for the first time that chemotherapy could retard the progression of HIV-1 disease and lower the incidence of opportunistic infections and HIV-1-associated death.<sup>102</sup> Subsequent analyses of these and other results indicate that the duration of single-agent antiviral activity was limited because of the development of resistance and inadequate control of viral replication. Thus, similar to successful control of tuberculosis, multiple antiretroviral agents were developed to suppress HIV-1 replication over long periods, decrease HIV-1 disease progression, and prevent or reverse HIV-1-induced immunologic incompetence.<sup>103-107</sup> This powerful "cocktail" of agents improves the natural history of HIV-1 infection by combining inhibitors of HIV-1 reverse transcriptase and protease to provide HAART.

Reverse-transcriptase inhibitors (RTIs), both nucleoside analogues (NRTIs) such as ZDV and nonnucleoside analogues (NNRTIs), primarily inhibit the ability of HIV-1 RNA to encode viral DNA, which can integrate into the host genome. After attachment of HIV-1 to the cell membrane, release from its envelope, and entry into the cytoplasm, the retroviral RNA generates a double-stranded DNA provirus through reverse transcriptase. This proviral DNA can then enter the nucleus and integrate into the host cell genomic DNA, and viral replication is initiated, particularly in activated cells. However, during prolonged RTI therapy, site-specific mutations in the *pol* gene, which encodes reverse transcriptase, confer progressive resistance to

**Table 2.** Potential Causes of Diarrhea in HIV-1–Infected Patients

Noninfectious	Antiretroviral therapy <sup>a</sup> Other medications Malignancies (intestinal lymphoma, <sup>b</sup> Kaposi's sarcoma) Idiopathic ("AIDS enteropathy") <sup>a</sup> Inflammatory bowel disease		
Infectious	Viral Cytomegalovirus <sup>a,b,c</sup> HIV-1 (especially acute infection) <sup>b,c</sup> Adenovirus  Herpes simplex virus <sup>b</sup>  Rotavirus, calcivirus, astrovirus, coronavirus, picobirnavirus  Fungal <i>Histoplasma capsulatum</i> <sup>b</sup>	Bacterial <i>Salmonellae</i> spp. <sup>b</sup> <i>Campylobacter</i> spp. <sup>b</sup> <i>Shigella</i> spp. <sup>b</sup>  <i>Clostridium difficile</i> <sup>b</sup> <i>Listeria monocytogenes</i> <sup>b</sup> Enteroaggregative <i>E. coli</i> <sup>b</sup> <i>Mycobacterium avium</i> complex <sup>b,c</sup> <i>Aeromonas</i> spp. <sup>b</sup>	Parasitic <i>Cryptosporidium parvum</i> <sup>a,b,c</sup> <i>Isospora belli</i> <sup>b</sup> Microsporidia <i>Enterocytozoon bienewisi</i> <sup>c</sup> <i>Septata intestinalis</i> <sup>b</sup> <i>Giardia lamblia</i> <sup>b</sup> <i>Cyclospora cayatanensis</i> <sup>b</sup> <i>Entamoeba histolytica</i> <sup>b</sup> <i>Blastocystis hominis</i> <sup>b</sup> Other parasites

Data from references 72, 79, 90, 96, 97, 119, 130, 134, 140, 174, and 176–188.

<sup>a</sup>Relatively common.

<sup>b</sup>Treatment available.

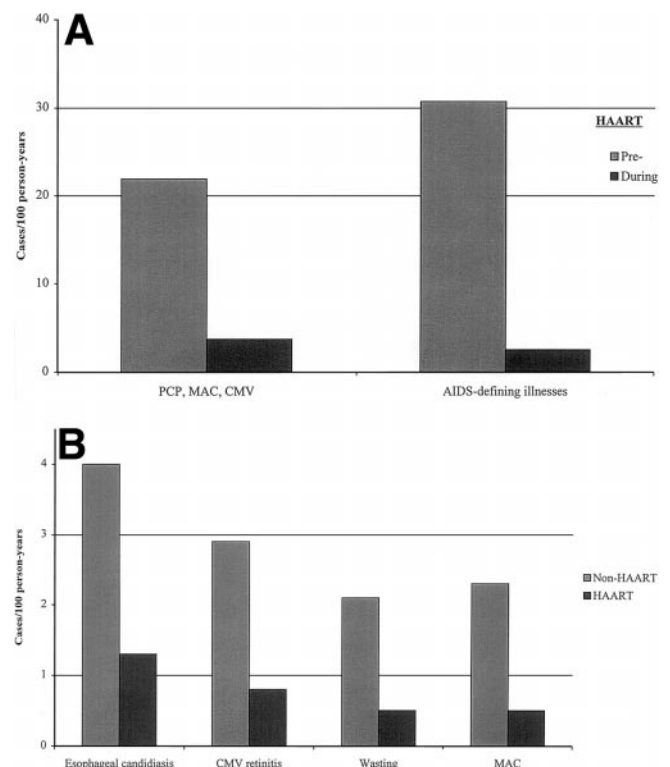
<sup>c</sup>Documented resolution or decreased incidence of infection in the presence of HAART.

RTI therapy, necessitating the use of additional agents to limit viral replication and the development of resistance. Protease inhibitors (PIs), a second major class of antiretroviral agents, induce dose-dependent inhibition of HIV-1 aspartic protease, which is required for production of mature infectious virions.<sup>99,108</sup> By blocking the cleavage of HIV-1 Gag-Pol polyprotein precursor into requisite structural core proteins and enzymes (reverse transcriptase, integrase, and protease), PIs cause the production of abnormal viral proteins and noninfectious virions. However, the development of selective mutations in the protease during therapy leads to resistance, and resistance to one PI affects the susceptibility of HIV-1 to other PIs.<sup>99,108</sup> Thus, virtually all current HAART regimens include 3 or more agents (typically a PI and 2 NRTIs) to diminish or ablate viral replication (reflected in a reduction in viral load), prevent the development of resistance, enhance recovery of immunologic competence (resulting in an increase in CD4<sup>+</sup> T cell number), and improve clinical status (based on CDC stage).<sup>99,104,108–110</sup> Clinically, the goals of therapy are to prevent HIV-1–associated illness and prolong survival.

### Impact on Mortality

HAART has dramatically reduced the death rate among patients with HIV-1 infection from the period before its widespread use (before 1996) to the present. Among US patients with advanced HIV-1 disease (CD4<sup>+</sup> T cell count < 100 cells/μL; normal, ≈750–1200 cells/μL), mortality decreased between 1995 and 1997 from 29.4 to 8.8 per 100 person-years.<sup>107</sup> Concomitantly, the incidence of the three most common HIV-1–associated opportunistic

infections (*Pneumocystis carinii* pneumonia, MAC disease, and cytomegalovirus [CMV] retinitis) decreased by more than 75% (Figure 3A and B). This decrease was proportional to the intensity of antiretroviral therapy and was most



**Figure 3.** Effect of HAART on rates of major opportunistic infections in the populations. The pre-HAART and post-HAART dates are (A) 1995 and 1997, respectively,<sup>107</sup> and (B) 1994 and 1998, respectively.<sup>106</sup>

prominent among persons on combination and PI-containing regimens. Similar results have been reported from Western Europe between 1994 and 1998 for AIDS-defining illnesses (Figure 3B) and for these and other infections in the United States.<sup>29,78,106,111</sup> These decreased rates were significant for a number of complications involving the alimentary tract, including esophageal candidiasis, MAC, CMV, cryptosporidiosis, and herpes simplex virus, as well as Kaposi's sarcoma and non-Hodgkin's lymphoma. Thus, combination antiretroviral therapy, particularly HAART, has had a significant impact on the natural history of HIV-1 infection and has substantially reduced the incidence of HIV-1-related infectious and neoplastic diseases, including those of the gastrointestinal tract, as well as death.

The dramatic effects of HAART on mortality and HIV-1-related infections are most likely caused by the inhibition of HIV-1 replication and the consequent recovery of immune function because most antiretroviral agents have little activity against other viruses or pathogens. Decreases in mortality and rates of infection before the introduction of PI and HAART were associated with earlier recognition of HIV-1 infection and treatment with ZDV, more rapid diagnosis and treatment of specific opportunistic infections, and prophylactic therapy with trimethoprim-sulfamethoxazole (TMP-SMX) for *Pneumocystis carinii* pneumonia (and toxoplasmosis). The widespread introduction of ZDV and TMP-SMX, each of which has activity against gram-negative bacteria, also was associated with a dramatic decrease in HIV-1-associated non-*typhi* *Salmonellae* infections in the United States.<sup>112,113</sup> Before this time, *Salmonellae* species were common causes of enteritis and bacteremia in these patients,<sup>114-119</sup> as they remain in African patients with HIV-1 disease today. Other than the activity of the PI aprenavir against *Giardia lamblia*<sup>99</sup> and of adefovir dipivoxil against DNA viruses (herpes simplex virus, CMV, and hepatitis B virus), most other antiretroviral agents have shown little activity against viral, bacterial, protozoan, or fungal pathogens. Thus, recovery of immune function probably underlies much of the clinical benefit that accompanies viral suppression with antiretroviral therapy.

Substantial immunologic benefits result from reductions in the levels of HIV-1 in both blood and lymphoid tissue following HAART. These benefits include increases in the number of CD4<sup>+</sup> T cells, decreases in T and B cell activation with subsequent enhancement of specific proliferative responses, and restoration of the functional architecture of lymph nodes.<sup>120-123</sup> However, functional immunologic recovery occurs over many months. Consequently, rates of HIV-1-related infections decrease most prominently after 2

months of potent antiretroviral therapy.<sup>124</sup> Thus, data supporting recommendations to discontinue prophylactic therapy against opportunistic infections after initiating HAART confirm the safety of this recommendation in patients whose CD4<sup>+</sup> T cell levels have increased to 200 cells/ $\mu$ L (or 14% of total lymphocytes) for more than 12 weeks.<sup>125-129</sup>

HAART has 3 potential effects on the natural history of HIV-1-associated infections, including enteric infections. First, effective control of HIV-1 results in a decreased incidence of secondary infections and decreased rates of reactivation of latent infections. Second, an indirect benefit of the decreased rates of such infections in patients receiving HAART is the discontinuation of long-time prophylactic antimicrobial therapy, leading to a decrease in the rate of antibiotic-associated enteric infections with *Clostridium difficile*,<sup>130,131</sup> as well as lower rates of drug reactions. A third consequence of HAART is the resolution of ongoing infections, probably because of repopulation of the peripheral T cells. Recent reports indicate that as the viral load decreases in the intestinal mucosa, CD4<sup>+</sup> T cells repopulate the mucosa,<sup>132,133</sup> and that on HAART this repopulation occurs more rapidly in the intestinal mucosa than in the blood.<sup>134</sup>

Earlier reports have suggested that heretofore untreatable or inadequately treatable enteric infections, such as *Cryptosporidium*, could improve clinically and microbiologically with ZDV.<sup>80,135,136</sup> However, the natural history of cryptosporidiosis is variable.<sup>80,137-139</sup> More recently, a case-control study showed that the use of antiretroviral therapy was associated with significant, but not absolute, protection against infection with *Cryptosporidium*.<sup>137</sup> In an open randomized trial among patients with previously diagnosed infections and persistent diarrhea, symptoms resolved and pathogens were undetectable in stools from 3 of 6 patients with microsporidia (*Enterocytozoon bieneusi*) and 2 patients with concomitant *Cryptosporidium*<sup>140</sup> after addition of the PI indinavir to NRTI.<sup>140</sup> Similarly, among 9 patients with chronic diarrhea associated with microsporidiosis (n = 5), cryptosporidiosis (n = 3), or both (n = 1), in 8 of whom antiparasitic therapy had failed, HAART induced complete resolution of symptoms and weight gain after a median of 6 weeks of therapy.<sup>141</sup> Organisms were not detected in the 8 patients evaluated, and marked histologic improvement was observed in those in whom biopsies were performed. However, diarrhea recurred in 4 patients at a median of 11 months (range, 7-13 months) when the patients failed to respond to antiretroviral therapy (increase in plasma HIV-1 load and decrease in CD4<sup>+</sup> T cell number). In an HIV-1-infected patient evaluated over time, persistent *Cryptosporidium parvum* infection resolved with HAART in associa-



tion with decreases in viral RNA and dramatic and sustained increases in CD4<sup>+</sup> T cell number in blood and intestinal mucosa.<sup>134</sup>

Given these promising results, it can be speculated that HAART will also improve one of the most difficult and challenging complications of HIV-1 infection, chronic diarrhea of unknown etiology, often referred to "AIDS enteropathy." As awareness of the potential pathogens has increased among clinicians and pathologists and as diagnostic techniques have become more sophisticated and sensitive (including stains, diagnostic antibodies, cultures, electron microscopy, and polymerase chain reaction), the number of patients with this complication has decreased.<sup>91,92,99</sup> Microsporidiosis, viral infections (including cytomegalovirus and adenovirus), and intestinal malignancies (Kaposi's sarcoma and non-Hodgkin's small bowel lymphoma) assume increasing importance among patients with AIDS enteropathy. Nevertheless, 10% to 50% of HIV-1-infected patients have diarrhea without an identifiable pathogen, and some potential pathogens are not treatable.<sup>91,92,96</sup> Thus, the report that HAART induced sustained clinical improvement in 8 such patients with chronic diarrhea of unknown etiology is extremely encouraging<sup>140</sup> for patients and frustrated physicians.

### Hepatitis C

Hepatitis C virus is the leading cause of chronic hepatitis among HIV-1-infected patients in the United States. Intravenous drug users and patients with hemophilia make up the majority of these coinfecting patients; 40% of HCV-infected hemophiliac men are coinfecting with HIV-1.<sup>142</sup> The natural history of patients with dual infections differs from that in HIV-1-seronegative adults. Compared with patients with HCV alone, those with concomitant HIV-1 infection have higher HCV RNA levels in blood and liver tissue, more rapid progression of liver disease, and possibly increased rates of death related to hepatic disease.<sup>143-147</sup> HCV viral loads are typically increased with advancing immunosuppression and thus are inversely proportional to CD4<sup>+</sup> T cell number.<sup>143,146,147</sup> Despite the accelerated course of HCV replication and associated liver disease, coinfection with HCV does not usually appear to promote progression of HIV-1 disease or to increase mortality.<sup>148</sup> However, an increased risk of death and new AIDS-defining illnesses, as well as delayed recovery of CD4<sup>+</sup> T cells with antiretroviral therapy, were recently reported among HIV-1-infected Swiss patients with HCV.<sup>149</sup> These increased risks were primarily associated with intravenous drug use and unrelated to more progressive liver disease.

Responses of HCV to antiviral therapy with interferon  $\alpha$  (IFN- $\alpha$ ) among patients with HIV-1 coinfection appear to

be similar to those among HIV-1-seronegative subjects; approximately a quarter of patients have sustained virologic responses 12 months after they discontinue therapy.<sup>150-152</sup> Most responders had high CD4<sup>+</sup> T cell counts (>500 cells/ $\mu$ L). Preliminary data suggest that the effects of IFN- $\alpha$  therapy with ribavirin may be greater than with IFN- $\alpha$  alone among both HIV-1-infected and -seronegative patients,<sup>153,154</sup> although anemia is an important complication. Another option for therapy in this group is HAART. Among HIV-1-infected patients with hepatitis B, initiation of potent antiretroviral therapy may lead to resolution of chronic infection with the development of antibodies to the hepatitis B surface antigen. In several series that monitored HCV status in patients before and during HAART, levels of plasma HCV and transaminases showed transient and clinically inapparent increases in HCV (0%-90%) and transaminases (0%-33%).<sup>142,155-159</sup> However, HCV RNA decreased to below the limits of detection in a small minority, as is observed in up to 15% of otherwise healthy patients after initial infection. Although both severe and clinically inapparent hepatitis can occur in patients upon initiation of HAART,<sup>160-163</sup> the presence of coinfection with HCV and HIV-1 should not serve as a primary determinant of the decision to begin effective antiretroviral therapy. The relatively infrequent "immune restoration" syndrome, in which deleterious inflammatory responses or even reactivation of infections (e.g., CMV and MAC) follow HAART,<sup>164-166</sup> does not appear to affect HCV infections to any consistent degree. In patients with HIV-1 disease, efforts to limit the impact of HCV infection should include limiting alcohol use, administering hepatitis A vaccine if the patient is seronegative, monitoring hepatic transaminase levels, and considering specific therapy for HCV to eradicate infection or limit progressive liver injury in those with significant hepatic pathology.

### Complications of HAART

Despite the remarkable ability of HAART and other measures to dramatically decrease the level of HIV-1 in plasma and the rates of opportunistic infections, antiretroviral therapy has not been sufficient to eradicate HIV-1 infection in any patient. Moreover, undetectable HIV-1 RNA levels are achieved in only about a third to half of patients on HAART in nonstudy settings.<sup>167,168</sup> Impaired access to care, particularly among blacks, Latinos, the uninsured or underinsured, women, and certain risk groups,<sup>169</sup> also reduces the impact of HAART in the community. In addition, the high cost and the inability of some patients to tolerate 1-3 dozen pills per day, even among those with access to regular skilled care, significantly affects the response to HAART.

**Table 3.** Gastrointestinal Complications of Antiretroviral Therapy and Potential Interactions with other Medications Used in Gastrointestinal Medicine

Type of Medication	Medication	Trade Name	Primary GI Toxicity <sup>a</sup>	GI-associated Drug Interactions
Antiretroviral NRTI	Zidovudine (AZT, ZDV)	Retrovir	Anorexia; nausea (4%–26%); vomiting (3%–8%) (rare hepatitis, steatosis, lactic acidosis)	Activity may be inhibited by ribavirin
	Didanosine (ddI)	Videx	Pancreatitis (4%–8%); diarrhea (16%); ↑ALT/AST (6%–20%)	Potential increased rate of pancreatitis with pentamidine, azathioprine; buffers associated with ↓absorption of itraconazole, ketoconazole, dapsone; tetracycline, ciprofloxacin; ddI levels ↑ with ranitidine, ganciclovir
	Zalcitabine (ddC)	HIVID	Stomatitis (self-limited) (2%–17%); pancreatitis (0.5%–9%)	Few; possible ↑ neuropathy with metronidazole, disulfuram
	Stavudine (d4T)	Zerit	Diarrhea (33%), nausea/vomiting (26%), abdominal pain (23%); ↑ALT/AST (65%); significant GI symptoms and hepatic abnormalities in 4%–10%	Few; possible ↑ neuropathy with ethanol; ribavirin may increase activity (in vitro data)
	Lamivudine (3TC)	EpiVir	Limited; mild and transient diarrhea, nausea, abdominal pain	Few
Nucleotide analog RTI	Abacavir (ABC)	Ziagen	Nausea (45%), diarrhea (25%), vomiting (15%) and abdominal pain (15%) may decrease over weeks of therapy; hypersensitivity reaction with fever ± rash, malaise, nausea, vomiting, ↑ALT/AST in 2%–5% within 1 month	None reported
	Adefovir dipivoxil	Preveon	Usually mild nausea, diarrhea, occasional vomiting (1%–8%); ↑ALT/AST (4%); (renal toxicity 38%)	None reported
NNRTI	ZDV-3TC	Combivir	As above	
	Nevirapine (NVP)	Viramune	Nausea; ↑ALT/AST (1%); isolated ↑GGT common; (rash most common)	
	Delavirdine (DLV)	Rescriptor	Nausea (7%); diarrhea (4%); ↑ALT/AST (≥5%); (rash most common; usually transient)	Level ↓ with rifampin, rifabutin (P-450 system) and antacids (↑gastric pH); level ↑ with clarithromycin, rifabutin, cisapride
PI <sup>b</sup>	Efavirenz (EFV)	Sustiva	(Transient rash and CNS symptoms of headache, dizziness, impaired concentration)	Avoid cisapride; should not be taken within 2 hours of antacids; not recommended with clarithromycin; (interacts with other PI)
	Saquinavir (SQV); Saquinavir-SGC (soft gel capsule)	Invirase; Fortovase	Nausea, diarrhea, abdominal pain, dyspepsia (5%–10%)	Cisapride contraindicated; SQV level ↑ with ketoconazole, clarithromycin; SQV level ↓ with rifampin, rifabutin; Clarithromycin level ↑ with SQV; (interacts with other PI)
	Ritonavir (RTV)	Norvir	Nausea, diarrhea, vomiting, anorexia, abdominal pain (20%–40%), especially in first few weeks of therapy; taste perversion (10%); increased triglycerides (60%, but >1500 mg/dL in 2%–8%); ↑ALT/AST (10%–15%), especially with NRTI	Cisapride contraindicated; caution with dronabinol, ondansetron, cimetidine, promethazine, corticosteroids; RTV level ↑ with ketoconazole, itraconazole; RTV level ↓ with rifampin; clarithromycin, rifampin; clarithromycin, erythromycin, rifampin, rifabutin levels increased with RTV; (interacts with other PI)
	Indinavir (IDV)	Crixivan	Nausea, vomiting, diarrhea, abdominal pain (4%–15%); increased indirect bilirubin (10%); (nephrolithiasis 5–10%)	Cisapride contraindicated; IDV level ↓ with rifabutin; IDV level ↑ with ketoconazole; rifabutin level ↑ with IDV; (interacts with other PI)
	Nelfinavir (NLF)	Viracept	Diarrhea (usually mild) (2%–19%)	Cisapride and rifabutin contraindicated; NLF levels ↓ with rifampin; rifabutin levels ↑ with NLF; (interacts with other PI)
	Amprenavir	Agenerase	Diarrhea, nausea, vomiting (7%–33%); rash (18%)	Cisapride and rifampin contraindicated; amprenavir levels ↓ with rifabutin; rifabutin levels ↑ with amprenavir; (interacts with other PI)
	ABT 378 (Lopinavir-Ritonavir)	Kaletra	Diarrhea (10%–20%); ↑ALT/AST (8%)	Similar to other PI
Other	Interleukin 2	Proleukin	Diarrhea, abdominal pain, stomatitis (7%); nausea; vomiting; isolated ↑ bilirubin (8%); ↑ALT/AST; acalculous cholecystitis; constitutional flu-like symptoms (fever, chills, muscle/joint pain) (45%)	
	Hydroxyurea	Hydrea	Nausea (12%); ↑ALT/AST (2%); stomatitis (8%); diarrhea; occasional anorexia, vomiting, diarrhea, constipation (myelosuppression; rash)	
Alternative	Vitamin C Allicin (garlic extract) Malaleuca (tea tree extract) N-acetylcysteine (mucomyst)			

ALT/AST, alanine/aspartate transaminase elevation >2.5–5 fold above normal values; GGT,  $\gamma$ -glutamyl transpeptidase; GI, gastrointestinal; CNS, central nervous system. Symptoms listed in parenthesis represent nongastrointestinal but prominent symptoms.

<sup>a</sup>Rates may vary among studies.

<sup>b</sup>As with other inhibitors of cytochrome p450 system, specifically CYP 3A4, protease inhibitors should not be given with cisapride (Propulsid), astemizole (Hismanal), terfenadine (Seldane), midazolam (Versed), triazolam (Halcion), or ergot derivatives.

Data from references 99, 101, 171, and 189–191.

Gastroenterologists may not routinely serve as the primary care physician for patients with HIV-1 infection, but they are often consulted to evaluate gastrointestinal symptoms in patients receiving HAART. Consequently, they should be aware of the toxicities associated with antiretroviral and support drugs (Table 3). In general, gastrointes-

tinal symptoms, such as nausea, vomiting, abdominal pain, and diarrhea, often occur early in the course of therapy and may abate over time. Gastrointestinal toxicity significantly limits the initial tolerance to protease inhibitors, often requiring dose escalation and sequential addition of other medications, such as nucleoside analogue RTI. Hepatic

toxicity is more often associated with long-term therapy and is typically mild, although severe hepatic toxicity, particularly with the protease inhibitor ritonavir, may require discontinuation of the medication.<sup>162</sup> Pancreatitis is a more specific complication of individual drugs. As in other immunocompromised hosts treated with multiple medications, such as organ and marrow transplant patients, rates of toxic reactions ascribed to each drug may be confounded by concomitant administration of 2 or more drugs. Increased rates of adverse events, such as pancreatitis or hepatic toxicity, also may result from simultaneous administration of medications with overlapping toxicities. Moreover, differentiating the symptoms of drug toxicities from those of opportunistic infections may require careful evaluation of the timing of events and presence of comorbid findings.

### Primary Toxicities

Adverse effects of antiretroviral therapy may severely compromise effective patient care, particularly the ability to consistently reduce HIV-1 viral load, because of poor adherence with drug regimens. Such events may be more common among patients with advanced disease ( $CD4^+$  T cell  $< 200/\mu\text{L}$ ).<sup>170</sup> Rates of specific intestinal complications for each agent are summarized in Table 3. Among patients taking NRTI, gastrointestinal symptoms, including nausea, vomiting, abdominal pain, and diarrhea, occur in more than a quarter of patients. The inhibition of cellular DNA polymerases, including mitochondrial polymerase  $\gamma$ , with long-term therapy may result in mitochondrial toxicity and associated myopathic, neuropathic, hepatic, pancreatic, and hematologic complications.<sup>171–173</sup> Among those taking NNRTI, gastrointestinal and hepatic toxicities are not common. Mild rashes are the predominant side effect. Drug interactions with NNRTIs are related primarily to their effects as inducers of and substrates for the cytochrome P450 system. The most frequent dose-limiting toxicities with PIs are diarrhea, nausea, and abdominal discomfort. Hepatic toxicity is most often associated with ritonavir. The presence of chronic hepatitis B or hepatitis C may increase the rate but not necessarily the severity of hepatic effects<sup>162</sup>; these infections should not limit the initiation of HAART.

Recent attention has focused on a number of metabolic complications, particularly with any PI-containing regimen and, less often, with NRTIs. These abnormalities include (1) glucose intolerance, (2) elevations in triglyceride and cholesterol levels, and (3) an enigmatic and disturbing complication referred to as “lipodystrophy syndrome.” Patients with this last syndrome have increased abdominal fat; loss of peripheral subcutaneous fat, including that in the face, arms, legs, and buttocks; and the presence or absence of a “buffalo hump.” Women on therapy may experience breast enlargement. These conditions may occur concomi-

tantly or separately. Rates of observed fat redistribution are 17%–68% with PIs and 16% with dual NRTIs.<sup>141,171,174</sup> Mitochondrial dysfunction has been invoked as one potential unifying mechanism underlying these syndromes in patients taking PI-containing combination therapy.<sup>171,173</sup> The first 2 conditions may be treated with standard medical management, but whether discontinuation of medications will reverse the potentially disfiguring effects of the lipodystrophy syndrome is currently unclear.

Management of the adverse events with antiretroviral therapy may be complicated by the difficulties of identifying a specific inciting agent in a multidrug regimen. Because many of the toxic effects of antiretroviral medications may be worse early in the course of treatment and are dose dependent, lowering the dose in this period may allow therapy to continue. However, optimal antiretroviral activity is usually dose dependent, particularly with PIs, and development of resistance of HIV-1 is a very real danger, so monitoring of both clinical and virologic status is important. Changing antiretroviral agents may be preferable to lowering doses. Evaluation of the overlapping toxicities of different medications and their effects on drug metabolism may allow successful continuation of the most critical agents. In this regard, patients should be asked about other unrecorded or nontraditional agents they may be taking. Severe or prolonged complications require discontinuation of individual agents, as does the development of hypersensitivity reactions with abacavir. Gastrointestinal symptoms are common and may be quite difficult to resolve. Antidiarrheal agents, such as loperamide or diphenoxylate atropine, may be useful for drug-related diarrhea, as may antiemetics for vomiting. Taking medications with or after eating, when appropriate, may limit nausea. Histamine receptor blockers and antacids, although commonly prescribed, may affect absorption of some drugs and are usually ineffective.

### Drug Interactions

The majority of observed and proposed drug interactions associated with PI is related to its high affinity for, and thus inhibition of, several -450 isoenzymes. In addition to the medications shown in Table 3, a more complete list and discussion of drug interactions with PI is available from the manufacturer and in articles by Dolan et al.<sup>99</sup> and Burger et al.<sup>175</sup> Cisapride has potential life-threatening cardiotoxic effects in the presence of protease inhibitors, azole antifungals, and macrolides because of the ability of these agents to inhibit the hepatic metabolism of cisapride. Clinically significant interactions of PIs with rifampin/rifabutin, macrolides (erythromycin, clarithromycin, azithromycin), and azole antifungals (ketoconazole, fluconazole, and itraconazole) are highlighted in Table 3. The chelating

effects of didanosine, antacids, iron and calcium products, and sucralfate limit the absorption and levels of quinolone antibiotics, which are most commonly used for empiric and directed treatment of acute bacterial diarrhea.

In summary, the clinical care of HIV-1-infected patients has improved dramatically over the last decade because of greater understanding of the pathogenesis of the virus, more rapid clinical diagnosis of HIV-1 disease and its complications, and the availability of potent antimicrobial and antiretroviral agents to resolve and prevent opportunistic infections. Each advance brings new hope as well as new challenges, such as providing affordable therapy to all who need it and managing immunologic and clinical complications of HAART, particularly its enteric toxicity. The greatest challenge is to use newly gained insights into the pathogenesis of primary HIV-1 infection at mucosal sites to provide protection against the first exposure to the virus and against the subsequent irreversible decline in mucosal defense mechanisms.

## References

- Gao F, Bailes E, Robertson DL, et al. Origin of HIV-1 in the chimpanzee *Pan troglodytes*. *Nature* 1999;397:436–441.
- UNAIDS and WHO. Report on the global HIV/AIDS epidemic—June 1998. Geneva: UNAIDS/WHO, 1998:48–50.
- Royce RA, Sena A, Cates W Jr, Cohen MS. Sexual transmission of HIV. *N Engl J Med* 1997;336:1072–1078.
- Smith PD, Wahl SM. Immunobiology of mucosal HIV-1 infection. In: Ogra PH, Mestecky J, Lamm ME, Strober W, Biennenstock J, McGhee JR, eds. *Mucosal immunology*, 2nd ed. San Diego: Academic; 1999.
- Newell M-L. Mechanisms and timing of mother-to-child transmission of HIV-1. *AIDS* 1998;12:831–837.
- Maayan S, Soskoine V, Engelhard D, Moses A, Rahav G, Raveh D. Sexual behavior of homosexual and bisexual man attending an HIV testing clinic in Jerusalem. *Isr J Psychiatry Rel Sci* 1993;30:150–154.
- Schwarzc SK, Kellogg TA, Kohn RP, Katz MH, Lemp GF, Golan GA. Temporal trends in human immunodeficiency virus seroprevalence and sexual behavior at the San Francisco municipal sexually transmitted disease clinic. *Am J Epidemiol* 1995;142:314–322.
- Schacker T, Collier AC, Hughes J, Shea T, Corey L. Clinical and epidemiologic features of primary HIV infection. *Ann Intern Med* 1996;125:257–264.
- Jacquez JA, Koopman SJ, Simon CP, Longini IM. Role of the primary infection in epidemics of HIV infection in gay cohorts. *J Acquir Immune Defic Syndr* 1994;7:1169–1184.
- Kinloch-de Loes S, Hirschel BJ, Hoen B, et al. A controlled trial of zidovudine in primary human immunodeficiency virus infection. *N Engl J Med* 1995;333:408–413.
- Daar ES, Moudgil T, Meyer RD, Ho DD. Transient high levels of viremia in patients with primary human immunodeficiency virus type 1 infection. *N Engl J Med* 1991;324:961–964.
- Vernazza PL, Eron JJ, Cohen MS, van de Horst CM, Troiani L, Fiscus SA. Detection and biologic characterization of infectious HIV-1 in semen of seropositive men. *AIDS* 1994;8:1325–1329.
- Mellors J, Rinaldo CR Jr, Gupta P, White RM, Todd JA, Kingsley LA. Prognosis in HIV-1 infection predicted by the quantity of virus in plasma. *Science* 1996;272:1167–1170.
- Anderson DJ, O'Brien TR, Politch JA, et al. Effects of disease stage and zidovudine therapy on the detection of human immunodeficiency virus type 1 in semen. *JAMA* 1992;267:2769–2774.
- Krieger JN, Coombs RW, Collier AC, et al. Recovery of human immunodeficiency virus type 1 from semen: minimal impact of stage of infection and current antiviral therapy. *J Infect Dis* 1991;163:386–388.
- Krieger JN, Combs RW, Collier AC, Ross SO, Speck C, Corey L. Seminal shedding of human immunodeficiency virus type 1 and human cytomegalovirus: evidence for different immunologic controls. *J Infect Dis* 1995;171:1018–1022.
- Nelson KE, Rungtongthanakit K, Margolick J, et al. High rates of transmission of subtype E human immunodeficiency virus type 1 among heterosexual couples in northern Thailand: role of sexually transmitted diseases and immune compromise. *J Infect Dis* 1999;180:337–343.
- Clemetson DB, Moss GB, Willerford DM. Detection of HIV DNA in cervical and vaginal secretions: prevalence and correlates among women in Nairobi, Kenya. *JAMA* 1993;269:2860–2864.
- Cohen MS, Hoffman IF, Royce RA, et al. Reduction of concentration of HIV-1 in semen after treatment of urethritis: implications for prevention of sexual transmission of HIV-1. *Lancet* 1997;349:1868–1873.
- Fleming DT, Wasserheit JN. From epidemiologic synergy to public health policy and practice: the contribution of other sexually transmitted diseases to sexual transmission of HIV infection. *Sex Transm Infect* 1999;75:3–17.
- Zhu T, Wang N, Carr D, et al. Genetic characterization of human immunodeficiency virus type 1 in blood and genital secretions: evidence for viral compartmentalization and selection during sexual transmission. *J Virol* 1996;70:3098–3107.
- Ping LH, Cohen MS, Hoffman I, et al. Effects of genital tract inflammation on human immunodeficiency virus type 1 V3 populations in blood and semen. *J Virol* 2000;74:8946–8952.
- Quinn TC, Wawer MJ, Sewankambo N, et al. Viral load and heterosexual transmission of human immunodeficiency virus type 1. *N Engl J Med* 2000;342:921–929.
- Orenstein JM, Fox C, Wahl SM. Macrophages as a source of HIV during opportunistic infections. *Science* 1997;276:1857–1861.
- Huang Y, Paxton WA, Wolinsky SM, et al. The role of a mutant CCR5 allele in HIV-1 transmission and disease progression. *Nat Med* 1996;2:1240–1243.
- Dean M, Carrington M, Winkler C, et al. Genetic restriction of HIV-1 infection and progression to AIDS by a deletion allele of the CCR5 structural gene. *Science* 1996;273:1856–1862.
- Liu R, Paxton WA, Choe S, et al. Homozygous defect in HIV-1 coreceptor accounts for resistance of some multiply-exposed individuals to HIV-1 infection. *Cell* 1996;86:367–377.
- Samson M, Libert F, Doranz BJ, et al. Resistance to HIV-1 infection in Caucasian individuals bearing mutant alleles of the CCR-5 chemokine receptor gene. *Nature* 1996;382:722–725.
- Vittinghoff E, Scheer S, O'Malley P, Colfax G, Holmberg SD, Buchbinder SP. Combination antiretroviral therapy and recent declines in AIDS incidence and mortality. *J Infect Dis* 1999;179:717–720.
- Downs AM, De Vincenzi I. European Study Group in Heterosexual Transmission of HIV. Probability of heterosexual transmission of HIV: relationship to the number of unprotected sexual contacts. *J Acquir Immune Defic Syndr Hum Retrovirol* 1996;11:388–395.
- Halperin DT, Bailey RC. Male circumcision and HIV infection: 10 years and counting. *Lancet* 1999;354:1813–1815.
- Amerongen HM, Weltzin R, Farnet CM, Michetti P, Haseltine WA, Neutra MR. Transepithelial transport of HIV-1 by intestinal M cells: a mechanism for transmission of AIDS. *J Acquir Immune Defic Syndr* 1991;4:760–765.
- Baba TW, Trichel AM, An L, et al. Infection and AIDS in adult

- macaques after nontraumatic oral exposure to cell-free SIV. *Science* 1996;272:1486–1489.
34. Stahl-Hennig C, Steinman RM, Tenner-Racz K, et al. Rapid infection of oral mucosal-associated lymphoid tissue with simian immunodeficiency virus. *Science* 1999;285:126–129.
  35. O'Leary AD, Sweeney EC. Lymphoglandular complexes of the colon: structure and distribution. *Histopathology* 1986;10:267–283.
  36. Maric I, Holt PG, Perdue MH, Bienenstock J. Class II MHC antigen (Ia)-bearing dendritic cells in the epithelium of the rat intestine. *J Immunol* 1996;156:1408–1414.
  37. Kelsall BL, Strober W. Distinct populations of dendritic cells are present in the subepithelial dome and T cell regions of the murine Peyer's patch. *J Exp Med* 1996;183:237–247.
  38. Hussain LA, Lehner T. Comparative investigation of Langerhans' cells and potential receptors for HIV in oral, genitourinary and rectal epithelia. *Immunology* 1995;85:475–484.
  39. Frankel SS, Wenig BM, Burke AP, et al. Replication of HIV-1 in dendritic cell-derived syncytia at the mucosal surface of the adenoid. *Science* 1996;272:115–117.
  40. Geijtenbeek TBH, Kwon DS, Torensma R, et al. DC-SIGN, a dendritic cell-specific HIV-1-binding protein that enhances trans-infection of T cells. *Cell* 2000;100:587–597.
  41. Cameron PU, Freudenthal PS, Barker JM, Gezelter S, Inaba K, Steinman RM. Dendritic cells exposed to human immunodeficiency virus type-1 transmit a vigorous cytopathic infection to CD4+ T cells. *Science* 1992;257:383–387.
  42. Smith PD, Meng G, Sellers MT, Rogers T, Shaw GM. Biological parameters of HIV-1 infection in primary intestinal lymphocytes and macrophages. *J Leukoc Biol* 2000;68:360–365.
  43. Meng G, Sellers MT, Mosteller-Barnum M, Rogers TS, Shaw GM, Smith PD. Lamina propria lymphocytes, not macrophages, express CCR5 and CXCR4 and are the likely target cell for human immunodeficiency virus type 1 in the intestinal mucosa. *J Infect Dis* 2000;182:785–791.
  44. Pavli L, Hume D, Van de Pol E, Doe W. Dendritic cells, the major antigen-presenting cells of the human colonic lamina propria. *Immunology* 1993;78:132–141.
  45. Bomsel M. Transcytosis of infectious human immunodeficiency virus across a tight human epithelial cell line barrier. *Nat Med* 1997;3:42–47.
  46. Smith PD, Janoff EN, Mosteller-Barnum M, et al. Isolation and purification of CD14-negative mucosal macrophages from normal human small intestine. *J Immunol Meth* 1997;202:1–11.
  47. Meng G, Wu X, Wei X, et al. Intestinal epithelial cells express CCR5 and selectively transfer R5 HIV-1 to CCR5+ cells (submitted for publication).
  48. Harouse JM, Bhat S, Spitalnik SL, et al. Inhibition of entry of HIV-1 in neural cell lines by antibodies against galactosyl ceramide. *Science* 1991;253:320–323.
  49. Fantini J, Cook DG, Nathanson N, Spitalnik SL, Gonzalez-Scarano F. Infection of colonic epithelial cell lines by type 1 human immunodeficiency virus is associated with cell surface expression of galactosylceramide, a potential alternative gp 120 receptor. *Proc Natl Acad Sci U S A* 1993;90:2700–2704.
  50. Dwinell MB, Eckmann L, Leopard JD, Varki NM, Kagnoff MF. Chemokine receptor expression by human intestinal epithelial cells. *Gastroenterology* 1999;117:359–367.
  51. Jordan NJ, Kolios G, Abbot SE, et al. Expression of functional CXCR4 chemokine receptors on human colonic epithelial cells. *J Clin Invest* 1999;104:1061–1069.
  52. McNearey T, Hornickova Z, Markham R, et al. Relationship of human immunodeficiency virus type 1 sequence heterogeneity to stage of disease. *Proc Natl Acad Sci U S A* 1992;89:10247–10251.
  53. Wolinsky SM, Wike CM, Korber BTM, et al. Selective transmission of human immunodeficiency virus type-1 variants from mothers to infants. *Science* 1992;255:1134–1137.
  54. Zhu T, Mo H, Wang N, et al. Genotypic and phenotypic characterization of HIV-1 in patients with primary infection. *Science* 1993;261:1179–1181.
  55. Dragic T, Litwin V, Allaway GP, et al. HIV-1 entry into CD4+ cells is mediated by the chemokine receptor CC-CKR-5. *Nature* 1996;381:667–673.
  56. Lu Z-H, Chen Y-H, Turner JD, et al. Evolution of HIV-1 coreceptor usage through interactions with distinct CCR5 and CXCR4 domains. *Proc Natl Acad Sci U S A* 1997;94:6426–6431.
  57. Smith PD, Meng G, Shaw GM, Li L. Infection of gastrointestinal macrophages by HIV-1. *J Leukoc Biol* 1997;62:72–77.
  58. Li L, Meng G, Graham MF, Shaw GM, Smith PD. Intestinal macrophages display reduced permissiveness to human immunodeficiency virus 1 and decreased surface CCR5. *Gastroenterology* 1999;116:1043–1053.
  59. Smith PD, Fox CH, Masur H, Winter HS, Alling DW. Quantitative analysis of mononuclear cells expressing HIV-1 RNA in esophageal mucosa. *J Exp Med* 1994;180:1541–1546.
  60. Schneider T, Jahn HU, Schmidt W, et al. Loss of CD4 T lymphocytes in patients infected with immunodeficiency virus type 1 is more pronounced in the duodenal mucosa than in the peripheral blood. *Gut* 1995;37:524–529.
  61. Clayton F, Snow G, Reka S, Kotler DP. Selective depletion of rectal lamina propria rather than lymphoid aggregate CD4 lymphocytes in HIV infection. *Clin Exp Immunol* 1997;107:288–292.
  62. Veazey RS, DeMaria M, Chalifoux LV, et al. Gastrointestinal tract as a major site of CD4+ T cell depletion and viral replication in SIV infection. *Science* 1998;280:427–431.
  63. Kewenig S, Schneider T, Hohloch K, et al. Rapid mucosal CD4(+) T-cell depletion and enteropathy in simian immunodeficiency virus-infected rhesus macaques. *Gastroenterology* 1999;116:1115–1123.
  64. Zeitz M, Greene WC, Peffer NJ, James SP. Lymphocytes isolated from the intestinal lamina propria of normal nonhuman primates have increased expression of genes associated with T-cell activation. *Gastroenterology* 1988;94:647–655.
  65. Schieferdecker HL, Ullrich R, Hirsland H, Zeitz M. T cell differentiation antigens on lymphocytes in the human intestinal lamina propria. *J Immunol* 1992;149:2816–2822.
  66. McNeely TB, Dealy M, Dripps DJ, Orenstein JM, Eisenberg SP, Wahl SM. Secretory leukocyte protease inhibitor: a human saliva protein exhibiting anti-human immunodeficiency virus 1 activity in vitro. *J Clin Invest* 1995;96:456–464.
  67. McNeely TB, Shugars DC, Rosendahl M, Tucker C, Eisenberg SP, Wahl SM. Inhibition of HIV-1 infectivity by secretory leukocyte protease inhibitor occurs prior to viral reverse transcription. *Blood* 1997;90:1141–1149.
  68. Lim SG, Condez A, Lee CA, Johnson MA, Elia C, Poulter LW. Loss of mucosal CD4 lymphocytes is an early feature of HIV infection. *Clin Exp Immunol* 1993;92:448–454.
  69. Rodgers VD, Fassett R, Kagnoff MF. Abnormalities in intestinal mucosal T cells in homosexual populations including those with the lymphadenopathy syndrome and acquired immunodeficiency syndrome. *Gastroenterology* 1986;90:552–558.
  70. Sniijders F, Meenan J, van den Blink B, van Deventer SJ, ten Kate FJ. Duodenal intraepithelial and lamina propria T lymphocytes in human immunodeficiency virus-infected patients with and without diarrhoea. *Scand J Gastroenterol* 1996;31:1176–1181.
  71. Greenspan D. Oral manifestations of HIV infection. In: Robertson PB, Greenspan JS, eds. *Oral manifestations of AIDS*. Littleton, MA: PSG Publishing, 1988.
  72. Smith PD, Quinn TC, Strober W, Janoff EN, Masur H. Gastrointestinal infections in AIDS. *Ann Intern Med* 1992;116:63–77.
  73. Ullrich R, Zeitz M, Heise W, L'age M, Höffken G, Riecken EO. Small intestinal structure and function in patients infected with human immunodeficiency virus (HIV): evidence for HIV-induced enteropathy. *Ann Intern Med* 1989;111:15–21.

74. Riecken EO, Zeitz M, Ullrich R. Non-opportunistic causes of diarrhoea in HIV infection. *Baillieres Clin Gastroenterol* 1990; 4:385-403.
75. Ullrich R, Zeitz M, Heise W, et al. Mucosal atrophy is associated with loss of activated T cells in the duodenal mucosa of human immunodeficiency virus (HIV)-infected patients. *Digestion* 1990; 46(suppl 2):302-307.
76. Ullrich R, Riecken E-O, Zeitz M. Human immunodeficiency virus-induced enteropathy. *Immunol Res* 1991;10:456-464.
77. Wilcox CM, Mönkemüller KE. Diagnosis and management of esophageal disease in the acquired immunodeficiency syndrome. *South Med J* 1998;91:1002-1008.
78. Forrest DM, Seminari E, Hogg RS, et al. The incidence and spectrum of AIDS-defining illnesses in persons treated with antiretroviral drugs. *Clin Infect Dis* 1998;27:1379-1385.
79. Rabeneck L, Crane MM, Risser JMH, Lacke CE, Wray NP. Effect of HIV transmission category and CD4 count on the occurrence of diarrhea in HIV-infected patients. *Am J Gastroenterol* 1993; 88:1720-1723.
80. Flanigan T, Whalen C, Turner J, et al. *Cryptosporidium* infection and CD4 counts. *Ann Intern Med* 1992;116:840-842.
81. Colebunders R, Francis H, Mann JM, et al. Persistent diarrhea, strongly associated with HIV infection in Kinshasa, Zaire. *Am J Gastroenterol* 1987;82:859-864.
82. Malebranche R, Arnoux E, Guérin JM, et al. Acquired immunodeficiency syndrome with severe gastrointestinal manifestations in Haiti. *Lancet* 1983;2:873-878.
83. Serwadda D, Mugerwa RD, Sewankambo NK, et al. Slim disease: a new disease in Uganda and its association with HTLV-III infection. *Lancet* 1985;1:849-852.
84. Janoff EN. Diarrheal disease with viral enteric infections in immunocompromised patients. In: Owen RL, Surawicz C, eds. *Gastrointestinal and hepatic infections*. Philadelphia: Saunders, 1995:93-120.
85. Smith PD, Wilcox CM. Gastrointestinal complications of the acquired immunodeficiency syndrome. In: Yamada T, Alpers DH, Laine L, Owyang C, Powell DW, eds. *Textbook of gastroenterology*. Philadelphia: Lippincott Williams & Wilkins, 1999:2400-2414.
86. Wilcox CM, Mönkemüller KE. Gastrointestinal disease. In: Dolin R, Masur H, Saag MS, eds. *AIDS Therapy*. Philadelphia: Churchill Livingstone, 1999:752-765.
87. Bellosillo NA, Gorbach SL. Diarrhea and HIV infection. *Infect Dis Clin Prac* 1998;7:213-219.
88. Flanigan TP. *Cryptosporidium*, *Isospora*, and *Cyclospora* infections. In: Dolin R, Masur H, Saag MS, eds. *AIDS therapy*. Philadelphia: Churchill Livingstone, 1999:328-335.
89. Laughon BE, Druckman DA, Vernon A, et al. Prevalence of enteric pathogens in homosexual men with and without acquired immunodeficiency syndrome. *Gastroenterology* 1988;94: 984-993.
90. Smith PD, Lane C, Gill VJ, et al. Intestinal infections in patients with the acquired immunodeficiency syndrome (AIDS): etiology and response to therapy. *Ann Intern Med* 1988;108:328-333.
91. Blanshard C, Gazzard BG. Natural history and prognosis of diarrhoea of unknown cause in patients with acquired immunodeficiency syndrome (AIDS). *Gut* 1995;36:283-286.
92. Blanshard C, Francis N, Gazzard BG. Investigation of chronic diarrhoea in acquired immunodeficiency syndrome: a prospective study of 155 patients. *Gut* 1996;39:824-832.
93. Crotty B, Smallwood RA. Investigating diarrhea in patients with acquired immunodeficiency syndrome. *Gastroenterology* 1996; 110:296-298.
94. Johanson JF. To scope or not to scope: the role of endoscopy in the evaluation of AIDS-related diarrhea. *Am J Gastroenterol* 1996;91:2261-2262.
95. Rinder H, Janitschke K, Aspöck H, et al. A blinded, externally controlled multicenter evaluation for the detection of microsporidia by light microscopy and PCR. *J Clin Microbiol* 1998;36: 1814-1818.
96. Weber R, Ledergerber B, Zbinden R, et al. Enteric infections and diarrhea in human immunodeficiency virus-infected persons. *Arch Intern Med* 1999;159:1473-1480.
97. Thea DM, St. Louis ME, Atido U, et al. A prospective study of diarrhea and HIV-1 infection among 429 Zairian infants. *N Engl J Med* 1993;329:1696-1702.
98. Thea DM, Glass R, Grohmann GS, et al. Prevalence of enteric viruses among hospital patients with AIDS in Kinshasa, Zaire. *Trans R Soc Trop Med Hyg* 1993;87:263-266.
99. Dolin R, Masur H, Saag MS. *AIDS therapy*. Philadelphia, Pennsylvania: Churchill Livingstone; 1999.
100. Gilbert DN, Moellering J, Sande MA. *Sanford guide to antimicrobial therapy*. 30th ed. Hyde Park, VT: Antimicrobial Therapy, 2000.
101. Bartlett JG, Gallant JE. *Medical management of HIV infection*. Baltimore, MD: Port City, 2000.
102. Fischl MA, Richman DD, Grieco MH, et al. The efficacy of azidothymidine (AZT) in the treatment of patients with AIDS and AIDS-related complex. *N Engl J Med* 1987;317:185-191.
103. Gulick RM, Mellors JW, Havlir D, et al. Treatment with indinavir, zidovudine, and lamivudine in adults with human immunodeficiency virus infection and prior antiretroviral therapy. *N Engl J Med* 1997;337:734-739.
104. Gulick RM. Assessing the benefits of antiretroviral therapy (editorial). *Ann Intern Med* 2000;133:471-473.
105. Hammer SM, Squires KE, Hughes MD, et al. A controlled trial of two nucleoside analogues plus indinavir in persons with human immunodeficiency virus infection and CD4 cell counts of 200 per cubic millimeter or less. *N Engl J Med* 1997;337: 725-733.
106. Mocroft A, Katlama C, Johnson AM, et al. AIDS across Europe, 1994-98: the EuroSIDA Study. *Lancet* 2000;356:291-296.
107. Palella FJ Jr, Delaney KM, Moorman AC, et al. Declining morbidity and mortality among patients with advanced human immunodeficiency virus infection. *N Engl J Med* 1998;338:853-860.
108. Deeks SG, Smith M, Holodniy M, Kahn JO. HIV-1 protease inhibitors. A review for clinicians. *JAMA* 1997;277:145-153.
109. Centers for Disease Control. Revision of the CDC surveillance case definition for acquired immunodeficiency syndrome. *MMWR* 1987;36(suppl 1S):1S-15S.
110. Mellors JW, Kingsley LA, Rinaldo CRJ, et al. Quantitation of HIV-1 RNA in plasma predicts outcome after seroconversion. *Ann Intern Med* 1995;122:573-579.
111. Kaplan JE, Hanson D, Dworkin MS, et al. Epidemiology of human immunodeficiency virus-associated opportunistic infections in the United States in the era of highly active antiretroviral therapy. *Clin Infect Dis* 2000;30:S5-S14.
112. Salmon D, Detruichis P, Lepout C, et al. Efficacy of zidovudine in preventing relapses of salmonella bacteremia in AIDS. *J Infect Dis* 1991;163:415-416.
113. Levine WC, Buehler JW, Bean NH, Tauxe RV. Epidemiology of nontyphoidal *Salmonella* bacteremia during the human immunodeficiency virus epidemic. *J Infect Dis* 1991;164:81-87.
114. Fischl MA, Dickinson GM, Sinave C, Pitchenik, Cleary TJ. *Salmonella* bacteremia as manifestation of acquired immunodeficiency syndrome. *Arch Intern Med* 1986;146:113-115.
115. Glaser JB, Morton-Kute L, Berger SR, et al. Recurrent *Salmonella typhimurium* bacteremia associated with the acquired immunodeficiency syndrome. *Ann Intern Med* 1985;102:189-193.
116. Jacobs JL, Gold JWM, Murray HW, Roberts RB, Armstrong D. *Salmonella* infections in patients with the acquired immunodeficiency syndrome. *Ann Intern Med* 1985;102:186-188.
117. Jacobson MA, Hahn SM, Gerberding JL, Lee B, Sande MA. Ciprofloxacin for salmonella bacteremia in the acquired immunodeficiency syndrome (AIDS). *Ann Intern Med* 1989;110:1027-1029.

118. Nelson MR, Shanson DC, Hawkins DA, Gazzard BG. Salmonella, Campylobacter and Shigella in HIV-seropositive patients. *AIDS* 1992;6:1495-1498.
119. Smith PD, Macher AM, Bookman MA, et al. *Salmonella typhimurium* enteritis and bacteremia in the acquired immunodeficiency syndrome. *Ann Intern Med* 1985;102:207-209.
120. Autran B, Carcelain G, Li TS, et al. Positive effects of combined antiretroviral therapy on CD4+ T cell homeostasis and function in advanced HIV disease. *Science* 1997;277:112-116.
121. Cavert W, Notermans DW, Staskus K, et al. Kinetics of response in lymphoid tissues to antiretroviral therapy of HIV-1 infection. *Science* 1997;276:960-964.
122. Pontesilli O, Kerkhof-Garde S, Notermans DW, et al. Functional T cell reconstitution and human immunodeficiency virus-1-specific cell-mediated immunity during highly active antiretroviral therapy. *J Infect Dis* 1999;180:76-86.
123. Zhang ZQ, Notermans DW, Sedgewick G, et al. Kinetics of CD4+ T cell repopulation of lymphoid tissues after treatment of HIV-1 infection. *Proc Natl Acad Sci U S A* 1998;95:1154-1159.
124. Michelet C, Arvieux C, Francois C, et al. Opportunistic infections occurring during highly active antiretroviral treatment. *AIDS* 1998;12:1815-1822.
125. Centers for Disease Control and Prevention. USPHS/IDSA guidelines for the prevention of opportunistic infections in persons infected with human immunodeficiency virus. *MMWR Morb Mortal Wkly Rep* 1999;48:RR-106.
126. Currier JS, Williams PL, Koletar SL, et al. Discontinuation of *Mycobacterium avium* complex prophylaxis in patients with antiretroviral therapy-induced increases in CD4+ cell count. *Ann Intern Med* 2000;133:493-503.
127. Furrer H, Egger M, Opravil M, et al. Discontinuation of primary prophylaxis against *Pneumocystis carinii* pneumonia in HIV-1-infected adults treated with combination antiretroviral therapy. *N Engl J Med* 1999;340:1301-1306.
128. Furrer H, Opravil M, Bernasconi E, Telenti A, Egger M, for the Swiss HIV Cohort Study. Stopping primary prophylaxis in HIV-1-infected patients at high risk of toxoplasma encephalitis. *Lancet* 2000;355:2217-2218.
129. Mussini C, Pezzotti P, Govoni A, et al. Discontinuation of primary prophylaxis for *Pneumocystis carinii* pneumonia and toxoplasmic encephalitis in human immunodeficiency virus type 1-infected patients: the changes in opportunistic prophylaxis study. *J Infect Dis* 2000;181:1635-1642.
130. Hutin Y, Molina JM, Casin I, et al. Risk factors for *Clostridium difficile*-associated diarrhoea in HIV-infected patients. *AIDS* 1993;7:1441-1447.
131. Tacconelli E, Tumbarello M, de Gaetano Donati K, Leone F, Mazzella P, Cauda R. *Clostridium difficile*-associated diarrhea in human immunodeficiency virus infection—a changing scenario (letter). *Clin Infect Dis* 1999;28:936-937.
132. Mattapallil JJ, Smit-McBride Z, Dailey P, Dandekar S. Activated memory CD4(+) T helper cells repopulate the intestine early following antiretroviral therapy of simian immunodeficiency virus-infected rhesus macaques but exhibit a decreased potential to produce interleukin-2. *J Virol* 1999;73:6661-6669.
133. Kotler DP, Shimada T, Snow G, et al. Effect of combination antiretroviral therapy upon rectal mucosal HIV RNA burden and mononuclear cell apoptosis. *AIDS* 1998;12:597-604.
134. Schmidt W, Wahnschaffe U, Schäfer M, et al. Rapid increase of mucosal CD4 T-cells followed by clearance of intestinal cryptosporidiosis in an AIDS patient receiving highly active antiretroviral therapy indicating effective mucosal immune reconstitution. *Gastroenterology* 2000 (in press).
135. Greenberg RE, Mir R, Bank S, Siegal FP. Resolution of intestinal cryptosporidiosis after treatment of AIDS with AZT. *Gastroenterology* 1989;97:1327-1330.
136. Chandrasekar PH. "Cure" of chronic cryptosporidiosis during treatment with azidothymidine in a patient with the acquired immune deficiency syndrome. *Am J Med* 1987;83:187.
137. Manabe YC, Clark DP, Moore RD, et al. Cryptosporidiosis in patients with AIDS: correlates of disease and survival. *Clin Infect Dis* 1998;27:536-542.
138. Janoff EN, Limas C, Gebhard RL, Penley KA. Cryptosporidial carriage without symptoms in the acquired immunodeficiency syndrome (AIDS). *Ann Intern Med* 1990;112:75-76.
139. Zar F, Geiseler PJ, Brown VA. Asymptomatic carriage of *Cryptosporidium* in the stool of a patient with acquired immunodeficiency syndrome. *J Infect Dis* 1985;151:195.
140. Foudraine NA, Weverling GJ, van Gool T, et al. Improvement of chronic diarrhoea in patients with advanced HIV-1 infection during potent antiretroviral therapy. *AIDS* 1998;12:35-41.
141. Carr A, Marriott D, Field A, Vasak E, Cooper DA. Treatment of HIV-1-associated microsporidiosis and cryptosporidiosis with combination antiretroviral therapy. *Lancet* 1998;351:256-261.
142. Ragni MV, Bontempo FA. Increase in hepatitis C virus load in hemophiliacs during treatment with highly active antiretroviral therapy. *J Infect Dis* 1999;180:2027-2029.
143. Beld M, Penning M, Lukashov V, et al. Evidence that both HIV and HIV-induced immunodeficiency enhance HCV replication among HCV seroconverters. *Virology* 1998;244:504-512.
144. Bonacini M, Govindarajan S, Blatt LM, Schmid P, Conrad A, Lindsay KL. Patients co-infected with human immunodeficiency virus and hepatitis C virus demonstrate higher levels of hepatic HCV RNA. *J Virol Hep* 1999;6:203-208.
145. Darby SC, Ewart DW, Giangrande PL, et al. Mortality from liver cancer and liver disease in haemophilic men and boys in UK given blood products contaminated with hepatitis C. UK Haemophilia Centre Directors' Organisation. *Lancet* 1997;350:1425-1431.
146. Eyster ME, Fried MW, Di Bisceglie AM, Goedert JJ. Increasing hepatitis C virus RNA levels in hemophiliacs: relationship to human immunodeficiency virus infection and liver disease. Multicenter Hemophilia Cohort Study. *Blood* 1994;84:1020-1023.
147. Sulkowski MS, Mast EE, Seeff LB, Thomas DL. Hepatitis C virus infection as an opportunistic disease in persons infected with human immunodeficiency virus. *Clin Infect Dis* 2000;30(suppl 1):S77-S84.
148. Macias J, Pineda JA, Leal M, et al. Influence of hepatitis C virus infection on the mortality of antiretroviral-treated patients with HIV disease. *Eur J Clin Microbiol Infect Dis* 1998;17:167-170.
149. Greub G, Ledergerber B, Battegay M, et al. Clinical progression, survival, and immune recovery during antiretroviral therapy in patients with HIV-1 and hepatitis C virus coinfection: the Swiss HIV Cohort Study. *Lancet* 2000;356:1800-1805.
150. Soriano V, Rodriguez-Rosado R, Garcia-Samaniego J. Management of chronic hepatitis C in HIV-infected patients. *AIDS* 1999;13:539-546.
151. Dieterich DT, Purow JM, Rajapaksa R. Activity of combination therapy with interferon alfa-2b plus ribavirin in chronic hepatitis C patients co-infected with HIV. *Semin Liver Dis* 1999;19:87-94.
152. Mauss S, Klinker H, Ulmer A, et al. Response to treatment of chronic hepatitis C with interferon alpha in patients infected with HIV-1 is associated with higher CD4+ cell count. *Infection* 1998;26:16-19.
153. Sulkowski M. The treatment of chronic HCV infection in HIV-infected persons (abstr S11). 7th Conference on Retroviruses and Opportunistic Infections, San Francisco, CA, 2000.
154. Poynard T, Marcellin P, Lee SS, et al. Randomised trial of interferon alpha2b plus ribavirin 48 weeks or for 24 weeks versus interferon alpha2b plus placebo for 48 weeks for treatment of chronic infection with hepatitis C virus. International Hepatitis Therapy Group. *Lancet* 1998;352:1426-1432.
155. Fialaire P, Payan C, Vitour D, et al. Sustained disappearance of

- hepatitis C viremia in patients receiving protease inhibitor treatment for human immunodeficiency virus infection. *J Infect Dis* 1999;180:574–575.
156. Puoti M, Gargiulo F, Roldan EQ, et al. Liver damage and kinetics of hepatitis C virus and human immunodeficiency virus replication during the early phases of combination antiretroviral treatment. *J Infect Dis* 2000;181:2033–2036.
  157. Rutschmann OT, Negro F, Hirschel B, Hadengue A, Anwar D, Perrin LH. Impact of treatment with human immunodeficiency virus (HIV) protease inhibitors on hepatitis C viremia in patients coinfecting with HIV. *J Infect Dis* 1998;177:783–785.
  158. Zylberberg H, Chaix M-L, Rabian C, et al. Tritherapy for human immunodeficiency virus infection does not modify replication of hepatitis C virus in coinfecting subjects. *Clin Infect Dis* 1998; 26:1104–1106.
  159. Perez-Olmeda M, Garcia-Samaniego J, Soriano V. Hepatitis C viraemia in HIV-HCV co-infected patients having immune restoration with highly active antiretroviral therapy (letter). *AIDS* 2000;14:212.
  160. Arribas JR, Ibanez C, Ruiz-Antoran B, et al. Acute hepatitis in HIV-infected patients during ritonavir treatment. *AIDS* 1998;12: 722–723.
  161. John M, Flexman J, French MA. Hepatitis C virus-associated hepatitis following treatment of HIV-infected patients with HIV protease inhibitors: an immune restoration disease? *AIDS* 1998;12:2289–2293.
  162. Sulkowski MS, Thomas DL, Chaisson RE, Moore RD. Hepatotoxicity associated with antiretroviral therapy in adults infected with human immunodeficiency virus and the role of hepatitis C or B virus infection. *JAMA* 2000;283:74–80.
  163. Bräu N, Leaf HL, Wiczorek RL, Margolis DM. Severe hepatitis in three AIDS patients treated with indinavir (letter). *Lancet* 1997;349:924.
  164. French MAH. Antiretroviral therapy immune restoration disease in HIV-infected patients with HAART. *AIDS Reader* 1999;9:548–562.
  165. DeSimone JA, Pomerantz RJ, Babinchak TJ. Inflammatory reactions in HIV-1-infected persons after initiation of highly active antiretroviral therapy. *Ann Intern Med* 2000;133:447–454.
  166. Cinti SK, Kaul DR, Sax PE, Crane LR, Kazanjian PH. Recurrence of *Mycobacterium avium* infection in patients receiving highly active antiretroviral therapy and antimycobacterial agents. *Clin Infect Dis* 2000;30:511–514.
  167. Lucas GM, Chaisson RE, Moore RD. Highly active antiretroviral therapy in a large urban clinic: risk factors for virologic failure and adverse drug reactions. *Ann Intern Med* 1999;131:81–87.
  168. Volberding PA, Deeks SG. Antiretroviral therapy for HIV infection: promises and problems. *JAMA* 1998;279:1343–1344.
  169. Shapiro MF, Morton SC, McCaffrey DF, et al. Variations in the care of HIV-infected adults in the United States: results from the HIV Cost and Services Utilization Study. *JAMA* 1999;281:2305–2315.
  170. Jones JL, Hanson DL, Dworkin MS, et al. Surveillance for AIDS-defining opportunistic illnesses. 1992-1997. *CDC Surveillance Summaries. MMWR Morb Mortal Wkly Rep* 1999;48:1–22.
  171. Max B, Sherer R. Management of the adverse effects of antiretroviral therapy and medication adherence. *Clin Infect Dis* 2000;30(suppl 2):S96–S116.
  172. Brinkman K, ter Hofstede HJ, Burger DM, Smeitink JA, Koopmans PP. Adverse effects of reverse transcriptase inhibitors: mitochondrial toxicity as common pathway. *AIDS* 1998;12:1735–1744.
  173. Brinkman K, Smeitink JA, Romijn JA, Reiss P. Mitochondrial toxicity induced by nucleoside-analogue reverse-transcriptase inhibitors is a key factor in the pathogenesis of antiretroviral-therapy-related lipodystrophy. *Lancet* 1999;354:1112–1115.
  174. Carr A, Samaras K, Chisholm DJ, Cooper DA. Pathogenesis of HIV-1-protease inhibitor-associated peripheral lipodystrophy, hyperlipidaemia, and insulin resistance. *Lancet* 1998;351:1881–1883.
  175. Burger DM, Hoetelmans RMW, Koopman PP, et al. Clinically relevant drug interactions with antiretroviral agents. *Antiviral Ther* 1997;2:149.
  176. Janoff EN, Smith PD. Perspectives on gastrointestinal infections in AIDS. *Gastroenterol Clin North Am* 1988;17:451–463.
  177. Janoff EN, Orenstein JM, Manischewitz JF, Smith PD. Adenovirus colitis in the acquired immunodeficiency syndrome. *Gastroenterology* 1991;100:976–979.
  178. Wanke CA, Mayer H, Weber R, Zbinden R, Watson DA, Acheson D. Enterococcal *Escherichia coli* as a potential cause of diarrheal disease in adults infected with human immunodeficiency virus. *J Infect Dis* 1998;178:185–190.
  179. Perlman DM, Ampel NM, Schiffman RB, et al. Persistent *Campylobacter jejuni* infections in patients infected with human immunodeficiency virus (HIV). *Ann Intern Med* 1988;108:540–546.
  180. Gurtman A, Szabo S, Rose D, Mayer H, Sacks H. Comparison of *Clostridium difficile* diarrhea (CdD) in hospitalized HIV seropositive (HIV+) and HIV seronegative (HIV-) patients. The 32nd Interscience Conference on Antimicrobial Agents and Chemotherapy. Anaheim, CA, October 11–14, 1992.
  181. Grohmann GS, Glass RI, Pereira HG, et al. Enteric viruses and diarrhea in HIV-infected patients. *N Engl J Med* 1993;329: 14–20.
  182. Cheung ANY, Ng IOL. Cytomegalovirus infection of the gastrointestinal tract in non-AIDS patients. *Am J Gastroenterol* 1993; 88:1882–1886.
  183. Schmidt W, Schneider T, Heise W, Berlin Diarrhea/Wasting Syndrome Study Group. Stool viruses, coinfections, and diarrhea in HIV-infected patients. *J Acquir Immune Defic Syndr* 1996;13:33–38.
  184. Kartalija M, Sande MA. Diarrhea and AIDS in the era of highly active antiretroviral therapy. *Clin Infect Dis* 1999;28:701–707.
  185. Didier ES. Microsporidiosis. *Clin Infect Dis* 1998;27:1–8.
  186. Dore GJ, Marriott DJ, Hing MC, Harkness JL, Field AS. Disseminated microsporidiosis due to *Septata intestinalis* in nine patients infected with the human immunodeficiency virus: response to therapy with albendazole. *Clin Infect Dis* 1995;21: 70–76.
  187. Wilcox CM, Chalasani N, Lazenby A, Schwartz DA. Cytomegalovirus colitis in acquired immunodeficiency syndrome: a clinical and endoscopic study. *Gastrointest Endosc* 1998;48:39–43.
  188. Goguel J, Katlama C, Sarfati C, Maslo C, Lepout C, Molina JM. Remission of AIDS-associated intestinal microsporidiosis with highly active antiretroviral therapy (letter). *AIDS* 1997;11:1658–1659.
  189. Beach JW. Chemotherapeutic agents for human immunodeficiency virus infection: mechanism of action, pharmacokinetics, metabolism, and adverse reactions. *Clin Ther* 1998;20:2–25.
  190. Moore RD, Fortgang I, Keruly J, Chaisson RE. Adverse events from drug therapy for human immunodeficiency virus disease. *Am J Med* 1996;101:34–40.
  191. Carr A, Cooper DA. Adverse effects of antiretroviral therapy. *Lancet* 2000;356:1423–1430.

---

Received October 25, 2000. Accepted December 15, 2000.

Address requests for reprints to: Phillip D. Smith, M.D., Division of Gastroenterology, University of Alabama at Birmingham, 703 19th Street S., ZRB 633, Birmingham, Alabama 35294-0007. Fax: (205) 934-8493.

Funded in part by the Veterans Affairs Research Service, the Center for Mucosal and Vaccine Biology, Minneapolis Veterans Affairs Medical Center, and National Institutes of Health grants AI-39445, DE-72621, DK-47322, HL-57880, and AI-41530.