

Injection site lipodystrophy and the endocrinologist

Sir,

A 7-year-old boy diagnosed to have Dandy–Walker syndrome was referred for evaluation of short stature. He had previously undergone ventriculo-peritoneal shunting at 2 years of age. His growth velocity in the preceding year was 2 cm. His height was 95 cm (height age 4 years, height SDS -2.19 , target paternal height 163 cm), weight was 15 kg (weight age 5 years, weight SDS -1.0), bone age was 4.6 years, and head circumference was 60 cm. Hematological and biochemical parameters were normal. Free triiodothyronine was 2.2 (2.4–4.2) pg/mL, free thyroxine was 0.55 (0.8–2.1) ng/mL, and thyroid stimulating hormone was 0.09 (0.5–6.5) μ U/mL, suggestive of secondary hypothyroidism. Stimulated cortisol (post ACTH) was 20.3 μ g/dL. He was started on thyroxine replacement. Once euthyroidism was achieved, growth hormone (GH) stimulation tests were performed. Insulin tolerance test and clonidine stimulation test revealed GH levels of 2.1 ng/mL and 3.3 ng/mL, respectively. He was initiated on GH therapy. The child and the parents were educated about the injection technique. At periodic review at 9 months after GH was started, examination of abdomen revealed cutaneous hypertrophy on the abdomen on either side of the umbilicus [Figure 1a]. On enquiring about the injection technique, parents reported that they injected GH at fixed places. They were counseled to avoid injecting in these areas and follow rotation technique. The boy was reviewed at 6 months subsequently and lipohypertrophy had subsided [Figure 1b]. He has gained 12 cm after being initiated on GH.

The list of drugs causing localized lipodystrophy is widening. Insulin is well known to cause lipodystrophy – either hypertrophy (due to anabolic actions) or atrophy (local immune reaction to crystals of impure insulin). GH inhibits adipocyte differentiation, reduces triglyceride accumulation, and increases lipolysis which reduces adipose

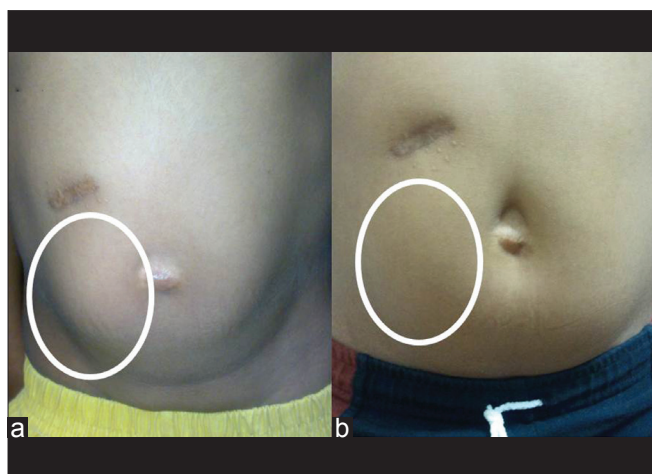


Figure 1: (a) Injection site hypertrophy seen in the encircled area. (b) Resolution of hypertrophy avoiding the site for GH injections. Also seen is the scar mark of ventriculo-peritoneal shunt

tissue mass.^[1] It would be logical to expect lipoatrophy with prolonged GH injection as evidenced by clinical studies using daily GH or once weekly pegylated GH preparation.^[2] However, lipohypertrophy described in the case above represents a paradox which has been infrequently reported previously.^[3,4] Cells are capable of synthesizing insulin like growth factor 1 (IGF-1). IGF-1 can act in autocrine/paracrine manner to induce adipocyte hypertrophy acting through IGF-1 receptors present on adipocyte. IGF-1 is also known to be a potent regulator of pre-adipocyte proliferation.^[5] With these evidences, one can postulate that chronic stimulation of subcutaneous adipocytes by GH injected might increase the local production of IGF-1 which would result in lipohypertrophy as seen in our patient. And the absence of this stimulus resulted in regression of lipohypertrophy.

Other injectable drugs concerned with endocrinology as they are known to cause lipodystrophy are corticosteroids (atrophy), octreotide (atrophy), pegvisomant (hypertrophy), and IGF-1 (hypertrophy).

This case should alert the clinician regarding lipodystrophy, which can hamper optimal drug absorption, occurring with commonly used injectable medications. The injection site should be periodically examined and the patient should be counseled about the rotation technique of injection.

**Abhay Gundgurthi, Manoj K. Dutta, Rajiv Pakhetra,
M. K. Garg**

Department of Endocrinology, Army Hospital (Research and Referral), Delhi Cantonment, India

Corresponding Author: Dr. M. K. Garg,
Department of Endocrinology, Army Hospital (Research and Referral),
Delhi Cantonment – 110010, India.
E-mail: mkgargs@gmail.com

REFERENCES

1. Richelsen B. Action of growth hormone in adipose tissue. *Horm Res* 1997;48 Suppl 5:105-10.
2. Touraine P, D'Souza GA, Kourides I, Abs R, Barclay P, Xie R, *et al.* Lipoatrophy in GH deficient patients treated with a long-acting pegylated GH. *Eur J Endocrinol* 2009;161:533-40.
3. Ruvalcaba RH, Klutter KB. Abdominal lipohypertrophy caused by injections of growth hormone: A case report. *Pediatrics* 1998;102:408-10.
4. Mersebach H, Feldt-Rasmussen UF. Localized hypertrophy during growth hormone therapy. *Ugeskr Laeger* 2002;164:1930-2.
5. Holly J, Sabin M, Perks C, Shield J. Adipogenesis and IGF-1. *Metab Syndr Relat Disord* 2006;4:43-50.

Access this article online

Quick Response Code:



Website:
www.ijem.in

DOI:
10.4103/2230-8210.95729