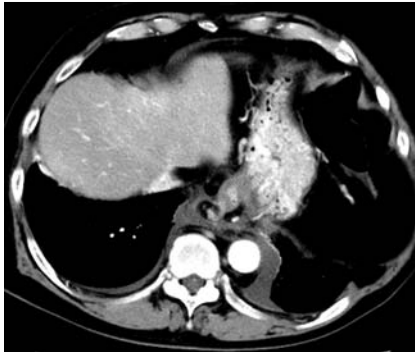
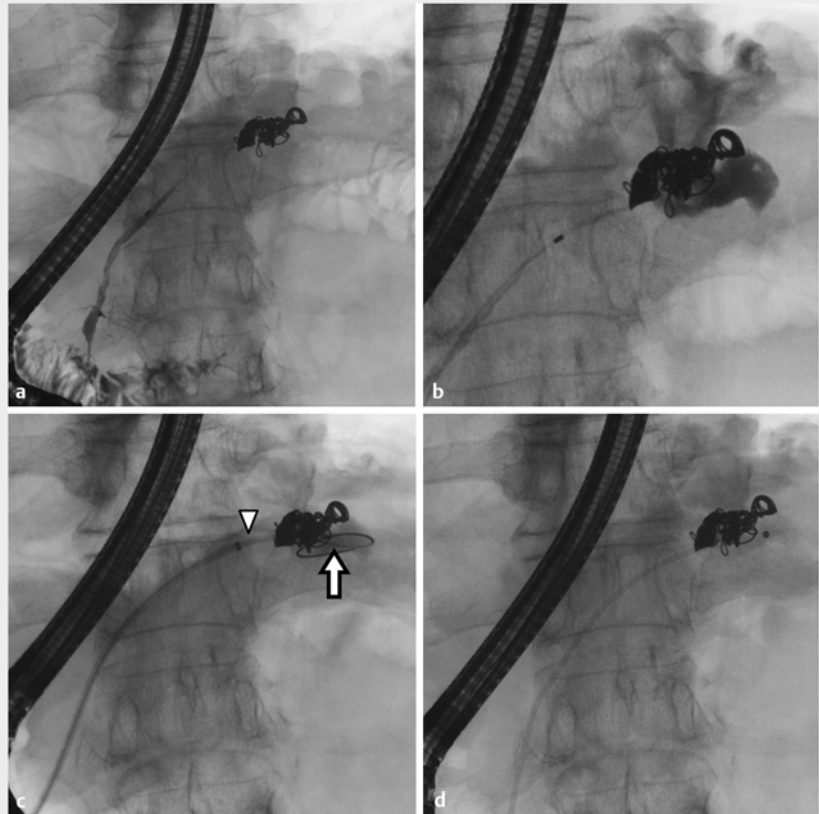

## Tunneling technique using a device delivery system for the treatment of pancreaticopleural fistula due to severe downstream pancreatic duct strictures



► **Fig. 1** A contrast-enhanced computed tomography image showing effusion extending from the pancreatic tail (not shown in this figure) toward the mediastinum, with accompanying bilateral pleural effusion.

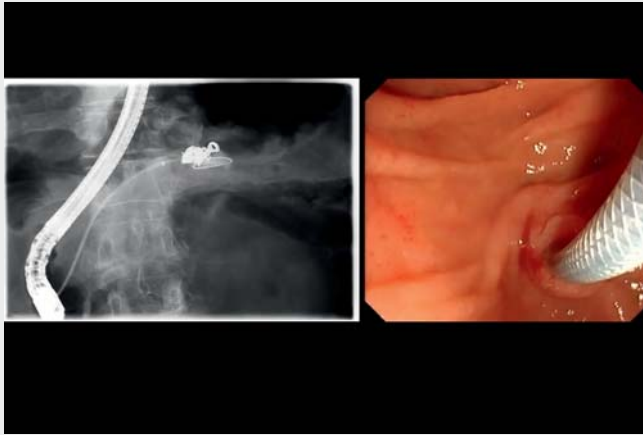A 70-year-old man presented with epigastric discomfort. He had undergone a transarterial coil embolization of a splenic artery pseudoaneurysm 3 months previously. Computed tomography revealed an effusion extending from the pancreatic tail towards the mediastinum, with an accompanying pleural effusion (► **Fig. 1**). Endoscopic retrograde pancreatography revealed severe ductal strictures in the pancreatic body (► **Fig. 2 a**) and a pancreaticopleural fistula upstream of those strictures (► **Fig. 2 b**). We then managed to advance a long-tapered catheter beyond the strictures; however, we were unable to pass a nasopancreatic drainage (NPD) tube through the strictures. Therefore, we next opted to perform a “tunneling technique” using a novel device delivery system (Endo-Sheather; Piolax Medical Devices, Kanagawa, Japan). The device delivery system consists of an inner catheter that tapers to a tip of 3.9Fr diameter within an outer sheath (6.2Fr inner diameter), which enables devices of up to 5.7Fr diameter to successfully pass through tight strictures. Thus, we advanced the delivery system over a 0.035-inch guidewire to dilate the



► **Fig. 2** Fluoroscopic images of a 70-year-old man. **a** Tight ductal strictures in the pancreatic body. **b** A pancreaticopleural fistula upstream of the strictures. **c** A device delivery system advanced beyond the strictures. Arrow, tip of the inner catheter of the device delivery system; arrowhead, tip of the outer sheath. **d** A nasopancreatic drainage tube was successfully placed beyond the strictures.

strictures (► **Fig. 2 c**), and after removing the inner catheter, we were now able to easily pass a 5-Fr NPD tube through the outer sheath of the device and past the strictures (► **Fig. 2 d**, ► **Video 1**). We removed the tube 3 weeks after the treatment and discharged the patient without any further complication. The endoscopic treatment of a pancreaticopleural fistula remains a challenging procedure, particularly when downstream pancreatic duct strictures are present. However, in this case, our “tun-

neling technique” allowed us to easily place the NPD tube beyond severe pancreatic duct strictures to successfully treat the fistula. Although the device delivery system has already been used to place metallic stents for malignant hilar biliary strictures [1], for endoscopic ultrasound-guided plastic stent placements [2], and for various types of selective biliary biopsies [3–5], we posit that it also has great potential for use in NPD tube placement across severe pancreatic duct strictures.



**Video 1** Tunneling technique using a device delivery system for the treatment of pancreaticopleural fistula due to severe downstream pancreatic duct strictures.

Endoscopy\_UCTN\_Code\_TTT\_1AR\_2AG

### Competing interests

The authors declare that they have no conflict of interest.

### The authors

**Sho Kitagawa** , **Narito Murakoshi, Keiya Okamura**

Department of Gastroenterology, Sapporo Kosei General Hospital, Sapporo, Japan

### Corresponding author

**Sho Kitagawa, MD**

Department of Gastroenterology, Sapporo Kosei General Hospital, Kita 3 Higashi 8, Chuo-ku, Sapporo 060-0033, Japan  
 Fax: +81-11-2715320  
 bossa0405@yahoo.co.jp

### References

- [1] Matsumori T, Uza N, Shiokawa M et al. Self-expandable metallic stent placement for malignant biliary stricture using a novel device delivery system. *VideoGIE* 2021; 6: 468–471
- [2] Kito Y, Kato A, Yoshida M et al. Facile and secure deployment of plastic stent through an endoscopic tapered sheath for endoscopic ultrasound-guided drainage. *Endoscopy* 2022. doi:10.1055/a-1747-3162
- [3] Matsumori T, Uza N, Shiokawa M et al. Mapping biopsy for bile duct cancer using a novel device delivery system. *Endoscopy* 2022; 54: E217–E219. doi:10.1055/a-1479-1969
- [4] Yane K, Sumiyoshi T, Kondo H. Transpapillary gallbladder biopsy using newly designed endoscopic sheath. *Dig Endosc* 2021; 33: e146–e147
- [5] Yane K, Morita K, Sumiyoshi T et al. Simple transmural antegrade biopsy method for indeterminate biliary stricture using endoscopic sheath. *Endosc Int Open* 2022; 10: E1309–E1310. doi:10.1055/a-1793-9454

### Bibliography

*Endoscopy* 2023; 55: E157–E158

DOI 10.1055/a-1952-0388

ISSN 0013-726X

published online 28.10.2022

© 2022. The Author(s).

This is an open access article published by Thieme under the terms of the Creative Commons Attribution-NonDerivative-NonCommercial License, permitting copying and reproduction so long as the original work is given appropriate credit. Contents may not be used for commercial purposes, or adapted, remixed, transformed or built upon. (<https://creativecommons.org/licenses/by-nc-nd/4.0/>)

Georg Thieme Verlag KG, Rüdigerstraße 14, 70469 Stuttgart, Germany



### ENDOSCOPY E-VIDEOS

<https://eref.thieme.de/e-videos>



*Endoscopy E-Videos* is an open access online section, reporting on interesting cases and new techniques in gastroenterological endoscopy. All papers include a high quality video and all contributions are freely accessible online. Processing charges apply (currently EUR 375), discounts and waivers acc. to HINARI are available.

This section has its own submission website at <https://mc.manuscriptcentral.com/e-videos>