

# Autologous hematopoietic stem cell transplantation for human immunodeficiency virus associated gastric Burkitt lymphoma

## A case report

Lu Junfeng, MD, PhD, Ma Lina, MD, Chen Xinyue, MD, PhD\*

### Abstract

**Rationale:** HIV-related lymphoma, especially non-Hodgkin lymphoma, is one of the most common malignant tumors in HIV/acquired immune deficiency syndrome (AIDS) patients. Autologous hematopoietic stem cell transplantation (AHSCT) for the patients with Burkitt lymphoma (BL) is needed to be further explored.

**Patient concerns:** A 57-year-old man was hospitalized with intermittent pain on upper abdomen and melena for >1 month.

**Diagnosis:** HIV antibody testing was positive. The upper gastrointestinal endoscopy was performed and histopathology and immunohistochemistry revealed BL.

**Interventions:** Highly effective antiretroviral therapy and sixth cycles of chemotherapy were administered, followed by autologous hematopoietic stem cell transplantation.

**Outcomes:** The patient has had tumor-free survival for >6 years with normal CD4+ T cell counts and HIV viral load below the lowest detection

**Lessons:** The patient was treated with AHSCT followed complete remission after chemotherapy and achieved long-term disease-free survival. AHSCT may be a promising way for clinical cure of HIV-related BL.

**Abbreviations:** AHSCT = autologous hematopoietic stem cell transplantation, BL = Burkitt lymphoma, HAART = highly active antiretroviral therapy.

**Keywords:** autologous hematopoietic stem cell transplantation, Burkitt lymphoma, HIV

## 1. Introduction

HIV infection significantly increases the risk of cancer and is the strongest risk factor for lymphoma. Even in the era of highly active antiretroviral therapy (HAART), lymphomas developed in 2.1% of these patients, of which Burkitt lymphoma (BL)

accounted for approximately 11.8%.<sup>[1]</sup> Patients with HIV-related BL currently received standard therapeutic regimens and achieved outcomes comparable to those of non-HIV-infected individuals.<sup>[2-4]</sup> But the role of autologous hematopoietic stem cell transplantation (AHSCT) remains unclear, especially in the absence of long-term follow-up after transplantation. In this paper, we report a case of gastric BL with acquired immune deficiency syndrome (AIDS) treated with AHSCT. Patient has provided informed consent for publication of the case.

## 2. Case report

A 57-year-old man was admitted to our unit with intermittent upper abdominal pain, black stool, low-grade fever (37.5–38°C) and weight loss for >1 month. Weight loss was about 5 kg in the past month prior to admission. He had a history of diabetes and was treated with oral Metformin and a history of unsafe sexual contact. Physical examination revealed mild tenderness on the upper abdomen. After admission in January 2013, laboratory examinations were performed. Liver and kidney function were normal with decreased albumin (29.2 g/L). Fecal occult blood was positive and hemoglobin was 8.0 g/dL. C reactive protein (23.1 mg/L) and erythrocyte sedimentation rate (46 mm/h) were slightly elevated. Antibody to Epstein-Barr virus (EBV) was positive with undetectable EBV-DNA level. Abdominal ultrasound showed a small amount of ascites. During hospitalization, HIV antibody confirmatory test was positive with CD4-positive T lymphocyte (CD4+T) cell count 367 cells/μL and the plasma

Editor: N/A.

This work was supported by the Capital Characteristic Clinical Application Research and Extension of Achievements (Z161100000516018), China's 13th Five-year plan for Key Projects in Infectious Diseases (No. 2017ZX10201201-001-008), and Research Projects of Health System in Fengtai District (2015-20).

Consent for publication: Informed written consent was obtained from the patient for publication of this case report and accompanying images.

The authors have no conflicts of interest to disclose.

International Medical Department, Beijing Youan Hospital, Capital Medical University, Beijing, China.

\* Correspondence: Chen Xinyue, International Medical Department, Beijing Youan Hospital, Capital Medical University, Beijing, 100069, China (e-mail: chenxydoc@163.com).

Copyright © 2019 the Author(s). Published by Wolters Kluwer Health, Inc. This is an open access article distributed under the terms of the Creative Commons Attribution-Non Commercial License 4.0 (CCBY-NC), where it is permissible to download, share, remix, transform, and buildup the work provided it is properly cited. The work cannot be used commercially without permission from the journal.

Medicine (2019) 98:29(e16222)

Received: 28 December 2018 / Received in final form: 29 April 2019 / Accepted: 4 June 2019

<http://dx.doi.org/10.1097/MD.00000000000016222>

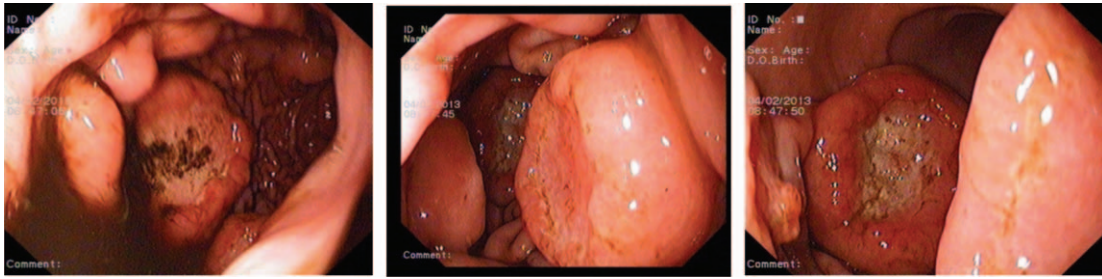


Figure 1. Gastroscopy showed multiple masses and ulcers in the fundus and body of the stomach before treatment.

HIV viral load 7500 copies/mL. Gastroscopy revealed multiple giant ulcers in the fundus and body of the stomach with the surrounding being uplifted and the middle being concave (Fig. 1). Histopathological examination revealed that the tumor cells were of medium size, round nucleus, basophilic. Phagocytes devouring cell debris were scattered among the tumor cells, conferring a “starry-sky” appearance. Immunohistochemical examination revealed the pathologic cells expressed CD20, CD79a, had a Ki67 index >90% and were not reactive for CD45RO, CD5, CD23, bcl-2, and Cyclin D1. Positron emission computed tomography (PET-CT) showed the wall of gastric body and antrum was thickened diffusely with multiple lymph nodes in the bilateral neck, fossa axillaris, and inguinal. Bone marrow smear and cerebrospinal fluid showed no abnormalities. On the basis of the above findings, the final diagnosis was HIV related gastric BL.

HAART using Tenofovir, lamivudine, and Efavirenz and symptomatic treatment were started after the admission. Two weeks later, the patient received chemotherapy with rituximab plus etoposide, prednisone, incristine, cyclo-phosphamide, and doxorubicin (R-EPOCH) regimen (rituximab, etoposide, predni-

sone, vincristine, cyclophosphamide, doxorubicin). During chemotherapy, methotrexate was given to prevent central nervous system involvement. After 4 courses of R-EPOCH treatment, the masses in the gastric fundus and body and enlarged lymph nodes disappeared completely reassessed by gastroscopy (Fig. 2) and PET-CT, respectively. Subsequently, the fifth course chemotherapy with R-high-dose CTX regimen (rituximab, high dose cyclophosphamide) was given for mobilization and autologous hematopoietic stem cells (HSCs) (PBMCs  $4.37 \times 10^8$ /kg and CD34+ cells  $2.06 \times 10^6$ /kg) were collected successfully. After sixth course R-EPOCH regimen, the curative effect was evaluated as complete remission. HSCs (autologous hematopoietic stem cells) were transfused after pretreatment chemotherapy with R-BEAC regimen (rituximab, carmustine, etoposide, cytarabine, cyclophosphamide) in September 2013. Neutrophil implantation time was 11 days, and platelet implantation time was 16 days. CD4+T cell count fluctuated during chemotherapy and before and after transplantation (ninth month) and HIV viral load was steadily below the lowest detection after 3 months of antiviral therapy (Fig. 3). Until the last follow-up, the patient had tumor-free survival for >6 years.

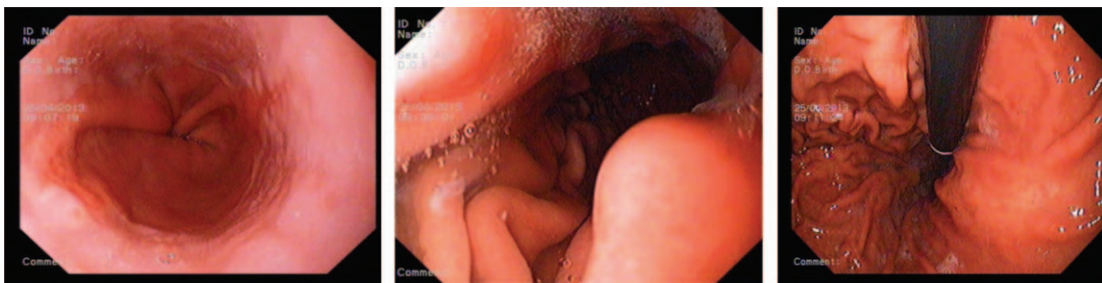

Figure 2. Gastroscopy showed no obvious lesions in the fundus and body of the stomach after treatment.

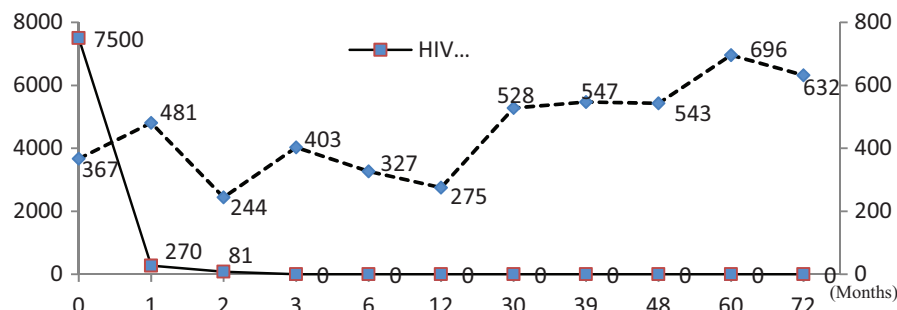


Figure 3. Changes of CD4+T cells and HIV RNA before and after transplantation and during long-term follow-up.

### 3. Discussion

Lymphoma is still one of the leading causes of cancer-related death among patients with HIV infection in the era of HAART and BL is a very aggressive subtype of non-Hodgkin lymphoma that occurs with higher frequency in patients with HIV/AIDS.<sup>[1]</sup> In this article, the patient was given HAART firstly. Two weeks later, no obvious adverse reactions were observed and then chemotherapy was started. After complete remission with 6-course chemotherapy, AHSCT was performed. The patient has survived for >6 years without tumors by this time.

The best time to combine chemotherapy with HAART is still uncertain. The use of antiviral drugs before or during chemotherapy was supported. The advantages include increasing the immune function, enhancing the tolerance and response to chemotherapy, and improving the survival and prognosis of the patients. Virologic and immunological response acquired by HAART is an important independent prognostic factor.<sup>[5]</sup> However, the interaction between chemotherapeutic agents and antiviral agents should be fully considered during treatment.

For HIV related BL, it was shown that treatment with short-course, high-intensity, multi-agent chemotherapy could result in substantial rates of durable remission and treatment-related toxicity and mortality did not seem to be appreciably increased.<sup>[6,7]</sup> These data helped for further investigation of intensive therapy for patients with HIV-BL. Dunleavy et al<sup>[8]</sup> had reported that R-EPOCH regimen had a very good therapeutic effect on BL. From this text, R-EPOCH regimen could also be safely and effectively administered in the patient receiving HAART. In addition, R-CODOX-M/IVAC (rituximab, cyclophosphamide, vincristine, doxorubicin, high-dose methotrexate/ ifosfamide, etoposide, and high-dose cytarabine) had been evaluated prospectively in a multicenter BL trial and the 2-year overall survival rate for patients with HIV-related BL was 69.0%.<sup>[9]</sup> From the above, both of the 2 regimens are effective in most HIV related BL. Moreover, the addition of rituximab was not associated with additional toxicity and was associated with improved overall survival and progression-free survival.<sup>[10]</sup>

Several prospective trials in the 2000s have demonstrated the safety and efficacy of AHSCT in HIV-positive patients.<sup>[11]</sup> Recently, a cooperative group study has been reported and outcomes of AHSCT for HIV-positive lymphoma patients were not different from matched controls without HIV infection.<sup>[12]</sup> In this case, CD34+ stem cells were successfully collected after mobilization chemotherapy and neutrophil and platelet implantation time was similar to those without HIV infection, which was consistent with previous literature.<sup>[12-14]</sup> It is suggested that HIV infection and the use of HAART do not affect collection quantity and implantation of HSCs.

In this case, after treatment with HAART, the HIV viral load gradually decreased to an undetectable level. There was no active HIV replication during the chemotherapy period or even after AHSCT which was consistent with Cillo report.<sup>[15]</sup> It was suggested that chemotherapy or AHSCT for HIV-1 related lymphoma in the context of continuous HAART had little impact on HIV replication. The CD4+T cells decreased temporarily during chemotherapy and transplantation and then returned to normal levels quickly. In multicenter 0803/AMC 071 study, the CD4+T cell returned to pre-transplantation levels 60 days after

AHSCT.<sup>[12]</sup> Similarly, HIV infection and the use of HAART do not affect immunological reconstitution after transplantation.

In conclusion, this patient is the first reported case of HIV-related BL treated by AHSCT in China and achieved long-term disease-free survival through chemotherapy combined with AHSCT. The therapeutic processes have a reference value for peers of relevant specialties.

### Author contributions

**Conceptualization:** Lu Junfeng.

**Funding acquisition:** Chen Xinyue.

**Investigation:** Lu Junfeng.

**Project administration:** Chen Xinyue.

**Resources:** Ma Lina.

**Writing – Original Draft:** Lu Junfeng.

### References

- [1] Gopal S, Patel MR, Yanik EL, et al. Temporal trends in presentation and survival for HIV-associated lymphoma in the antiretroviral therapy era. *J Natl Cancer Inst* 2013;105:1221–9.
- [2] Little RF, Dunleavy K. Update on the treatment of HIV-associated hematologic malignancies. *Hematology Am Soc Hematol Educ Program* 2013;2013:382–8.
- [3] Xicoy B, Miralles P, Morgades M, et al. Long-term follow up of patients with human immunodeficiency virus infection and advanced stage Hodgkin's lymphoma treated with doxorubicin, bleomycin, vinblastine and dacarbazine. *Haematologica* 2013;98:e85–6.
- [4] Uldrick TS, Little RF. How I treat classical Hodgkin lymphoma in patients infected with human immunodeficiency virus. *Blood* 2015;125:1226–35.
- [5] Hoffmann C, Wolf E, Fätkenheuer G, et al. Response to highly active antiretroviral therapy strongly predicts outcome in patients with AIDS-related lymphoma. *AIDS* 2003;17:1521–9.
- [6] Lopez TM, Hagemester FB, McLaughlin P, et al. Small noncleaved cell lymphoma in adults: superior results for stages I-III disease. *J Clin Oncol* 1990;8:615–22.
- [7] McMaster ML, Greer JP, Greco FA, et al. Effective treatment of small-noncleaved-cell lymphoma with high-intensity, brief-duration chemotherapy. *J Clin Oncol* 1991;9:941–6.
- [8] Dunleavy K, Pittaluga S, Shovlin M, et al. Low-intensity therapy in adults with Burkitt's lymphoma. *N Engl J Med* 2013;369:1915–25.
- [9] Noy A, Lee JY, Cesarman E, et al. AMC 048: modified CODOX-M/IVAC-rituximab is safe and effective for HIV-associated Burkitt lymphoma. *Blood* 2015;126:160–6.
- [10] Alwan F, He A, Montoto S, et al. Adding rituximab to CODOX-M/IVAC chemotherapy in the treatment of HIV-associated Burkitt lymphoma is safe when used with concurrent combination antiretroviral therapy. *AIDS* 2015;29:903–10.
- [11] Durand CM, Ambinder RF. Hematopoietic stem cell transplantation in HIV-1-infected individuals: clinical challenges and the potential for viral eradication. *Curr Opin Oncol* 2013;25:180–6.
- [12] Alvarnas JC, Le Rademacher J, Wang Y, et al. Autologous hematopoietic cell transplantation for HIV-related lymphoma: results of the BMT CTN 0803/AMC 071 trial. *Blood* 2016;128:1050–8.
- [13] Ramaswami R, Pria AD, Parker K, et al. Outcomes of autologous stem cell transplantation (ASCT) in patients with relapsed/refractory HIV-associated lymphoma. *Bone Marrow Transplant* 2016;51:1609–11.
- [14] Morawa E, Martin P, Gergis U, et al. Autologous stem cell transplant in human immunodeficiency virus-positive patients with lymphoid malignancies: focus on infectious complications. *Leuk Lymphoma* 2013;54:885–8.
- [15] Cillo AR, Krishnan A, Mitsuyasu RT, et al. Plasma viremia and cellular HIV-1 DNA persist despite autologous hematopoietic stem cell transplantation for HIV-related lymphoma. *J Acquir Immune Defic Syndr* 2013;63:438–41.