

Techniques in distal access of wide-necked giant intracranial aneurysms during treatment with flow diversion

Peter Kan, Ajay Kumar Wakhloo¹, Maxim Mokin, Ajit Puri

Department of Neurosurgery, Baylor College of Medicine, Houston, Texas, ¹Department of Radiology, University of Massachusetts Medical School, Worcester, Massachusetts, USA

E-mail: *Peter Kan - pkkan@health.usf.edu; Ajay Kumar Wakhloo - ajay.wakhloo@umassmemorial.org

*Corresponding author

Received: 19 December 14 Accepted: 19 March 15 Published: 28 May 15

This article may be cited as:

Kan P, Wakhloo AK, Mokin M, Puri A. Techniques in distal access of wide-necked giant intracranial aneurysms during treatment with flow diversion. *Surg Neurol Int* 2015;6:S284-8. Available FREE in open access from: <http://www.surgicalneurologyint.com/text.asp?2015/6/8/284/157797>

Copyright: © 2015 Kan P. This is an open-access article distributed under the terms of the Creative Commons Attribution License, which permits unrestricted use, distribution, and reproduction in any medium, provided the original author and source are credited.

Abstract

Background: Accessing the normal distal vessel in treatment of wide-necked giant intracranial aneurysms with flow diversion can be difficult.

Case Description: Through illustrative cases, the authors present several useful techniques in distal access of wide-necked giant aneurysms during flow diversion treatment. Obtaining an optimal projection that separates the outflow limb from the aneurysm is most critical. Each of the three techniques described enabled the distal access to giant intracranial aneurysms during treatment with flow diversion.

Conclusion: The looped-around technique, balloon-assisted technique, and retrograde access are valuable strategies in crossing the aneurysm if direct distal access cannot be obtained.

Key Words: Distal access, flow diversion, giant intracranial aneurysms, neurovascular, wide-necked

Access this article online

Website:

www.surgicalneurologyint.com

DOI:

10.4103/2152-7806.157797

Quick Response Code:



With approval from the U.S. Food and Drug Administration of the Pipeline Embolization Device (PED), the use of flow diversion has become more common for the treatment of unruptured giant aneurysms in the anterior circulation that cannot be treated by traditional endovascular methods. Early results have been very encouraging, with occlusion rates of large and giant aneurysms approaching 90% at 6 months;^[1] however, the change in paradigm from an intrasaccular to an endoluminal approach has introduced a new set of technical challenges to the neurointerventionalist. In particular, access of the distal normal vessel often can be a formidable obstacle in giant aneurysms with disjointed in- and outflow limbs. Several papers have addressed the issue of maintenance of distal access once it is established,^[2,3,5] but none focuses on the techniques for obtaining distal access. Through three illustrative cases, we present several techniques that are useful in crossing

S284

giant intracranial aneurysms during their treatment with flow diversion.

FLOW DIVERSION PROCEDURE

All patients were treated with dual antiplatelets consisting of 325 mg of aspirin daily and 75 mg of clopidogrel daily for 5 days prior to the procedure. The degree of P2Y12 inhibition and aspirin response was tested with VerifyNow (Accumetrics, San Diego, CA) on the day of treatment. An aspirin response unit value of ≤ 550 and a Plavix Response Unit of ≤ 230 were considered to indicate an appropriate level of platelet inhibition for treatment. All procedures were performed under general anesthesia. Systemic heparin was used to achieve an activated clotting time of ≥ 250 s. To ensure robust proximal support, a triaxial system was used through femoral access in each case. This consisted of a 6 French

shuttle sheath (Cook Medical, Bloomington, IN) placed in the common carotid artery prior to the bifurcation, a 5 French Navien distal access catheter (Covidien Vascular Therapies, Mansfield, MA) placed proximal to the neck of the aneurysm, and the delivery microcatheter for the flow diverter.

Case 1

A 73-year-old female presented with an enlarging, giant right cavernous internal carotid artery (ICA) aneurysm [Figure 1]. To obtain distal access, we first found a projection that separated the distal limb from the aneurysm so that the outflow was clearly visualized. We then looped a Synchro standard 014 wire (Stryker Neurovascular, Fremont, CA) two times around the aneurysm to increase support so that we could push the distal wire into the middle cerebral artery (MCA) [Figure 2]. A SL-10 microcatheter (Stryker, Kalamazoo, MI) was then tracked into the superior MCA division. To reduce the catheter redundancy in the aneurysm, a previously described sea anchor technique was employed.^[2] A Transcend 014 exchange length wire (Stryker Neurovascular, Fremont, CA) was used to exchange the microcatheter for a 4 × 40-mm Surpass device (Stryker Neurovascular, Fremont, CA). The device was deployed from the supraclinoid ICA to the posterior genu of the cavernous carotid to cover the giant aneurysm. Stasis within the aneurysm was seen immediately. The patient remained neurologically intact and was discharged on postoperative day (POD) 1.

Case 2

A 53-year-old female presented with a 1-week loss of visual acuity over her left eye. Catheter angiography demonstrated a giant left carotid ophthalmic aneurysm [Figure 3]. To obtain distal access, we again found a projection that allowed us to visualize the outflow limb independent of the aneurysm. We then shaped a Synchro standard 014 wire into a large Simmons shape to allow reentry into the distal parent vessel and access to the left MCA [Figure 4]. A SL-10 microcatheter was then tracked into the MCA. To reduce the catheter redundancy in the aneurysm, the recently described stent anchor technique was used.^[3]

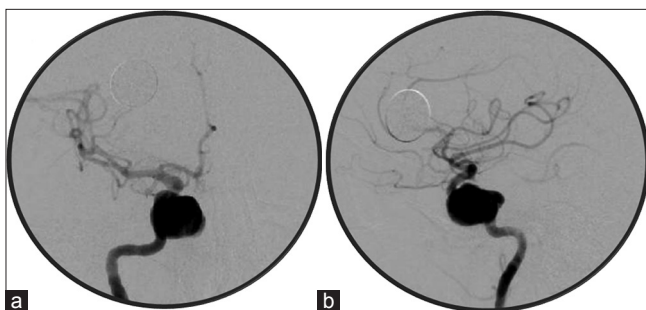


Figure 1: Anteroposterior (a) and lateral (b) right ICA injection revealed a giant right cavernous ICA aneurysm

The SL-10 catheter was exchanged out for a Marksman microcatheter (Covidien, Mansfield, MA), and a 4 × 20-mm Solitaire device (Covidien) was deployed in the MCA to provide distal support and anchorage [Figure 5]. Once the redundancy was reduced, the Solitaire device was recaptured, and a Synchro 014 exchange wire was used to deliver two 4 × 20-mm Surpass devices to cover the giant ophthalmic aneurysm and the additional distal cavernous aneurysm. Stasis was observed immediately in both aneurysms. The patient's vision improved, and the patient was discharged on POD2.

Case 3

A 58-year-old female presented with headache. A computed tomography (CT) scan did not reveal subarachnoid hemorrhage. Magnetic resonance imaging (MRI) and subsequently catheter angiography demonstrated a 3 × 2-cm giant left cavernous ICA aneurysm [Figure 6]. To obtain distal access, a Hyperform 7 × 15-mm balloon (Covidien) was inflated within the aneurysm. This reduced the volume of the aneurysm to facilitate access to the distal limb of the parent vessel with the looped-around technique described above [Figure 7]. The SL10 microcatheter was then exchanged for the Marksman microcatheter. Two PEDs (4.5 × 35 mm followed by a 4.5 × 20 mm) were deployed across the aneurysm with a 50% overlap. A HyperGlide 4 × 7-mm balloon was then used for angioplasty to address malapposition between the first PED and the distal vessel. Unfortunately, the two PEDs became disconnected within the aneurysm upon angioplasty, and distal access was subsequently lost.

On a separate intervention, bilateral femoral groin access was obtained. A 5 French guide was placed in the right cervical ICA. An SL-10 microcatheter and a Synchro standard 014 wire were used to access the aneurysm retrograde across the anterior communicating

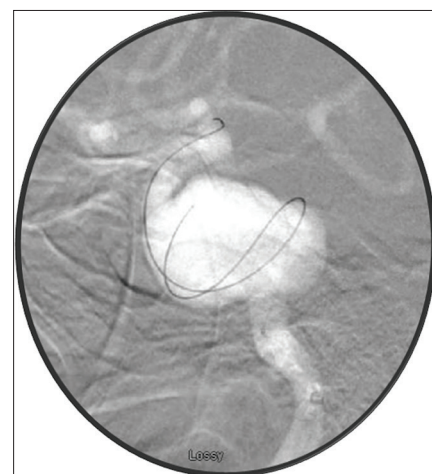


Figure 2: The looped-around technique showing a double loop of the Synchro Standard 014 microwire within the aneurysm along with its stiff part and distal access of the supraclinoid ICA

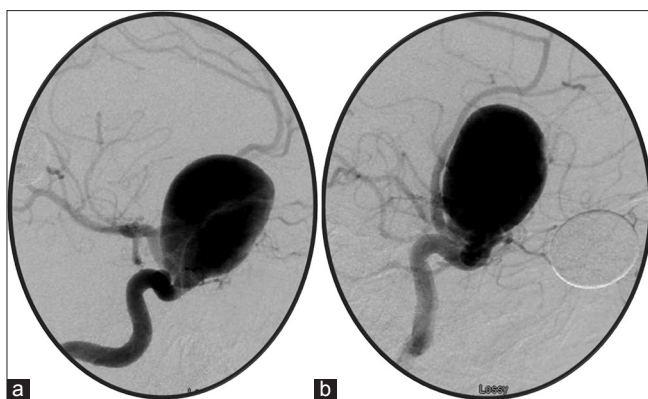


Figure 3: Anteroposterior (a) and lateral (b) left ICA injection revealed a giant left carotid ophthalmic aneurysm

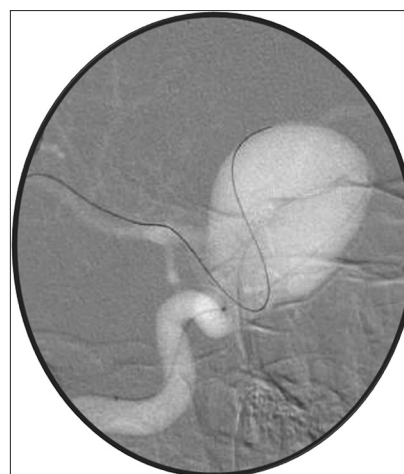

Figure 4: The looped-around technique showing a Simmons-shaped Synchro Standard 014 microwire accessing the distal vessel with its reverse curve

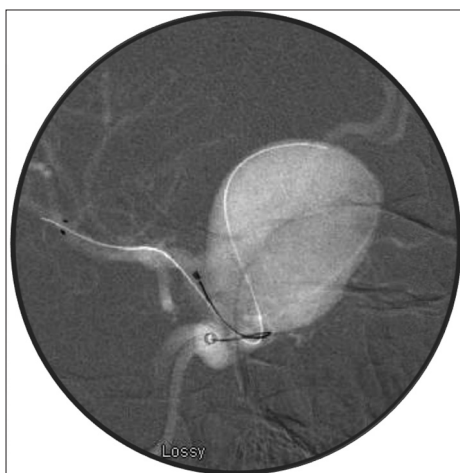

Figure 5: The recapturable Solitaire stent was deployed in the MCA to provide distal anchorage so that the microcatheter redundancy can be reduced without losing distal access

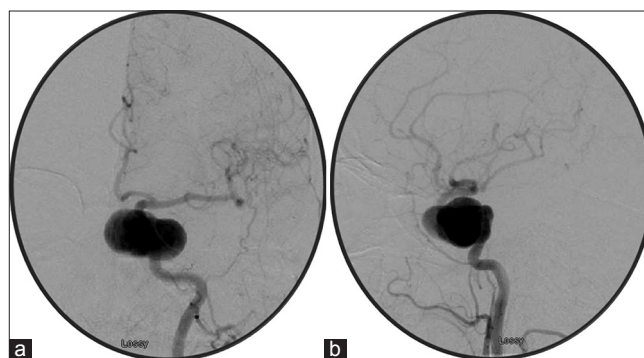


Figure 6: Anteroposterior (a) and lateral (b) left ICA injection revealed a giant left cavernous ICA aneurysm

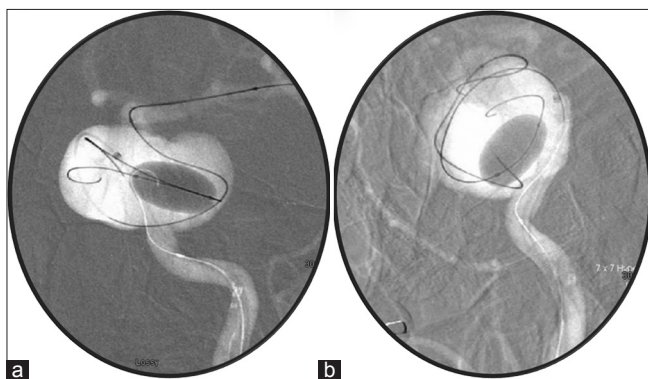


Figure 7: Anteroposterior (a) and lateral (b), a large hyperform balloon was inflated to reduce the volume of the aneurysm to facilitate crossing

artery [Figure 8]. Through the right groin, our standard triaxial system was used as described above. A 6-mm snare through a Marksman microcatheter was then used to capture the Synchro microwire, and the Marksman was flossed into the distal PED/supraclinoid ICA [Figure 9] as described by Hauck *et al.*^[4] MCA access was then

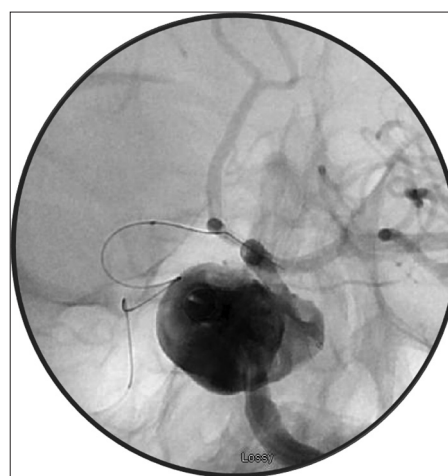

Figure 8: Retrograde access of the giant aneurysm across the anterior communicating artery through the distal PED

reestablished, and two additional PEDs (4.75×30 mm) were deployed to connect the disconnected devices. The patient was discharged on POD2. The 3-month and 1-year follow-up angiograms showed complete obliteration of the aneurysm.

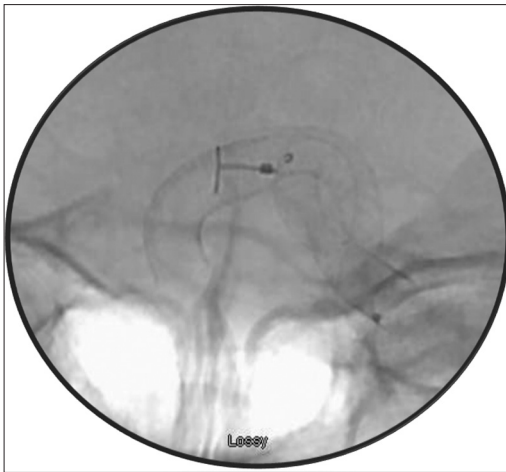


Figure 9: Flossing technique was used to pull the Marksman microcatheter within the distal PED

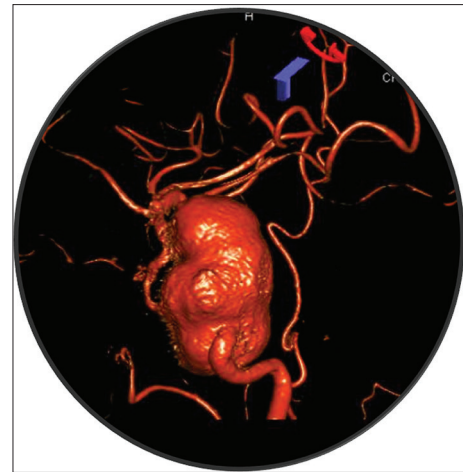


Figure 10: Example of an optimal working projection of a giant ICA aneurysm where the outflow limb is separated from the aneurysm dome to increase the chance of successful distal access

DISCUSSION

The use of flow diverting stents has become more common for treatment of unruptured sidewall large and giant intracranial aneurysms in the anterior circulation that cannot be treated by traditional endovascular methods. Unlike intrasaccular coil embolization, its successful deployment relies on access to the normal vasculature distal to the aneurysm neck, which can be very challenging for the neurointerventionalist because the proximal and distal limbs of these aneurysms are often distant from each other with no intervening normal vessel. We highlight several techniques that facilitate the distal access of giant intracranial aneurysms during treatment with flow diversion.

The first and foremost step is to obtain a projection that separates the aneurysm from the outflow limb such that the outflow vessel can be clearly visualized. The optimal projection is best obtained from the three-dimensional rotational image on the workstation. In cases of giant aneurysms, there is often a delay in opacification of the outflow vessel because of the transit time of contrast in the aneurysm. As a result, we typically increase the delay before acquisition during three-dimensional rotational angiography to ensure that the outflow vessel is well visualized [Figure 10]. The wire looped-around technique, employed primarily in the first and second cases, coupled with a trackable microcatheter and a torque-sensitive microwire, should be the first maneuver if the distal limb cannot be accessed directly. We found that a large Simmons shape or an 'S' shape on the microwire often helps to engage the outflow limb of the aneurysm by the reverse distal curve on the wire (as in case 2). By looping around the aneurysm wall and placing the stiff part of the wire within the aneurysm, wire support dramatically increases and facilitates the engagement of the outflow vessel. The redundancy of the microcatheter within the

aneurysm can then be reduced by several techniques described in the literature such as the stent, balloon, or sea anchor technique.^[2,3,5] Essentially, all these techniques allow the reduction of microcatheter redundancy within the aneurysm with little backward movement of the system by anchoring the MCA with either a stent, balloon, or microcatheter. After straightening of the system, the stent, balloon, or microcatheter is then exchanged for the delivery catheter. This step is crucial as it avoids tracking the flow diverter around the aneurysm and placing unnecessary stress on the aneurysm dome, which can increase the risk of intraprocedural rupture. Once the catheter redundancy within the aneurysm is reduced, one can then proceed to device delivery.

If the looped-around technique fails to engage the outflow limb as in case 3, a large balloon can be used to reduce the volume of the aneurysm to increase the chance of obtaining distal access. In this case, a larger distal access catheter (Navien 072) is required to allow simultaneous balloon and microcatheter placement into the aneurysm. Again, a trackable microcatheter is used to cross the now-smaller aneurysm with the above-mentioned looped-around technique. Once distal access is obtained, the balloon can then be removed. The catheter can then be reduced for device deployment.

Finally, if the above techniques were unsuccessful and the patient has an adequate anterior or posterior communicating artery, retrograde access of the aneurysm can be performed. A large snare can be used to capture the retrograde microwire into the microcatheter, which, in turn, can bring the microcatheter into the distal limb ("flossing"). At this point, antegrade access of the MCA can be obtained.

Flow diversion is emerging as an important technique in the armamentarium for treatment of unruptured

large and giant intracranial aneurysms in the carotid circulation. Its successful deployment relies on access to the vasculature distal to the aneurysm neck. We have found that the above-mentioned techniques are valuable and practical to increase the success of flow diversion in the treatment of these difficult intracranial aneurysms.

REFERENCES

1. Becske T, Kallmes DF, Saatci I, McDougall CG, Szikora I, Lanzino G, et al. Pipeline for uncoilable or failed aneurysms: Results from a multicenter clinical trial. *Radiology* 2013;267:858-68.
2. Edwards L, Kota G, Morris PP. The sea anchor technique: A novel method to aid in stent-assisted embolization of giant cerebral aneurysms. *J Neurointerv Surg* 2013;5:e39.
3. Fargen KM, Velat GJ, Lawson MF, Hoh BL, Mocco J. The stent anchor technique for distal access through a large or giant aneurysm. *J Neurointerv Surg* 2013;5:e24.
4. Hauck EF, Natarajan SK, Langer DJ, Hopkins LN, Siddiqui AH, Levy EI. Retrograde trans-posterior communicating artery snare-assisted rescue of lost access to a foreshortened pipeline embolization device: Complication management. *Neurosurgery* 2010;67 (2 Suppl Operative):S495-502.
5. Snyder KV, Natarajan SK, Hauck EF, Mocco J, Siddiqui AH, Hopkins LN, et al. The balloon anchor technique: A novel technique for distal access through a giant aneurysm. *J Neurointerv Surg* 2010;2:363-7.