

# Application of Lung Ultrasonography in the Diagnosis of Childhood Lung Diseases

Shui-Wen Chen<sup>1,2,3</sup>, Ming-Yu Zhang<sup>4</sup>, Jing Liu<sup>1,2</sup>

<sup>1</sup>Department of Neonatology and NICU of Bayi Children's Hospital, Beijing Military General Hospital, Beijing 100700, China

<sup>2</sup>The Graduate School of Southern Medical University, Guangzhou, Guangdong 510515, China

<sup>3</sup>Department of Pediatrics, Baoan Maternal and Child Health Hospital, Shenzhen, Guangdong 518133, China

<sup>4</sup>Department of Ultrasonography, Beijing Military General Hospital, Beijing 100700, China

**Key words:** Childhood; Infants, Newborn; Lung Disease; Lung Ultrasonography

## INTRODUCTION

Lung diseases are the most common conditions in newborn infants and children and are also the primary causes of death in children younger than 5 years old.<sup>[1]</sup> Therefore, accurate and timely diagnosis is extremely important in order to enable efficient treatment and improve the prognosis of patients with lung diseases. In the past, the diagnosis of lung disease mainly depended on chest radiography (CR) and/or computed tomography (CT). However, the use of these imaging techniques is limited due to transportation and inevitable radiation. Ultrasound imaging is based on the reflection and scattering of ultrasound beam occurring at the interfaces between different media. Traditionally, it is considered that lung is not a target for an ultrasound because ultrasound wave cannot penetrate anatomical structures full of gas. With deepening recognition about ultrasound in recent years, the lung with diseases produces ultrasound artifacts result from the abnormal tissue/gas/tissue interface when ultrasound wave penetrate lung tissue. The ultrasound artifacts are the basis of lung ultrasonography (LUS) application in the clinic. Recently, LUS has been increasingly used for detecting lung diseases because of its bedside convenience, accuracy, and free of radiation.<sup>[2-5]</sup> Therefore, the aim of this study is to present the application of LUS in the field of pediatric respiratory disease.

## FREQUENCY OF USE OF DIFFERENT PROBES

Neonatal LUS is often performed with a high frequency 9–14 MHz linear array probe, which is more effective in visualizing the chest wall, pleura, and lung peripheral parenchyma.<sup>[2]</sup> In neonates with small gestational age (GA), LUS

can be performed with a higher frequency probe. In infants and older children, it is performed using a relatively lower frequency linear probe, which can visualize deeper lung structures.

## EXAMINATION APPROACH

The examination is performed in the horizontal position for neonates and in the sitting and supine positions for the older patients. The chest wall is divided into 6 areas by the anterior and posterior axillary lines. Each area is scanned from the apex to the base, and the probe should be positioned perpendicular to the ribs for each intercostal space.

## PRINCIPLE AND TERMINOLOGY

The injured lung has a remarkable increase in tissue extending to the lung periphery that produces ultrasound artifacts caused by the abnormal interface of tissue/gas/tissue. And the LUS images are primarily made up of these ultrasound artifacts. The LUS image can be simplified as follows: The normal lung is “black,” the moderately diseased lung (with interstitial water) is “black and white” (with white lines corresponding to B-lines), and the markedly diseased lung (with alveolar edema) is “white” (diffusely bright).

**Address for correspondence:** Dr. Jing Liu,  
Department of Neonatology and NICU of Bayi Children's Hospital,  
Beijing Military General Hospital, Beijing 100700, China  
E-Mail: liujingbj@live.cn

This is an open access article distributed under the terms of the Creative Commons Attribution-NonCommercial-ShareAlike 3.0 License, which allows others to remix, tweak, and build upon the work non-commercially, as long as the author is credited and the new creations are licensed under the identical terms.

**For reprints contact:** reprints@medknow.com

© 2015 Chinese Medical Journal | Produced by Wolters Kluwer - Medknow

**Received:** 18-04-2015 **Edited by:** Yuan-Yuan Ji  
**How to cite this article:** Chen SW, Zhang MY, Liu J. Application of Lung Ultrasonography in the Diagnosis of Childhood Lung Diseases. Chin Med J 2015;128:2672-8.

### Access this article online

Quick Response Code:



**Website:**  
www.cmj.org

**DOI:**  
10.4103/0366-6999.166035

## Pleural line and lung sliding

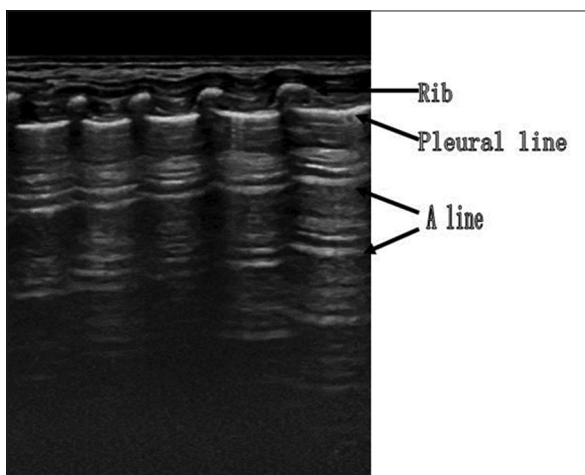
The pleural line is a smooth regular hyperechogenic and sliding line with a thickness of lesser than 0.5 mm below the rib line. Abnormalities of the pleural line include disappearance, thickness more than 0.5 mm, evidence of small subpleural consolidation and coarse or irregular appearance.<sup>[5]</sup> Lung sliding is the movement of the pleura synchronized with respiration in a to-and-fro pattern.<sup>[6]</sup> In time motion mode, a “seashore sign” is present, which highlights a clear distinction between the motionless parietal tissue over the pleural line and a sand-like pattern below it [Figures 1 and 2].<sup>[7]</sup>

## A-lines

An A-line arises from the reverberation artifact of the pleural line. A-lines beyond the pleural line are characterized by a series of parallel and equidistant lines on LUS. The spacing of the A-line is equal to the distance between the pleural line and the skin [Figures 1 and 2].<sup>[8]</sup>

## B-lines and comet-tail artifacts

B-lines project from the pleural line to the edge of the screen, erase A-lines, and move synchronously with respiratory movement.<sup>[7,9]</sup> The presence of B-lines is caused by an ultrasound beam encountering the alveolar gas–liquid interface. Previous research has shown that B-lines are linked to the interstitial syndrome and might be useful in assessing adults with heart failure.<sup>[10-13]</sup> B-lines cannot be seen in the lungs of children or adults, but they can be found in neonates, because the fetal lung has a high fluid content.<sup>[14]</sup> The comet-tail artifact is gradually weakening parallel lines that have the appearance of a comet-tail.<sup>[10]</sup> Many people seem to believe that B-lines and comet-tails are the same things because they both are related to the presence of the alveolar gas–liquid interface. However, their mechanisms are different; B-lines are ring-down artifacts, and comet-tail signs are caused by a type of reverberation artifact. In clinical practice,



**Figure 1:** Normal lung pattern. Longitudinal scan is showing the ribs, pleural line, and A-lines. A-line arises from the reverberation artifact of the pleural line and is characterized by a series of parallel and equidistant lines. The spacing of the A-line is equal to the distance between the pleural line and the skin.

lines reaching the edge of the screen without fading can be considered “B-lines,” whereas those that do not reach the edge of the screen can be considered “comet-tails” [Figure 2].

## Interstitial syndrome

The interstitial syndrome is the presence of areas of “white lung” or the presence of more than three B-lines in every examined area.<sup>[5]</sup>

## Bilateral “white lung”

Bilateral “white lung” is when compact B-lines appear in all 6 areas.<sup>[5]</sup>

## Spared areas

Spared areas are the areas of the normal pattern that extend for at least one intercostal space in the longitudinal scan and are surrounded by areas of the interstitial syndrome.<sup>[5]</sup>

## Lung pulse

Lung pulse is when lung sliding is replaced by a type of pulsation, synchronized with heart activity, which represents the early specific sign of complete atelectasis on LUS.<sup>[15]</sup>

## Lung point

The lung point is the abnormal lung pattern in a particular location on the chest wall and is a specific sign of pneumothorax on ultrasound.<sup>[16]</sup>

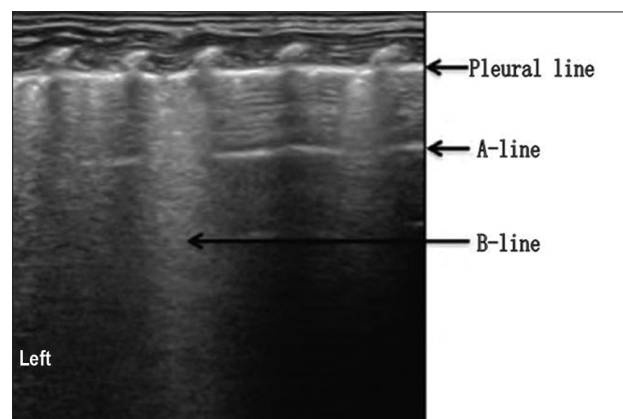
## Double lung point

The sharp cut-off point between the upper and lower lung fields with a longitudinal scan is known as a “double lung point (DLP).”<sup>[14]</sup>

## APPLICATION OF LUNG ULTRASONOGRAPHY IN THE DIAGNOSIS OF LUNG DISEASES IN CHILDREN

### Respiratory distress syndrome

Respiratory distress syndrome (RDS) is characterized by diffuse lesions of the pulmonary capillaries and enhancement



**Figure 2:** B-line. Those reaching the edge of the screen are called B-lines. B-lines project from the pleural line to the edge of the screen, erase A-lines, and move synchronously with respiratory movement. The presence of B-lines is caused by an ultrasound beam encountering the alveolar gas–liquid interface.

of permeability. Its primary pathological changes are pulmonary edema, atelectasis, and the formation of transparent membrane, and its clinical features are progressive dyspnea and refractory hypoxemia. The main features of RDS on LUS are as follows:<sup>[5,17,18]</sup> Lung consolidation with air bronchogram, decrease or disappearance of lung sliding, disappearance of spared areas, alveolar-interstitial syndrome, pleural line abnormalities, pleural effusion, lung pulse and bilateral “white lung.” Although “white lung” or pleural effusion are the features of RDS, it is also found in transient tachypnea of newborn (TTN) and other lung diseases.<sup>[14,19]</sup> However, the presence of a DLP discriminates TTN from RDS because it does not exist in RDS and has both a specificity and sensitivity of 100% in diagnosing TTN.<sup>[14]</sup> Furthermore, the presence of lung consolidation can distinguish RDS from TTN because it does not exist in TTN.<sup>[2,5,14]</sup> When compared with bedside CR, LUS has a higher diagnostic accuracy for consolidation, pleural effusion, and interstitial syndrome in patients with RDS, and it has been shown that the nature and extent of lesions in bilateral lung can be different.<sup>[20]</sup> Moreover, LUS can detect changes in lung morphology preceding changes in the oxygenation index (Arterial oxygen tension $[PaO_2]$ /Inspired oxygen fraction $[FiO_2]$ ) in animals with RDS [Figure 3].<sup>[21]</sup>

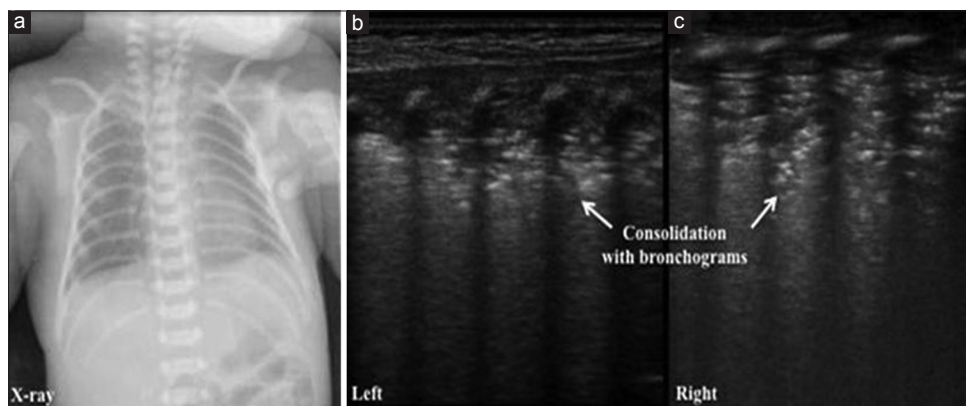
Patients with RDS always require treatment with mechanical ventilation and positive end-expiratory pressure (PEEP) because low respiratory compliance and reduced aerated lung volume are the main features of RDS, and its aim is to prevent end-expiratory alveolar collapse and to open closed alveoli. Therefore, it is necessary to assess the efficacy of different methods of assessing ventilation and lung volume. Currently, the methods of reference mainly are CT scan and pressure-volume (P-V) curves. Recently, bedside LUS has become a new and useful way to assess lung aeration.<sup>[22,23]</sup> The advantages of LUS include the reduction of risks of transportation and radiation, as well as the ability to gradually increase ventilation pressure and reduce the risk of barotrauma. Clinical research has found a highly significant correlation between CT and the “ultrasound lung re-aeration

score” (the sum of each area score according to the four stages of lung aeration examined by LUS) in patients with ventilator-associated pneumonia after antibiotic therapy.<sup>[24]</sup> The ultrasound re-aeration score for assessing PEEP-induced lung recruitment was also highly linked to P-V curves.<sup>[25]</sup> These research studies indicate that LUS is a good method to assess PEEP-induced lung recruitment at the bedside.

### Pneumonia

Pneumonia is defined as a respiratory tract infection illness. The pulmonary ultrasonic signs of pneumonia include a hypoechoic area of varying shape and size with irregular margins of heterogeneous echogenicity.<sup>[26,27]</sup> Moreover, the ultrasound also includes air bronchograms (multiple lentil-sized echoes within the lesion), dynamic air bronchograms, and pleural effusion. Occasionally, a positive fluid bronchogram (echo-poor or echo-free tubular structures without any perfusion signals) might be found in pneumonia by LUS. The most characteristic feature of pneumonia on LUS is air bronchogram, which was detected in approximately 70–97% of cases.<sup>[26,27]</sup> Air bronchograms reflect residual air within consolidated areas similar to the visible air bronchogram sign on CT and CR. Simultaneously, pleural effusion was detected in more than two-thirds of pneumonia cases.<sup>[26,28]</sup> Both neonatal pneumonia and community-acquired pneumonia in children had a similar features on LUS.<sup>[29-31]</sup> The features mainly included air bronchograms, lung consolidation, pleural line abnormalities, and pleural effusion [Figure 4].<sup>[28,31]</sup>

A meta-analysis showed that LUS had a high sensitivity (94%) and specificity (96%) for diagnosing pneumonia in adults and was superior to CR.<sup>[32]</sup> LUS also had a consistently high diagnostic accuracy of pneumonia when compared with chest CT scan as the gold standard.<sup>[19,27,33]</sup> In another study of infants with bronchiolitis regarded as a special type of pneumonia, LUS was a good tool for the diagnosis and evaluation of follow-up, and LUS can detect lung abnormalities that cannot be revealed by CR.<sup>[20]</sup> Several studies have shown that, LUS was a useful tool for diagnosing pneumonia in children.<sup>[28,31,34]</sup> Furthermore,



**Figure 3:** Respiratory distress syndrome on lung ultrasonography. (a) Chest radiography showed grade III appearance in an infant with severe respiratory distress syndrome. (b and c) Lung ultrasound showed significant consolidation (arrow) with air bronchogram, the pleural line and A-line disappearance in the same infant.



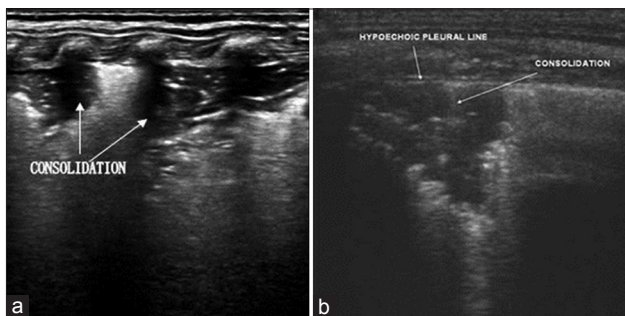
several authors have emphasized that the specific anatomical features of children (such as shorter thoracic width, thinner chest wall, and small lung mass) make the LUS examination of pneumonia in children easier than in adults.<sup>[35]</sup>

### Pneumothorax

Pneumothorax is defined as air between the visceral and the parietal pleura. It can be quickly life-threatening.<sup>[36]</sup> Because of the mechanism of pneumothorax, the movement of the visceral pleura on the parietal pleura cannot be seen because they fill with air. Therefore, the ultrasound of pneumothorax shows no lung sliding. Similarly, the B-lines cannot be seen because they originate from the visceral pleura. The lung point is a critical feature of pneumothorax on LUS because it confirms that the absence of lung sliding is authentic and cannot be ascribed to technical errors. The presence of lung point, the absence of B-lines, the absence of lung sliding, and lung pulse are the four most important sonographic images used to diagnose pneumothorax by LUS [Figure 5].<sup>[23,37-39]</sup>

The identification of a lung point is essential to confirm the presence of a pneumothorax. One study showed that its specificity in diagnosing pneumothorax was 100%, although its sensitivity was only 66%.<sup>[16]</sup> However, another research study showed that both its sensitivity and specificity were 100% in diagnosing pneumothorax.<sup>[6]</sup> As for B-lines or the comet-tail sign in pneumothorax, their negative predictive value is 99.2–100%.<sup>[22,37-40]</sup> Absent lung sliding is an initial and basic step for diagnosing pneumothorax. The absence of lung sliding has a predictive value of 100% in diagnosing pneumothorax, whereas its specificity and sensitivity were 91.1% and 95.3%, respectively.<sup>[41]</sup> In the case of absent lung sliding, the A-lines sign would contribute to distinguishing pneumothorax from effusion, (being absent in the latter).

LUS has proven superior to radiography in diagnosing pneumothorax.<sup>[42]</sup> A meta-analysis indicates that LUS is more accurate than CR for diagnosing pneumothorax.<sup>[43]</sup> Therefore, LUS is accurate in diagnosing pneumothorax.



**Figure 4:** Pneumonia on lung ultrasonography. (a) Neonatal pneumonia on lung ultrasonography showed large consolidations with irregular edges, as well as air bronchograms. The pleural line was either blurred or disappeared, and the A-line disappeared. (b) Community-acquired pneumonia in children on lung ultrasonography shows less echogenic pleural line above the lung consolidation with irregular edges, air bronchograms, and A-line disappeared.

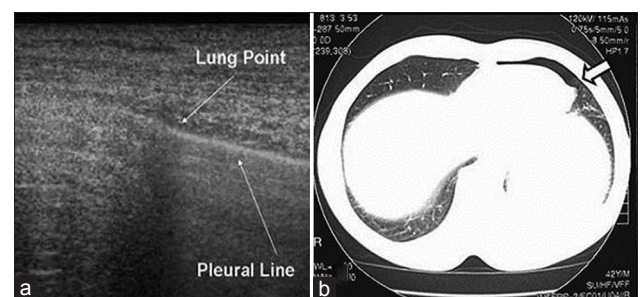
### Pulmonary atelectasis

Pulmonary atelectasis is characterized by a state of collapsed and nonaerated region of the lung parenchyma resulting from parenchymal compression (nonobstructive atelectasis) or bronchial obstruction (obstructive atelectasis).

The main features of atelectasis on LUS include lung consolidation and air bronchograms.<sup>[5,44,45]</sup> In most cases, a static air bronchogram is seen, whereas a dynamic air bronchogram is not. The presence of a dynamic air bronchogram not only can rule out atelectasis but also allows the discrimination between inflammatory and alveolar consolidation of atelectasis.<sup>[15,44,45]</sup> In some case with total or near-total opacification of the hemithorax, LUS has a high sensitivity in differentiating between consolidation of atelectasis and pleural effusion, whereas CR is unable to make this distinction.<sup>[46]</sup> LUS has been used in diagnosing atelectasis in children, and its sensitivity was 100% in our research [Figure 6].<sup>[44]</sup> Because the main ultrasound images of RDS have the same signs of lung consolidation and air bronchograms as pulmonary atelectasis,<sup>[47]</sup> how can they be distinguished? According to our experience,<sup>[45,47]</sup> the following features might contribute to their differences: (1) The air bronchogram image in atelectasis has a linear and parallel arrangement, whereas in RDS the air bronchogram is seen as dots and irregularity, which is related to the extent and scope of lung consolidation. (2) The air bronchogram of atelectasis is static, and a dynamic air bronchogram can exclude atelectasis. (3) The edge of wide local atelectasis is quite regular and different from the pulmonary parenchyma without consolidation. (4) The signs of pleural effusion and white lung can be seen often in RDS but not in atelectasis.

### Transient tachypnea of the newborn

TTN is one of the most common causes of perinatal dyspnea. The incidence rates of TTN are from 4.0% to 5.7% among term infants and 10.0% among premature infants.<sup>[48]</sup> Because the main pathological feature of TTN is excessive water in the lung tissues, the interstitial syndrome is the most common and important ultrasonic manifestations of TTN.<sup>[49]</sup> In addition, white lung or even pleural effusion can be detected in patients with severe TTN. The common ultrasonographic



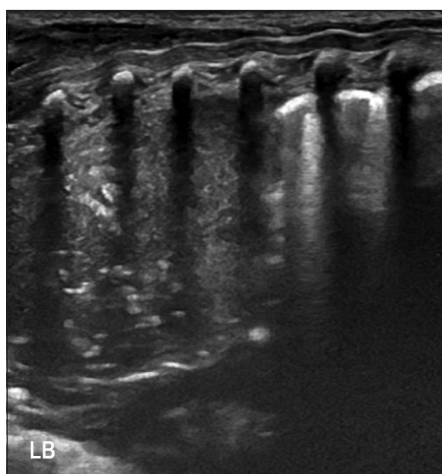
**Figure 5:** Pneumothorax on lung ultrasonography. (a) Lung ultrasonography shows lung point in patient with pneumothorax. The lung point is the abnormal lung pattern in a particular location on the chest wall and is a specific sign of pneumothorax on ultrasound. (b) Anterior pneumothorax on computed tomography scan with delimitation (arrow) in the same patient.

manifestations of TTN are interstitial syndrome or white lungs, DLP, pleural line abnormalities, and A-line disappearance [Figure 7].<sup>[14,49]</sup> Although, TTN rarely leads to death, it is necessary to correctly differentiate TTN from other diseases with dyspnea, such as RDS, pneumonia, and meconium aspiration syndrome (MAS), to correctly manage infants with TTN and dyspnea. It is estimated that over 70% of infants with TTN are clinically misdiagnosed with RDS.<sup>[48]</sup> In particular, infants with dyspnea whose CR examinations show a white lung feature are often diagnosed with RDS. Given that CR cannot correctly differentiate TTN and RDS, is LUS a more useful method?

Based on the previous literature reports,<sup>[5,8,50,51]</sup> lung consolidation with air bronchograms without DLP was the primary ultrasonic feature of RDS, whereas DLP without lung consolidation was the most specific ultrasonic feature of TTN. Therefore, LUS can easily differentiate TTN from RDS. Furthermore, studies with LUS also showed that the ultrasonic features of different lung fields could be variable, reinforcing the idea that the water content of the lung tissue (i.e., the degree of pulmonary edema) in different areas is inconsistent in patients with TTN.<sup>[49]</sup>

### Meconium aspiration syndrome

MAS is a life-threatening neonatal lung injury induced by meconium in the airways and lung tissue. A previous research on six patients with MAS found that the following features were seen in all patients on LUS:<sup>[52]</sup> (1) B-pattern (interstitial) coalescent or sparse; (2) consolidations; (3) bronchograms; and (4) atelectasis. There is no specific pattern for the distribution of these signs in different lung areas. Although, both CR and LUS show easily interpreted and typical findings in MAS, LUS has the added advantage of real-time evaluation of the lungs at both the airway level and the parenchyma, thereby describing more closely the clinical situation [Figure 8]. More researches of LUS on MAS are needed in the future.



**Figure 6:** Pulmonary atelectasis on lung ultrasonography. Lung ultrasonography showed a large area of consolidation with clearly demarcated borders and air bronchograms (hyperechogenic lines in the area of consolidation) and fluid bronchograms (hypoechoic lines in the area of consolidation).

### Identification of long-term oxygen dependence in premature


Identification of long-term oxygen dependence (LTOD) is one of the most commonly encountered respiratory problems in preterm infants, particularly in patients with a GA <32 weeks. This condition is often diagnosed as either bronchopulmonary dysplasia (BPD) or neonatal chronic lung disease in oxygen-dependent infants >28 days of life.<sup>[53]</sup> However, the definition focuses only on the time of oxygen dependence and does not consider specific reasons for the dependence. As a result, this approach clearly has significant limitations and might result in over-diagnosis and poor understanding of BPD, which might lead to both unnecessary and unreasonable interventions, even subsequently adverse consequences.

We recently conducted LUS examinations on 49 patients with BPD and found that LTOD was caused by inflammation, atelectasis, severe pulmonary edema, and coexisting consolidation in more than one-third of the infants enrolled in the study. This means that more than one-third of these cases of LTOD were caused by either BPD alone or diseases other than BPD.<sup>[54]</sup> Therefore, it is necessary to modify the diagnostic criteria for BPD as soon as possible.

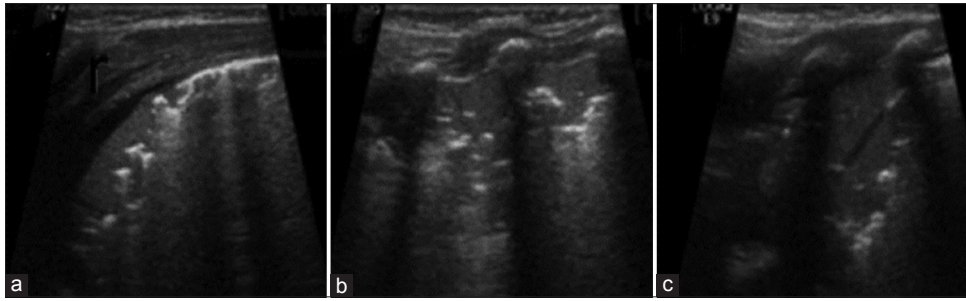
Although lung ultrasound helps differentiate causes of neonatal LTOD, diagnosing BPD with lung ultrasound is difficult; thus, how to diagnose BPD by ultrasound requires further study and represents our future research direction.

### LIMITATIONS OF LUNG ULTRASONOGRAPHY

The limitations of LUS include the inability to visualize the paravertebral regions (beneath the scapulae) and the difficulty in examining some patients who are characterized as hypo-echogenic (e.g., patients with obesity, subcutaneous emphysema, dressings/wounds). Furthermore, dyspneic patients often lie in nonoptimal positions, which



**Figure 7:** Transient tachypnea of the newborn on lung ultrasonography. Lung ultrasonography showed interstitial syndrome and double lung point (arrow) in transient tachypnea of newborn, the sharp cut-off point between the upper and lower lung fields with a longitudinal scan is known as a "double lung point".



**Figure 8:** Meconium aspiration syndrome on lung ultrasonography. Longitudinal and horizontal scans of the anterior and postero-lateral chest wall were performed in the supine position. Lung ultrasonography showed an irregular and thickened pleural line (panel a), multiple B-lines (panels a-c), as well as multiple consolidations (panels b and c), and numerous bronchograms (panels b and c).

limits the examination of certain lung areas. Air leak syndromes (pneumomediastinum, pneumopericardium, and interstitial emphysema) cannot be easily identified using LUS. In addition, it is difficult to diagnose BPD by using LUS.

## SUMMARY

In this paper, we focus on the characteristics of LUS in diagnosing childhood pulmonary disease. LUS is convenient, noninvasive, and free of radiation. It helps in the differentiation of lung diseases. Therefore, LUS has the potential to become a reference instrument for bedside dynamic respiratory monitoring. We hope that this review will help clinicians become acquainted with LUS and will accelerate the extensive application of LUS in children.

## Financial support and sponsorship

This study was supported by a grant of the Clinical Research Special Fund of Wu Jieping Medical Foundation (No. 320.6750.15072).

## Conflicts of interest

There are no conflicts of interest.

## REFERENCES

1. Wardlaw T, Salama P, Johansson EW, Mason E. Pneumonia: The leading killer of children. *Lancet* 2006;368:1048-50.
2. Liu J. Lung ultrasound for the diagnosis of neonatal respiratory distress syndrome (in Chinese). *J Appl Clin Pediatr* 2014;29:1438-40.
3. Raimondi F CL, Copetti R. Point-of-care chest ultrasound in the neonatal intensive care unit: An Italian perspective. *Neoreviews* 2014;15:e2-6.
4. Via G, Storti E, Gulati G, Neri L, Mojoli F, Braschi A. Lung ultrasound in the ICU: From diagnostic instrument to respiratory monitoring tool. *Minerva Anestesiol* 2012;78:1282-96.
5. Copetti R, Cattarossi L, Macagno F, Violino M, Furlan R. Lung ultrasound in respiratory distress syndrome: A useful tool for early diagnosis. *Neonatology* 2008;94:52-9.
6. Lichtenstein DA, Menu Y. A bedside ultrasound sign ruling out pneumothorax in the critically ill. *Lung sliding*. *Chest* 1995;108:1345-8.
7. Lichtenstein DA, Mezière G, Lascols N, Biderman P, Courret JP, Gepner A, *et al*. Ultrasound diagnosis of occult pneumothorax. *Crit Care Med* 2005;33:1231-8.
8. Lichtenstein DA, Lascols N, Mezière G, Gepner A. Ultrasound diagnosis of alveolar consolidation in the critically ill. *Intensive Care Med* 2004;30:276-81.
9. Dénier A. Ultrasound: Its application to diagnosis. *Presse Med* 1946;22:307-8.
10. Lichtenstein D, Mezière G, Biderman P, Gepner A, Barré O. The comet-tail artifact. An ultrasound sign of alveolar-interstitial syndrome. *Am J Respir Crit Care Med* 1997;156:1640-6.
11. Lichtenstein D, Mezière G. A lung ultrasound sign allowing bedside distinction between pulmonary edema and COPD: The comet-tail artifact. *Intensive Care Med* 1998;24:1331-4.
12. Copetti R, Soldati G, Copetti P. Chest sonography: A useful tool to differentiate acute cardiogenic pulmonary edema from acute respiratory distress syndrome. *Cardiovasc Ultrasound* 2008;6:16.
13. Koenig SJ, Narasimhan M, Mayo PH. Thoracic ultrasonography for the pulmonary specialist. *Chest* 2011;140:1332-41.
14. Copetti R, Cattarossi L. The ‘double lung point’: An ultrasound sign diagnostic of transient tachypnea of the newborn. *Neonatology* 2007;91:203-9.
15. Lichtenstein DA, Lascols N, Prin S, Mezière G. The ‘‘lung pulse’’: An early ultrasound sign of complete atelectasis. *Intensive Care Med* 2003;29:2187-92.
16. Lichtenstein D, Mezière G, Biderman P, Gepner A. The ‘‘lung point’’: An ultrasound sign specific to pneumothorax. *Intensive Care Med* 2000;26:1434-40.
17. Lichtenstein D, Goldstein I, Mourgeon E, Cluzel P, Grenier P, Rouby JJ. Comparative diagnostic performances of auscultation, chest radiography, and lung ultrasonography in acute respiratory distress syndrome. *Anesthesiology* 2004;100:9-15.
18. Bober K, Swietlinski J. Diagnostic utility of ultrasonography for respiratory distress syndrome in neonates. *Med Sci Monit* 2006;12:CR440-6.
19. Lichtenstein DA. Lung ultrasound in the critically ill. *Ann Intensive Care* 2014;4:1.
20. Caiulo VA, Gargani L, Caiulo S, Fiscicaro A, Moramarco F, Latini G, *et al*. Lung ultrasound in bronchiolitis: Comparison with chest X-ray. *Eur J Pediatr* 2011;170:1427-33.
21. Gargani L, Lionetti V, Di Cristofano C, Bevilacqua G, Recchia FA, Picano E. Early detection of acute lung injury uncoupled to hypoxemia in pigs using ultrasound lung comets. *Crit Care Med* 2007;35:2769-74.
22. Arbelot C, Ferrari F, Bouhemad B, Rouby JJ. Lung ultrasound in acute respiratory distress syndrome and acute lung injury. *Curr Opin Crit Care* 2008;14:70-4.
23. Volpicelli G, Elbarbary M, Blaivas M, Lichtenstein DA, Mathis G, Kirkpatrick AW, *et al*. International evidence-based recommendations for point-of-care lung ultrasound. *Intensive Care Med* 2012;38:577-91.
24. Bouhemad B, Liu ZH, Arbelot C, Zhang M, Ferarri F, Le-Guen M, *et al*. Ultrasound assessment of antibiotic-induced pulmonary reabsorption in ventilator-associated pneumonia. *Crit Care Med* 2010;38:84-92.
25. Bouhemad B, Brisson H, Le-Guen M, Arbelot C, Lu Q, Rouby JJ. Bedside ultrasound assessment of positive end-expiratory pressure-induced lung recruitment. *Am J Respir Crit Care Med* 2011;183:341-7.
26. Reissig A, Kroegel C. Sonographic diagnosis and follow-up of



- pneumonia: A prospective study. *Respiration* 2007;74:537-47.
27. Reissig A, Copetti R, Mathis G, Mempel C, Schuler A, Zechner P, *et al.* Lung ultrasound in the diagnosis and follow-up of community-acquired pneumonia: A prospective, multicenter, diagnostic accuracy study. *Chest* 2012;142:965-72.
  28. Copetti R, Cattarossi L. Ultrasound diagnosis of pneumonia in children. *Radiol Med* 2008;113:190-8.
  29. Ho MC, Ker CR, Hsu JH, Wu JR, Dai ZK, Chen IC. Usefulness of lung ultrasound in the diagnosis of community-acquired pneumonia in children. *Pediatr Neonatol* 2015;56:40-5.
  30. Caiulo VA, Gargani L, Caiulo S, Fiscaro A, Moramarco F, Latini G, *et al.* Lung ultrasound characteristics of community-acquired pneumonia in hospitalized children. *Pediatr Pulmonol* 2013;48:280-7.
  31. Liu J, Liu F, Liu Y, Wang HW, Feng ZC. Lung ultrasonography for the diagnosis of severe neonatal pneumonia. *Chest* 2014;146:383-8.
  32. Chavez MA, Shams N, Ellington LE, Naithani N, Gilman RH, Steinhoff MC, *et al.* Lung ultrasound for the diagnosis of pneumonia in adults: A systematic review and meta-analysis. *Respir Res* 2014;15:50.
  33. Xirouchaki N, Magkanas E, Vaporidi K, Kondili E, Plataki M, Patrianakos A, *et al.* Lung ultrasound in critically ill patients: Comparison with bedside chest radiography. *Intensive Care Med* 2011;37:1488-93.
  34. Kurian J, Levin TL, Han BK, Taragin BH, Weinstein S. Comparison of ultrasound and CT in the evaluation of pneumonia complicated by parapneumonic effusion in children. *AJR Am J Roentgenol* 2009;193:1648-54.
  35. Riccabona M. Ultrasound of the chest in children (mediastinum excluded). *Eur Radiol* 2008;18:390-9.
  36. Steier M, Ching N, Roberts EB, Nealon TF Jr. Pneumothorax complicating continuous ventilatory support. *J Thorac Cardiovasc Surg* 1974;67:17-23.
  37. Elia F, Ferrari G, Molino P, Aprà F. Lung ultrasound in postprocedural pneumothorax. *Acad Emerg Med* 2010;17:e81-2.
  38. Soldati G, Testa A, Sher S, Pignataro G, La Sala M, Silveri NG. Occult traumatic pneumothorax: Diagnostic accuracy of lung ultrasonography in the emergency department. *Chest* 2008;133:204-11.
  39. Volpicelli G. Sonographic diagnosis of pneumothorax. *Intensive Care Med* 2011;37:224-32.
  40. Husain LF, Hagopian L, Wayman D, Baker WE, Carmody KA. Sonographic diagnosis of pneumothorax. *J Emerg Trauma Shock* 2012;5:76-81.
  41. McLoud TC, Flower CD. Imaging the pleura: Sonography, CT, and MR imaging. *AJR Am J Roentgenol* 1991;156:1145-53.
  42. Galbois A, Ait-Oufella H, Baudel JL, Kofman T, Bottero J, Viennot S, *et al.* Pleural ultrasound compared with chest radiographic detection of pneumothorax resolution after drainage. *Chest* 2010;138:648-55.
  43. Alrajab S, Youssef AM, Akkus NI, Caldito G. Pleural ultrasonography versus chest radiography for the diagnosis of pneumothorax: Review of the literature and meta-analysis. *Crit Care* 2013;17:R208.
  44. Lichtenstein D, Mezière G, Seitz J. The dynamic air bronchogram. A lung ultrasound sign of alveolar consolidation ruling out atelectasis. *Chest* 2009;135:1421-5.
  45. Liu J, Chen SW, Liu F, Li QP, Kong XY, Feng ZC. The diagnosis of neonatal pulmonary atelectasis using lung ultrasonography. *Chest* 2015;147:1013-9.
  46. Yu CJ, Yang PC, Wu HD, Chang DB, Kuo SH, Luh KT. Ultrasound study in unilateral hemithorax opacification. Image comparison with computed tomography. *Am Rev Respir Dis* 1993;147:430-4.
  47. Liu J, Cao HY, Wang HW, Kong XY. The role of lung ultrasound in diagnosis of respiratory distress syndrome in newborn infants. *Iran J Pediatr* 2014;24:147-154.
  48. Greenough A. Transient tachypnea of the newborn. In: Greenough A, Milner AD, editors. *Neonatal Respiratory Disorder*. 2<sup>nd</sup> ed. London: CRC Press; 2003. p. 272-7.
  49. Liu J, Wang Y, Fu W, Yang CS, Huang JJ. Diagnosis of neonatal transient tachypnea and its differentiation from respiratory distress syndrome using lung ultrasound. *Medicine (Baltimore)* 2014;93:e197.
  50. Lovrenski J. Lung ultrasonography of pulmonary complications in preterm infants with respiratory distress syndrome. *Ups J Med Sci* 2012;117:10-7.
  51. Stefanidis K, Dimopoulos S, Tripodaki ES, Vitzilaios K, Politis P, Piperopoulos P, *et al.* Lung sonography and recruitment in patients with early acute respiratory distress syndrome: A pilot study. *Crit Care* 2011;15:R185.
  52. Piastra M, Yousef N, Brat R, Manzoni P, Mokhtari M, De Luca D. Lung ultrasound findings in meconium aspiration syndrome. *Early Hum Dev* 2014;90 Suppl 2:S41-3.
  53. Mosca F, Colnaghi M, Fumagalli M. BPD: Old and new problems. *J Matern Fetal Neonatal Med* 2011;24 Suppl 1:80-2.
  54. Liu J, Chen SW, Liu F, Wang Y, Kong XY, Li QP, *et al.* BPD, Not BPD, or iatrogenic BPD: Findings of lung ultrasound examinations. *Medicine (Baltimore)* 2014;93:e133.