

Comparison of posterior corneal elevation in children with and without vernal keratoconjunctivitis using a new tomographer

Kavitha V, Mallikarjun M Heralgi, Saba Aafreen

Purpose: To assess the posterior corneal elevation (PCE) in children with vernal keratoconjunctivitis (VKC) and compare the same with that of age and gender-matched normal children. **Methods:** This was a case control study. We included 110 children attending the Pediatric ophthalmology outpatient department of a tertiary eye care center in South India between September 2019 and June 2020. Fifty-five children with VKC and 55 normal age and gender-matched children were examined by Sirius tomographer/topographer (CSO, Italy) to determine the PCE, thinnest corneal thickness (TCT), simulated K (Sim K), keratoconus front (KVf) and keratoconus vertex back (KVb). The parameters were compared between the two groups. **Results:** A total of 220 eyes of 110 children were examined. The mean age in both groups was 10.44 ± 3.28 years, each group included 44 males and 11 females. There was no statistically significant difference in TCT and Sim K between the two groups. The mean PCE was $18.8 \pm 8.4 \mu\text{m}$ in VKC group and $11.7 \pm 3.9 \mu\text{m}$ in control group ($P < 0.001$). Both KVf and KVb were significantly higher in VKC group when compared to the control group. **Conclusion:** Children with VKC have significantly higher PCE as measured by Sirius tomographer, and hence, all VKC children should be screened for development of KC and the Sirius tomographer may be an appropriate tool for the same.

Key words: Keratoconus, keratoconus vertex back, keratoconus vertex front, posterior corneal elevation, sirius tomographer, thinnest corneal thickness, vernal keratoconjunctivitis

Vernal keratoconjunctivitis (VKC) is a chronic, bilateral, external ocular inflammatory disease occurring in children and young adults with a seasonal recurrence.^[1]

Corneal involvement occurs in severe form of disease which may result in complications like astigmatism, keratoconus, microbial keratitis, shield ulcer, vernal plaques, corneal scarring, and limbal stem cell deficiency.^[2-4] Diagnosis is easily arrived at based on history and typical clinical findings. There are three forms of VKC: palpebral, limbal, and mixed.^[5]

Keratoconus is bilaterally asymmetrical, progressive thinning and conical protrusion of the apical cornea. It is a proven complication of severe and prolonged VKC.^[1,3]

Several clinical and quantitative analytical studies have shown the frequency of association between VKC and keratoconus. In the cohort of patients enrolled in the Collaborative Longitudinal Evaluation of Keratoconus Study, nearly 50% reported rubbing both eyes vigorously.^[6] VKC in the tropical climate of India is essentially similar to that seen in other tropical countries and KC was prevalent in 6% of VKC patients.^[7]

While the diagnosis of moderate to advanced KC can be easily made by clinical signs and slit-lamp examination, subclinical keratoconus goes undetected as there are no clinical findings and in most cases vision gets fully corrected with spectacle. In this scenario, diagnosis can be made only after topographic examination.^[8]

Videokeratography is the most effective method for detecting keratoconus like pattern. Recent studies have proven that corneal changes in keratoconus start on the posterior corneal surface; therefore, it is considered as an important

clinical tool in detection of subclinical cases of KC.^[9,10] Diagnosing KC in early stages in children with VKC plays an important role, as it has an aggressive course in children.^[11]

Several topographic parameters and indices have been used to analyze the corneal characteristics in VKC patients. To our best knowledge, none of the studies have assessed either posterior corneal elevation (PCE) or other keratoconus indices (which were included in our study) in VKC patients using the Sirius tomographer (CSO, Italy). The purpose of our study was to determine the PCE using a new tomographer-Sirius.

Methods

The sample size was calculated considering 90% power and 95% level of confidence with reference to previous study (Topographic corneal changes in patients with VKC by Dantas *et al.*^[12]). The estimated sample size was 55 in study group and 55 in control group.

This case control study included 110 children attending the Pediatric ophthalmology outpatient department of a tertiary eye care center between September 2019 and June 2020. The study was halted during the COVID-19 lockdown period (between March 21 and May 31). In the month of June, six children were recruited, COVID-19 safety protocols were followed while examining these children. The study group had 55 children (VKC group), aged between 5 and 18 years who were clinically diagnosed with VKC.

This is an open access journal, and articles are distributed under the terms of the Creative Commons Attribution-NonCommercial-ShareAlike 4.0 License, which allows others to remix, tweak, and build upon the work non-commercially, as long as appropriate credit is given and the new creations are licensed under the identical terms.

For reprints contact: WKHLRPMedknow_reprints@wolterskluwer.com

Cite this article as: Kavitha V, Heralgi MM, Aafreen S. Comparison of posterior corneal elevation in children with and without vernal keratoconjunctivitis using a new tomographer. *Indian J Ophthalmol* 2021;69:2060-3.

Access this article online

Website:

www.ijo.in

DOI:

10.4103/ijo.IJO_35_21

Quick Response Code:



Sankara Eye Hospital, Shimoga, Karnataka, India

Correspondence to: Dr. Kavitha V, Sankara Eye Hospital, Thirthahalli Road, Harakere, Shimoga, Karnataka, India. E-mail: kavithachalam2@gmail.com

Received: 04-Jan-2021

Revision: 07-Mar-2021

Accepted: 30-Jun-2021

Published: 26-Jul-2021

Children with allergic ocular diseases other than VKC, children with VKC having ocular conditions which precluded the eye from topographic examination, children with VKC having any systemic diseases, children with VKC with established KC (confirmed by the presence of keratometric, topographic, retinoscopic, and slit-lamp findings), previous history of shield ulcer, corneal scars, history of surgery, contact lens wear and trauma, children/parents unwilling to participate, children uncooperative for examination and topography were excluded from the study.

The control group included 55 age and gender-matched children examined during the same period, with no history of ocular diseases, ocular or systemic allergy, previous ocular trauma, or surgery.

The purpose and procedure of study were explained and an informed written consent was taken from all parents/guardians. The approval of implementation of the study was taken from the ethics review committee of Institute. The research protocol was conducted in accordance with the tenets of the Declaration of Helsinki for research involving human subjects.

Detailed history including age of onset, duration of symptoms of VKC, visual difficulties, and past medical history was taken. Details regarding the birth history, developmental history, family history of allergy, and other ocular and systemic conditions were noted. Uncorrected and best-corrected distance visual acuity with Log MAR chart at 3 m and near vision with Jaeger chart at 33 cm, each eye was tested separately. Anterior segment examination was done using torch light and slit-lamp biomicroscopy. Intraocular pressure was measured using a noncontact tonometer, and in case of uncooperative children, tonopen was used after topography. The diagnosis of VKC was made on the basis of typical clinical history and signs by well-experienced ophthalmologists. Corneal topography was performed on all nondilated eyes using a Sirius tomographer (Costruzione Strumenti Oftalmici, Florence, Italy) by a single examiner. After appropriate alignment of the instrument, the operator triggered the acquisition sequence and scanned the cornea. Three images were taken from each eye and the one with best centration and greatest corneal coverage area was included in the study.

The following indices were measured:

- i. Thinnest corneal thickness (TCT) in micro meters

- ii. Simulated keratometry (Sim k) in diopters (D) represents the simulation of the readings that would be obtained with a keratometer. Average Sim k is average of Sim K1 and Sim K2. It is the mean sagittal curvature from the fourth to the eighth placido ring.^[13]
- iii. PCE (micro meters) in central 5 mm zone: PCE is elevation of the corneal surface with respect to a best fit reference surface. The radius of the reference surface (Rbf) represents the radius of the sphere that best approximates the cornea being examined (Best Fit Radius). The radius of the best-fit sphere is selected in such a manner as to minimize the mean square error of the corneal elevations with respect to the reference surface. It is represented in microns, and in reference to the Klyce/Wilson scale, the warm colors (red, orange, yellow) indicate the areas projecting above the reference surface and the cool colors (green, blue) indicate areas lying below the reference surface.
- iv. Keratoconus index front and back (KVf and KVb): these are the highest points of ectasia on the corneal surface with respect to asphero toric reference sphere for the anterior and posterior surface of cornea.

After topography, children were dilated with cyclopentolate hydrochloride 1% one drop twice at an interval of 10 min and one drop of tropicamide plus 1% eye drops and subjected to dilated retinoscopy and fundus examination using an indirect ophthalmoscope and a +20 Diopter lens.

Statistical analysis

The data were analyzed descriptively first with mean and then standard deviation estimates were derived. Categorical variables were expressed as frequencies and percentages. The comparison of variables between the groups was performed using Student's *t* test. Nominal categorical data between the groups was compared using Chi-square test as appropriate. *P* value < 0.05 was considered significant.

Statistical testing was conducted with the statistical package for the social science system version SPSS 23.0.0.

Results

A total of 220 eyes of 110 children between 5 and 18 years were examined: 110 eyes of 55 children with VKC (VKC group) and 110 eyes of 55 normal children (control group). Both groups

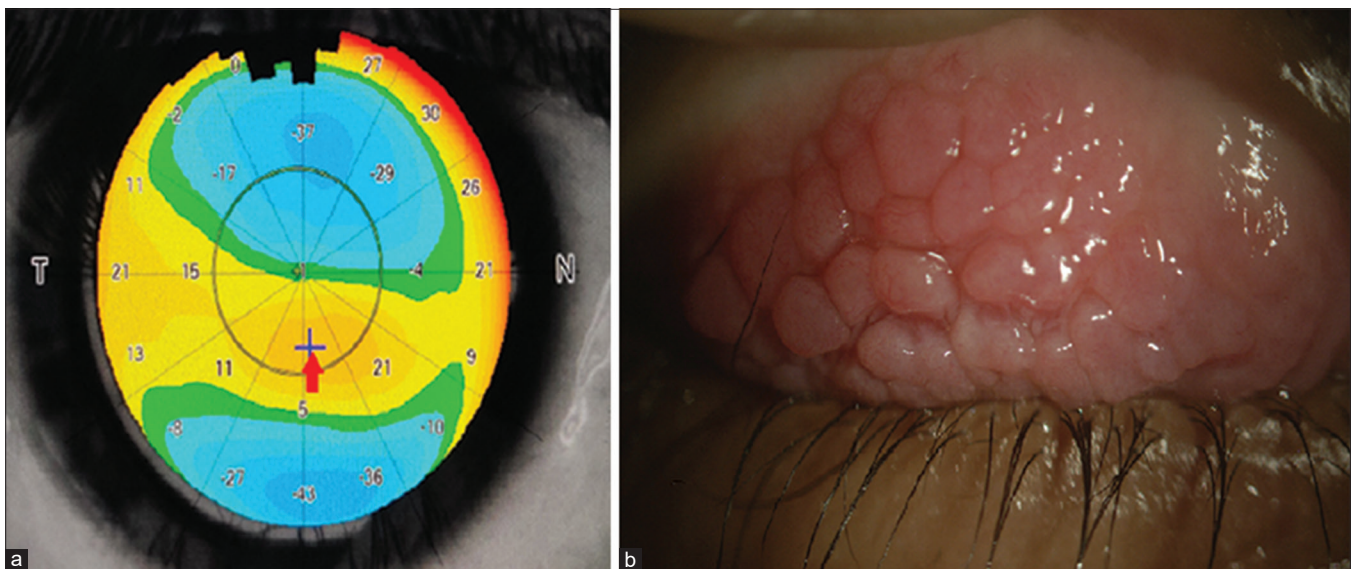


Figure 1: (a) Posterior corneal elevation map of a VKC child; vertical red arrow shows highest posterior corneal elevation and the horizontal red arrow corresponds to its value. (b) Cobblestone papillae in the same child

included 44 male children (80%) and 11 female children (20%), with an average age of 10.44 ± 3.28 years. IOP was not recorded in the six children who were recruited in June (during COVID-19 pandemic). Table 1 summarizes the minimum and maximum TCT, Sim K, PCE, KVf, and KVb in VKC and control groups. There was no significant statistical difference in TCT and SimK between the two groups. However, PCE, KVf, and KVb values were significantly higher in the VKC group when compared to the control group. The comparison of topographic indices between the VKC and control group has been presented in Table 2.

Five eyes of four children had PCE $\geq 40 \mu\text{m}$ ($47 \mu\text{m}$ being highest); out of the five eyes, three eyes had mixed astigmatism with mixed VKC and two eyes had compound myopic astigmatism with mixed VKC. Forty-five out of 110 eyes (40.9%) in the VKC group had refractive error. Most of the control group children were emmetropic: 74 eyes of 38 children (67.2%) and 22 eyes of 12 (20%) children had simple hypermetropia ($< -4\text{D}$), and both eyes of 1 child (1.8%) had mixed astigmatism (Cylinder $< 2\text{D}$). Distribution of PCE in both the groups has been summarized in Table 3.

Thirty-four VKC group children (61.8%) had duration of symptoms for ≤ 3 years with an average PCE of $17.15 \mu\text{m}$. Sixteen children (29.09%) had VKC symptoms for 4–6 years; their average PCE was $21.36 \mu\text{m}$. The remaining five children (9%) had symptoms for 7–10 years; the average PCE in them was $22 \mu\text{m}$ (PCE in all 10 eyes was more than $15 \mu\text{m}$). A 14-year-old male child had longest duration of symptoms of 10 years, with a PCE of OD: $30 \mu\text{m}$ and OS: $34 \mu\text{m}$. However, the highest PCE was recorded in a 7-year-old male child with the duration of symptoms of just 2 years (OD: $40 \mu\text{m}$, OS: $47 \mu\text{m}$). By this, we can understand that PCE is dependent on duration as well as severity of VKC.

Fig. 1a: Sirius PCE map, Fig. 1b shows cobblestone papillae in the same patient.

In Table 4, corneal indices of only the right eyes of the VKC and control groups have been compared, in order to eliminate the correlational effect that might have occurred by considering both eyes.

Discussion

Researchers have studied various corneal topographic parameters in VKC patients with an aim to detect keratoconus in early stages.^[12,14,15] Most of the studies done to assess topographic changes in VKC patients have used placido-based topographers,^[12,14-16] Penacam (Oculus Wetzlar, Germany) or Orbscan (Bosh and Lomb).^[17,18] Assessment of PCE using Sirius tomographer has not been done so far to study corneal changes in VKC patients. The Sirius tomography system has shown good repeatability and intrasessional reproducibility for anterior segment parameters.^[14,19]

In our study, VKC was four times more prevalent in males than in females, which included 44 (80%) males and 11 (10%) females. This pattern of male predilection is consistent with the previous literature in which the male to female ratio has been reported to be from 4:1 to 2:1.^[12,16,20]

We found TCT to be $539.35 \pm 31.5 \mu\text{m}$ in the VKC group and $542.114 \pm 29.6 \mu\text{m}$ in the normal group, which was not a significant difference. However, Gautam V *et al.*,^[16] Barreto J *et al.*,^[17] and Safarzadeh M *et al.*,^[9] in their studies found statistical difference in the corneal thickness between VKC and control groups.

In our study, the average Sim K in the VKC group was $43.673 \pm 1.68 \text{ D}$ and the same in the control group was $43.39 \pm 1.44 \text{ D}$. In the VKC group, the highest Sim K was seen in an 11-year-old female with a diagnosis of OU mixed VKC with compound myopic astigmatism, with a cylinder of -3.75 D in

OD and -2.5 D in OS; she had Sim K of 47.6 D in both the eyes, the PCE was $24 \mu\text{m}$ in OD and $17 \mu\text{m}$ in the OS. By this, we can also infer that the PCE may not depend on the astigmatic status of eye.

Table 1: Minimum and maximum values of corneal indices

Corneal Indices	Minimum / Maximum	VKC group	Control group
TCT (μm)	Minimum	7	1
	Maximum	47	22
Sim K (Diopter)	Minimum	40	40.4
	Maximum	47.6	46.9
PCE (μm)	Minimum	7	1
	Maximum	47	22
KVf (μm)	Minimum	2	2
	Maximum	31	15
KVb (μm)	Minimum	3	2
	Maximum	31	19

VKC: Vernal keratoconjunctivitis, TCT: thinnest corneal thickness, Sim K: Simulated K, PCE: posterior corneal elevation, KVf: Keratoconus front, and KVb: Keratoconus vertex back

Table 2: Outcome of statistical analysis of cornea indices

	VKC Group	Control Group	P
TCT (μm)	539.35 ± 31.5	542.11 ± 29.6	0.85
Sim K (D)	43.673 ± 1.68	43.39 ± 1.44	0.3
PCE (μm)	18.8 ± 8.4	11.7 ± 3.9	< 0.001
KVf (μm)	8.891 ± 6.3	5.37 ± 1.96	< 0.001
KVb (μm)	13.12 ± 5.6	9.8 ± 2.9	< 0.001

Indices are described by mean and standard deviation. Statistical equivalence (two-tailed test significance > 0.05) between VKC and Control group has been performed. VKC: Vernal keratoconjunctivitis TCT: thinnest corneal thickness, Sim K: Simulated K, PCE: posterior corneal elevation, KVf: Keratoconus front, and KVb: Keratoconus vertex back

Table 3: Distribution of PCE in both the VKC and control group

	$< 12 \mu\text{m}$	$13-19 \mu\text{m}$	$20-29 \mu\text{m}$	$30-39 \mu\text{m}$	$> 40 \mu\text{m}$
VKC (number)	23	49	23	10	5
Control (number)	63	44	3	-	-

VKC: Vernal keratoconjunctivitis, PCE: posterior corneal elevation

Table 4: Corneal indices of right eyes and statistical analysis

	VKC group	Control group	P
TCT (μm)	539.54 ± 31.768	540.664 ± 28.672	0.85
SimK (D)	43.687 ± 1.56	43.391 ± 1.39	0.296
PCE (μm)	18.545 ± 8.651	11.927 ± 3.872	< 0.001
KVf (μm)	8.691 ± 6.146	5.145 ± 1.693	< 0.001
KVb (μm)	12.982 ± 5.658	9.273 ± 3.396	< 0.001

Indices are described by mean and standard deviation. Statistical equivalence (two-tailed test significance > 0.05) between VKC and Control group has been performed. VKC: Vernal keratoconjunctivitis TCT: thinnest corneal thickness, Sim K: Simulated K, PCE: posterior corneal elevation, KVf: Keratoconus front, and KVb: Keratoconus vertex back

Umale RH *et al.*,^[20] Barreto J *et al.*^[17], and Hakak DB *et al.*^[21] found higher keratometric readings (K max > 47 D) in VKC groups when compared to the control groups. However, we found only two eyes of a child with VKC having an average Sim K value of more than 47 D.

Studies in recent years have proven that posterior cornea is the earliest to get effected in keratoconus.^[8,22,23] We considered maximum PCE in the central 5 mm zone because the earliest keratoconus changes occur in the paracentral area rather than the central 3 mm zone.

In our study, the PCE was 18.7 ± 8.4 and 11.708 ± 3.9 μm in the VKC group and control group, respectively, which was a statistically significant difference. About 20.9% of VKC eyes had PCE similar to the control group.

Jackson Barreto *et al.*^[17] study suggested that the PCE in the VKC group was 49.40 ± 53.6 μm , and it was 28.90 ± 9.2 μm in the control group using Orbscan IIz. Masoud Safarzadeh *et al.*^[9] compared anterior segment characteristics of normal eyes to keratoconus eyes using the Sirius topographer. They found PCE to be 9.7 ± 3.6 μm in the normal group and 17.8 ± 11.7 μm in the suspect keratoconus group.

We found that keratoconus vertex front in the VKC group was 8.891 ± 6.3 μm and the same in the control group was 5.37 ± 1.96 μm . Likewise the keratoconus vertex back in the VKC group was 13.12 ± 5.6 μm and in the control group was 9.8 ± 2.9 μm . Both KVf and KVb values were significantly higher in the VKC group when compared to the control group. None of the children were detected as keratoconus compatible by the Sirius keratoconus screening system. The study which came closest to our results was by Mehdi Shajari *et al.*,^[22] where they studied early tomographic changes in the eyes of patients with keratoconus using Pentacam. They came to a similar conclusion that astigmatism, keratometry, and pachymetry hardly change in the early stages, so these values are not as important as corneal elevation parameters for early diagnosis of KC.

It is well known that VKC children are at higher risk of developing KC, but what percentage of these children will develop KC is not certain. From this study, we found that VKC eyes have abnormal posterior corneal parameters (PCE and KVb) when compared to normal eyes. Hence, all VKC children should be screened for development of KC and the Sirius tomographer may be reliable modality for the same. Since KC has an aggressive course in children,^[11] it is essential to detect the disease in early stages, by doing this we can benefit VKC children with early intervention and treatment options.

Limitations

Progression of corneal topographic changes in VKC children was not assessed as it was a cross-sectional study. The effect of severity, duration of VKC, and refractive error on PCE has not been analyzed in our study. It may not be accurate to generalize the data obtained from our study to other regions of the world, as the study sample was not big enough to apply the results for general population.

Conclusion

Children with VKC have significantly higher PCE as measured by Sirius tomographer, and hence, all VKC children should be screened for development of KC and the Sirius tomographer may be an appropriate tool for the same.

Financial support and sponsorship

Nil.

Conflicts of interest

There are no conflicts of interest.

References

- Leonardi A. Vernal keratoconjunctivitis: Pathogenesis and treatment. *Prog Retin Eye Res* 2002;21:319–39.
- Addis H, Jeng B. Vernal keratoconjunctivitis. *OPHTH* 2018;12:119–23.
- Ben-Eli H, Erdinest N, Solomon A. Pathogenesis and complications of chronic eye rubbing in ocular allergy. *Curr Opin Allergy Clin Immunol* 2019;19:526–34.
- Solomon A. Corneal complications of vernal keratoconjunctivitis. *Curr Opin Allergy Clin Immunol* 2015;15:489–94.
- Totan Y, Hepşen İF, Çekiç O, Gündüz A, Aydın E. Incidence of keratoconus in subjects with vernal keratoconjunctivitis. *Ophthalmology* 2001;108:824–7.
- Zadnik K, Barr JT, Edrington TB, Everett DF, Jameson M, McMahon TT, *et al.* Baseline findings in the Collaborative Longitudinal Evaluation of Keratoconus (CLEK) Study. *Invest Ophthalmol Vis Sci* 1998;39:2537–46.
- Saboo U, Sangwan V, Jain M, Reddy J. Demographic and clinical profile of vernal keratoconjunctivitis at a tertiary eye care center in India. *Indian J Ophthalmol* 2013;61:486.
- Uçakhan ÖÖ, Çetinkor V, Özkan M, Kanpolat A. Evaluation of Scheimpflug imaging parameters in subclinical keratoconus, keratoconus, and normal eyes. *J Cataract Refract Surg* 2011;37:1116–24.
- Safarzadeh M, Nasiri N. Anterior segment characteristics in normal and keratoconus eyes evaluated with a combined Scheimpflug/Placido corneal imaging device. *J Curr Ophthalmol* 2016;28:106–11.
- Miháltz K, Kovács I, Takács Á, Nagy ZZ. Evaluation of keratometric, pachymetric, and elevation parameters of keratoconic corneas with pentacam. *Cornea* 2009;28:976–80.
- Tuft SJ, Moodaley LC, Gregory WM, Davison CR, Buckley RJ. Prognostic factors for the progression of keratoconus. *Ophthalmology* 1994;101:439–47.
- Dantas PEC, Alves MR, Nishiwaki-Dantas MC. Topographic corneal changes in patients with vernal keratoconjunctivitis. *Arq Bras Oftalmol* 2005;68:593–8.
- Phoenix Company User Manual for Sirius CSO.90000017. rev. 0000. 05/2015.
- Masoud M, Livny E, Bahar I. Repeatability and intrasession reproducibility obtained by the Sirius anterior segment analysis system. *Eye Contact Lens* 2015;41:107–10.
- Ükponmwan CU. Vernal Keratoconjunctivitis in Nigerians: 109 Consecutive Cases. *Trop Doct* 2003;33:242–5.
- Gautam V, Chaudhary M, Sharma AK, Shrestha GS, Rai PG. Topographic corneal changes in children with vernal keratoconjunctivitis: A report from Kathmandu, Nepal. *Cont Lens Anterior Eye*. 2015;38:461–5.
- Barreto J, Netto MV, Santo RM, José NK, Bechara SJ. Slit-Scanning topography in vernal keratoconjunctivitis. *Am J Ophthalmol* 2007;143:250–4.e1.
- Kaya V, Karakaya M, Utine CA, Albayrak S, Oge OF, Yilmaz OF. Evaluation of the corneal topographic characteristics of keratoconus with orbscan II in patients with and without atopy. *Cornea* 2007;26:945–8.
- Nasser CK, Singer R, Barkana Y, Zadok D, Avni I, Goldich Y. Repeatability of the sirius imaging system and agreement with the pentacam HR. *J Refract Surg* 2012;28:493–7.
- Umale RH, Khan MA, Moulick PS, Gupta S, Shankar S, Sati A. A clinical study to describe the corneal topographic pattern and estimation of the prevalence of keratoconus among diagnosed cases of vernal keratoconjunctivitis. *Med J Armed Forces India* 2019;75:424–8.
- Hakak B, Khan A, Wani JS, Anjum N. Topographic corneal changes in patients with vernal keratoconjunctivitis-A cross sectional study. *J Med Sci Clin Res* 2018;6. doi: 10.18535/jmscr/v6i12.116.
- Shajari M, Jaffary I, Herrmann K, Grunwald C, Steinwender G, Mayer WJ, *et al.* Early tomographic changes in the eyes of patients with keratoconus. *J Refract Surg* 2018;34:254–9.
- Mahmoud MEA, Hamza IE, Assaf AH, Eliwa TF. Posterior corneal astigmatism changes in cases with keratoconus. *Egypt J Hosp Med* 2018;72:5433–7.