

Access this article online

Quick Response Code:



Website:
www.e-tjo.org

DOI:
10.4103/tjo.tjo_73_20

Lipemia retinalis with different therapeutic responses: A report of two cases

Chun-Chieh Lai¹, Chun-Hsiang Chang^{2*}

Abstract:

Lipemia retinalis is characterized by retinal blood vessels that are creamy white in color and is considered to be directly correlated to serum triglyceride levels. It is a rare retinal manifestation, with typical serum triglyceride levels above 2500 mg/dL required for its expression. We report two cases of lipemia retinalis with hypertriglyceridemia who presented with different retinal pictures during a 5-year follow-up. One showed a normalization of retinal vessels even though the serum triglyceride level was still far more than 2500 mg/dL (4660 mg/dL), but the other had persistent creamy white discoloration despite decreases in serum triglyceride level to below 2500 mg/dL (1031 mg/dL). This suggests that the absolute serum triglyceride level may not be the sole determinant of the typical retinal manifestation. In spite of this, early detection that leads to timely treatment will assist in prevention of severe ocular and systemic vascular complications.

Keywords:

Hypertriglyceridemia, lipemia retinalis, retina

Introduction

Lipemia retinalis, first described by Heyl in 1880, is characterized by retinal blood vessels that are creamy white in color and is considered to be directly correlated with serum triglyceride levels.^[1,2] It is a rare retinal manifestation, with typical serum triglyceride levels above 2500 mg/dL required for its expression.^[2-4] We report two cases of lipemia retinalis with hypertriglyceridemia, who each presented with different retinal pictures during a 5-year follow-up. One showed a normalization of retinal vessels even though the serum triglyceride level was still far more than 2500 mg/dL (4660 mg/dL), but the other had a persistent creamy white discoloration despite the serum triglyceride level being decreased to below 2500 mg/dL (1031 mg/dL).

This is an open access journal, and articles are distributed under the terms of the Creative Commons Attribution-NonCommercial-ShareAlike 4.0 License, which allows others to remix, tweak, and build upon the work non-commercially, as long as appropriate credit is given and the new creations are licensed under the identical terms.

For reprints contact: WKHLRPMedknow_reprints@wolterskluwer.com

Case Report

Case 1

A 56-year-old woman presented to the ophthalmology department for a fundus examination to screen for diabetic retinopathy. She had a past history of type 2 diabetes mellitus, chronic pancreatitis, and littoral cell angioma status post splenectomy. On examination of the fundus, creamy white discolorations in the retinal vessels were found in her eyes [Figure 1a]. She had normal vision, with visual acuity of 0.9 bilaterally. Laboratory studies revealed hypertriglyceridemia with a serum triglyceride level of 3500 mg/dL (normal: 50–200 mg/dL). Fluorescein angiography showed diabetic retinopathy with numerous microaneurysms at the posterior pole in both eyes without delayed filling. In addition, some lipid infiltrates in the retinal fiber layers with autofluorescence were noted around her right optic disc. She then received lipid-lowering agents in the endocrinology department.

How to cite this article: Lai CC, Chang CH. Lipemia retinalis with different therapeutic responses: A report of two cases. Taiwan J Ophthalmol 2021;11:405-7.

¹Department of Ophthalmology, National Cheng Kung University Hospital, ²Department of Medicine, National Cheng Kung University, Tainan, Taiwan

*Address for correspondence:

Dr. Chun-Hsiang Chang,
Department of Medicine,
National Cheng Kung University, 138,
Sheng Li Road,
Tainan 70403, Taiwan.
E-mail: chchang.sean@gmail.com

Submission: 08-08-2020
Accepted: 03-10-2020
Published: 20-01-2021

During 5-year follow-ups, her serum triglyceride levels had fluctuated. Follow-up fundus photography was recorded. Creamy white discolorations in the retinal vessels remained, even when her serum triglyceride level was decreased to 1031 mg/dL [Figure 1b].

Case 2

A 43-year-old woman with a history of type 2 diabetes mellitus and chronic pancreatitis presented to the ophthalmology department for a fundus examination to screen for diabetic retinopathy. On examination of the fundus, creamy white discolorations in the retinal vessels were found in her eyes [Figure 2a]. She had normal vision, with visual acuity of 0.9 bilaterally. Laboratory studies revealed hypertriglyceridemia with a serum triglyceride level of more than 5000 mg/dL (normal: 50–200 mg/dL). She then received lipid-lowering agents in the endocrinology department.

During 5-year follow-ups, her serum triglyceride levels had fluctuated, and follow-up fundus photography was taken. She presented with a normal appearance of retinal vessels when her serum triglyceride level was below or equal to 4660 mg/dL [Figure 2b].

Discussion

Lipemia retinalis is a pathognomonic ocular finding for hypertriglyceridemia.^[2-4] The associated characteristic creamy white appearance of retinal blood vessels is thought to be caused by the scattering light due to

triglyceride-laden chylomicrons in the plasma of blood vessels.^[1,2] Although vision usually remains unaffected, severe retinal vein occlusions with significant visual consequences may occur.^[4] In a previous report, decreased amplitudes of a- and b-waves in both cone and rod responses on electroretinography were described, indicating the possibility of some degree of retinal damage.^[5]

While previous studies suggest that retinal findings typically do not occur until the triglyceride level reaches 2500 mg/dL,^[2-4] neither of our patients followed this rule. One presented with a normal appearance of retinal vessels with a serum triglyceride level far beyond 2500 mg/dL (4660 mg/dL), whereas creamy white discoloration of the retinal vessels was still observed in the other despite a serum triglyceride level below 2500 mg/dL (1031 mg/dL). The two completely different manifestations suggest that the absolute serum triglyceride level may not be the sole determinant of the occurrence of lipemia retinalis.

While comparing case 1 to case 2, she had differences including: (1) a past history of a splenectomy more than 20 years before diagnosis, (2) a longer disease course of hypertriglyceridemia, (3) more advanced in age, and (4) genetic factors. These may contribute to the persistent abnormal appearance of the fundus even after a lipid-lowering treatment. However, more relevant experimental and clinical studies will be needed to support our hypothesis.

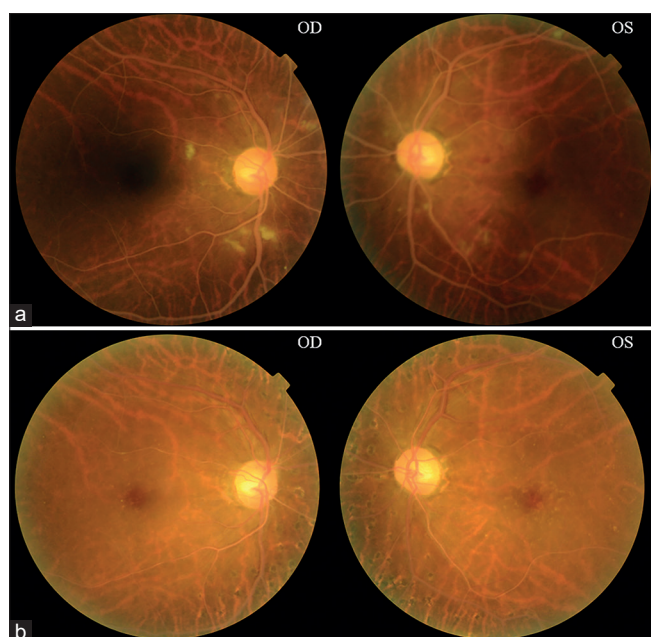


Figure 1: (a) Fundus photographs in the 56-year-old woman showed creamy white discolorations in the retinal vessels, cotton wool spots, and dot retinal hemorrhages. (b) The creamy white discolorations in the retinal vessels remained even when the serum triglyceride level was decreased to 1031 mg/dL.

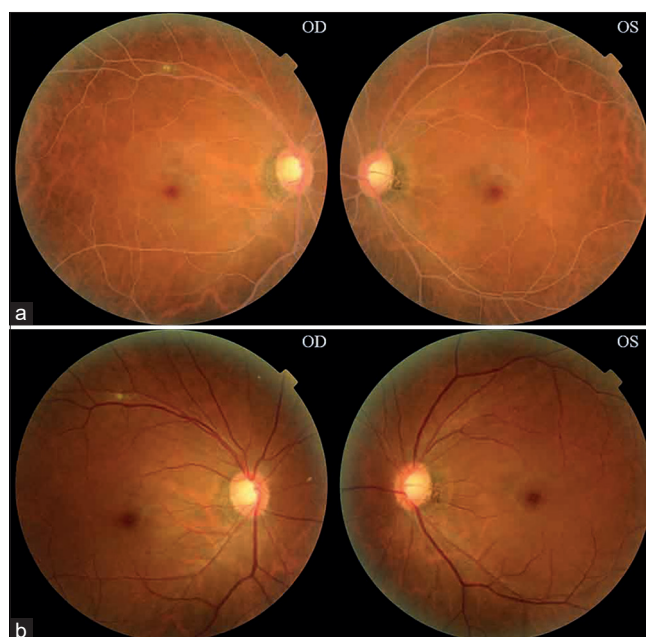


Figure 2: (a) Initial fundus photographs showed creamy white discolorations of the retinal vessels in this 43-year-old woman. (b) The color of the retinal vessels became normal when her serum triglyceride level was 4660 mg/dL.

Early detection and timely treatment is important because that lipemia retinalis is usually asymptomatic and found accidentally. This means that the time when we discover such finding, the patient may have suffered from hypertriglyceridemia for a long time. The longer the time of hypertriglyceridemia, the more damage is caused to the patient's vessel. On the other hand, retinal vessels belong to the category of peripheral vessels. This means that when the retinal vessels are damaged, other peripheral vessels such as renal vessels may have also been damaged. Therefore, once diagnosed, ophthalmologists should be aware of its underlying risks of life-threatening atherosclerotic diseases.^[1] Early detection and timely treatment with systemic lipid-lowering agents may prevent possible devastating consequences including retinal vessel occlusion diseases or systemic vascular complications.^[4]

Treatment options include: (1) adherence to a fat-restricted diet, (2) medication of fibric acid derivatives or *n*-3 polyunsaturated fatty acids, and (3) exchange transfusion or ileal bypass surgery may also be considered in special conditions.^[6] The goal of the treatment is to control the levels of serum triglyceride below 500 mg/dl.

Apart from regular follow-up at the endocrinologist outpatient unit, several tests may be considered to detect possible devastating consequences, including: (1) blood data of fats, cholesterol, sugar, and proteins, (2) electrocardiogram to detect the sign of heart damage, (3) ankle/brachial index to diagnose peripheral artery disease, (4) echocardiography to monitor the blood flow, and (5) computed tomography or angiography to show the conditions of vessels.

In conclusion, we report two cases of lipemia retinalis with hypertriglyceridemia, each of which presented with different retinal pictures during a 5-year follow-up. The absolute serum triglyceride level may not be the

sole determinant of the typical retinal manifestation. In spite of this, early detection leading to timely treatment would assist in prevention of severe ocular and systemic vascular complications.

Declaration of patient consent

The authors certify that they have obtained all appropriate patient consent forms. In the form, the patients have given their consent for their images and other clinical information to be reported in the journal. The patients understand that their names and initials will not be published and due efforts will be made to conceal their identity, but anonymity cannot be guaranteed.

Financial support and sponsorship

Nil.

Conflicts of interest

The authors declare that there are no conflicts of interests of this paper.

References

1. Rymarz E, Matysik-Woźniak A, Baltaziak L, Prystupa A, Sak J, Grzybowski A. Lipemia retinalis - An unusual cause of visual acuity deterioration. *Med Sci Monit* 2012;18:CS72-5.
2. Silva PS, Gupta A, Ajlan RS, Schlossman DK, Tolson AM, Cavallerano JD, *et al.* Ultrawide field scanning laser ophthalmoscopy imaging of lipemia retinalis. *Acta Ophthalmol* 2018;96:e643-6.
3. Park YH, Lee YC. Images in clinical medicine. Lipemia retinalis associated with secondary hyperlipidemia. *N Engl J Med* 2007;357:e11.
4. Nagra PK, Ho AC, Dugan JD Jr. Lipemia retinalis associated with branch retinal vein occlusion. *Am J Ophthalmol* 2003;135:539-42.
5. Lu CK, Chen SJ, Niu DM, Tsai CC, Lee FL, Hsu WM. Electrophysiological changes in lipaemia retinalis. *Am J Ophthalmol* 2005;139:1142-5.
6. Maki KC, Bays HE, Dicklin MR. Treatment options for the management of hypertriglyceridemia: Strategies based on the best-available evidence. *J Clin Lipidol* 2012;6:413-26.