

External syringomyelia – is it an evidence of focal spinal instability?

In the scenario of chronic, subtle or potential and less frequently manifest atlantoaxial instability, there are a number of secondary so-called “pathological” musculoskeletal, spinal structural, or neural alterations that include basilar invagination, Chiari formation, syringomyelia, Klippel-Feil alteration, assimilation of atlas, C2-3 fusion, os-odontoideum, bifid arch of atlas, platybasia, short neck, and torticollis.^[1-12] Whenever any of these radiologically identifiable alterations are present discretely or in the cohort, they are indicative of atlantoaxial instability and suggest the need for atlantoaxial stabilization. All these secondary alterations have a neural protective role and are potentially reversible following atlantoaxial stabilization. Our articles on the subject identified that chronic or long-standing atlantoaxial instability is more often of central or axial type atlanto-axial dislocation.^[13,14]

It was observed that in situations with chronic atlantoaxial instability, there could be excessive fluid or cerebrospinal fluid (CSF) inside the spinal cord (syringomyelia) or outside the spinal cord (external syringomyelia). Similarly, excessive CSF can be present in the medulla (syringobulbia) or outside the medulla (external syringobulbia).^[3,4,15] We reported the presence of external syringomyelia in benign foramen magnum tumors such as meningiomas and neurinomas.^[16] Essentially, it appeared that both external syringomyelia and syringomyelia have a protective role; they can be indicators of presence of atlantoaxial instability and suggest the need for atlantoaxial stabilization [Figures 1-3]. Apart from their location inside or outside the neural structures, both syringomyelia and external syringomyelia have similar significance and both indicate the presence of segmental or multisegmental spinal instability.

Like all other alterations that are secondary to chronic atlantoaxial instability, syringomyelia is characterized by

chronic relentlessly progressive symptoms that are initially subtle or marginal but are ultimately disabling. Other generally recognized causes of syringomyelia include benign spinal tumors, chronic infections, and trauma.^[17] In the year 2000, we proposed that syringomyelia is “always” protective and should not be directly manipulated by direct surgical drainage.^[17,18]

“Fluids” in the body form the basis of life and of movements. CSF is present inside the brain, outside the brain and through the brain, and inside and outside each and every cell. Our general observation is that CSF has a “divine” role in the formation, function, and protection of neural structures.

More recently, we identified central or axial atlantoaxial instability in cases with myelopathy related to multisegmental cervical spinal degeneration, ossification

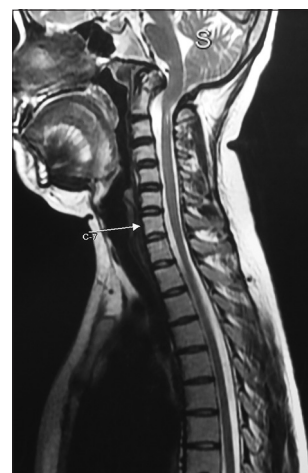

Figure 1: T2-weighted sagittal MRI showing Group B basilar invagination, Chiari formation and external syringomyelia. MRI - Magnetic resonance imaging

Submitted: 03-Sep-22
Published: 14-Sep-22

Accepted: 07-Sep-22

This is an open access journal, and articles are distributed under the terms of the Creative Commons Attribution-NonCommercial-ShareAlike 4.0 License, which allows others to remix, tweak, and build upon the work non-commercially, as long as appropriate credit is given and the new creations are licensed under the identical terms.

How to cite this article: Goel A. External syringomyelia – is it an evidence of focal spinal instability? J Craniovert Jun Spine 2022;13:221-3.


Access this article online	
Website: www.jcvjs.com	Quick Response Code 
DOI: 10.4103/jcvjs.jcvjs_109_22	

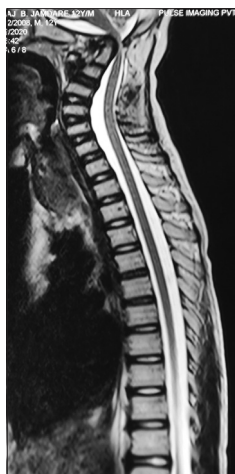

Figure 2: T2-weighted MRI showing Group A basilar invagination, external syringomyelia and external syringobulbia. MRI - Magnetic resonance imaging

of posterior longitudinal ligament, and Hirayama disease.^[19-21] Long-standing atlantoaxial instability can be associated with multisegmental subaxial spinal instability in these cases. One or more “secondary” and protective alteration can be associated in such cases. The presence of external syringomyelia can be indicative of segmental spinal instability. On some occasions, external syringomyelia can be a sole indicator of presence of spinal instability.

The extent of CSF cavitation necessary outside the confines of neural tissues to label it as external syringomyelia or external syringobulbia remains to be identified. Such presence of more than normal CSF is generally related to cord atrophy and to spinal degeneration and other similar “nonsurgical” clinical issues and is essentially ignored. In the absence of other defined causes that can be incriminated to result in spinal cord-related myelopathy, presence of external syringomyelia cannot be ignored and can be an additional radiological indicator of atlantoaxial and/or subaxial spinal instability. Association of alteration of spinal curvatures, facet mal-alignment, osteophytes, basilar invagination, evidence of rotatory dislocation, and similar such so-called “pathological” issues reinforce the clinical-radiological correlation. The identification and treatment of atlantoaxial instability can be a gratifying experience, both for the surgeon and for the patient.

ATUL GOEL^{1,2,3}

¹Department of Neurosurgery, Lilavati Hospital and Research Center, Bandra, ²Department of Neurosurgery, R.N Cooper Hospital and Medical College, ³Department of Neurosurgery, Bombay Hospital Institute of Medical Sciences, Mumbai, Maharashtra, India

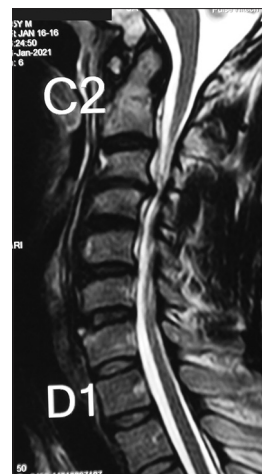


Figure 3: T2-weighted MRI showing multi-segmental cervical spondylotic disease. External syringomyelia can be seen. MRI - Magnetic resonance imaging

Address for correspondence: Prof. Atul Goel, Department of Neurosurgery, Lilavati Hospital and Research Center, Bandra, Mumbai, Maharashtra, India. E-mail: atulgoel62@hotmail.com

REFERENCES

1. Goel A. Goel's classification of atlantoaxial “facet” dislocation. *J Craniovertebr Junction Spine* 2014;5:3-8.
2. Goel A. Facetal alignment: Basis of an alternative Goel's classification of basilar invagination. *J Craniovertebr Junction Spine* 2014;5:59-64.
3. Goel A, Nadkarni T, Shah A, Sathe P, Patil M. Radiologic evaluation of basilar invagination without obvious atlantoaxial instability (Group B Basilar Invagination): Analysis based on a study of 75 patients. *World Neurosurg* 2016;95:375-82.
4. Goel A, Sathe P, Shah A. Atlantoaxial fixation for basilar invagination without obvious atlantoaxial instability (Group B Basilar Invagination): Outcome analysis of 63 surgically treated cases. *World Neurosurg* 2017;99:164-70.
5. Goel A. Is atlantoaxial instability the cause of Chiari malformation? Outcome analysis of 65 patients treated by atlantoaxial fixation. *J Neurosurg Spine* 2015;22:116-27.
6. Goel A, Jadhav D, Shah A, Rai S, Dandpat S, Vutha R, *et al.* Chiari 1 formation redefined-clinical and radiographic observations in 388 surgically treated patients. *World Neurosurg* 2020;141:e921-34.
7. Shah A, Sathe P, Patil M, Goel A. Treatment of “idiopathic” syrinx by atlantoaxial fixation: Report of an experience with nine cases. *J Craniovertebr Junction Spine* 2017;8:15-21.
8. Goel A. Cervical fusion as a protective response to craniovertebral junction instability: A novel concept. *Neurospine* 2018;15:323-8.
9. Goel A, Jadhav D, Shah A, Rai S, Dandpat S, Jadhav N, *et al.* Is C2-3 fusion an evidence of atlantoaxial instability? An analysis based on surgical treatment of seven patients. *J Craniovertebr Junction Spine* 2020;11:46-50.
10. Goel A, Nadkarni T, Shah A, Ramdasi R, Patni N. Bifid anterior and posterior arches of atlas: Surgical implication and analysis of 70 cases. *Neurosurgery* 2015;77:296-305.
11. Goel A, Shah A. Atlantoaxial facet locking: Treatment by facet manipulation and fixation. Experience in 14 cases. *J Neurosurg Spine* 2011;14:3-9.
12. Goel A, Vutha R, Shah A, Dharurkar P, Jadhav N, Jadhav D. Spinal kyphoscoliosis associated with chiari formation and syringomyelia ‘recovery’ following atlantoaxial fixation: A preliminary report and early results based on experience with 11 surgically treated cases. *World*

- Neurosurg 2019;125:e937-46.
13. Goel A. Central or axial atlantoaxial instability: Expanding understanding of craniovertebral junction. *J Craniovertebr Junction Spine* 2016;7:1-3.
 14. Goel A. A review of a new clinical entity of 'central atlantoaxial instability': Expanding horizons of craniovertebral junction surgery. *Neurospine* 2019;16:186-94.
 15. Goel A, Jain S, Shah A. Radiological evaluation of 510 cases of basilar invagination with evidence of atlantoaxial instability (group A basilar invagination). *World Neurosurg* 2018;110:533-43.
 16. Goel A, Shah AH, Vutha R, Goel A. External syringomyelia in longstanding benign foramen magnum tumors. *Surg Neurol Int* 2020;11:92.
 17. Goel A, Desai K. Surgery for syringomyelia: An analysis based on 163 surgical cases. *Acta Neurochir (Wien)* 2000;142:293-301.
 18. Goel A. Is syringomyelia pathology or a natural protective phenomenon? *J Postgrad Med* 2001;47:87-8.
 19. Goel A. Role of subaxial spinal and atlantoaxial instability in multisegmental cervical spondylotic myelopathy. *Acta Neurochir Suppl* 2019;125:71-8.
 20. Goel A, Grasso G, Shah A, Rai S, Dandpat S, Vaja T, *et al.* "Only spinal fixation" as surgical treatment of cervical myelopathy related to ossified posterior longitudinal ligament: Review of 52 cases. *World Neurosurg* 2020;140:556-63.
 21. Goel A, Dhar A, Shah A. Multilevel spinal stabilization as a treatment for hirayama disease: Report of an experience with five cases. *World Neurosurg* 2017;99:186-91.