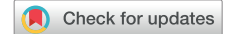

Defibrillation threshold testing: What is all that noise?



Ad W.G.J. Oomen, MD,* Robert Giles, MBBS, FRACP,[†] Zal Dastur, BSc,[†]
Kim H. Chan, BSc(Med), MBBS, PhD, FRACP*[‡]

From the *Department of Cardiology, Royal Prince Alfred Hospital, Camperdown, Australia, [†]Eastern Heart Clinic, Prince of Wales Hospital, Randwick, Australia, and [‡]Sydney Medical School, University of Sydney, Sydney, Australia.

Introduction

Noise detected on implantable cardioverter-defibrillator (ICD) systems is common and may be due to an external source or ICD malfunction.¹ To our knowledge, we report the first case of ICD noise detected on both device electrograms and external electrocardiogram (ECG) monitoring occurring after defibrillation threshold testing (DFT).

Case report

We present a case of a 27-year-old woman with long QT syndrome diagnosed following an episode of loss of consciousness after being woken up by a phone call. A dual-chamber ICD (Ellipse DR, 2277-36Q, St Jude Medical, Little Canada, MN) was implanted in the submammary position. The atrial lead (Tendril ST Optim 1888TC/58 cm, St Jude Medical) was positioned in the right atrial appendage and the right ventricular (RV) dual-coil shock lead (Durata 7120Q/58 cm, St Jude Medical) in the RV apex (Figure 1). The procedure was uncomplicated. Following the implant, an in-hospital DFT was performed, which was successful twice at 16 J.

Four years later, a vibratory alert was triggered by an elevated high-voltage lead impedance measurement involving the superior vena cava (SVC) coil. During interrogation of the device, the RV-to-SVC vector and SVC-to-can vectors showed high impedances. Tapping over the can produced noise in both vectors but not in the RV-to-can vector. Apart from the above-mentioned abnormalities, other lead parameters were satisfactory. Fluoroscopy of the RV shock lead and ICD generator did not reveal any abnormalities. The SVC coil was therefore turned off. A decision was made to repeat the DFT because of the changed shock configuration, owing to the fact that channelopathies are under-represented in randomized studies on DFT.²

KEYWORDS Defibrillation threshold testing; Device explantation; High-voltage shock; Implantable cardioverter-defibrillator; Noise (Heart Rhythm Case Reports 2019;5:457–460)

Dr Chan has received educational travel support from Medtronic and Abbott. The remaining authors report no conflicts of interest. **Address reprint requests and correspondence:** Dr Kim H. Chan, Department of Cardiology, Royal Prince Alfred Hospital, Missenden Rd, Camperdown, NSW 2050, Australia. E-mail address: kimhoe_chan@yahoo.com.au.

KEY TEACHING POINTS

- Transient implantable cardioverter-defibrillator (ICD) noise is commonly due to external noise/interference, although other common causes include lead integrity and connector issues and myopotentials oversensing.
- Transient ICD noise can lead to inappropriate shocks.
- It is unusual to detect noise on both ICD electrograms and external electrocardiogram monitoring after a high-voltage shock.

During the DFT, ventricular fibrillation was induced by DC Fibber (St Jude Medical) and was adequately sensed and detected. The ventricular fibrillation was terminated by

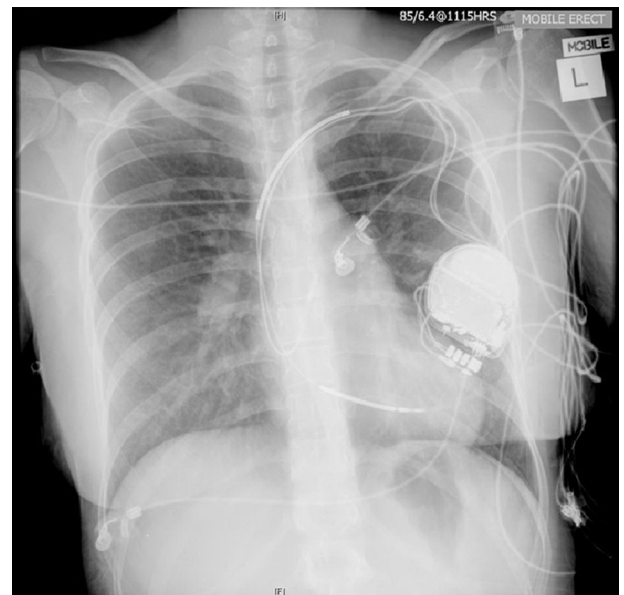


Figure 1 Chest radiograph showing submammary position of implantable cardioverter-defibrillator generator, dual-coil right ventricular shock lead, and right atrial lead.

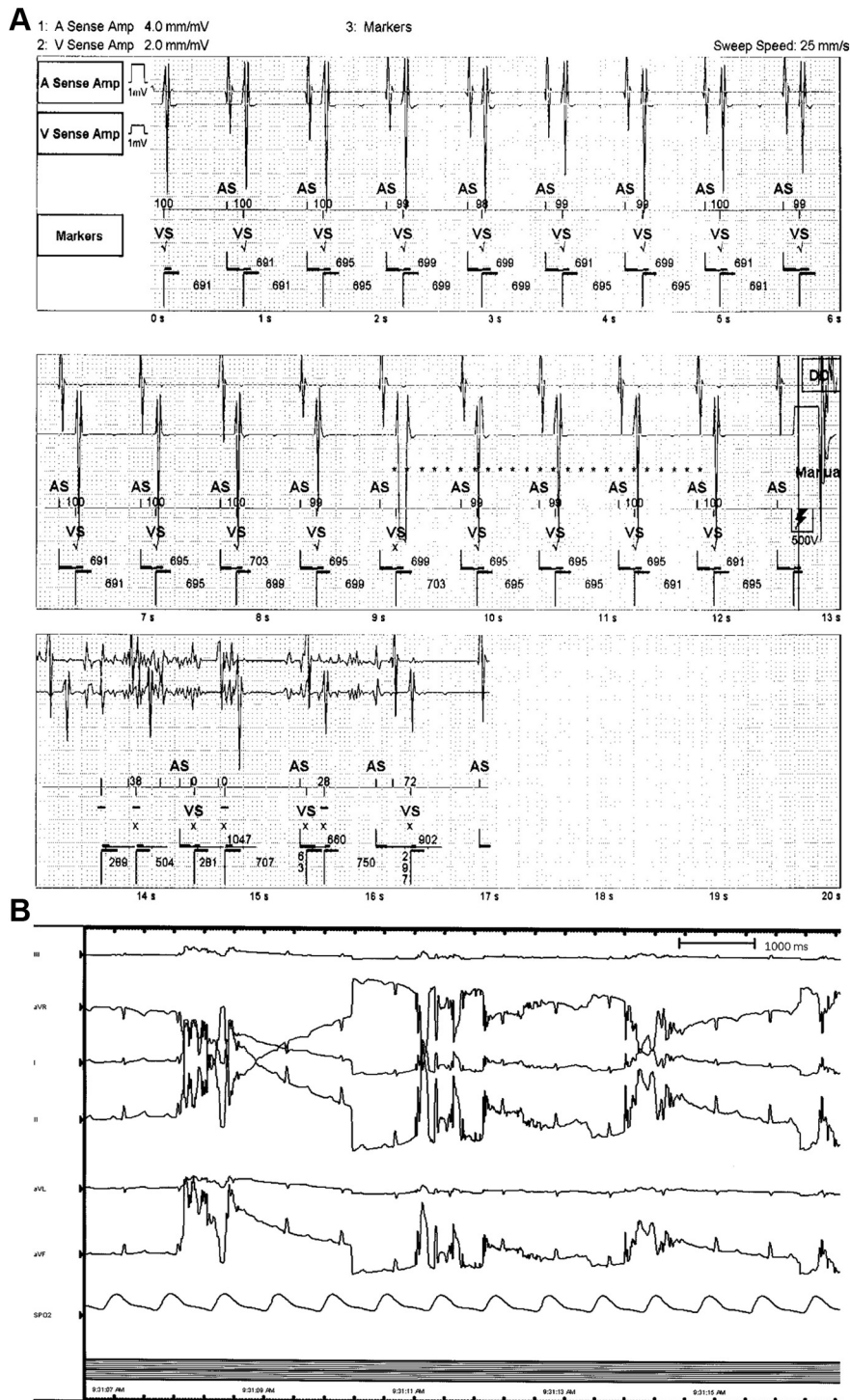


Figure 3 Noise recorded on **A**: stored intracardiac electrograms from the implantable cardioverter-defibrillator (ICD) and **B**: external electrocardiogram monitoring following a synchronized high-voltage shock prior to ICD explant at another hospital.

All lead measurements were unchanged before and after the DFT. The ICD tachycardia therapies were disabled owing to concerns regarding inappropriate ICD therapies and she was admitted to the cardiology ward for continuous rhythm monitoring. However, over the next few days no further noise was observed and the lead parameters remained unchanged.

Given the uncertainty about the cause of this noise and the risk of inappropriate shocks with noise, the decision was

made to explant the entire ICD system and reimplant a new ICD at another institution specializing in lead extraction. To explore whether the ICD noise observed previously was reproducible, a synchronized high-voltage shock was delivered by the ICD at the beginning of the procedure (prior to explant). Following this shock, the same noise was seen on both leads (Figure 3A) and external ECG monitoring system (Figure 3B). The ICD generator and leads were inspected at

time of extraction, with no abnormalities observed. The subsequent extraction and reimplantation of the ICD system was without complications.

Discussion

The differential diagnosis of ICD noise recorded on the lead electrograms includes electromagnetic interference from an external source, lead integrity issues (insulation breach, conductor coil fracture), myopotentials oversensing, lead-lead interactions, and lead/header connection problem.^{2,3} In the ALTITUDE NOISE study, 134 episodes of noise/artifact and oversensing were found when analyzing 1570 episodes of inappropriate shocks. External noise (57%) and lead/connector noise (28%) were the primary causes, followed by muscle noise (8%), oversensing of the atrium (5%), T-wave oversensing (2%), and other noise (not specified, 1%).⁴ In this case, noise from external electromagnetic interference is essentially excluded, as this abnormality was reproduced at 2 remote institutions/sites. Oversensing of myopotentials and lead-lead interactions are both also unlikely owing to the fact that the noise was only observed after a high-voltage shock. Lead/header connection problem is also unlikely, given that the noise was observed remote from the implant, device/pocket manipulation failed to reproduce the noise, and lead impedances were stable (with SVC coil turned off). While the RV shock lead had a lead integrity issue (ie, suspected SVC coil fracture owing to elevated SVC coil impedances), an isolated issue involving the RV shock lead is very unlikely, given the fact that the noise was apparent on both the right atrial and RV leads and also on all external ECG monitoring systems.

To our knowledge, this is the first report of such ICD malfunction. Our case is also in contrast to the report by Stroobandt and colleagues,⁵ who described a case of noise on both the near-field and far-field electrograms of an ICD RV shock lead following a 20 J test shock after battery replacement. However, this was clearly a lead problem and in that

case the noise was not apparent on other external ECG monitoring equipment.

Unfortunately, we do not have a definite explanation for the noise, and bench-top and saline bath testing performed by the company failed to replicate the noise we have observed or identify the cause of the malfunction. The most plausible explanations are a short circuit involving the ICD generator and/or high-voltage component, or current leakage after a high-voltage shock. However, the ICD lead parameters appeared to be satisfactory when checked before and after the DFT, with normal RV high-voltage lead impedances.

Conclusion

In summary, we report a case of transient ICD noise detected on device intracardiac electrograms as well as external ECG monitoring systems occurring after delivery of a high-voltage shock. Although no explanation has been found to date, we believe that it is important for the medical community to be aware of such a potential ICD malfunction. It remains to be seen whether this is an isolated event or whether this will become a more widespread issue with this particular brand/model of ICD.

References

1. Swerdlow CD, Asirvatham SJ, Ellenbogen KA, Friedman PA. Troubleshooting implanted cardioverter defibrillator sensing problems I. *Circ Arrhythm Electrophysiol* 2014;7:1237–1261.
2. Healey JS, Hohnloser SH, Glikson M, et al. Cardioverter defibrillator implantation without induction of ventricular fibrillation: a single-blind, non-inferiority, randomised controlled trial (SIMPLE). *Lancet* 2015;385:785–791.
3. Bracke FA, Meijer A, Van Gelder LM. Malfunction of endocardial defibrillator leads and lead extraction: where do they meet? *Europace* 2002;4:19–24.
4. Powell BD, Asirvatham SJ, Perschbacher DL, et al. Noise, artifact, and oversensing related inappropriate ICD shock evaluation: ALTITUDE NOISE study. *Pacing Clin Electrophysiol* 2012;35:863–869.
5. Stroobandt R, Hagers Y, Provenier F, Van Belle Y, Hamerlijnck R, Barold SS. Silent lead malfunction detected only during defibrillator replacement. *Pacing Clin Electrophysiol* 2006;29:67–69.