

## Coexisting Vestibular Schwannoma with Fibrous Dysplasia: A Rare Occurrence

### Abstract

Coexisting vestibular schwannoma (VS) with fibrous dysplasia is extremely rare. Here, we represent the case of a 48-year-old female with coexisting VS and fibrous dysplasia of overlying occipital bone. After proper evaluation, the patient underwent surgery and microscopic total excision of the right cerebellopontine angle lesion was achieved. However, during surgery, bone work was extremely tedious and exposure to reach up to lesion was difficult. To the best of our knowledge, this is the first reported case of coexisting fibrous dysplasia of overlying bone and VS as histopathological diagnosis.

**Keywords:** Coexistent, fibrous dysplasia, vestibular schwannoma

### Introduction

Coexistent vestibular schwannoma and fibrous dysplasia is a rare phenomenon. There is a distinct paucity of literature in this regard. Ours is probably the first such case association being reported, along with a discussion on probable clinical implications.

### Case Report

A 48-year-old female was admitted to the neurosurgery unit with a 3–5-month history of gradually increasing hearing loss on the right side along with neck pain. She was a known case of hypothyroidism on treatment. There was no personal or familiar history of brain diseases. Clinical examination showed profound right-sided hearing loss. Higher mental functions were preserved. There were no other deficits. A magnetic resonance imaging with contrast revealed a medium-sized extra-axial mass lesion in the right cerebellopontine angle (CPA) cistern extending into the right internal acoustic canal, suggestive of vestibular schwannoma (VS) with expanded clivus, right petrous apex, and left temporal and bilateral occipital bones with no abnormal postcontrast enhancement suggestive of benign bony pathology. The clinical presentation and neuroimaging appearance

led to an initial diagnosis of fibrous dysplasia with right VS [Figure 1].

A right retromastoid approach with right suboccipital craniectomy was taken, and microscopic total excision of right CPA lesion and duraplasty with fascia was done. Intraoperatively, an atypically thickened occipital bone was observed (>2.5 cm at places) [Figure 2]. Double layer of arachnoid was dissected off the tumor capsule. The lesion was extra-axial, yellowish white, soft to firm, and suckable with a well-defined capsule all around. Arachnoid strands connecting the upper and lower poles of the tumor to surrounding tissue were resected. Internal decompression was done with cavitron ultrasonic surgical aspirator (CUSA) and microsurgical procedures, maintaining the plane between inner arachnoid layer and tumor capsule. Facial nerve monitoring was used. The part of tumor going into internal auditory canal was also resected with ring curette. Gross total tumor excision was achieved, at end of which facial nerve was displayed to be anatomically and physiologically intact. Postoperative noncontrast computed tomography head was done, which showed complete tumor resection and bone windows delineated the dysplastic bone [Figure 3].

Bone and extra-axial lesion were sent for histopathological examination. Histopathological examination showed

This is an open access journal, and articles are distributed under the terms of the Creative Commons Attribution-NonCommercial-ShareAlike 4.0 License, which allows others to remix, tweak, and build upon the work non-commercially, as long as appropriate credit is given and the new creations are licensed under the identical terms.

For reprints contact: reprints@medknow.com

**How to cite this article:** Sharma V, Kedia R, Mohapatra I, Banerjee AD. Coexisting vestibular schwannoma with fibrous dysplasia: A rare occurrence. *Asian J Neurosurg* 2019;14:1295-7.

**Vikas Sharma,  
Rishabh Kedia,  
Ishani Mohapatra<sup>1</sup>,  
Anirban Deep  
Banerjee**

*Department of Neurosurgery,  
Institute of Neurosciences,  
Medanta the Medicity,  
<sup>1</sup>Department of Pathology,  
Medanta the Medicity, Gurgaon,  
Haryana, India*

### Address for correspondence:

*Dr. Anirban Deep Banerjee,  
Senior Consultant  
Neurosurgeon, Department  
of Neurosurgery, Institute of  
Neurosciences, Medanta the  
Medicity, Gurgaon - 122 001,  
Haryana, India.  
E-mail: banerjeeanirbandeep391@  
gmail.com*

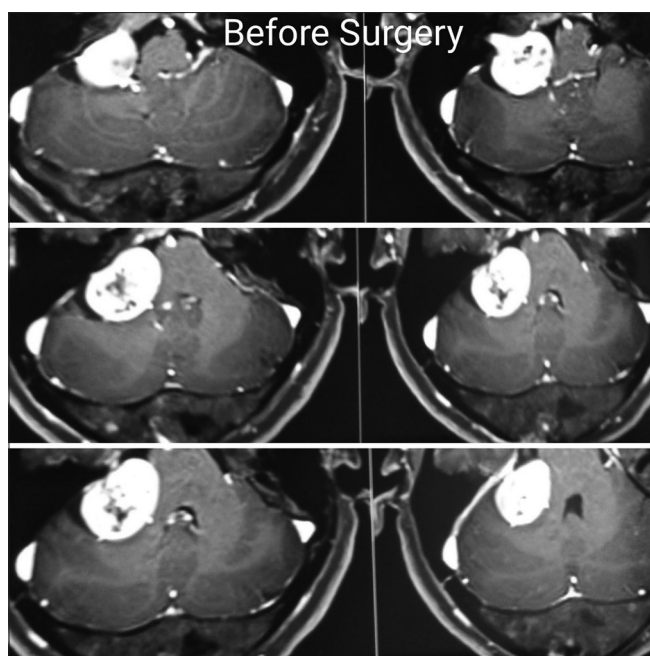
### Access this article online

**Website:** www.asianjns.org

**DOI:** 10.4103/ajns.AJNS\_73\_19

### Quick Response Code:





**Figure 1:** Magnetic resonance imaging with contrast revealed expanded bilateral occipital bones with a medium-sized extra-axial mass lesion in the right cerebellopontine angle cistern extending into the right internal acoustic canal suggestive of vestibular schwannoma

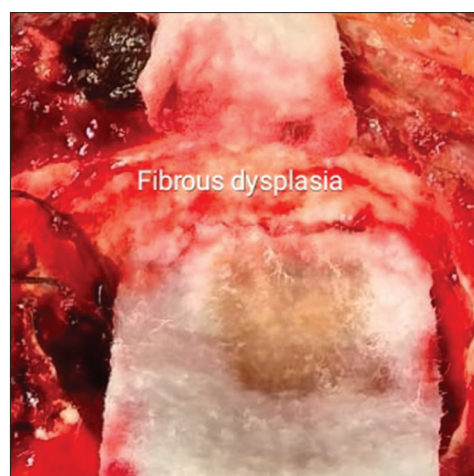bony trabeculae with marrow elements and adipose tissue and a lesion composed of spindle cell proliferation with production of woven bony trabeculae and focal prominent osteoblastic rimming with no evidence of atypia, necrosis, abnormal mitosis, or malignancy. These features favor a diagnosis of “osteofibrous dysplasia.” Other parts of the biopsy specimen showed spindle cell neoplasm with alternate hypo- and hypercellular areas, nuclear palisading, microcystic changes, and verocay bodies. There is no evidence of necrosis or abnormal mitosis. These features are suggestive of “vestibular schwannoma – WHO Grade 1.”

No complication was observed during the postoperative period. The patient was discharged 1 week after surgery with no further deterioration in facial nerve paresis as compared to before surgery status. The patient was able to completely close her eyes with minimal effort.

## Discussion

Fibrous dysplasia is a nonfamilial benign anomaly of bone development occurring in single or multiple bones and characterized by the replacement of normal bone by fibro-osseous tissue.<sup>[1]</sup> It represents 2.5% of all osseous neoplasms and is found more frequently in women (2:1).<sup>[2]</sup> It is of two types. Most (70%–80%) of the cases are monostotic, involving only single bone, and 20%–30% are polyostotic, involving more than single bone. Skull and facial bones were involved in 10%–25% in monostotic form and about 50% in polyostotic form.

Approximately one-third of patients with fibrous dysplasia have involvement of cranial and face bones. These patients



**Figure 2:** Intraoperative image showing thickened occipital bone

commonly present with headaches, facial pain, cranial nerve palsy, and facial deformities due to bone compression.<sup>[1,2]</sup>

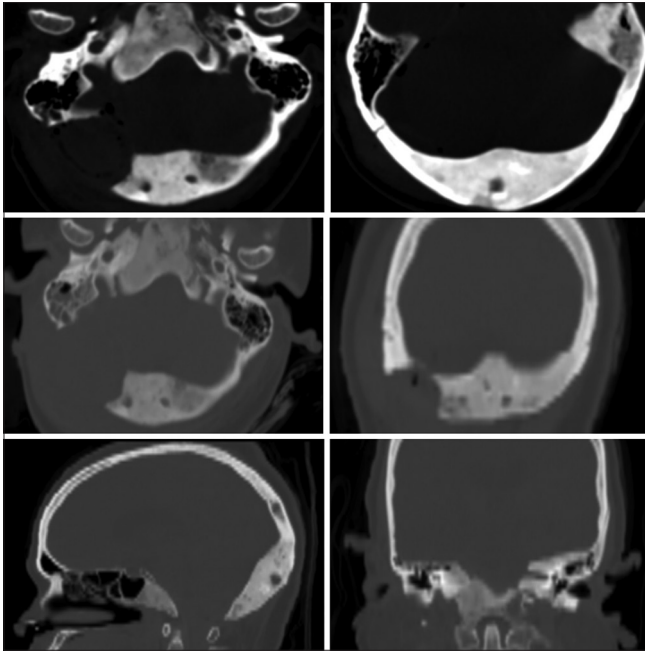
On the other hand, (VS) is a benign primary intracranial tumor of vestibulocochlear nerve (8<sup>th</sup> cranial nerve). This tumor arises from the Schwann cells responsible for the myelin sheath that helps keep insulation of peripheral nerves.

VS can present in association with other tumors, but presenting association is considered anecdotal. Most commonly, this tumor may be associated with other tumors in neurofibromatosis type 2.<sup>[3]</sup> Patients with neurofibromatosis, however, may develop gliomas and multiple cranial nerve schwannomas in association with meningiomas.<sup>[4,5]</sup>

There is no exact etiopathological factor known for the coexistence of these two lesions. However, there may be some common but yet undetected influencing factors between the two tumors.<sup>[1,2]</sup> The coexisting of these lesions in central nervous system should be reported to help us understand the etiology of these lesions. Similarly, no previous association with fibrous dysplasia of the overlying bone has been reported so far.

The problem we faced during surgery was tedious bone work due to extremely thickened overlying bone, which was necessary for the exposure of the tumor. Secondly, due to thickened bone, larger exposure was needed and more angulation of microscope was required to reach the lesion along with increased retraction of ipsilateral cerebellar lobe.

In view of increased thickness of dysplastic bone, we should anticipate a difficult craniotomy. In that regard, a larger craniotomy ought to be done, especially avoiding the dysplastic bone at its thickest, making the drilling procedure less cumbersome. In view of increased vascularity of the dysplastic bone, adequate blood products should be arranged before initiation of craniotomy. Anticipating the thickened bony margins which might obstruct the



**Figure 3: Computed tomography head bone windows delineating the involved dysplastic bones**

microscopic view of underlying tumor, a greater degree of lateral rotation of neck might be required while positioning the patient (park bench position), which, in turn, might facilitate the exposure of VS.

In summary, we report, in this study, a 48-year-old female patient with extremely rare case of coexisting fibrous dysplasia and VS. The occurrence of VS and fibrous dysplasia has not previously been reported in the literature.

### Declaration of patient consent

The authors certify that they have obtained all appropriate patient consent forms. In the form the patient(s) has/have given his/her/their consent for his/her/their images and other clinical information to be reported in the journal. The patients understand that their names and initials will not be published and due efforts will be made to conceal their identity, but anonymity cannot be guaranteed.

### Financial support and sponsorship

Nil.

### Conflicts of interest

There are no conflicts of interest.

### References

1. Frankel J, Ianotti F, Powell M, Schon F. Meningioma – An unrecognised complication of fibrous dysplasia of the skull? *J Neurol Neurosurg Psychiatry* 1989;52:546-7.
2. Ghosal N, Furtado SV, Santosh V, Sridhar M, Hegde AS. Co-existing fibrous dysplasia and atypical lymphoplasmacyte-rich meningioma. *Neuropathology* 2007;27:269-72.
3. Halefoğlu AM. Multiple cranial nerve schwannomas and meningiomas as a hallmark sign of neurofibromatosis type 2 in a child. *Turk J Pediatr* 2018;60:107-10.
4. Al-Mefty O, Heth J. Meningiomas. In: Rengachary SS, Ellenbogen RG, (eds). *Principles of Neurosurgery*. 2<sup>nd</sup> ed. England: Elsevier; 2005. p. 486-500.
5. Martuza RL. Neurofibromatosis as a model for tumor formation in the human nervous system. In: Salzman, editor. *Neurobiology of Brain Tumors: Concepts in Neurosurgery*. Vol. 4. Baltimore: Williams & Wilkins; 1991. p. 53-62.