

CASE REPORT

Open Access



A rare case of residual root myiasis caused by *Clogmia albipunctata* larvae (Diptera: Psychodidae)

Juan Chen^{1,2†}, Jinrui Liu^{3†}, Yun Liu⁴ and Yingjie Liu^{1*}

Abstract

Background: Dental injury caused by caries and trauma is the main cause of residual roots. Food trapped in the residual roots is difficult to clean. If the residual roots are not treated and cared for in time, flies can take advantage as soon as hygiene slips. Here, we present a rare case of human residual root myiasis caused by *Clogmia albipunctata* larvae, never previously reported.

Case presentation: A 26-year-old lady found two active, living larvae in her mouth while brushing her teeth. She did not present with fever, pain and any uncomfortable oral feeling. The intraoral examination revealed the right second mandibular molar was severely damaged as a result of caries, leaving a residual tooth root. The mucosa above it was mildly erythematous and edematous. No larvae and no inflamed gums were observed in her mouth. When normal saline was used to flush the area of the residual root with a syringe, four larvae appeared from the residual root. The larvae were observed by naked eye and under a light microscope. They were identified as the mature stage larvae of *Clogmia albipunctata*. Because the patient was in lactation, medication was not recommended. Treatment included the removal of all visible larvae followed by flushing the residual root with normal saline three times a day. The patient was followed-up weekly for one month. No more larvae were found and the erythematous and edematous mucosa healed completely.

Conclusions: The existence of a residual root can result in residual root myiasis. Myiasis caused by *Clogmia albipunctata* larvae or other fly larvae should be considered in cases of residual root infection.

Keywords: Myiasis, Residual root, *Clogmia albipunctata*, Larvae, Case report

Background

Human myiasis is defined as the infestation of the tissue of living human with dipterous larvae. It occurs worldwide [1, 2]. In humans, the sites most commonly affected are skin, nose, ears, eyes, anus, vagina, and oral cavity [2, 3]. Oral myiasis of humans is a pathology associated with a medical condition, poor oral hygiene, mouth breathing,

and incompetent lip [4]. Here, we report a rare case of human oral myiasis caused by *Clogmia albipunctata* larvae, never previously reported.

Case presentation

A 26-year-old woman was referred from Kaifeng New District Maternal and Child Health Care Hospital to the Department of Pathogenic Biology, Medical College of Henan University with the chief complaint being that she had found two living, active fly larvae in her mouth while brushing her teeth in the morning.

The woman was a civil servant living in the suburb of Kaifeng, Henan Province, China. She did not report fever,

*Correspondence: L-yingjie@henu.edu.cn

[†]Juan Chen and Jinrui Liu are co-first authors.

¹ Department of Pathogenic Biology, School of Basic Medical Sciences, Henan University, Kaifeng, China

Full list of author information is available at the end of the article



pain or any uncomfortable oral feeling. However, she appeared anxious and frightened. The initial intraoral examination revealed no larvae and no inflamed gums were observed in her mouth. Two years ago, her right second mandibular molar was severely damaged as a result of caries, leaving a residual tooth root. The patient never treated and cared of the residual tooth root except for brushing her teeth once a day. The mucosa above the residual root was mildly erythematous and edematous and no bleeding was present (Fig. 1).

When normal saline was used to flush the area of the residual root with a syringe, a total of four larvae mixed with a little of trapped, decomposed food were flushed out of the residual root. The larvae were removed quickly and gently using forceps. They wriggled around actively in water and crawled quickly on a solid surface.

Because the patient was in lactation, medication was not recommended. Treatment included the removal of

all visible larvae followed by flushing the residual root with normal saline. She was advised to flush the residual root with normal saline three times a day before brushing her teeth. We advised her to refer to dentist to treat the residual root as soon as possible. We also advised her to clean the room to eliminate the breeding environment of the flies and spray with insecticides to exterminate the flies. The patient was followed-up weekly for one month. No more larvae were found and the erythematous and edematous mucosa healed completely.

The larvae were observed by naked eye and under a light microscope (Motic BA210, MOTIC CHINA GROUP CO., LTD.). The larvae were cylindrical and about 7–8 mm long and 1 mm wide. They were grayish dorsally and white ventrally, while the ovoid shaped head and the cone-shape tail were dark brown (Fig. 2A). The dorsal surface of the body segments were covered with 26 saddle-shaped dark chitinous plates. The mouthparts were of the chewing type. The body was densely covered with long black backward projecting setae dorsally and laterally (Fig. 2B, red arrow). Two internal breathing tubes appear extending along the length of the body starting at a pair of anterior spiracles on the prothorax and ending with a pair of posterior spiracles, at the tip of the terminal segment. Caudally, the siphon was cone-shape. There were two dorsal anal processes and two ventral anal processes with a tuft of hairs at the end (Fig. 2C, black arrow).

From previous morphological characters and comparing them to literatures [5–8], the larvae were identified as the mature stage larvae of *Clogmia albipunctata* (Diptera: Psychodidae).

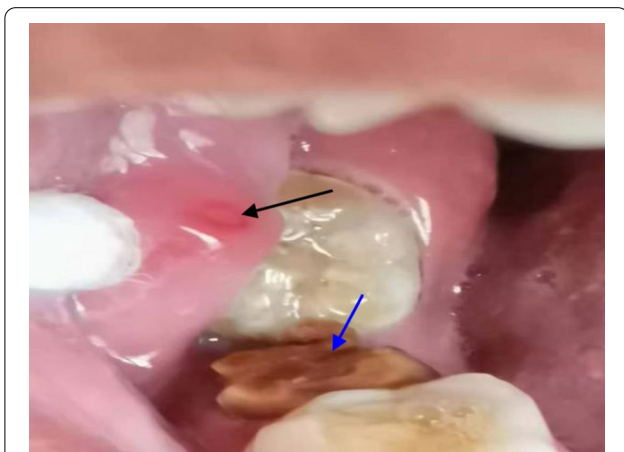

Fig. 1 The residual root (blue arrow) and the mildly erythematous edematous mucosa (black arrow)




Fig. 2 *Clogmia albipunctata* larva. **A** Full-larva. **B** The ovoid head (black arrow) and the thoracic segments and a part of abdominal segments with long dark backwardly directed filiform setae (red arrow, 40 \times). **C** Caudal part showing dorsal anal plates (green arrow), 2 internal breathing tubes extending along the length of the body (red arrow) and end anal processes with a tuft of hairs at the end (black arrow, 40 \times)

Discussion and conclusions

Oral myiasis of humans is associated with poor oral hygiene, alcoholism, senility, mental debility, mouth breathing [9], incompetent lip, cerebral palsy [10], severe halitosis, suppurating lesions, gingival disease and trauma [11]. Poor oral hygiene is among the more important risk factors in oral myiasis. After careful taking of history from the patient, we learned she had the habit of sleeping with her mouth open. Because she was in lactation, there were many fruits and snacks in the bedroom which attracted some small flies. It was concluded that the patient did not look after her oral hygiene. Food trapped in the residual root is difficult to clean. While the patient slept with her mouth open, the smell of the trapped, decomposed food in the residual root attracted one or more flies to lay eggs in the residual root.

The main species reported to cause oral myiasis are *Cochliomyia hominivorax*, *Chrysomya bezziana*, *Musca domestica*, *Sarcophaga* species, *Luciliasericata*, *Lucilia cuprina*, *Musca nebulosa*, *Oestrus ovis*, *Calliphoridae*, *Dermatobia hominis*, *Hypoderma bovis*, *Hypoderma tarandi* and *Wohlfahrtia magnifica* [2]. Larvae of *Clogmia albipunctata* had been reported to cause human nasopharyngeal myiasis [12], intestinal myiasis [6, 8] and urinary myiasis [5, 7]. However, the case of human residual root myiasis caused by *Clogmia albipunctata* larvae had never been reported.

Clogmia albipunctata is a primitive Nematoceran of the family Psychodidae, subfamily Psychodinae and cosmopolitan in distribution. The adult flies can survive and spread outdoors during the temperate seasons. *Clogmia albipunctata* can elicit inhalant allergy as a result of inhaling fragments of their disintegrated body parts and can play a significant role as a potential mechanical vector of pathogens [13]. Their larvae are coprophagous and saprophagous. They feed on decaying organic matter and vertebrate feces. They are present in moist places such as bathrooms and toilets [14]. Because they are non-biting, tiny and quiet, most people do not notice them. The treatments of myiasis include manual removal of larvae and debridement, application of antibiotic therapy, asphyxiating substances and ivermectin. Because the patient was in lactation, we used just the treatment of manual removal of larvae and flushing the area of the residual root with normal saline.

In summary, good oral hygiene is important in all circumstances and residual roots should be treated and cared for in time until it is fully healed, as flies can take advantage as soon as hygiene slips. The existence of a residual root can result in residual root myiasis. Myiasis caused by *Clogmia albipunctata* larvae or other fly larvae should be considered in cases of residual root infection.

Acknowledgements

The authors thank the patient for the consent to participate in this study.

Author contributions

YL participated in the identification of the larval species and drafted the manuscript. JC participated in the case collection and the identification of the larval species. JL participated in the microscopic examination, the identification of the larval species and revised the manuscript. YL participated in the microscopic examination and the identification of the larval species. All authors read and approved the final manuscript.

Funding

The authors have not declared a specific grant for this research from any funding agency in the public, commercial or not-for-profit sectors.

Availability of data and materials

All data discussed in the manuscript are included within this published article.

Declarations

Ethical approval and consent to participate

This study was approved by the Human Research Ethics Committee of the Henan University in China and the committee's reference number is [HUSOM2021-003]. The patient received an explanation about the scope of the study, such as objectives, procedures, and potential risks, and signed an informed consent for the use of the patient's clinical samples.

Consent for publication

Written informed consent was obtained from the patient for publication of this case study. A copy of the written consent is available for review by the editor of this journal.

Competing interests

The authors declare that they have no competing interests.

Author details

¹Department of Pathogenic Biology, School of Basic Medical Sciences, Henan University, Kaifeng, China. ²Department of Gynecology and Obstetrics, Kaifeng New District Maternal and Child Health Care Hospital, Kaifeng, China. ³Grade 2021, The Special Class for the Gifted Young, Xi'an Jiaotong University, Xi'an, China. ⁴Department of Inorganic Chemistry, College of Chemistry and Chemical Engineering, Henan University, Kaifeng, China.

Received: 28 September 2021 Accepted: 29 March 2022

Published online: 13 April 2022

References

- Droma EB, Wilamowski A, Schnur H, Yarom N, Scheuer E, Schwartz E. Oral myiasis: a case report and literature review. *Oral Surg Oral Med Oral Pathol Oral Radiol Endod.* 2007;103:92–6.
- Francesconi F, Lupi O. Myiasis. *Clin Microbiol Rev.* 2012;25:79–105.
- Gunbay S, Bicacki N, Canda T, Canda S. A case of myiasis gingiva. *J Periodontol.* 1995;66:892–5.
- Vasanthakumar V, Varalakshmi PR, Vanmathi R. Oral myiasis of maxilla (Palatal Gingiva). *Contemp Clin Dent.* 2020;11:162–4.
- Farrag HMM, Huseein EAM, Almatary AM, Othman RA. Morphological and initial molecular characterization of *Clogmia albipunctatus* larvae (Diptera: Psychodidae) causing urinary myiasis in Egypt. *PLoS Negl Trop Dis.* 2019;13:e0007887.
- Mokhtar AS, Braima KAO, Chin HP, Jeffery J, Zain SNM, Rohela M, Lau YL, Jamaiah I, Wilson JJ, Abdul-Aziz NM. Intestinal myiasis in a Malaysian patient caused by larvae of *Clogmia albipunctatus* (Diptera: Psychodidae). *J Med Entomol.* 2016;53:957–60.
- Hajia D, Sawalha SS, Amr ZS, Katbeh-Bader A, Hassoon RAH. Urinary myiasis caused by *Clogmia albipunctata* from the Palestinian Territories. *Bulletin de la Société de pathologie exotique.* 2018;111:148–51.

8. El-Dib NA, Ali MI, Hamdy DA, Wahab WMAE. Human intestinal myiasis caused by *Clogmia Albipunctata* larvae (Diptera: Psychodidae): First report in Egypt. *J Infect Public Health*. 2020;13:661–3.
9. Zachariah JE, Sehgal K, Dixit UB, Bhatia R. Oral myiasis: a case report. *Special Care Dent*. 2014;34:51–3.
10. Vasanthakumar V, Varalakshmi P, Vanmathi R. Oral myiasis of maxilla (palatal gingiva). *Contemp Clin Dent*. 2020;11:162–4.
11. Ramakrishna S, Vrinda K, Pranav I, Jignesh R, Jui K, Sunil K, Kunal P. Management of oral myiasis caused by *Chrysomya bezziana*-A case series. *Ann Maxillofac Surg*. 2020;10:521–4.
12. Mohammed N, Smith KGV. Nasopharyngeal myiasis in man caused by larvae of *Clogmia* (= *Telmetoscopus*) *albipunctatus* Williston (Psychodidae, Dipt.). *Trans R Soc Trop Med Hygiene*. 1976;70:91.
13. Faulde M, Spiesberger M. Hospital infestations by the moth fly, *Clogmia albipunctata* (Diptera: Psychodinae), in Germany. *J Hosp Infect*. 2012;81:134–6.
14. Onder Z, İnci A, Yıldırım A, Ciloğlu A, Düzlü O. Molecular characterization of myiasis-causing moth flies (Diptera: Psychodidae). *Turkiye Parazitoloj Derg*. 2018;42:223–8.

Publisher's Note

Springer Nature remains neutral with regard to jurisdictional claims in published maps and institutional affiliations.

Ready to submit your research? Choose BMC and benefit from:

- fast, convenient online submission
- thorough peer review by experienced researchers in your field
- rapid publication on acceptance
- support for research data, including large and complex data types
- gold Open Access which fosters wider collaboration and increased citations
- maximum visibility for your research: over 100M website views per year

At BMC, research is always in progress.

Learn more biomedcentral.com/submissions

