

Collagen cross-linking in the treatment of pellucid marginal degeneration

Ziad Hassan, Gabor Nemeth¹, Laszlo Modis¹, Eszter Szalai¹, Andras Berta¹

Orbident Refractive Surgery and Medical Center, ¹Department of Ophthalmology, Medical and Health Science Center, University of Debrecen, Debrecen, Hungary

Correspondence to: Dr. Ziad Hassan, Orbident Refractive Surgery and Medical Center, Debrecen, Hungary, Nagyerdei Blvd. 98, H-4012 Debrecen, Hungary. E-mail: zhassan@dote.hu

Manuscript received: 04-08-2011; Revision accepted: 14.03.12

Pellucid marginal degeneration (PMD) is an uncommon cause of inferior peripheral corneal thinning disorder, characterized by irregular astigmatism. We analyzed a case of bilateral PMD patient and treated one eye with corneal collagen cross-linking (CXL) therapy. Corneal topography was characteristic for PMD. Visual acuity, slitlamp examinations, tonometry, and

Access this article online

Quick Response Code:



Website:

www.ijo.in

DOI:

10.4103/0301-4738.109523

corneal thickness were observed. Simulated keratometric and topographic index values were detected with corneal topography. Uncorrected, LogMAR visual acuity has improved from +0.8 to +0.55 during the 6 months and +0.3 during the 8 months follow-up after CXL. Pachymetry values and intraocular pressure showed no changes. Keratometric values and topographic indexes disclosed no progression of the disease. CXL may postpone or eliminate the need of corneal transplantation in cases with PMD.

Key words: Collagen cross-linking, pellucid marginal degeneration, Pentacam HR

Pellucid marginal degeneration (PMD) of the cornea is a progressive, rare, and uncommon noninflammatory corneal disorder characterized by the thinning in the peripheral portion of the inferior cornea with marked steepening just superior to the thinned zone.^[1,2] It occurs in both men and women and can be differentiated from other peripheral corneal thinning disorders such as keratoconus and keratoglobus by its characteristics that this thinning occurs 1–3 mm from the limbus in the 4–8 o'clock position.^[3] It is differentiated from peripheral corneal disorders associated with inflammation such as Terrien's marginal degeneration and Mooren's ulcer by the absence of vascularisation. Although histopathologically it is considered a variant of keratoconus, it differs in that the marked corneal steepening occurs more inferiorly.^[1]

Corneal cross-linking was introduced by Wollensak *et al.* in 2003 for the treatment of progressive keratoconus and related disorders increasing the biomechanical strength of the cornea by about 300%.^[4]

Here we present one case showing the features of PMD both clinically and topographically treated by collagen cross-linking (CXL). It was clinically typical bilateral PMD with a characteristic pattern of irregular astigmatism on corneal topography, with chief complaints of progressive dimness of vision caused by irregular astigmatism. The CXL treatment can stop PMD progression and produce better quality of vision.

Case Report

We analyzed a case of advanced bilateral PMD patient and treated one eye with corneal CXL. A 55-year-old male is presented, complaining of progressive dimness of vision in both eyes with decreased vision started 1 year before examinations at our clinic, but the visual loss was larger in the right eye. There was no history of excessive eye rubbing, trauma, contact lens wear, or episodic redness of the eye. There was no familiar history. Earlier, he was diagnosed with glaucoma simplex treated with timolol 0.5%. His right eye was pseudophakic, and his left eye had posterior subcapsular cataract. He had high blood pressure and type II diabetes mellitus was treated for around 9 years. The patient tried rigid gas-permeable contact lenses but could never get an acceptable fit. Visual acuity, slitlamp examination, corneal thickness map measurement (Pentacam HR, Oculus), and tonometry were carried out, and simulated keratometric (SK1, SK2) and topographic index values were detected with corneal topograph (Tomey TMS4).

Ophthalmic examination revealed his best-uncorrected visual acuity, a value of +0.8 in the right eye and +0.1 in the

left eye observed with a logarithmic scale (LogMAR). Slitlamp examination of the cornea showed inferior peripheral corneal thinning without iron lines, vascularization, or lipid deposition [Fig. 1]. The lesion was nonulcerative and inflammatory, and implied the protrusion of the cornea. Between the thinned area and the limbus, the corneal thickness was normal. However, the left eye showed a clear band of peripheral thinning about 1–2 mm wide, with anterior protrusion of the cornea just above the thinned area. A 2.0-mm zone of normal-thickness cornea was seen between the thinned area and the limbus. Scheimpflug image (Oculus Pentacam HR) of the anterior segment of the right eye shows irregular shaped central corneal region [Fig. 2a and b].

Both anterior chambers were 4.11 mm deep. Corneal thickness measured by ultrasonic pachymeter of the right eye were 502 μm centrally and 520 μm peripherally; in the left eye, the readings were 540 μm centrally, and 520 μm at the periphery. The intraocular pressure measured by noncontact tonometry was in normal range in both eyes.

Corneal topography was characteristic for PMD. The vertical axis images showed significant central irregular against-the-rule astigmatism, marked peripheral thinning within 2.0 mm of the limbus, and more normal corneal thickness inferior to the band of thinning. Topograph sagittal curvature map on the right eye showed vertical flattening and irregular inferior corneal astigmatism. The horizontal axis had more normal corneal contour and thickness. Keratometric readings were 53.98D/36.04D in the right eye. In both eyes, there was a bow-tie-shaped corneal astigmatism with a value of 17.96D in the right eye [Fig. 3]. This clinical picture was consistent with a diagnosis of PMD of both eyes.

CXL was performed on the right eye using InPro CCL-Lix device (Norderstadt, Germany). During treatment, 8 mm of the central corneal epithelium was removed and 0.1% riboflavin solution (with 20% dextrane) was instilled on the surface of the cornea with eccentric method of Spadea^[5] and was repeated every 2 minutes thereafter. In the meantime, UV-A irradiation was performed with an emission at 370 nm, with radiant energy of 3 mW/cm², focusing distance of 60 mm, and lasted for 30 minutes. The postoperative treatment was antibiotic eye drops for 5 days (tobramycin) and steroid eyedrops (fluorometholone) and artificial tear drops for at

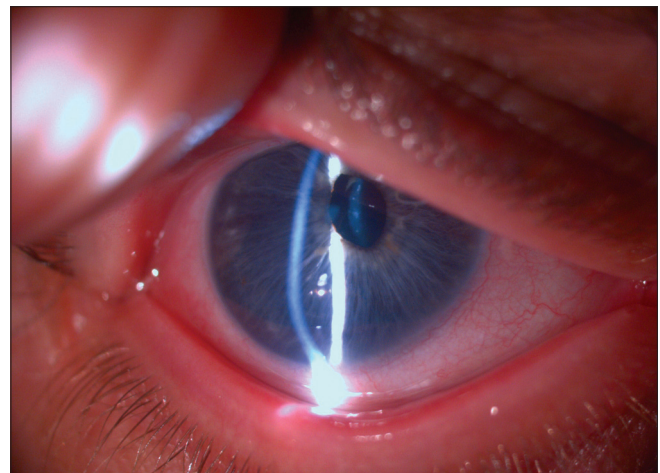


Figure 1: Slit-lamp photograph of the right eye shows inferior steepening with a clear zone between limbus and the steep band

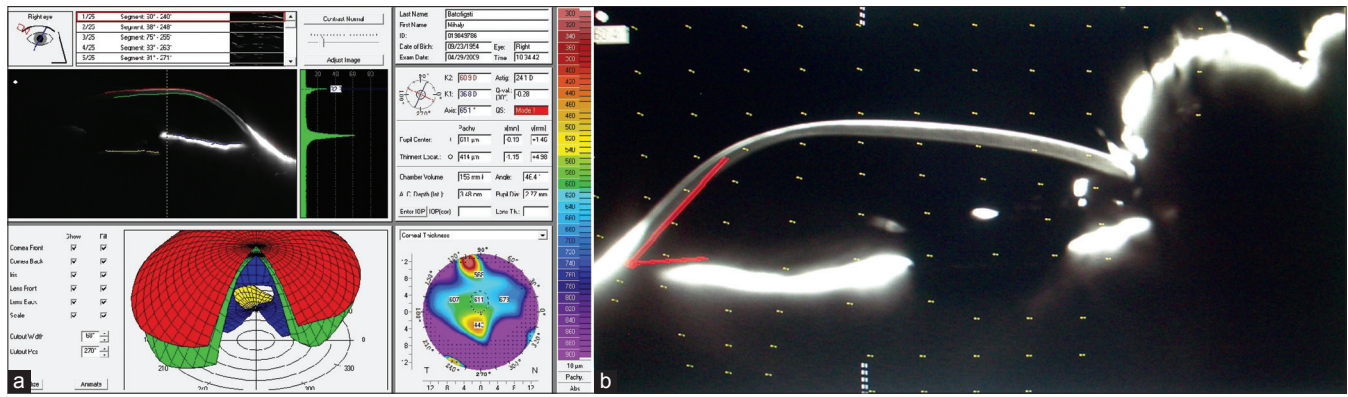


Figure 2: (a and b) Scheimpflug image (Oculus Pentacam HR) of the anterior segment shows irregular shaped central corneal region

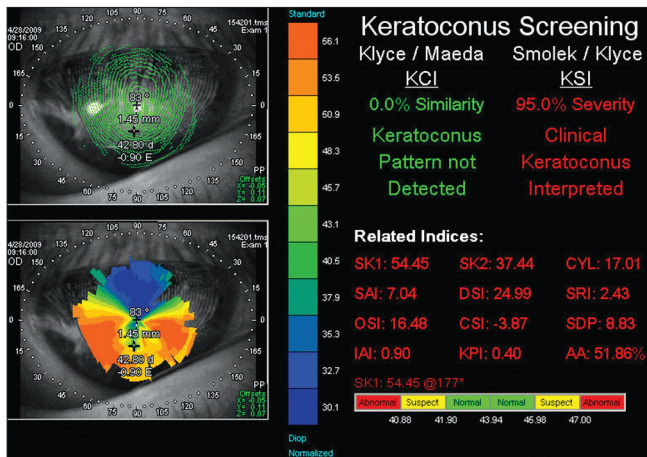


Figure 3: Preoperative corneal topographic picture of the right eye shows the characteristic bow-tie appearance of corneal steepening (red zones) and midperipheral inferior corneal flattening

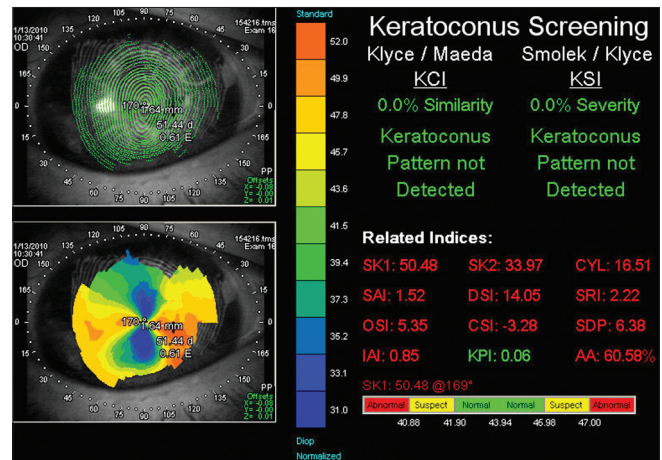


Figure 4: Corneal topograph shows flattening of the inferior cornea 8 months after CXL treatment

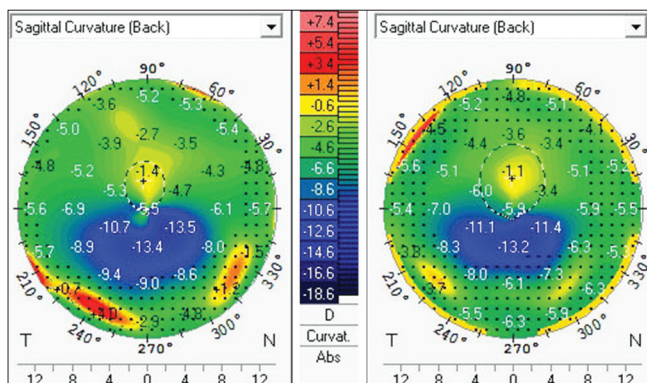


Figure 5: Pre- and postoperative corneal back surface Scheimpflug pictures (Pentacam HR) do not show difference

least 1 month. We did not use contact lens postoperatively. There was no corneal edema or endothelial damage postoperatively.

The follow-up period was 8 months. Visual acuity, simulated keratometric indexes, and corneal thickness values were detected during the postoperative period. Uncorrected visual acuity has increased from +0.8 to +0.55; best-corrected visual acuity was +0.25 with a correction of spherical equivalent of

-4.0 D 8 months after CXL treatment. After CXL treatment, SK1 decreased to 50.48 D and SK2 to 33.97 D [Fig. 4]. Pre- and postoperative corneal back surface Scheimpflug pictures (Pentacam HR) do not show difference [Fig. 5].

Pachymetry map showed minimal increase in peripheral corneal thickness (from 520 μ m preoperatively to 528 μ m postoperatively) 8 months after treatment. No change in intraocular pressure was measured, during the follow-up period. IOP varied between 14 and 19 mmHg. Our data are summarized in Tables 1 and 2.

Discussion

PMD has been postulated to the abnormality of the connective tissue, but the exact pathogenesis is still unknown. On corneal topography, marked steepening of the inferior corneal periphery can be seen, which also extends into mid-peripheral inferior corneal meridians. The mid-peripheral cornea is gradually decreased in keratometric power above the inferior oblique meridians.^[3,6] Our patient had all these features in both eyes, and there was no stromal thickness less than 400 μ m, but the left eye showed less deviation than the right eye. The usual treatments for PMD are intrastromal ring insertion, lamellar keratoplasty, crescentic lamellar keratoplasty, penetrating keratoplasty, cyanoacrylate adhesive, and a bandage contact lens. Conservative treatment is also possible.^[7]

Table 1: Patient data before and after collage cross-linking treatment

	Central corneal thickness (μm)	Peripheral corneal thickness (μm)	UCVA	BCVA	Intraocular pressure (mmHg)
Preoperative	505	520	+0.8	+0.7	14
Postoperative 1 month	589	530	+0.6	+0.4	19
Postoperative 3 months	506	527	+0.55	+0.3	14
Postoperative 6 months	501	518	+0.55	+0.3	16
Postoperative 8 months	499	528	+0.3	+0.25	14

UCVA: Uncorrected LogMAR visual acuity, BCVA: Best-corrected visual acuity

Table 2: Patient data before and after surgery

	K1	K2	SAI	SRI
Preoperative	53.98 D	36.02 D	5.37	2.40
Postoperative 1 month	54.45 D	37.44 D	7.01	2.43
Postoperative 3 months	45.34 D	41.93 D	2.91	2.13
Postoperative 6 months	43.44 D	38.57 D	2.21	2.01
Postoperative 8 months	50.48 D	33.97 D	1.52	2.22

K1, K2: Keratometric data, SAI: Surface asymmetry index, SRI: surface regularity index

Corneal transplantation for keratectasia is a difficult procedure with a long and uncertain visual recovery. Ertan *et al.*^[8] inserted intacs ring using a femtosecond laser to correct pellucid marginal corneal degeneration with safe and efficient results. In the report of Stojanovic *et al.*, 12 eyes were treated with topography-guided custom ablation and CXL, which after uncorrected visual acuity increased and astigmatism and keratometric asymmetry decreased.^[9] Spadea described eccentric irradiation CXL technique followed by us in case of PMD.^[5] Kymionis *et al.*^[10] treated a woman with simultaneous photorefractive keratectomy and corneal CXL with riboflavin-ultraviolet-A irradiation for the treatment of progressive pellucid marginal corneal degeneration in both eyes with good results. Histologically and clinically, CXL is a well-circumscribed and well-published therapeutic possibility of corneal ectasias.^[11,12] There are some possible complications after CXL: early pseudo-haze, bacterial infection,^[13] scarring, melting, or perforation. The safety parameter of a minimal stromal thickness of 400 μm to spare the endothelium.^[14]

In this case, progression had been stopped by CXL treatment, and the best-corrected visual acuity increased during the observation period. No intraoperative or early postoperative complications occurred. The CXL irradiation was safe and efficient in the treatment of certain stages of PMDs with the help of which progression can be reversed or at least stopped, and visual acuity can be improved. This method may postpone or eliminate the need of corneal transplantation in cases with PMD.

References

1. Krachmer JH. Pellucid marginal degeneration. *Arch Ophthalmol* 1978;96:1217-21.

2. Walker RN, Khachikian SS, Belin MW. Scheimpflug photographic diagnosis of pellucid marginal degeneration. *Cornea* 2008;27:963-6.
3. Krachmer JH, Feder RS, Belin MW. Keratoconus and related noninflammatory corneal thinning disorders. *Surv Ophthalmol* 1984;28:293-322.
4. Wollensak G, Spoerl E, Seiler T. Riboflavin/ultraviolet-A-induced collagen cross linking for the treatment of keratoconus. *J Cataract Refract Surg* 2003;135:620-7.
5. Spadea L. Corneal collagen cross-linking with riboflavin and UVA irradiation in pellucid marginal degeneration. *J Refract Surg* 2010;26:375-7.
6. Klyce SD. Computer-assisted corneal topography: high resolution graphic presentation and analysis of keratometry. *Invest Ophthalmol Vis Sci* 1984;25:1426-35.
7. Forooghian F, Assaad D, Dixon WS. Successful conservative treatment of hydrops with perforation in pellucid marginal degeneration. *Can J Ophthalmol* 2006;41:74-7.
8. Ertan A, Bahadit M. Intrastromal ring segment insertion using a femtosecond laser to correct pellucid marginal corneal degeneration. *J Cataract Refract Surg* 2006;32:1710-6.
9. Stojanovic A, Zhang J, Chen X, Nitter TA, Chen S, Wang Q. Topography-guided transepithelial surface ablation followed by corneal collagen cross-linking performed in a single combined procedure for the treatment of keratoconus and pellucid marginal degeneration. *J Refract Surg* 2010;26:145-52.
10. Kymionis GD, Karavitaki AE, Kounis GA, Portaliou DM, Yoo SH, Pallikaris IG. Management of pellucid marginal corneal degeneration with simultaneous customized photorefractive keratectomy and collagen crosslinking. *J Cataract Refract Surg* 2009;35:1298-301.
11. Wollensak G. Crosslinking treatment of progressive keratoconus: New hope. *Curr Opin Ophthalmol* 2006;17:356-60.
12. Wollensak G. Corneal collagen cross-linking: New horizons. *Expert Rev Ophthalmol* 2010;5:201-15.
13. Sharma N, Maharana P, Singh G, Titiyal JS. Pseudomonas keratitis after collagen crosslinking for keratoconus: Case report and review of literature. *J Cataract Refract Surg* 2010;36:517-20.
14. Wollensak G, Spoerl E, Wilsch M, Seiler T. Endothelial cell damage after riboflavin-ultraviolet-A treatment in the rabbit. *J Cataract Refract Surg* 2003;29:1786-90.

Cite this article as: Hassan Z, Nemeth G, Modis L, Szalai E, Berta A. Collagen cross-linking in the treatment of pellucid marginal degeneration. *Indian J Ophthalmol* 2014;62:367-70.

Source of Support: Nil. **Conflict of Interest:** None declared.