

Management Strategies for Rotator Cuff Defects After Calcific Tendinitis Debridement



W. Kyle Wilson, M.D., and Larry D. Field, M.D.

Abstract: Management of rotator cuff defects that are created in the process of excising calcific deposits for patients undergoing surgical intervention for symptomatic calcific tendinitis is not well defined. Such defects can vary considerably in depth, size, and location, and surgical treatment of these rotator cuff lesions depends on a number of factors. Accurately identifying the location and extent of these calcific deposits is important in ensuring their complete removal, and techniques designed to consistently localize these calcific deposits are also described.

Rotator cuff calcific tendinitis occurs as a result of abnormal accumulation of hydroxyapatite within the tendon. The initiating mechanism is not definitely known. These deposits are most often located within the supraspinatus tendon, occurring in this location in 80% of patients presenting with calcific deposits.¹ This commonly results in significant, and sometimes severe, shoulder pain often combined with restricted active range of motion.

A number of nonoperative treatment modalities are commonly used initially, such as nonsteroidal anti-inflammatory drugs, corticosteroid injections, and organized physical therapy. However, when symptoms prove to be recalcitrant to nonoperative management, operative intervention is warranted. Excision of these calcific deposits from rotator cuff tissue often results in some degree of removal and loss of rotator cuff tendon. Controversy exists regarding optimum management of and strategies for repair of these variably sized rotator cuff defects.²⁻⁶

The size and location of the defects created after debridement of calcific deposits are the primary factors in determining surgical management for these lesions. Barber and Cowden⁷ recommended treating the defect in the same manner as a defect not associated with calcific deposits. They suggested repairing the rotator cuff only if the remaining defect was larger than 5 mm in depth.

The degree of postoperative healing that these rotator cuff defects, created as a result of calcific deposit removal, undergo is not well elucidated. It is not clear, for example, whether a partial-thickness defect reconstitutes itself to full thickness postoperatively. Verhaegen et al.,² in a Level II randomized controlled trial, showed persistent rotator cuff defects at 1 year on both ultrasound and magnetic resonance imaging examinations after arthroscopic needling of rotator cuff calcific deposits.

The surgical techniques described are the preferred interventions and strategies of the senior author (L.D.F.) for rotator cuff defects created as a consequence of calcific deposit excision. The major advantages and disadvantages of these techniques are summarized in [Table 1](#).

Surgical Technique

The calcific deposits are identified and localized using a number of arthroscopic techniques and likewise excised using arthroscopic instruments ([Video 1](#)). This procedure can be effectively performed with the patient in either the lateral decubitus or beach-chair position. Standard anterior, lateral, and posterior portals are used with accessory portals created as necessary to access these calcific deposits. The size and location of an individual deposit are initially defined based on

From Mississippi Sports Medicine and Orthopaedic Center (W.K.W.) and Upper Extremity Service and Sports Medicine and Arthroscopy Fellowship, Mississippi Sports Medicine and Orthopaedic Center (L.D.F.), Jackson, Mississippi, U.S.A.

The authors report that they have no conflicts of interest in the authorship and publication of this article. Full ICMJE author disclosure forms are available for this article online, as [supplementary material](#).

Received December 13, 2018; accepted May 12, 2019.

Address correspondence to Larry D. Field, M.D., Mississippi Sports Medicine and Orthopaedic Center, 1325 E Fortification St, Jackson, MS, 39202 U.S.A. E-mail: lfield@msmoc.com

© 2019 by the Arthroscopy Association of North America. Published by Elsevier. This is an open access article under the CC BY-NC-ND license (<http://creativecommons.org/licenses/by-nc-nd/4.0/>).

2212-6287/194

<https://doi.org/10.1016/j.eats.2019.05.018>

Table 1. Advantages and Disadvantages**Advantages**

The technique allows for complete excision of calcific deposits.
 Needle localization helps to identify deposits at the adjacent rotator cuff.
 Side-to-side repair, when indicated, allows for excellent conversion of rotator cuff tears.

Disadvantages

Complete calcium deposit resection sometimes results in significant rotator cuff defects.
 Anchor use may be comprised based on tuberosity erosions that are sometimes seen adjacent to calcific deposits.

preoperative radiographic imaging (Fig 1) and use of arthroscopic visualization, probing, and/or spinal needle localization.⁸ Removal of the calcific deposits can be easily accomplished using an arthroscopic shaver (Dyonics Powermax; Smith & Nephew, London, England) if the deposits are on or near the surface of the rotator cuff tendon (Fig 2). If the deposits are deeper within the rotator cuff tendinous tissue and not visible arthroscopically, identification of these deeper calcific deposits can be more difficult to localize. A surgical tip that we use for such situations when the calcific deposits are not visible is to use a standard 18-gauge spinal needle (Fig 3). This spinal needle can be used to repeatedly pierce the rotator cuff tendinous tendon

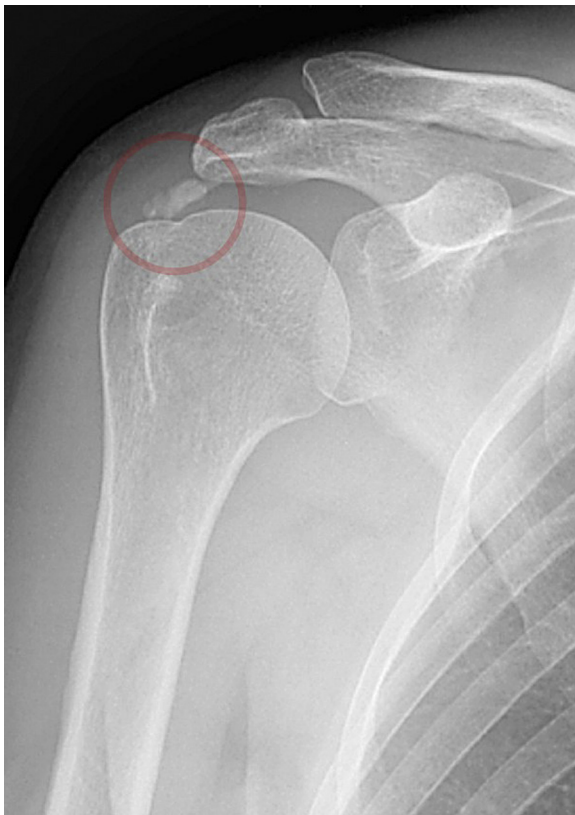

Fig 1. Anteroposterior radiograph, of patient's right shoulder, with calcific deposit (circle) marked within the supraspinatus tendon near its insertion on the greater tuberosity.

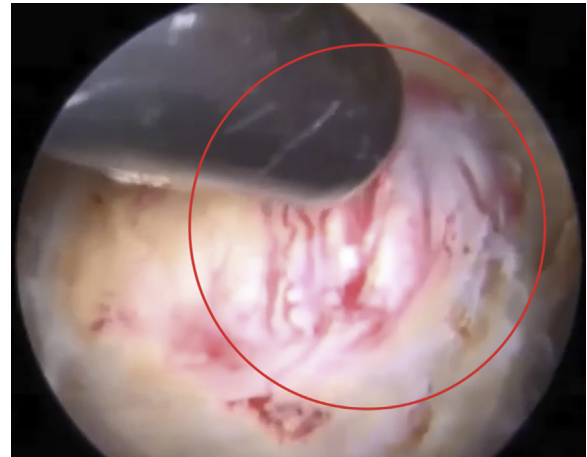

Fig 2. A calcific deposit (circle) on the bursal aspect of the supraspinatus in a right shoulder, as viewed from the lateral portal, is debrided using an arthroscopic shaver, resulting in a relatively small partial-thickness tendon defect. Of note is the extent of inflammatory tissue reaction present adjacent to the calcific deposit. The patient is in the beach-chair position.

in proximity to the location at which the calcific deposits have been identified on preoperative or intraoperative (fluoroscopic) imaging while very carefully watching arthroscopically for evidence of calcific deposits being "flushed" from within the rotator cuff tissue. Once a deposit is identified by aid of the spinal needle technique, it can be removed using the arthroscopic instruments. In addition, on occasion, we use a No. 11 or No. 15 scalpel blade on a standard knife handle to create a partial-thickness longitudinal incision on the bursal surface of the rotator cuff in close proximity to the anticipated location of calcific deposits that

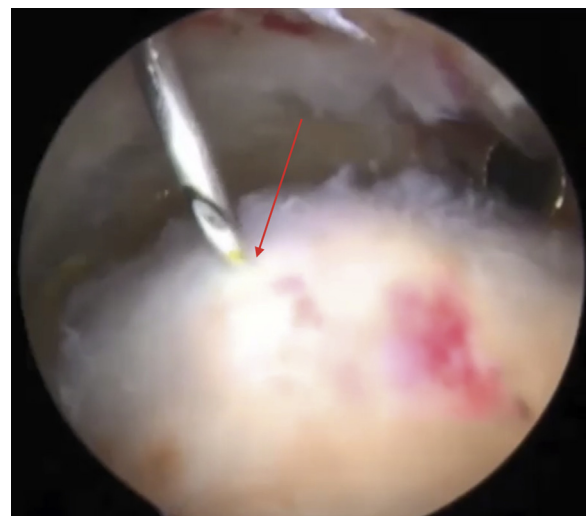

Fig 3. The use of a spinal needle via the lateral portal is shown probing tendinous tissue (arrow) in an effort to elicit calcific deposit "snow" that helps to localize the deposit within the rotator cuff tissue in a left shoulder. The patient is in the beach-chair position.

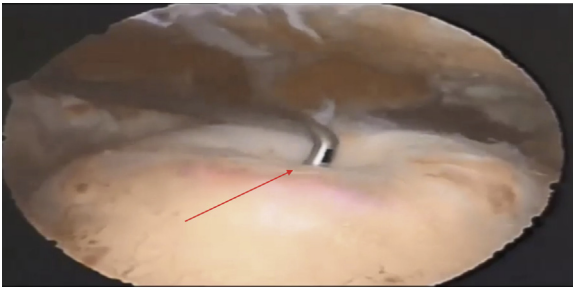


Fig 4. A blunt arthroscopic probe, introduced through the anterior portal, is used to apply external compression to a fluid-filled calcific deposit (arrow) in the rotator cuff tissue in a left shoulder, viewed from the lateral portal, causing increased extravasation. The patient is in the beach-chair position.

are not visible arthroscopically. Incising the rotator cuff exposes the deeper portion of the tendon and exposes the location of the deposits. Finally, a standard arthroscopic probe sometimes can be used to identify the hidden calcific deposits (Fig 4). The consistency of the calcific deposits can vary significantly and may be composed of a chalky substance, a milky-type fluid, or a combination thereof. We usually attempt to remove the calcific deposits completely and then confirm removal using intraoperative fluoroscopy. Care should be taken by the surgeon to minimize excision of adjacent rotator cuff tissue during calcific deposit debridement, but such removal of rotator cuff tissue is often unavoidable. Calcific deposits are most often visualized on the bursal side of the rotator cuff tendon. Occasionally, however,

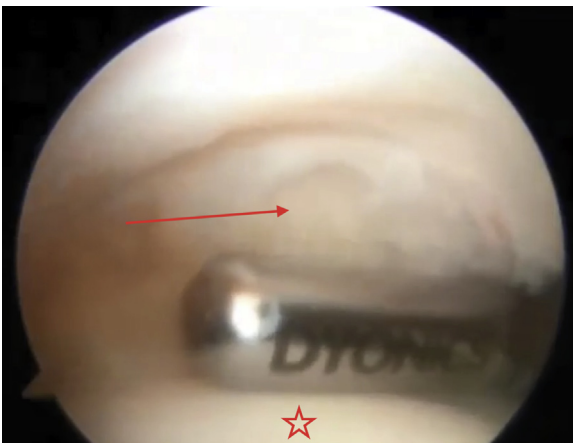


Fig 5. A very large, transtendinous calcific deposit (arrow) in a left shoulder, viewed from the posterior portal, is seen and approached from the articular aspect of the tendon. The articular aspect of the humeral head is marked by a star. The assistant or limb holder should hold the arm in slight abduction and external rotation to provide the best visualization of the articular aspect of the supraspinatus, as seen in this image. The shaver is introduced through the anterior portal in this case. The patient is in the beach-chair position.

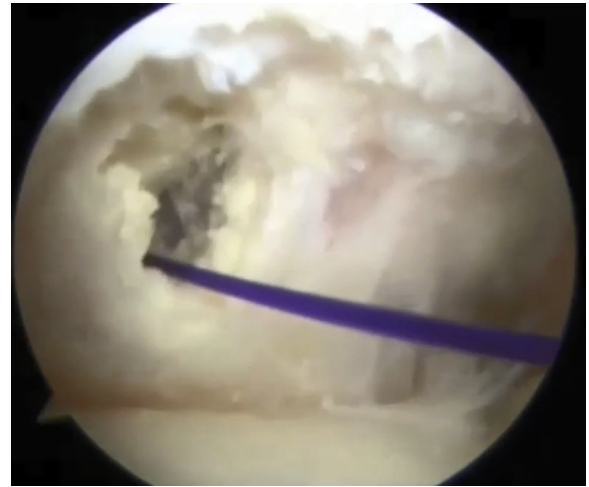


Fig 6. A spinal needle-guided marking suture, introduced through the lateral portal and viewed from the posterior portal, is used to aid in identifying the adjacent bursal-sided rotator cuff tissue and calcific deposit within the subacromial space in a left shoulder. The patient is in the beach-chair position.

calcific deposits may be seen arthroscopically on the articular surface of the rotator cuff. For such situations, debridement of the deposits can be initiated on the articular surface of the tendon (Fig 5). In addition, localization of calcific deposits on the bursal surface of the rotator cuff, which are only visible on the articular surface, can be aided by using a spinal needle to advance a marking suture through the deposit while visualizing the deposit intra-articularly. Finding the marking suture in the subacromial space then serves to localize the adjacent bursal-sided rotator cuff tendon in close proximity to the articular-sided deposit (Fig 6). If, after calcific deposit debridement, the residual rotator cuff defect remains partial thickness and relatively

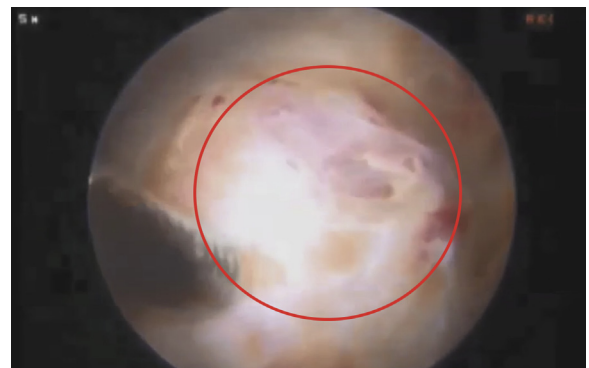

Fig 7. A partial-thickness defect in the rotator cuff (circle) in a right shoulder is visualized via the lateral portal after calcific deposit debridement using an arthroscopic soft-tissue shaver via the posterior portal. The patient is in the beach-chair position.

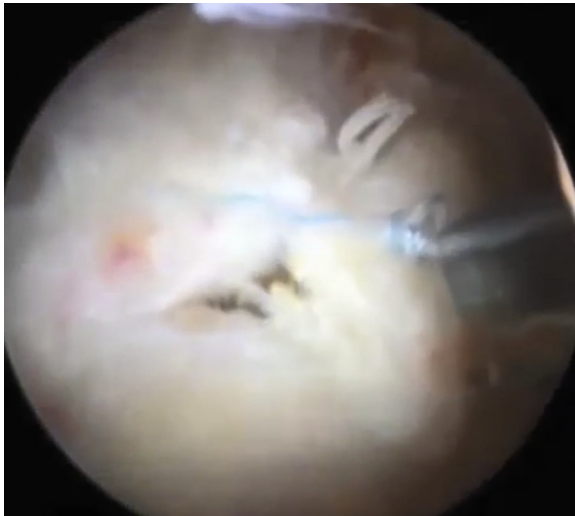

Fig 8. In a left shoulder, excision of a large calcific deposit results in a full-thickness rotator cuff defect, visualized via the lateral portal, that is repaired using side-to-side convergence sutures. The patient is in the beach-chair position.

superficial (<3-5 mm in depth), the defect is generally left unrepaired by us (Fig 7, first case in Video 1).

For those residual defects that are deeper (>5 mm), nearly complete, or even full thickness after calcific deposit debridement, rotator cuff repair is accomplished. Side-to-side convergence suture repair is usually carried out for partial-thickness defects (Fig 8). For some full-thickness defects, side-to-side convergence repair is used, particularly if the bone quality is poor and precludes suture anchor placement or if a large bony void is present after deposit debridement (Figs 9 and 10). For most full-thickness defects that are not reapproximated easily with convergence stitches (Fig 11), however, suture anchors are used to reapproximate the rotator cuff tendon to the tuberosity (Fig 12). Likewise, suture anchors are used when rotator cuff debridement results in full-thickness detachment of the rotator cuff tendon from the greater tuberosity laterally.

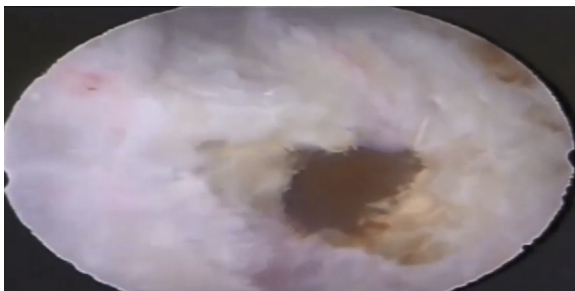


Fig 9. A large, full-thickness defect, viewed from the lateral portal, is shown after excision of the calcific deposits in a left shoulder. A large bone void is visible in the greater tuberosity. The patient is in the beach-chair position.

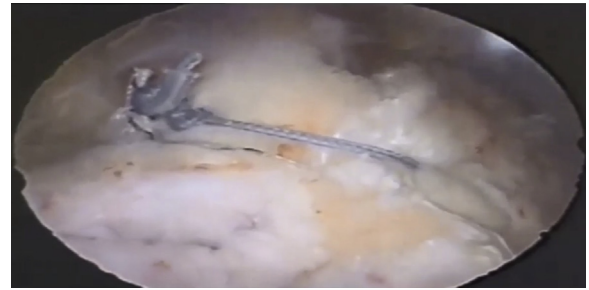

Fig 10. Adequate mobility of the tendinous tissue allows for the reapproximation of a full-thickness defect in a left shoulder, with little tension, using 2 side-to-side convergence sutures. This technique is used if there is a large cyst in the region of the greater tuberosity or if very poor bone quality precludes suture anchor placement. The repair is visualized from the lateral portal in this case, and the patient is in the beach-chair position.

Discussion

The management of rotator cuff defects created as a result of debridement of calcific tendinitis deposits is largely determined based on the size and location of the resulting rotator cuff lesion. If the defect is only superficial and partial thickness, debridement alone is usually sufficient. Good results can be expected using this method, and Maier et al.³ reported excellent results in 90% of patients after only debridement after a mean follow-up period of 3 years.⁴ However, the long-term sequelae especially with respect to the residual rotator cuff tissue after debridement remain unclear. After a mean follow-up period of 6 years, Balke et al.⁵ found that the shoulders that underwent arthroscopic debridement alone for calcific tendinitis had significantly lower clinical scores and a higher rate of partial-

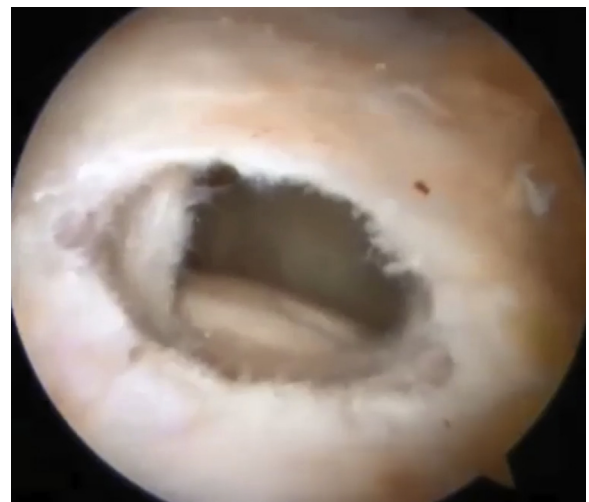

Fig 11. A large, full-thickness supraspinatus defect is shown, as viewed from the lateral portal, subsequent to complete calcific deposit excision in a left shoulder. The patient is in the beach-chair position.

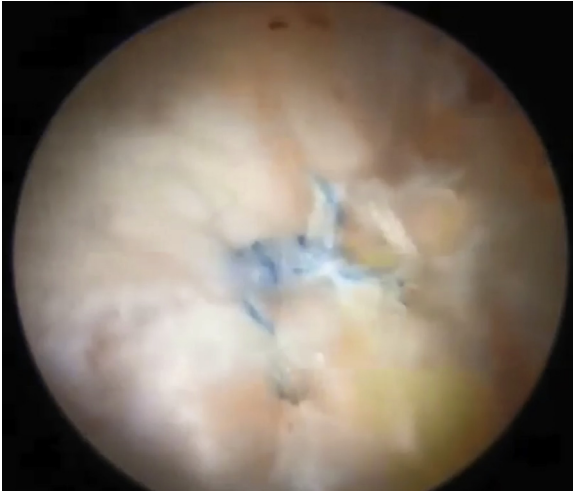


Fig 12. An anchor-supplemented repair of a full-thickness supraspinatus defect is seen, viewed through the lateral portal, incorporating the margins of the rotator cuff defect in a left shoulder. The patient is in the beach-chair position.

thickness tendon tears than the contralateral healthy shoulders. Maier et al., however, performed second-look arthroscopy 7 years after debridement of a calcific deposit and reported that the tendon exhibited complete remodeling.

If the remaining defect is nearly complete or full thickness in depth, repair is generally completed. Such repairs are generally carried out either by a side-to-side repair technique or through use of suture anchors in a fashion similar to the techniques used for rotator cuff tears not associated with calcific tendinitis. Ranalletta et al.⁴ reported favorable outcomes after repair of such defects in this clinical setting. In a cohort of 70% of their patients for whom postoperative magnetic resonance imaging was available, Ranalletta et al. reported that no subsequent tendon tearing was observed. Yoo et al.⁶ also reported success after either performing side-to-side repairs or using suture anchors to achieve repair, but they did note that postoperative stiffness developed in 10 of their 35 study patients.

Proper management of rotator cuff defects after debridement of calcific deposits can be a significant challenge. In general, small defects can be effectively managed with debridement alone, whereas larger residual defects may require either side-to-side suture repair or suture anchor-supplemented repair. A

Table 2. Pearls and Pitfalls

Pearls

Intraoperative fluoroscopic imaging aids in ensuring that all of the calcific deposits have been removed.

A spinal needle can be effective in identifying calcific deposits that are not visible arthroscopically.

Use of a suture marker can help to localize a calcific deposit on the opposite surface of the rotator cuff tendon.

Pitfalls

Overzealous debridement of the rotator cuff tendon adjacent to the calcific deposit can result in an unnecessarily large defect that may be challenging to repair.

Failure to accurately localize the calcific deposit within the tendon can lead to iatrogenic rotator cuff damage remote from the true location of the calcific defect.

summary of the discussed clinical techniques and precautions is shown in Table 2.

References

1. Serafini G, Sconfienza LM, Lacelli F, Silvestri E, Aliprandi A, Sardanelli F. Rotator cuff calcific tendonitis: Short-term and 10-year outcomes after two-needle US-guided percutaneous treatment—Nonrandomized controlled trial. *Radiology* 2009;252:157-164.
2. Verhaegen F, Brys P, Debeer P. Rotator cuff healing after needling of a calcific deposit using platelet-rich plasma augmentation: A randomized, prospective clinical trial. *J Shoulder Elbow Surg* 2016;25:169-173.
3. Maier D, Jaeger M, Izadpanah K, Bornebusch L, Suedkamp NP, Ogon P. Rotator cuff preservation in arthroscopic treatment of calcific tendinitis. *Arthroscopy* 2013;29:824-831.
4. Ranalletta M, Rossi LA, Bongiovanni SL, Tanoira I, Piuze N, Maignon G. Arthroscopic removal and rotator cuff repair without acromioplasty for the treatment of symptomatic calcifying tendinitis of the supraspinatus tendon. *Orthop J Sport Med* 2015;3:1-5.
5. Balke M, Bielefeld R, Schmidt C, Dedy N, Liem D. Calcifying tendinitis of the shoulder: Midterm results after arthroscopic treatment. *Am J Sports Med* 2012;40:657-661.
6. Yoo JC, Park WH, Koh KH, Kim SM. Arthroscopic treatment of chronic calcific tendinitis with complete removal and rotator cuff tendon repair. *Knee Surg Sports Traumatol Arthrosc* 2010;18:1694-1699.
7. Barber FA, Cowden CH. Arthroscopic treatment of calcific tendonitis. *Arthrosc Tech* 2014;3:237-240.
8. Wikipedia. Calcific tendinitis, https://en.wikipedia.org/w/index.php?title=Calcific_tendinitis&oldid=864242353. Accessed December 12, 2018.