

# Treatment Following Intoxication With Lethal Dose of Paraquat: A Case Report and Review of Literature

Mohammad Ali Davarpanah<sup>1</sup>; Farideh Hosseinzadeh<sup>2</sup>; S. Saeed Mohammadi<sup>2,\*</sup>

<sup>1</sup>Department of Infectious Diseases, Gastroenterohepatology Research Center, Shiraz University of Medical Sciences, Shiraz, IR Iran

<sup>2</sup>Student Research Committee, School of Medicine, Shiraz University of Medical Sciences, Shiraz, IR Iran

\*Corresponding Author: S. Saeed Mohammadi, Student Research Committee, School of Medicine, Shiraz University of Medical Sciences, Shiraz, IR Iran. Tel: +98-9364402630, E-mail: s.saeed.mohammadi@gmail.com

Received: April 9, 2014; Revised: September 9, 2014; Accepted: March 30, 2015

**Introduction:** Paraquat is a widely used nitrogen-based herbicide which is lethal and causes multi-organ failure by accumulation in cells, which subsequently leads to death.

**Case Presentation:** The present case report introduced a 25-year-old male with nausea, vomiting, and severe substernal burning sensation after incidentally ingestion of a large amount of paraquat. The treatment of the patient with antioxidants (N-acetylcysteine and vitamin E) and hemodialysis started immediately after arriving to the hospital.

**Conclusions:** Immediate and adequate use of antioxidants and hemodialysis has an undeniable and important role in survival of patients after ingestion of a large amount of paraquat.

**Keywords:** Paraquat; Antioxidants; Acetylcysteine; Vitamin E

## 1. Introduction

Pesticide poisoning is one of the major public health concerns in developing countries due to its rate of hospitalization and mortality (1). Annually, there are about two million hospitalization cases as a result of pesticide poisoning. Although paraquat is responsible for about 0.34 of all poisonings, it has the highest mortality rate amongst them (2). Paraquat, a nitrogen-based herbicide widely used for controlling weed growth, is severely toxic for humans and many cases of death have been reported due to its poisoning. Paraquat exerts its herbicidal effect by inhibiting the function of the intracellular electron transfer systems in plants (3). The rapid distribution of paraquat throughout the body is one of the major factors of its high mortality rate. It specially accumulates in the lung via an energy-dependent process, called polyamine transport system, in Clara cells and pneumocyte types 1 and 2. When accumulated in the lung, paraquat produces superoxide anion which leads to hydrogen peroxide and hydroxyl radical formation. Oxidative insult causes respiratory failure due to lung fibrosis, which leads to death (3, 4). The depletion of nicotinamide adenine dinucleotide phosphate (NADPH) sources due to the oxidation of NADPH by paraquat disrupts biochemical processes requiring NADPH. Paraquat also causes oxidative degeneration of cellular polyunsaturated fatty acids by lipid peroxidation (5, 6). Finally, it damages the lung, liver, and kidneys, causes multi-organ failure and subsequently leads to death due to pulmonary fibrosis. The clinical

manifestation of paraquat poisoning can be categorized into three groups: 1) mild poisoning (< 20 mg paraquat ion per kilogram of body weight), in which the patients often have minor gastrointestinal symptoms and usually recover fully; 2) severe poisoning (20 - 40 mg paraquat ion per kilogram of body weight), in which patients develop acute renal failure, acute lung injury and progressive pulmonary fibrosis, which leads to respiratory failure 2 - 3 weeks after the ingestion of paraquat; 3) fulminant poisoning (> 40 mg paraquat ion per kilogram of body weight); this high concentration of paraquat establishes multiple organ failure, leading to death within hours to a few days after the ingestion (7).

This article presented a case of severe paraquat poisoning and discussed the probable ways for effective management of the patient.

## 2. Case Presentation

The patient, a single 25-year-old male in reported good health, was admitted in 2011 to Faghihi Hospital in Shiraz, southern Iran, due to nausea, vomiting, and severe substernal burning sensation after accidentally poisoning with about 100 mL concentrated paraquat (60% solution). He was using a spray gun during farming when he was accidentally intoxicated with paraquat. Paraquat was sprayed to his face and mouth, so, he swallowed it instantly and then vomited the content. Therefore, he was brought to the emergency department for further evaluation. Initially, he was treated using gastrointesti-

nal lavage, which is a standard practice for PQ poisoning. The patient received gastric evacuation followed by activated charcoal (1 g/kg). Hemodialysis was immediately carried out for him through double lumen catheter. Subsequently, he received antibiotics (cefepime 3 g/day and clindamycin 1.8 g/day) and antioxidants (vitamin E and N-acetylcysteine (NAC)). The initial complete blood count (CBC) was normal. Thereafter, he showed a rise in the leukocyte count from  $8.3 \times 10^3$  in the day of admission to  $25.49 \times 10^3$  on the 10th day and a decrease in hemoglobin from 14.6 on the day of admission to 10.6 g/dL on the 27th day of the admission.

Blood urea nitrogen (BUN) and creatinine (Cr) elevated gradually to 68 and 5.7, respectively, in five days; the patient became oliguric; so, hemodialysis was performed four other times when Cr and BUN were back to normal.

During the hospital course, the oxygen saturation dropped to 73.9% - 91.3% and the arterial partial pressure of oxygen fluctuated between 37.2 - 49.1 mmHg. The serum  $\text{HCO}_3$  was between 13.1 - 24.2 and the pH was between 7.43 - 7.59.

The initial chest X-ray was normal, but chest CT scan revealed severe lung fibrosis three weeks later. On the second day of admission, he developed dysphagia and several oral ulcers, so endoscopy was performed, which showed multiple lesions in different sizes distributed in the cricopharyngeus and the upper third part of the esophagus.

At the admission time, liver transaminases were close to normal, but a significant rise happened in the aspartate aminotransferase (AST) and alanine aminotransferase (ALT) levels (339 and 230, respectively). These enzymes gradually regressed to the normal limits over about one month. In addition, this hepatobiliary damage led to a rise in alkaline phosphatase, total and direct bilirubin values (1258 u/L, 13.06 mg and 9.44 mg, respectively); so, he became severely icteric. These figures reversed to normal ranges till the last day of admission.

Erythrocyte sedimentation rate (ESR) and C-reactive protein (CRP) values were 62 mm/h and 48 (positive), respectively on the seventh day of admission. The patient was relatively well on the 28th day of admission, so he was discharged.

Seven months later, the patient referred with dyspnea. Physical examination showed decreased breathing sound and diffused rales. Therefore, he was admitted to our emergency room with the impression of pneumonia. Lab data showed mild leukocytosis ( $12.2 \times 10^3$  u/L), normal BUN and Cr levels and normal liver function test except for alkaline phosphatase which was 507 u/L. Chest X-ray showed three bullae in the upper and middle lobes of the right lung which caused the right lower lobe to collapse, moving the heart and the mediastinum to the left due to the pressure effect and the fibrotic band in the left upper lobe because of subsegmental collapse or linear atelectasis. A bulla in the lingual lobe of the left lung was seen.

The patient received antibiotics for two days, but on the

second day he left the hospital and did not stay for further evaluation.

Three months later he developed dyspnea and fever again, so he was admitted with impression of pneumonia. Lab data showed normal BUN and Cr and electrolytes. The total bilirubin increased to 1.33 and ALT to 48. His alkaline phosphatase was 575 u/L. He showed leukocytosis ( $20.44 \times 10^3$  u/L). Ampicillin-sulbactam, azithromycin, prednisolone, salbutamol, and NAC were prescribed for him. The patient was discharged on the next day of admission.

On the follow up, chest CT-scan was prescribed for the patient and due to emphysematous lung and multiple large bullae in the right lung (Figure 1), the patient underwent anterolateral thoracotomy, pneumolysis, bullectomy and nonanatomical segmentectomy.

Another chest CT-scan was performed after the surgery. In the new chest CT-scan, the left lung field was well aerated and well applied to the chest wall without evidence of pleural effusion or fluid collection. However, hydro-pneumothorax in the right upper zone and also consolidation in the right middle and lower lobes with air bronchogram were noted. There was also a large bulla in the LT lingual lobe.

He was relatively well for several months after the surgery, when he developed fever and cough and was admitted to the hospital with impression of infected bulla and lung abscess. He received imipenem 2 g/day and azithromycin 500 mg once a day, but fever and cough did not stop; so, pigtail was inserted under the guide of sonography to drain the abscess of the right lung. Spiral chest CT-scan showed multiple cystic formations with irregular walls which were noted bilaterally. Consolidation was noted in the right lower lobe associated with air bronchogram (Figure 2).

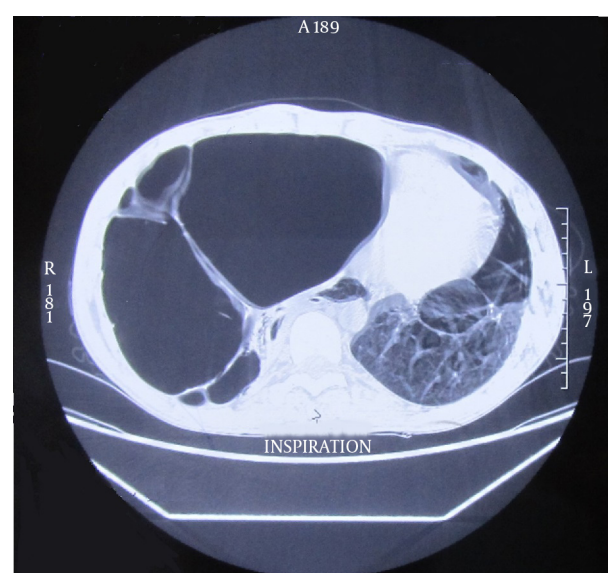
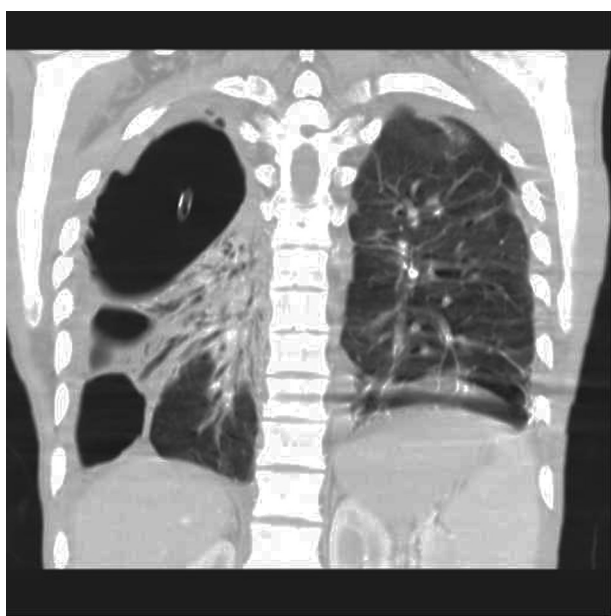


Figure 1. Multiple Large Bullae in the Right Lung



**Figure 2.** Multiple Cystic Formations With Irregular Walls Bilaterally

After drainage of the abscess by pigtail and continuing antibiotic therapy, the patient's condition got better and he was discharged.

### 3. Discussion

As noted before, fulminant poisoning of the patient by paraquat can cause multiple organs failure and death within hours to days after poisoning. Poor prognostic factors for a patient with acute paraquat intoxication are hemoglobin  $14.4 \pm 1.8$  g/dL, white blood cell (WBC) count =  $17.49 \pm 8.8 \times 10^3$ , pH =  $7.389 \pm 0.10$ , PaCO<sub>2</sub> =  $28.69 \pm 7.0$  mmHg, PaO<sub>2</sub> =  $96.59 \pm 29.2$  mmHg, BUN =  $22.69 \pm 23.6$  mg/dL, Cr =  $2.29 \pm 2.1$  mg/dL, AST =  $77.79 \pm 121.4$  IU/L, ALT =  $63.39 \pm 120.1$  IU/L, total bilirubin =  $1.89 \pm 2.4$  mg/dL, amylase =  $512.29 \pm 794.9$  IU/L, and glucose =  $174.29 \pm 84.7$  mg/dL (8). Despite fulminant poisoning of our patient, he interestingly survived. The patient experienced multiple organ failures in the first days of poisoning, but he recovered. Whereas there are no pharmacological antagonist and chelating agents for the poison, management of the paraquat stays mainly supportive and directed toward modification of the toxicokinetics of the agent. Thereby, due to mechanisms of injury, using antioxidants have become the main management of paraquat poisoning (3).

NAC is a derivative of amino acid L-cysteine, which acts as sulfhydryl group donor for restoring glutathione (9, 10). Glutathione acts as an antioxidant, leading to the destruction of free radicals. In vitro exposure of pneumocytes with paraquat and the inhibition of apoptosis by adding NAC suggests preventive effect of NAC in paraquat toxicity (11). NAC increases the glutathione content and protects rat alveolar type II cells against paraquat-induced cytotoxicity (12).

Vitamin E is a lipid-soluble vitamin, which has antioxidant effect. This vitamin exerts its effect via disrupting free radicals and also preventing the oxidation of unsaturated fatty acids. There are some controversial studies on the effect of vitamin E on paraquat toxicity. Several studies showed that vitamin E-deficient animals that are exposed to paraquat have less survival (13, 14). Therefore, the administration of vitamin E to vitamin E-deficient animals before exposure to paraquat lessened the paraquat toxicity.

Further studies showed the neutralizing effects of vitamin E in hepatocytes exposed to paraquat in vivo. Vitamin E, administered after the intake of paraquat was inhibited, increased lactate dehydrogenase, an indicator of liver damage clinically and of cytotoxicity of tissue cultures in vitro, lipid peroxidation and cell death, an indicator of the protein contents of cells (15).

In this case, vomiting the content of stomach readily after the ingestion of the poison, starting hemodialysis early after the admission, and using antioxidants such as NAC and vitamin E seemed to be the reasons for the survival of the patient.

### Acknowledgements

We thank Dr. Shokrpour for revising the English grammar of this article.

### Authors' Contributions

Acquisition of data: Farideh Hosseinzadeh. Drafting of the manuscript and critical revision of the manuscript for important intellectual content: S. Saeed Mohammadi. Study supervision: Mohammad Ali Davarpناه.

### References

- Bertolote JM, Fleischmann A, Eddleston M, Gunnell D. Deaths from pesticide poisoning: a global response. *Br J Psychiatry*. 2006;**189**:201-3.
- Klein Schwartz W, Smith GS. Agricultural and Horticultural Chemical Poisonings: Mortality and Morbidity in the United States. *Ann Emerg Med*. 1997;**29**(2):232-8.
- Suntres Z. Role of antioxidants in paraquat toxicity. *Toxicol*. 2002;**180**(1):65-77.
- Dinis-Oliveira RJ, Duarte JA, Sanchez-Navarro A, Remiao F, Bastos ML, Carvalho F. Paraquat poisonings: mechanisms of lung toxicity, clinical features, and treatment. *Crit Rev Toxicol*. 2008;**38**(1):13-71.
- Comporti M. Three models of free radical-induced cell injury. *Chem Biol Interact*. 1989;**72**(1-2):1-56.
- Gram TE. Chemically reactive intermediates and pulmonary xenobiotic toxicity. *Pharmacol Rev*. 1997;**49**(4):297-341.
- Sabzghabae AM, Eizadi-Mood N, Montazeri K, Yaraghi A, Golabi M. Fatality in paraquat poisoning. *Singapore Med J*. 2010;**51**(6):496-500.
- Lee EY, Hwang KY, Yang JO, Hong SY. Predictors of survival after acute paraquat poisoning. *Toxicol Ind Health*. 2002;**18**(4):201-6.
- Anderson ME, Luo JL. Glutathione therapy: from prodrugs to genes. *Semin Liver Dis*. 1998;**18**(4):415-24.
- Kelly GS. Clinical applications of N-acetylcysteine. *Altern Med Rev*. 1998;**3**(2):114-27.
- Cappelletti G, Maggioni MG, Maci R. Apoptosis in human lung epithelial cells: triggering by paraquat and modulation by antioxidants. *Cell Biol Int*. 1998;**22**(9-10):671-8.
- Hoffer E, Baum Y, Tabak A, Taitelman U. N-acetylcysteine increas-

- es the glutathione content and protects rat alveolar type II cells against paraquat-induced cytotoxicity. *Toxicol Lett.* 1996;**84**(1):7-12.
13. Block ER. Potentiation of acute paraquat toxicity by vitamin E deficiency. *Lung.* 1979;**156**(3):195-203.
  14. Bus JS, Aust SD, Gibson JE. Lipid peroxidation: a possible mechanism for paraquat toxicity. *Res Commun Chem Pathol Pharmacol.* 1975;**11**(1):31-8.
  15. Watanabe N, Shiki Y, Morisaki N, Saito Y, Yoshida S. Cytotoxic effects of paraquat and inhibition of them by vitamin E. *Biochim Biophys Acta - Gen Subjects.* 1986;**883**(3):420-5.