

● IMAGING IN NEURAL REGENERATION

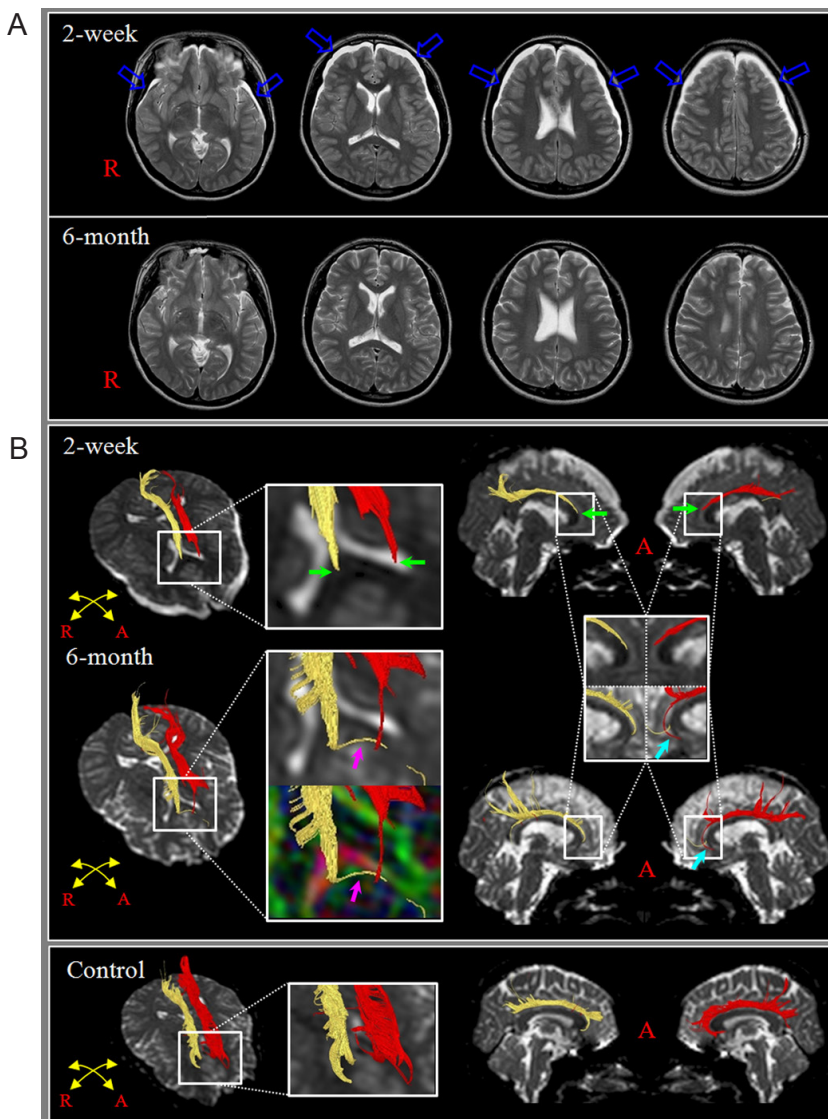
## Recovery of injured cingulum in a patient with traumatic brain injury

The cingulum is the neural fiber bundle that connects the basal forebrain and medial temporal lobe. The cingulum contains the medial cholinergic pathway, which originates from the basalis nucleus of Meynert in the basal forebrain. Therefore, it is important for memory function (Malykhin et al., 2008; Hong and Jang, 2010). In the past, identification of the cingulum on conventional brain MRI has been impossible because it cannot discern the cingulum from other adjacent structures. Diffusion tensor tractography (DTT), derived from diffusion tensor imaging (DTI), allows three-dimensional visualization and estimation of the cingulum (Malykhin et al., 2008). Many DTI studies have reported on injury of the cingulum following traumatic brain injury (TBI) (Hong and Jang, 2010; Hong et al., 2012; Jang et al., 2013). However, very

little is known about neural recovery of injured cingulum following TBI.

In the current study, we presented with a patient that had TBI and appeared to show neural recovery of injured cingulum on DTT.

A 19-year-old, right-handed female who had suffered a traffic accident underwent conservative management for diffuse traumatic axonal injury at the department of neurosurgery of a university hospital. The patient lost consciousness for 5 days due to head trauma since the time of TBI onset and transferred to the rehabilitation department of the same hospital. Brain MRI was performed 2 weeks after onset and showed subdural hygroma on both frontotemporal areas and an encephalomalactic lesion at the body of the corpus callosum (**Figure 1A**). Upon evaluation for cognitive function performed 2 weeks after onset, the patient revealed severe cognitive impairment (total intelligence quotient (IQ) on the Wechsler adult intelligence scale: 65, global memory on the Memory Assessment Scale (MAS): 61 (< 1%ile), immediate memory on MAS: 83 (13%ile). The patient underwent comprehensive rehabilitation, including physical and cogni-



**Figure 1** Conventional MRI and diffusion tensor tractography (DTT) images of a 19-year-old female patient with traumatic brain injury.

(A) T2-weighted MR images taken 2 weeks and 6 months after onset show subdural hygromas (blue arrows) in both fronto-temporal areas (2 weeks) and no specific lesions in the basal forebrain and cingulum areas. On the T2-weighted MR images taken at 6 months after onset, subdural hygromas are disappeared. (B) 2-week DTT for cingulum (yellow: right; red: left) reveals discontinuities (green arrows) anterior to genu of corpus callosum in both cingulum compared with that of a normal control (a 21-year-old female). On 6-month follow up DTTs, the left cingulum elongates to the left basal forebrain (skyblue arrows) and the right cingulum is connected to the left basal forebrain *via* new tract (pink arrows) which passes anterior to the genu of corpus callosum. A: Anterior; R: right.

tive therapies, until 6 months after onset and showed nearly complete recovery in terms of motor and language functions. At the 6-month evaluation, the cognitive impairment improved as much as total IQ: 82, global memory on the MAS: 102 (55%ile), immediate memory on MAS: 107 (68%ile) (Wechsler, 1981; Williams, 1991).

DTIs were acquired twice (2 weeks and 6 months after onset) using a 6-channel head coil on a 1.5-T Philips Gyroscan Intera (Philips, Ltd., Best, The Netherlands) with single-shot echo-planar imaging. In addition, one age-matched normal subject (a 21-year-old female) was enrolled in this study. Imaging was performed. For each of the 32 non-collinear diffusion-sensitizing gradients, we acquired 67 contiguous slices parallel to the anterior commissure-posterior commissure line. Imaging parameters used were as follows: acquisition matrix =  $96 \times 96$ , reconstructed to matrix =  $128 \times 128$  matrix, field of view =  $221 \times 221$  mm<sup>2</sup>, repetition time = 10,726 ms, echo time = 76 ms, sensitivity encoding factor = 2, echo planar imaging factor = 49 and  $b = 1,000$  s/mm<sup>2</sup>, number of excitations = 1, and a slice thickness of 2.3 mm. Fiber tracking was performed using the fiber assignment continuous tracking (FACT) algorithm implemented within the DTI task card software (Mori et al., 1999; Stieltjes et al., 2001). The cingulums were reconstructed using fibers passing through two regions of interest (ROIs). The first ROI was drawn at the middle portion of cingulum (green color) on the color map with coronal image (blue color: superiorinferior orientation; red color: mediolateral orientation; green color: anteroposterior orientation) (Malykhin et al., 2008). The second ROI was drawn at the posterior portion of cingulum (green color) on the color map with coronal image (Malykhin et al., 2008). Termination criteria were fractional anisotropy (FA) < 0.2 and an angle change > 25°.

On 2-week DTIs for cingulums in the patient, we observed discontinuations of both cingulums anterior to the genu of corpus callosum. However, on 6-month follow up DTIs, the left cingulum was elongated and showed the integrity to the left basal forebrain and the right cingulum was connected to left basal forebrain by a new tract that passed anterior to the genu of corpus callosum and was not observed on 2-week DTT (Figure 1B).

In the current study, we observed changes of DTT for cingulum along with changes of cognitive impairment in a patient with TBI. Two-week DTIs of the patient showed discontinuations above the basal forebrain anterior to the genu of corpus callosum in both cingulums. Considering that the patient satisfied the diagnostic criteria of diffuse axonal injury (a mechanism of injury associated with significant acceleration/deceleration force, loss of consciousness for 5 days since the onset of TBI without a lucid interval, no specific lesions in the basal forebrain and cingulum areas), the patient appeared to get traumatic axonal injury in the anterior portion of both cingulums by the traffic accident. However, on 6-month follow up DTIs, the left cingulum was elongated to the basal forebrain and the right cingulum was connected to the left basal forebrain via a new tract that passed anterior to the genu of corpus callosum. These DTT changes of both cingulums appeared to indicate the recovery of both injured cingulums and to coincide with the improvement of cognitive impairment, in particular, the improvement of immediate memory impairment (Wolk and Budson, 2010).

In conclusion, we report on a patient who appeared to show

recovery of injured cingulums following TBI. Regarding the recovery of an injured cingulum, to the best of our knowledge, there was only a patient with hypoxic ischemic brain injury following spontaneous subarachnoid hemorrhage whose discontinued cingulum was elongated to the basal forebrain (Seo and Jang, 2013). Therefore, this is the first DTT study that tried to demonstrate the recovery of injured cingulum in patients with TBI. We believe that the evaluation of cingulum using DTT would be helpful in the diagnosis of cingulum injury and in estimating the changes of cingulum injuries in TBI. However, because it is a case report, this study is limited. Further complementary studies involving larger numbers of patients are warranted.

*This research was supported by Basic Science Research Program through the National Research Foundation of Korea (NRF) funded by the Ministry of Education, Science and Technology, No. 2012RIA1A4A01001873.*

Sung Ho Jang, Seong Ho Kim, Hyeok Gyu Kwon\*

Department of Physical Medicine and Rehabilitation, College of Medicine, Yeungnam University 317-1, Daemyung dong, Namku, Daegu, 705-717, Republic of Korea (Jang SH, Kwon HG)  
Department of Neurosurgery, College of Medicine, Yeungnam University 317-1, Daemyung dong, Namku, Daegu, 705-717, Republic of Korea (Kim SH)

\*Correspondence to: Hyeok Gyu Kwon,  
khg0715@hanmail.net.

Accepted: 2014-12-06

doi:10.4103/1673-5374.152391 <http://www.nrronline.org/>  
Jang SH, Kim SH, Kwon HG (2015) Recovery of injured cingulum in a patient with traumatic brain injury. *Neural Regen Res* 10(2):323-324.

## References

- Hong JH, Jang SH (2010) Neural pathway from nucleus basalis of Meynert passing through the cingulum in the human brain. *Brain Res* 1346:190-194.
- Hong JH, Jang SH, Kim OL, Kim SH, Ahn SH, Byun WM, Hong CP, Lee DH (2012) Neuronal loss in the medial cholinergic pathway from the nucleus basalis of Meynert in patients with traumatic axonal injury: a preliminary diffusion tensor imaging study. *J Head Trauma Rehabil* 27:172-176.
- Jang SH, Kim SH, Kim OR, Byun WM, Kim MS, Seo JP, Chang MC (2013) Cingulum injury in patients with diffuse axonal injury: A diffusion tensor imaging study. *Neurosci Lett* 543:47-51.
- Malykhin N, Concha L, Seres P, Beaulieu C, Coupland NJ (2008) Diffusion tensor imaging tractography and reliability analysis for limbic and paralimbic white matter tracts. *Psychiatry Res* 164:132-142.
- Mori S, Crain BJ, Chacko VP, van Zijl PC (1999) Three-dimensional tracking of axonal projections in the brain by magnetic resonance imaging. *Ann Neurol* 45:265-269.
- Seo JR, Jang SH (2013) Recovery of injured cingulum in a patient with brain injury: diffusion tensor tractography study. *NeuroRehabilitation* 33:257-261.
- Stieltjes B, Kaufmann WE, van Zijl PC, Fredericksen K, Pearlson GD, Solaiyappan M, Mori S (2001) Diffusion tensor imaging and axonal tracking in the human brainstem. *Neuroimage* 14:723-735.
- Wechsler D (1981) Manual for the wechsler adult intelligence scale-revised. New York: The Psychological Corporation.
- Williams JM (1991) MAS: Memory Assessment Scales: professional manual. Odessa, Fla.: Psychological Assessment Resources.
- Wolk DA, Budson AE (2010) Memory systems. *Continuum; Behavioral Neurology* 16:15-28.

Copyedited by Davenport ND, Li CH, Song LP