

Journal of Veterinary Internal Medicine



Official Publication of the American College of Veterinary Internal Medicine

Volume 10, Number 2

March-April 1996

REVIEW ARTICLE

- 51 **Gastrointestinal Motility and Disease in Large Animals**
Christine B. Navarre and Allen J. Roussel
- 60 **Plasma von Willebrand Factor Antigen Concentration and Buccal Mucosal Bleeding Time in Dogs With Experimental Hypothyroidism**
David L. Panciera and Gary S. Johnson
- 65 **A Retrospective Study of Cavernous Sinus Syndrome in 4 Dogs and 8 Cats**
Sharon K. Theisen, Michael Podell, Theresa Schneider, David A. Wilkie, and William R. Fenner
- 72 **Cystic Meningiomas in 2 Dogs**
Rodney S. Bagley, Joe N. Kornegay, Steven B. Lane, Donald L. Thrall, and Rodney L. Page
- 76 **Amputation and Carboplatin for Treatment of Dogs With Osteosarcoma: 48 Cases (1991 to 1993)**
Philip J. Bergman, E. Gregory MacEwen, Ilene D. Kurzman, Carolyn J. Henry, Alan S. Hammer, Deborah W. Knapp, Ann Hale, Stephen A. Kruth, Mary K. Klein, Jeffrey Klausner, Alan M. Norris, Dudley McCaw, Rodney C. Straw, and Stephen J. Withrow
- 82 **Evaluation of a Whole Blood Glutaraldehyde Coagulation Test for the Detection of Failure of Passive Transfer in Calves**
Jeff W. Tyler, Thomas E. Besser, Leilani Wilson, Dale D. Hancock, Sean Sanders, and Douglas E. Rea
- 85 **Effects of Enalapril on Exercise Tolerance and Longevity in Dogs With Heart Failure Produced by Iatrogenic Mitral Regurgitation**
Robert L. Hamlin, Antonio M. Benitz, Glenn F. Ericsson, Sam Cifelli, and Carolyn P. Daurio
- 88 **Bradycardia-Associated Episodic Weakness, Syncope, and Aborted Sudden Death in Cardiomyopathic Doberman Pinschers**
Clay A. Calvert, Gilbert J. Jacobs, and Cynthia W. Pickus
- ## CASE REPORTS
- 94 **Clostridial Myonecrosis, Hepatitis, and Nephritis in a Llama With Vegetative Endocarditis**
Jeff W. Tyler, Annette Petersen, Jan Ginsky, Steven Parish, Thomas Besser, Charles Leathers, and Joseph Beyer
- 97 **Progression of Subaortic Stenosis Detected by Continuous Wave Doppler Echocardiography in a Dog**
Tomohiro Nakayama, Yoshito Wakao, Ryokichi Ishikawa, and Mitsugi Takahashi
- ## CORRESPONDENCE
- 99
- ## ERRATUM
- 101
- ## ANNOUNCEMENTS
- 101

Journal of Veterinary Internal Medicine



Official Publication of the American College of Veterinary Internal Medicine

Editorial Board

C. Guillermo Couto, DVM
Editor-in-Chief
Ohio State University

Cleta Sue Bailey, DVM, PhD
Neurology
University of California, Davis

Peter D. Constable, BVSc, MS, PhD
Statistics
University of Illinois

E. Gregory MacEwen, VMD
Oncology
University of Wisconsin

D. David Sisson, DVM
Cardiology
University of Illinois

Jeff W. Tyler, DVM, MPVM, PhD
Statistics
Washington State University

Colin F. Burrows, BVetMed, PhD, MRCVS
Small Animal Internal Medicine
University of Florida

Stephen P. DiBartola, DVM
Small Animal Internal Medicine
Ohio State University

Kenneth W. Hinchcliff, BVSc, PhD
Large Animal Internal Medicine
Ohio State University

Richard W. Nelson, DVM
Small Animal Internal Medicine
University of California, Davis

Bradford P. Smith, DVM
Large Animal Internal Medicine
University of California, Davis

Officers of the College

Gary P. Carlson - Chairperson
David C. Twedt - President
Cheryl L. Chrisman - President Elect
Gregory F. Grauer - Vice President

Members of the Board

Michael S. Garvey - Internal Medicine
June Johnson - Executive Director
Joe N. Kornegay - Neurology
Bruce R. Madewell - Oncology
John E. Oliver - Professional Liaison
Keith P. Richter - At Large
D. David Sisson - Cardiology
Marilyn E. Stiff - At Large

Editorial Office: 4694 Cemetery Rd, Suite 395, Hilliard, OH 43026. Phone and Fax: 614-870-5328.

ACVIM Office: 7175 W Jefferson Ave, Suite 2125, Lakewood, CO 80235-2300.
Phone: 800-245-9081; 303-980-7136. Fax: 303-980-7137.

W.B. Saunders Company
A Division of Harcourt Brace & Company
The Curtis Center
Independence Square West
Philadelphia, Pennsylvania 19106-3399

Instructions for Authors

The *Journal of Veterinary Internal Medicine*, the Official Publication of the American College of Veterinary Internal Medicine, invites submission of clinical and research manuscripts in the areas of small animal and large animal internal medicine, cardiology, neurology, and oncology. The *Journal* is particularly interested in manuscripts dealing with results of prospective or retrospective studies on pathophysiology, diagnosis, prognosis, and treatment of naturally occurring diseases in animals. Review articles, brief communications, clinical vignettes, and letters to the Editor will also be accepted (see below). All manuscripts and letters are subject to editing before publication.

Manuscript Submission

Please submit **five** copies of the manuscript and **four** copies of all illustrations to: C. Guillermo Couto, DVM, Editor, 4694 Cemetery Road, Suite 395, Hilliard, OH 43026; 614-870-5328 (telephone and fax).

A nonrefundable fee of \$50.00 per manuscript (payable in US funds only) is required at the time of submission. It may be paid by check, money order (payable to ACVIM), or credit card.

Manuscripts will be considered for publication with the clear understanding that their contents have not been previously published (abstracts presented at scientific meetings are excepted), and have not been (and will not be) submitted or published elsewhere while acceptance by the *Journal* is under consideration. A cover letter with the name of a corresponding author and the following statement should accompany the manuscript: **"The author represents and warrants that his/her part of the work as submitted will in no way violate any copyright, or any other right."**

The *Journal* strongly discourages authors from fragmented reporting of aspects of a single investigation or clinical study. Authors submitting a manuscript that is but one of a number of existing or planned manuscripts related to a single study must, therefore, include a statement in the cover letter that (1) so identifies the paper, and (2) justifies the use of the fragmented approach. Related manuscripts, published or unpublished, should also be included with the submitted manuscript. The submitted manuscript itself must clearly explain and justify the fragmented approach and reveal the full extent of the investigation.

A copyright form will be sent to the corresponding author upon manuscript acceptance and must be signed by all authors prior to final processing of the manuscript.

All manuscripts will be reviewed by two experts in the field, usually, but not restricted to, diplomates of the American College of Veterinary Internal Medicine. Manuscripts will receive a priority score from the reviewers and the Editorial Board: those with a low priority score may be returned to the authors.

At the Editor's discretion, particularly meritorious manuscripts that are of unusually high priority and significance and that represent definitive and original studies will be considered as rapid publications. Authors will be notified by the Editorial Office upon scheduling of their manuscript as a rapid publication.

Manuscript Preparation

Manuscripts must be double spaced, typed on one side of standard typewriter or printer paper, leaving at least 1-inch margins. Page numbers should be included in the upper right-hand corner of each page. Each manuscript component should begin on a new page and should comprise the following:

Standard Paper

Title page: The first page should include the title of the manuscript, the names of the authors, their highest degrees, institutions or affiliations, and a short title for use as a running head. Separate paragraphs should specify where the work was done; whether the study was supported by a grant or otherwise; the meeting, if any, at which the

paper was presented; acknowledgments; and the name and address of the author to whom reprint requests should be sent.

Abstract: The abstract should not exceed 250 words. It should provide a concise, factual condensation of the manuscript, including the purpose(s) of the study, basic procedures, main findings, and principal conclusions.

Introduction: The introduction is untitled. Please provide a clear statement of the objective and rationale of the study, and provide only pertinent references. A brief overview of the topic is appropriate. An extensive review of the subject will not be accepted.

Materials and Methods: Include a clear description of the observations or experimental subjects. Provide a concise description of the experimental and statistical methods and of the procedures in sufficient detail to allow other workers to reproduce the results. A statement of animal care must be made, ie, animals were cared for according to the principles outlined in the NIH Guide for the Care and Use of Laboratory Animals. Statistical methods used must be outlined and referenced. When the methods have been extensively detailed elsewhere, there is no need to duplicate this material. Instead, list the appropriate reference.

Results: State concisely, in logical sequence, the results of the study. Subheadings may be used for particular sections, ie, clinical findings, radiographic findings, etc. Do not reproduce the same data in both tables and figures. Summarize the important observations.

Discussion: Provide a concise discussion of the investigation or study. Emphasize the new and important implications of the findings, their limitations, and how the observations relate to other relevant studies.

Text: Although considerable freedom regarding style and format will be afforded the author, the following guidelines are suggested for the sake of clarity.

1. When referring to a drug, use the generic name approved by the US Food and Drug Administration or recognized as the US-adopted name. Trade names may be used parenthetically at the author's discretion.
2. All measurements should be in the metric system. If confusion could result, include other measurement systems in parentheses.
3. Where an instrument or specific equipment is referred to that is not widely available, cite the source in footnotes.
4. In items of nomenclature, The *Journal of Veterinary Internal Medicine* adheres to the principles specified in *Nomina Anatomica*, *Nomina Histologica*, *Nomina Embryologica*, *Nomina Anatomica Veterinaria*, and *Nomina Anatomica Avium* where appropriate.

References: Number references consecutively in the order in which they are first mentioned in text (or tables and legends), using Arabic numerals. References must be verified by the author(s) against the original documents.

Reference listings should use the form adopted by the US National Library of Medicine and used in the *Index Medicus*. The following examples illustrate the proper style:

Journal Article

1. Divers TJ, Bartholomew RC, Messick JB, et al. Clostridium botulinum type B toxicosis in a herd of cattle and a group of mules. *J Am Vet Med Assoc* 1986;188:382-386.

Book

2. Ettinger SJ. *Textbook of Veterinary Internal Medicine*, 2nd ed. Philadelphia, PA: WB Saunders; 1983:55-57.

Chapter in a Book

3. Bonagura JD. Therapy of cardiac arrhythmias. In: Kirk RW, ed. *Current Veterinary Therapy*. Philadelphia, PA: WB Saunders; 1983:360-372.

Tables: Type each table on a separate sheet, double spaced. Number tables consecutively, as cited in text, and supply a brief title for

each. Give each column a short or abbreviated heading. Put explanatory matter in footnotes, not the heading.

Legends for Illustrations: Type legends double spaced, with Arabic numerals corresponding to the illustrations. Explain clearly in the legends any symbols, arrows, numbers, or letters used to identify parts of the illustrations. For photomicrographs, identify method of staining and magnification.

For further details concerning manuscript preparation consult the AMA's *Manual for Authors & Editors: Editorial Style & Manuscript Preparation and/or Uniform Requirements for Manuscripts Submitted to Biomedical Journals*.

Illustrations

Only high-quality illustrations will be considered for publication. Submit four copies of illustrations, measuring one column or 85 mm in maximum width. Large photographs measuring two columns (175 mm) will be occasionally considered. Smaller photographs are permissible, but they must be grouped to make maximum use of space. To depict magnification in photomicrographs, include in the photograph a line or rule of appropriate length and explain it in the legend. The author may wish to provide a montage of suggested photograph grouping, but the editor reserves the right to regroup them. Black-and-white illustrations, in the form of glossy prints, will be reproduced free of charge, but the editor reserves the right to establish a reasonable limit. Color illustrations may be published; the cost to the author for the publication of color illustrations will be determined for each article.

Line drawings should be done professionally, and photographed and reproduced to conform to the column widths noted above.

To avoid imprints on the face of photographs, do not write directly on the back of the photograph. Instead, affix a label on which the author's name, illustration number in Arabic numerals, indication of top, and brief title of the article have been previously written. The illustrations should be submitted **unmounted** and should be adequately protected from shipping damage.

Other Submissions

The guidelines for letters to the editor, brief communications, and review articles as they relate to illustrations, references, etc, are the same as those for the standard paper.

Letters: The letters to the editor section provides a forum for issues in veterinary internal medicine. Letters can relate to any aspect of internal medicine, as well as provide an opportunity for the reader to respond to the contents of *The Journal of Veterinary Internal Medicine*. Preliminary findings of new investigations will also be considered. Letters must not exceed two double-spaced typewritten pages.

Letters should be sent to: C. Guillermo Couto, DVM, Editor, 4694 Cemetery Road, Suite 395, Hilliard, OH 43026; 614-870-5328 (telephone and fax).

Brief Communications: The *Journal* will contain a separate section of brief communications. This section does not necessarily contain conventional subdivisions but must be accompanied by a brief abstract and essential references not to exceed ten. This section is meant to accommodate reports of small completed investigations, new techniques, or case descriptions where the findings are new or unique. Brief communications must not exceed three printed pages (approximately 7 double-spaced typewritten pages), including tables, illustrations, and references, and should be clearly marked "Brief Communication." Brief communications usually have the same priority for publication as regular manuscripts.

Clinical Vignettes: The *Journal* will also consider for publication short items for the "Clinical Vignettes" feature. This feature will be based on good quality photographs of cytological or gross clinical specimens, recordings of electrophysiologic measurements, ultrasound images, radiographs, or other diagnostic data. For each feature, the author will provide concise background clinical data and pertinent description of the illustrations submitted. The material should be presented as an unknown clinical entity to allow the reader to study the data and arrive at a clinical diagnosis or list of differential diagnoses. A brief discussion of the diagnostic work-up and definitive diagnosis will follow, and key references will be included. Material for considerations will include interesting diagnostic problems, new clinical entities, or new diagnostic methods that can be portrayed pictorially. The maximum page length for this feature will be two printed pages (approximately five double-spaced typewritten pages). Submissions to this feature will be subjected to peer review. The guidelines for photographs are listed elsewhere.

Review Articles: Review articles, which may be solicited by the editorial board or submitted unsolicited by the authors, are meant to provide the reader with an overview of the state of the art in a specialized area of veterinary internal medicine. They should be submitted by individuals who are actively working in the area and **not by individuals who have reviewed the literature as a prelude to beginning a project in the area.** The review should be informative and appreciated by the generalists as well as the specialists. Outlines of the unsolicited review articles should be submitted to the editors for approval before extensive writing is done.

Permissions

Permissions of author and publisher must be obtained for the use of previously published material (text, photographs, drawings) and must accompany the manuscript when it is submitted for publication.

Reprints

Reprints may be ordered on the reprint order form sent to the authors with page proofs.

If you wish to pay the \$50.00 manuscript submission fee by credit card, please complete this form and send it attached to your cover letter.

Visa MasterCard Credit Card # _____ Expiration _____

Name _____ Signature _____

Address _____

City _____ State _____ Zip Code _____

Country _____

Gastrointestinal Motility and Disease in Large Animals

Christine B. Navarre and Allen J. Rousel

An understanding of the relationship between gastrointestinal (GI) motility and disease is imperative for the proper treatment of large animal patients, especially as new therapeutic agents become available. However, the abundance of information that has become available in the last 2 decades makes gaining this understanding a formidable task. This article summarizes the changes in

The effects of disease on gastrointestinal (GI) motility have been investigated since the 19th century. However, there has been an explosion of information in the last 20 years, and it is no longer acceptable to describe changes in GI motility as simply increases or decreases in motility. GI motility can be evaluated by quantifying several different parameters. A better understanding of the relationship between GI motility and disease is imperative to proper patient care, especially as new therapeutic agents become available. This article focuses on the specific changes in GI motility caused by some common diseases and conditions encountered in large animal practice.

Until more studies specifically involving large animals are available, we must extrapolate from other species. However, in doing this, we must remember the extreme variation in the structure and function of the GI tract among species, particularly in the large intestine, and make extrapolations with caution. Data from human patients, small animals, and laboratory animals are included in this review; however, only those diseases and conditions affecting large animals are discussed. Also, only results of *in vivo* studies are included. More extensive reviews, including data from research *in vitro*, are available for most of these subjects. A brief discussion of normal motility patterns is included to familiarize the reader with terminology. For a more detailed description of normal motility, terminology, and recording methods, the reader is referred elsewhere.¹⁻³ Therapeutic options will not be discussed in this article, but several reviews on this subject are also available.^{4,5}

Normal GI Motility

Three basic parameters of GI motility can be measured: myoelectric activity, mechanical activity, and transit of intraluminal contents.¹ Myoelectric and mechanical activities are closely coupled: as one increases, so does the other.^{6,7} However, transit of gut contents does not always increase as myoelectric and mechanical activities increase.⁸

Two types of myoelectric activity, slow waves and spikes, are produced by the GI tract. Slow waves are subthreshold fluctuations in membrane potential that are not accompanied by muscle contraction (Fig 1),⁷ and are continually propagated from the esophagus to the rectum. Spikes are membrane fluctuations that exceed the threshold, causing depolarization and muscle contraction (Fig 2).⁷ They are usually superimposed on slow waves, and groups of spikes assume several different patterns depending on the species, the area of the GI tract, and the digestive state studied.

GI motility caused by some common diseases and conditions encountered in large animal practice, such as GI obstruction, postoperative ileus, resection and anastomosis, diarrhea, endotoxemia, GI parasitism, hypocalcemia, and pregnancy.

J Vet Intern Med 1996;10:51-59. Copyright © 1996 by the American College of Veterinary Internal Medicine.

The migrating myoelectric complex (MMC) is the myoelectric pattern in the stomach and small intestine of fasted nonruminants, fed and fasted ruminants, and pigs and horses fed *ad libitum*.^{2,3,9,11} There are 3 phases of the MMC: the quiescent phase, in which very little spike activity occurs; the irregular phase, characterized by intermittent spike activity; and the activity front, characterized by intense, continuous spike activity (Fig 3).^{1-3,9,10} There is very little muscle contraction or transit of gut contents during the quiescent phase.^{1,8} During the irregular phase, contractions mix the gut contents and propel them in an aboral direction.^{1,8,10} The activity front is accompanied by intense muscular contraction that obliterates the lumen, preventing backflow of contents as it propagates, or "migrates" down the gut.^{2,10} In nonruminants, and pigs and horses fed periodically, feeding abolishes the MMC pattern for several hours. The MMC pattern is replaced by the fed pattern, which is characterized by intermittent spike activity resembling the irregular phase.^{2,3,9,10}

Normal cecal and colonic myoelectric activities, like those of the small intestine, are characterized by slow waves and spikes. However, unlike the small intestine, the patterns of spikes vary greatly with the species and the area of the large intestine studied. The two major spike patterns are the short spike burst (SSB) and the long spike burst (LSB).^{1,2,12} SSBs cause segmental contractions and do not propagate; LSBs propagate both orally and aborally.^{1,2,12}

There are many interchangeable terms for all of the patterns described. The terminology used here is preferred and will be used in the rest of the article.

Intestinal Obstruction

Obstruction of the small and large intestines may be intraluminal (eg, intussusceptions, impactions, enteroliths, foreign bodies) or extraluminal (eg, displacements and entrapments).¹³ Both types are characterized by bowel distension

From the Department of Large Animal Medicine and Surgery, Texas Veterinary Medical Center, Texas A & M University, College Station, TX.

Accepted May 1, 1995.

Reprint requests: Christine B. Navarre, DVM, Department of Large Animal Surgery and Medicine, Auburn University, Auburn, AL 36849-5522.

Copyright © 1996 by the American College of Veterinary Internal Medicine

0891-6640/96/1002-0001\$3.00/0

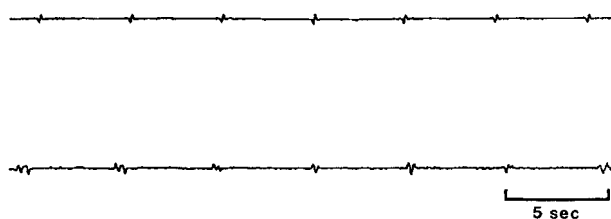


Fig 1. Slow waves recorded from the jejunum of a normal calf.

and increased intraluminal pressure orally, and absence of intraluminal contents and decreased intraluminal pressure aborally. Most of the information on changes of motility after obstruction was derived from models of acute obstruction of the small intestine in horses and ponies,¹⁴⁻¹⁷ cows,¹⁸ sheep,¹⁹ dogs,²⁰⁻²¹ and rats.²² Human patients with spontaneous obstruction have also been studied.²³

Despite differences in experimental design and species studied, the pattern of myoelectric activity of the segment oral to small intestinal obstruction was similar in most studies. Myoelectric and mechanical activity of the intestine after a complete obstruction consisted of alternating periods of contraction and quiescence.^{20,23} The period of contraction was characterized by clusters of discrete spikes on consecutive slow waves, or prolonged, constant spike activity that lasted for several seconds (Fig 4).^{14,15,18,20,22} The clusters of spikes were approximately 10 to 45 seconds in duration and occurred every 1 to 2 minutes.^{14,22} The mechanical correlate of the clustered spikes were small groups of contractions of medium amplitude and duration, interrupted by short periods of inactivity.¹⁶ When prolonged, constant spike complexes occurred, the mechanical activity consisted of single, high amplitude, contractions of long duration or spasms.¹⁵

Changes in small intestinal motility aboral to an obstruction were less consistent among studies. Total spike activity was significantly decreased aboral to small intestinal obstruction in dogs.^{20,21} Long periods of quiescence, infrequent activity fronts, and periods of no irregular activity of the small intestine were described in a pony, in contrast to continuous irregular activity after an initial quiescent period in rats.^{16,22} In sheep, total occlusion produced strong and prolonged bursts of activity aborally, whereas partial occlusion caused general inactivity.¹⁹ These inconsistencies may be explained

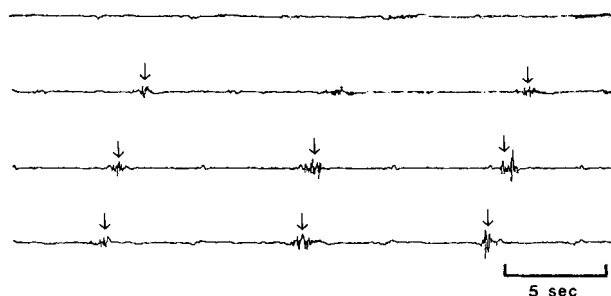


Fig 2. Spikes (arrows) superimposed on slow waves, recorded from the jejunum of a normal calf.

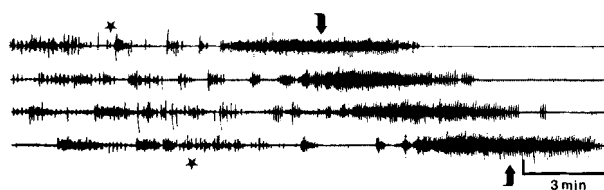


Fig 3. The phases of the migrating myoelectric complex recorded from a normal calf. Very little or no spike activity occurs in the quiescent phase intermittent spike activity occurs in the irregular phase (*) and intense, continuous spike activity occurs during an activity front (▲).¹

in part by species differences, experimental conditions, relationship of the recording period to feeding, and duration of the obstruction.

After relief of a small intestinal obstruction, the MMC was recognizable within 10 to 20 minutes, although duration of activity fronts is decreased and the quiescent phase was prolonged. Normalization of the MMC continued over time and was complete in 12 to 24 hours.^{18,19,22}

The pathogenesis of the changes associated with small intestinal obstruction are not clearly understood. It is postulated that distention oral to an obstruction activates local myenteric receptors; activity is then stimulated oral to the obstruction via cholinergic pathways, and activity aboral is inhibited via noncholinergic, nonadrenergic pathways.²¹

The response of the large intestine to obstruction has not been studied extensively. Lowe et al¹⁷ placed fistulas in the pelvic flexure of ponies and induced impactions by manipulating diet or creating intraluminal obstructions. Episodes of colic were accompanied by multiple high-amplitude, long-duration pressure peaks interpreted as contractions, oral and aboral to the pelvic flexure. Further research is needed before conclusions can be made about the effects of obstruction on large intestinal motility.

Postoperative Ileus

Veterinarians and physicians alike have long recognized postoperative ileus (POI) as a relevant clinical problem.^{24,25} It is characterized by dilation and lack of propulsive contractions of the gut leading to accumulation of fluid and gas.²⁶ Its importance as a clinical disease is unmistakable. In a

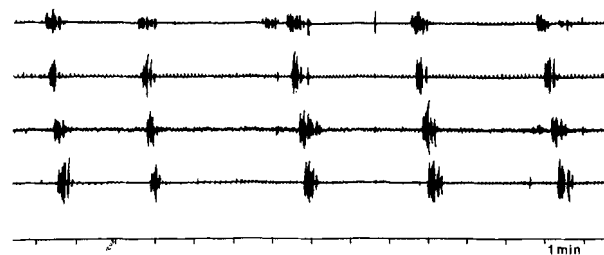


Fig 4. Clusters of spikes recorded from the jejunum of a calf during obstruction after administration of a psyllium-containing oral electrolyte supplement (Deliver [previously named Diaproof]; Miles Inc, Shawnee, KS).

retrospective study of postoperative complications of horses with colic, POI was the cause of death in 36 of 84 patients (42.9%).²⁵ In human patients, POI causes serious discomfort and prolongs hospitalization after surgery.²⁶

Normal gastric and small intestinal motilities were altered in the postoperative period in several ways. In dogs and horses, an experimental model of POI was produced by rubbing a segment of small bowel with a dry sponge for 5 or 10 minutes, respectively, then leaving the same segment exposed to air for 30 minutes.^{24,27,28} In dogs, this procedure abolished or greatly decreased the number and duration of activity fronts, and increased the duration of the irregular phase in the stomach and small intestine during the postoperative period.^{24,27} The motility index (derived from the magnitude of contractile forces and the duration of myoelectric complexes) was also decreased.²⁷ In horses, the number of activity fronts was decreased and the normal synchrony of gastric and oral duodenal MMCs was disrupted.²⁸ As would be expected with a decrease in myoelectric activity, transit of plastic spheres and nonabsorbable markers was also delayed during the immediate postoperative period in dogs, horses, and rats.^{24,28,29}

POI also occurs in the colon. In human patients undergoing various abdominal surgical procedures, only random, single, spike bursts were present initially.^{26,30,31} Within 3 to 4 days, long, propagated, spike bursts resembling a normal pattern returned.^{26,30,31} Mechanical activity and intraluminal pressures were decreased, and transit was delayed in the colon after various operative procedures.^{26,32} Cecal impaction and rupture have been reported in the horse after various surgical procedures, including elective orthopedic surgery.³³⁻³⁵ In those reports, the terms "ileus" and "intestinal hypomotility" were used but not defined.³³⁻³⁵ It is not known if the authors were referring to gastric reflux, absence of borborygmi, or something else. Unfortunately, like equine duodenitis-proximal jejunitis, an experimental model mimicking the natural disease is not yet available so that more detailed studies can be performed.

Most researchers agree that normal motility returns first to the stomach, then to the small intestine, and finally to the large intestine.^{26,28,30,36} Gastric and small intestinal motility returns within hours and colonic motility returns within a few days.^{26,30,36} Surprisingly, neither the length nor the type of operative procedure affected the duration of postoperative changes of motility in monkeys and human patients.^{31,32,36,37}

The pathophysiology of POI is incompletely understood at present. Depending on the anesthetic(s) used, general anesthesia alone has immediate variable effects on myoelectric activity, but there is no evidence to suggest that it significantly alters myoelectric activity of the GI tract in the postoperative period.³⁸⁻⁴⁰ Disruption of gastroduodenal coordination is thought to be the principal lesion in equine postoperative ileus by some investigators.²⁸ Sympathetic and dopaminergic hyperactivity activity are proposed to play a role, but many other factors, such as other hormonal influences and the enteric nervous system, are probably also involved.²⁸

Intestinal Resection and Anastomosis

Resection of devitalized small intestine and subsequent anastomosis is a common surgical procedure in large animal

practice, particularly in horses. The effects of simply opening the abdomen and handling the bowel during surgery were discussed in the previous section. Now the effects of interruption of the continuity of the bowel wall on motility will be discussed.

Most of the information in this area was derived from studies of myoelectric activity of animals after a simple small intestinal resection and anastomosis or the creation of Thiry-Vella loops.⁴¹⁻⁴⁷ A Thiry-Vella loop is a section of small intestine that has been transected at both ends from the bowel, but its mesenteric attachments have been preserved.⁴¹ The free ends of the isolated loop are passed through openings in the abdominal wall and sutured to the skin, forming 2 stomas, and the remaining bowel is anastomosed. Early studies of dogs and sheep suggested that propagation of MMCs was not interrupted by resection and anastomosis or Thiry-Vella loop preparation.^{41,42} The complexes were said to start in the bowel orad to the anastomosis, migrate in sequence to the Thiry-Vella loop, and then to the aboral segment. Even though only a percentage of the complexes (60% in dogs, 30% in sheep) behaved in this manner, the authors suggested that continuity of the bowel was not needed for propagation of the MMC. However, in a similar study of dogs, Bueno et al⁴³ showed that approximately two-thirds of the MMCs appear to migrate directly across one anastomotic site, and only about one-third across a second anastomotic site. They also noted that the appearance and properties of these complexes were changed. This led them to the theory that MMCs do not propagate through anastomosis sites, but instead, new complexes are formed beyond the anastomosis. Thus, continuity of the bowel (ie, continuity of the enteric nerves and/or the musculature) is essential for normal propagation of the MMC.⁴³ This theory has since been supported by other studies.^{44,45} The new MMCs arising aborad to an anastomosis occur with higher frequency, and the activity fronts of these complexes are increased in duration.^{43,45,46} Coordination of propagation starts to return as the normal healing process begins. A closer association between the coordination of the oral and aboral segments was first noticed 8 weeks postoperatively, and normal coordination was completely restored by 10 to 12 weeks.^{45,47}

The physiological relevance of interruption of the MMC after resection and anastomosis is unknown, but it does not appear to be clinically important. Without complications from strictures, animals can resume normal eating and defecating habits within 1 week, suggesting that aboral movement of ingesta is not considerably altered.

Diarrhea

The role of GI motility in the pathogenesis of diarrhea has been extensively researched. One might intuitively assume that diarrhea and an increase in propulsive motility go hand in hand. However, this is not necessarily the case. Thus, the changes that occur in the small and large intestines during diarrhea, and the effects of etiology on the pattern of motility will be discussed.

Three major myoelectric patterns of motility have been recognized in the small intestine in association with diarrhea; the migrating action potential complex (MAPC), the repeti-

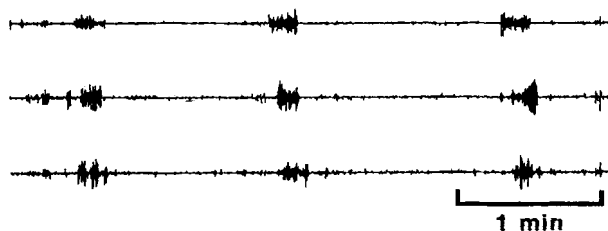


Fig 5. MAPCs propagating through 3 electrode sites, recorded from the jejunum of a calf after administration of *E coli* heat-stable enterotoxin.

tive bursts of action potentials (RBAP), and the minute rhythm. The MAPC and RBAP were first described and defined by Mathias et al, who introduced various preparations into an isolated loop of rabbit ileum.⁴⁸⁻⁵⁸ The MAPC is characterized by action potential discharges (spikes) of 2.5 seconds or longer, that migrate aborally over at least 2 consecutive electrodes, and propel fluid (Fig 5).⁴⁸ The RBAP is an action potential discharge (spike) greater than 1.5 seconds in duration that is repeated on 3 or more successive slow waves on the same recording site (Fig 6).⁴⁹ RBAPs may or may not be propagated, and are less propulsive than MAPCs.^{50,59} MAPCs are associated with noninvasive bacterial agents and their heat-labile toxins, such as *Vibrio cholerae*, *Escherichia coli* heat-labile enterotoxin, enteropathogenic *E coli*, and *Salmonella typhimurium*.^{48,51-53,60} RBAPs are associated with invasive and cytotoxic organisms and their heat-stable toxins, such as enteroinvasive *E coli*, *E coli* heat-stable enterotoxin, *Shigella dysenteriae*, and *Campylobacter jejuni*.^{48-50,54,61,62} It must be noted that these experiments were performed during anesthesia, and that the rabbit is not a natural host to all of the organisms studied.

In the rabbit ileum model, MAPCs were also recorded after gradual luminal distension of obstructed loops (but not of patent loops), exposure of the loops to castor oil and ricinoleic acid, and in the intestine orad to the ligated loop.^{49,55,63} MAPCs also occurred in human patients after laxative abuse and secretory diarrhea of unknown etiology.⁶⁴ In contrast, pigs infected with coronavirus (transmissible gastroenteritis) had decreased numbers of MAPCs, and calves exposed to *E coli* heat-stable enterotoxin PO had no change in the numbers of MAPCs.^{65,66} The definition of the

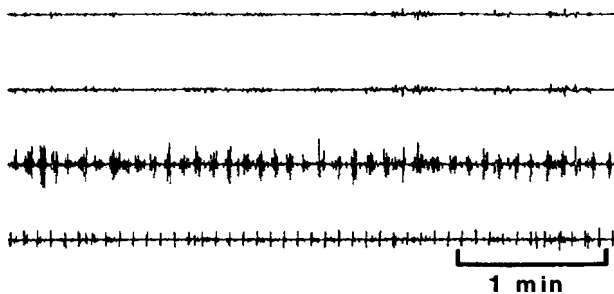


Fig 6. Intense spike activity representative of RBAPs on the third electrode site recorded from a calf infected with coronavirus.




Fig 7. Minute rhythms recorded from the jejunum of a calf after administration of *E coli* heat-stable enterotoxin.⁶⁵

MAPC (ie, propagated spikes longer than 2.5 seconds in duration) encompasses many patterns, including RBAPs and the long spike complexes described in response to obstruction. Also, although its frequency usually increases in patients with diarrheal diseases, the MAPC (also called a peristaltic rush) is a normal myoelectric pattern during the irregular phase in several species when flow of contents is greatest.⁶⁵⁻⁶⁸ Therefore, the MAPC is thought to be a nonspecific motor pattern resulting from fluid distension, although it has also been induced by subunits of the enterotoxin molecules that do not induce secretion.⁵¹

The third and most frequently recorded myoelectric pattern from the small intestine during diarrhea is the minute rhythm,^{59,69} which is characterized by propagating clusters of 3 to 10 spike bursts lasting 10 to 45 seconds, recurring at approximately 1-minute intervals, and separated by periods of quiescence (Fig 7).^{59,70} Infusion of saline into the jejunum in pigs, and of D-mannitol into the duodenum of sheep resulted in well defined minute rhythms.⁷⁰ Grain overload in sheep, administration of *E coli* heat-stable enterotoxin to calves PO, and of ricinoleic acid and magnesium sulphate in dogs, all produced minute rhythms.^{10,59,65} Minute rhythms are reported to be the most common myoelectric pattern recorded in humans with diarrhea, especially after laxative abuse.⁶⁹ Minute rhythms were also recorded in several species during normal fasting and fed states.⁷⁰ By definition, the minute rhythm also includes the clusters of discrete spikes described orad to an obstruction. Because the minute rhythm was recorded from normal animals during the irregular phase (when flow of digesta is greatest), during diarrheal states, and orad to obstructions, it is possible that this myoelectric pattern is a response to fluid distension.

The exact mechanisms leading to MAPCs, RBAPs, and minute rhythms are unclear. They may be a result of bacterial invasion or toxin production, or a reflex response to fluid distension. Prostaglandins are proposed to be involved in the pathophysiology of MAPCs, and tissue destruction is proposed to be important in the pathophysiology of RBAPs.^{52,56-58} In vitro data suggest that nitric oxide is involved in the physiology and pathophysiology of intestinal motility.⁷¹⁻⁷³ Inhibitors of nitric oxide synthesis decreased the severity of castor oil-induced diarrhea in rats,⁷⁴ so nitric oxide may also be involved in the pathophysiology of these motility patterns. Research into the cellular mechanisms of these changes is already underway, and will be one of the major focuses of future studies.

The effects of diarrhea on small intestinal mechanical activity and transit are less well studied compared to the myoelectric activity. Ring-like contractions occurred simultaneously with RBAPs, and similar contractions that propagated

rapidly were observed simultaneously with MAPCs.^{48,53} Prolonged, propagated contractions and giant migrating contractions recorded in normal dogs and after exposure to cholera toxin may be the motor correlates of the MAPC.⁷⁵⁻⁷⁷ Also, discrete clustered contractions and migrating clustered contractions recorded from the same dogs may be the motor correlates of the minute rhythm.

Lack of uniformity in the terminology used to describe colonic patterns of motility during diarrhea makes correlation of information from different studies difficult. Colonic motility was altered in human patients with irritable bowel syndrome (IBS),⁷⁸ human patients and dogs with laxative-induced (castor oil, senna extract, magnesium citrate, oleic acid) diarrhea,⁷⁸⁻⁸⁰ and human patients and dogs with ulcerative colitis.⁸¹⁻⁸³ Gross and histopathologic lesions are absent in IBS and laxative-induced diarrhea, but occur in those with ulcerative colitis.^{55,83} Despite this difference, the changes in motility are similar for both. Myoelectric activity was altered by a decrease in the frequency of SSBs and LSBs, and a decrease in the duration of total spiking activity.^{78,81} Mechanical activity was altered by an increase in the duration of colonic migrating motor complexes, and the occurrence of giant migrating contractions (GMCs).^{79,80,83} GMCs are distinct, high-amplitude contractions that rapidly migrate aborally, and are frequently followed by expulsion of feces or gas. As would be expected with the occurrence of GMCs, colonic transit is increased.^{80,82}

The pathophysiology of changes in colonic motility during diarrhea are unclear. Because the changes are similar regardless of whether morphological changes in the colon occur, it is difficult to attribute these changes to a structural change in the gut wall. As is suspected in the small intestine, prostaglandins are also proposed by some to play a role in these changes.^{84,85}

Endotoxemia

Endotoxemia is a contributing factor in the pathogenesis of many diseases, including diseases of the GI tract.³⁸ Changes in GI motility induced by endotoxin may contribute to the pathogenesis of GI diseases. In addition, the magnitude and duration of effects of endotoxin on motility, like those on clinical signs are dose-dependent.⁸⁶⁻⁸⁹ It should be noted that in the studies subsequently cited in this section, diarrhea was not induced by any of the doses of endotoxin administered.

The myoelectric and mechanical activities of the ruminant forestomach and abomasum, and of the monogastric stomach were decreased in response to IV administered endotoxin.^{86,87,90-92} Decreased frequency and amplitude of ruminal contractions at low doses, and complete inhibition of reticular and abomasal spikes at higher doses were recorded in sheep and goats.^{86,87} In the stomach of ponies and pigs, total spike activity, and the amplitude and rate of contractions were also decreased.^{87,91-92}

The effects of endotoxin on small intestinal activity were not as consistent. During myoelectric and mechanical recordings in sheep, rats, pigs, and horses, the MMC was disrupted and replaced by short periods of intense activity that resembled activity fronts, but were shorter in duration

and more frequent.⁸⁷⁻⁹² This occurred with low doses of endotoxin in horses and pigs, and relatively high doses in sheep and rats. In these studies, the authors compared these complexes with MAPCs, RBAPs, and minute rhythms, but evaluation of these comparisons cannot be made without more detailed descriptions of the complexes than those published in the texts.

The myoelectric and mechanical activities of the large intestine were evaluated in horses.^{92,93} The number of contractions of the cecum and right ventral colon, the contractile product of the left dorsal colon, and the spike rate of the small colon were decreased.^{92,93}

The IV administration of endotoxin induced alterations in GI motility very rapidly. The inhibition of reticular contractions and MMCs in sheep, and the decrease in the amplitude and rate of gastric contractions in ponies occurred within minutes of endotoxin administration^{80,84}; normal motility was reestablished within hours.^{90,92}

The pathophysiology of these changes is still being investigated. Some of the proposed mechanisms include increases in concentrations of platelet-activating factor, free radicals, and inflammatory mediators (in particular prostaglandins); interference with blood flow to the bowel; increased sympathetic innervation; a central opioid effect; or a combination of these.^{87,88,90,93} Other inflammatory mediators like nitric oxide and tumor necrosis factor are important in the systemic and GI effects of endotoxemia,⁹⁴⁻⁹⁶ and although there are no studies of intestinal motility specifically, these mediators may also play a role in the effects of endotoxin on gastrointestinal motility.

Gastrointestinal Parasitism

The pathogenic mechanisms of parasites, like bacteria, vary with the species. Despite these variations, changes in motility in different animal species with different parasites are somewhat consistent.

The myoelectric activity of the nematode-infested small intestine was studied in dogs and rats infested with *Trichinella spiralis*, dogs with hookworm infestations, horses with mixed small and large strongyle infestations, and sheep infested with *Haemonchus contortus*.⁹⁷⁻¹⁰² Similar changes were found in all cases. The cycle length of the MMC was increased, and therefore the number of MMCs per unit time was decreased in all cases, except sheep with *H. contortus*, in which the opposite occurred.⁹⁸⁻¹⁰² Various rapidly propagating, intense, spike complexes were also recorded.^{97,99,100,103} One author described these as MAPCs, but without more detailed descriptions of these complexes, it is not possible to know if these complexes are synonymous with the MAPCs described previously in this article.⁹⁹ In another study, both live and dead strongyle larvae disrupted the MMC pattern in ponies.⁶⁷

The mechanical activity of the small intestine was recorded from dogs infested with *T. spiralis*. The frequency and amplitude of contractions, and the distance of propagation of contractions were all decreased.^{98,104} An increased number of GMCs, like those described in the colon during diarrhea, were recorded in these dogs.^{98,104} It is possible that GMCs are the motor correlate of the rapidly propagating spike com-

plexes described previously. Diarrhea was a consistent finding in these animals and the decrease in numbers of GMCs to normal coincided with cessation of diarrhea.

Small intestinal transit time was increased in dogs infested with *T. spiralis*, and in rabbits infested with *Eimeria magna*.^{103,104} In rats infested with *T. spiralis*, however, the transit time was decreased.¹⁰⁵ In the case of the dogs with *T. spiralis*, this discrepancy may be due to the fact that transit time was measured only during periods when no GMCs were present.¹⁰⁴

Cecal motility was not changed in fasted ponies with mixed strongyle infestations, but cecal spike bursts were more frequent in foals infested with *Strongylus vulgaris* and in rabbits with *E. magna*.^{102,103,106} Opposing results were also found in the colon. The cranial colon showed a decrease in spike frequency in ponies, but no change in rabbits, whereas the spike frequency of the colonic pelvic flexure in foals was increased.^{102,103,106} These discrepancies could be due to species differences or differences in experimental design.

Hypocalcemia

Calcium is of vital importance to the proper functioning of smooth muscle and nervous tissue, both of which are abundant in the GI tract. Hypocalcemia, a clinical problem in postparturient dairy cattle, would therefore be expected to cause changes in GI motility. Indeed, decreased ruminal contractions and ruminal tympany often accompany clinical signs of postparturient paresis.¹⁰⁷ Hypocalcemia is also believed to be a predisposing factor in abomasal displacement in postparturient dairy cattle.^{108,109} These facts prompted the investigations¹¹⁰⁻¹¹² of the effects of hypocalcemia on ruminal and abomasal motility.

Experimentally induced hypocalcemia in sheep and cows was accompanied by changes in intestinal mechanical activity; more specifically, there was a decrease in the rate and amplitude of ruminal and abomasal contractions.¹¹⁰⁻¹¹² Two studies showed that as blood calcium concentrations decreased, ruminal and abomasal mechanical activity decreased in a positive linear relationship.^{110,111} In some instances, the mechanical activity decreased until stasis occurred (rumen of sheep, abomasum in some cows).^{110,111} However, a third study showed no linear relationship for the abomasum, but an "all or none" response, where mechanical activity remained unchanged despite decreasing calcium concentrations, until a threshold was reached and stasis occurred.¹¹² Different conclusions were reached with these experiments. In the first, Huber et al¹¹⁰ concluded that rumen stasis occurred because of a failure of neuromuscular transmission. Daniel¹¹¹ concluded that the changes in motility were caused by the generalized effects of calcium on smooth muscle contractility. Both agreed that subclinical hypocalcemia may play a role in the pathogenesis of abomasal displacement because abomasal motility is decreased before clinical signs of postparturient paresis occur. Because Madison and Trout¹¹² found that decreased abomasal motility occurred in an "all or none" response, and only at serum calcium concentrations corresponding to clinical stage 3 postparturient paresis, they disagreed and concluded that subclinical hypocalcemia is not a predisposing factor in abo-

masal displacement. Differences in experimental design, species differences, low numbers of animals, and inferences drawn from data that are not statistically significant make it difficult to draw a conclusion regarding the importance of blood calcium concentrations in motility.

Pregnancy

GI disturbances such as constipation, heartburn and nausea, are frequent complaints of pregnant women.¹¹³ In animals, the only clinically recognized GI disturbance associated with pregnancy is vagal indigestion in cattle.¹¹⁴ Studies of GI motility have not been performed in pregnant cattle, but have been performed in pregnant women and laboratory animals.¹¹⁴⁻¹¹⁹

Gastric emptying is delayed, and small intestinal and colonic transit times are increased in humans, guinea pigs, and rats, especially in late gestation.¹¹⁵⁻¹¹⁸ There is also more variation in MMC cycle length due to prolongation of some, but not all MMC cycles in rats in late gestation.¹¹⁹ Gastric emptying increased and the MMC cycle length returned to normal within a few days after parturition in guinea pigs and rats.^{116,119}

These changes are thought to be caused by hormonal changes, particularly increases in progesterone concentrations.¹¹⁸ Although vagal indigestion in late pregnancy is presumed by some to be caused by the large gravid uterus compressing the abomasum and/or the cranial small intestine, hormonal influences should not be discounted.¹¹⁴

Conclusion

As investigations continue and information accumulates, we will gradually learn more about the diseases just discussed and their effects on GI motility. However, there are other diseases, such as equine duodenitis-proximal jejunitis, postoperative cecal impaction, and enteric neuropathy (grass sickness), about which very little information is known in regard to their relationship to GI motility. As large animal practitioners, we must continue to seek knowledge about these diseases, and we must support and encourage clinical and experimental investigations into these diseases.

References

1. Roussel AJ. Intestinal Motility: A Review. *Comp Cont Educ Pract Vet* 1994;16:1433-1442.
2. Ruckebusch Y. Motor functions of the intestine. *Adv Vet Sci Comp Med* 1981;25:345-369.
3. Wingate DL. Backwards and forwards with the migrating complex. *Digest Dis Sci* 1981;26:641-666.
4. Reynolds JC, Putnam PE. Prokinetic agents. *Gastrointest Pharmacol* 1992;21:567-597.
5. Gerring EL. Effects of pharmacological agents on gastrointestinal motility. *Vet Clin N Am Equine Pract* 1989;5:283-294.
6. Sarna SK. Gastrointestinal electrical activity: Terminology. *Gastroenterology* 1975;68:1631-1635.
7. Sarna SK, Otterson MF. Gastrointestinal motility: Some basic concepts. *Pharmacology* 1988;36:7-14(suppl 1).
8. Merritt AM, Ruckebusch Y. Milk feeding and xylazine treatment induce increased antroduodenal motility in young cattle with opposite effects on duodenal digesta flow rate. *Dig Dis Sci* 1988;33:60-66.

9. Vantrappen G. The migrating myoelectric complex. In: Weinbeck M, ed. *Motility of the Digestive Tract*. New York, NY: Raven; 1982:157-167.
10. Bueno L, Ruckebusch Y. Migrating myoelectrical complexes: disruption, enhancement and disorganization. In: Duthie HL, ed. *Gastrointestinal Motility in Health and Disease*. Baltimore, MD: University Park Press; 1978:83-91.
11. Bueno L, Fioramonti J, Ruckebusch Y. Rate of flow of digesta and electrical activity of the small intestine in dogs and sheep. *J Physiol* 1975;249:69-85.
12. Ruckebusch Y, Fioramonti J. Colonic myoelectrical spiking activity: Major patterns and significance in six different species. *Zentralbl Veterinarmed A* 1980;27:1-8.
13. Coffman JR. Diarrheal diseases and obstructive bowel diseases of horses. *Proc Am Coll Vet Intern Med* 1983;1:61-65.
14. Phaneuf LP, Grivel ML, Ruckebusch Y. Electromyography during normal gastrointestinal activity, or painful or non-painful colic and morphine analgesia, in the horse. *Can J Comp Med* 1972;36:138-144.
15. MacHarg MA, Adams SB, Lamar CH, et al. Electromyographic, myomechanical, and intraluminal pressure changes associated with acute extraluminal obstruction of the jejunum in conscious ponies. *Am J Vet Res* 1986;47:7-11.
16. King JN, Gerring EL. Observations on the colic motor complex in a pony with a small intestinal obstruction. *Equine Vet J* 1989;7:43-45.
17. Lowe JE, Sellers AF, Brondum J. Equine pelvic flexure impaction a model used to evaluate motor events and compare drug response. *Cornell Vet* 1980;70:401-412.
18. Rutgers LJE, Kuiper R, Van Der Velden MA. Effects of experimental duodenal occlusion on electrical activity of the proximal duodenum in cattle. *Res Vet Sci* 1988;45:186-193.
19. Ruckebusch Y, Bueno L. Electrical activity of the ovine jejunum and changes due to disturbances. *Dig Dis* 1975;20:1027-1034.
20. Summers RW, Yanda R, Prihoda M, et al. Acute intestinal obstruction: An electromyographic study in dogs. *Gastroenterology* 1983;85:1301-1306.
21. Prihoda M, Flatt A, Summers RW. Mechanisms of motility changes during acute intestinal obstruction in the dog. *Am J Physiol* 1984;247:G37-G42.
22. Enochsson L, Hellstrom PM, Nylander G, et al. Myoelectric motility patterns during mechanical obstruction and paralysis of the small intestine in the rat. *Scand J Gastroenterol* 1987;22:969-974.
23. Summers RW, Anuras S, Green J. Jejunal manometry patterns in health, partial intestinal obstruction, and pseudoobstruction. *Gastroenterology* 1983;85:1290-1300.
24. Hunt JM, Edwards GB, Clarke KW. Incidence, diagnosis and treatment of postoperative complications in colic cases. *Equine Vet J* 1986;18:264-270.
25. Woods JH, Erickson LW, Condon RE, et al. Postoperative ileus: A colonic problem? *Vet Surg* 1978;84:527-533.
26. Smith J, Kelly KA, Weinshilboun RM. Pathophysiology of postoperative ileus. *Arch Surg* 1977;112:203-209.
27. Graves GM, Becht JL, Rawlings CA. Metoclopramide reversal of decreased gastrointestinal myoelectric and contractile activity in a model of canine postoperative ileus. *Vet Surg* 1989;18:27-33.
28. Gerring EL, Hunt JM. Pathophysiology of equine postoperative ileus: Effect of adrenergic blockade, parasympathetic stimulation and metoclopramide in an experimental model. *Equine Vet J* 1986;18:249-255.
29. Dubois A, Weise VK, Kopin IJ. Postoperative ileus in the rat: physiopathology, etiology and treatment. *Ann Surg* 1972;178:781-786.
30. Waldhausen JHT, Shaffrey ME, Skenderis BS, et al. Gastrointestinal myoelectric and clinical patterns of recovery after laparotomy. *Ann Surg* 1990;211:777-785.
31. Condon RE, Frantzides CT, Cowles VE, et al. Resolution of postoperative ileus in humans. *Ann Surg* 1986;203:574-581.
32. Wilson JP. Postoperative motility of the large intestine in man. *Gut* 1975;16:689-692.
33. Adams SB, Sojka JK, Robertson-Smith G. Effects of selected drugs on intestinal motility in the horse. *Proc Equine Colic Symp* 1986;2:84-88.
34. Campbell ML, Colahan PC, Brown MP, et al. Cecal impaction in the horse. *J Am Vet Med Assoc* 1984;184:950-952.
35. Ross MW, Tate LP, Donawick WJ, et al. Cecocolic anastomosis for the surgical management of cecal impaction in horses. *Vet Surg* 1986;15:85-92.
36. Graber JN, Schulte WJ, Condon RE, et al. Duration of postoperative ileus related to extent and site of operative dissection. *Surg Forum* 1980;31:141-144.
37. Catchpole BN, Duthie HL. Postoperative gastrointestinal complexes. In: Duthie HL, ed. *Gastrointestinal Motility in Health and Disease*. Baltimore, MD: University Park Press; 1977:33-41.
38. Lester GD, Bolton JR, Cullen LK, et al. Effects of general anesthesia on myoelectric activity of the intestine in horses. *Am J Vet Res* 1992;53:1553-1557.
39. Henry MM, Moore JN. Equine endotoxemia. In: Smith BP, ed. *Large Animal Internal Medicine*. St. Louis, MO: Mosby; 1990:668-674.
40. Healey TEJ, Foster GE, Evans DF, et al. Effect of some IV anaesthetic agents on canine gastrointestinal motility. *Br J Anaesth* 1981;53:229-233.
41. Carlson GM, Bedi BS, Code CF. Mechanism of propagation of intestinal interdigestive myoelectric complex. *Am J Physiol* 1972;222:1027-1030.
42. Grivel ML, Ruckebusch Y. The propagation of segmental contractions along the small intestine. *J Physiol* 1972;277:611-625.
43. Bueno L, Pradaude F, Ruckebusch Y. Propagation of electrical spiking activity along the small intestine: Intrinsic versus extrinsic neural influences. *J Physiol* 1979;292:15-26.
44. Ormsbee HS, Telford GL, Mason GR. Mechanism of propagation of canine migrating motor complex—a reappraisal. *Gastroenterology* 1972;76:1212 (abstr).
45. Pearce EAN, Wingate DL. Myoelectric and absorptive activity in the transected canine small bowel. *J Physiol* 1980;302:11P-12P.
46. Papisova M, Atanassova E. Adaptation to surgical perturbations. In: Schultz SG, Wood JD, Rauner BB, eds. *Handbook of Physiology*. Bethesda, MD: American Physiological Society; 1989:1199-1224.
47. Grivel ML, Ruckebusch Y. A study in the dog and cat of the electrical activity of the small intestine some months after transection and transplantation of the gut. *Life Sci* 1971;10:241-250.
48. Mathias JR, Carlson GM, DiMarino AJ, et al. Intestinal myoelectric activity in response live *Vibrio cholerae* and cholera enterotoxin. *J Clin Invest* 1976;58:91-96.
49. Burns TW, Mathias JR, Martin JL, et al. Alteration of myoelectric activity of small intestine by invasive *Escherichia coli*. *Am J Physiol* 1980;238:G57-G62.
50. Justus PG, Martin JL, Goldberg DA, et al. Myoelectrical effects of *Clostridium difficile*: Motility-altering factors distinct from its cytotoxin and enterotoxin in rabbits. *Gastroenterology* 1982;83:836-843.
51. Sinar DR, Charles LG, Burns TW. Migrating action-potential complex activity in absence of fluid production is produced by B subunit of cholera enterotoxin. *Am J Physiol* 1982;242:G47-G51.
52. Mathias JR, Carlson GM, Bertiger G, et al. Migrating action

potential complex of cholera: A possible prostaglandin-induced response. *Am J Physiol* 1977;232:E529–E534.

53. Weisberg PB, Carlson GM, Cohen S. Effect of *Salmonella typhimurium* on myoelectrical activity in the rabbit ileum. *Gastroenterology* 1978;74:47–51.

54. Mathias JR, Nogueira JL, Martin JL, et al. *Escherichia coli* heat-stable toxin: Its effect on motility of the small intestine. *Am J Physiol* 1982;242:G360–G363.

55. Mathias JR, Martin JL, Burns TW. Ricinoleic acid effect on the electrical activity of the small intestine in rabbits. *J Clin Invest* 1978;61:640–644.

56. Justus PG, Mathias JR, Carlson GM, et al. The myoelectrical activity of the small intestine in response to *Clostridium perfringens* A enterotoxin and *Clostridium difficile* culture filtrate. In: Christensen J, ed. *Gastrointestinal Motility*. New York, NY: Raven; 1980:379–386.

57. Justus PG, Mathias JR, Martin JL, et al. Myoelectrical activity in the small intestine in response to *Clostridium perfringens* A enterotoxin: Correlation with histologic findings in an in vivo rabbit model. *Gastroenterology* 1981;80:902–906.

58. Mathias JR, Carlson GM, Martin JL, et al. *Shigella dysenteriae* I enterotoxin: Proposed role in pathogenesis of shigellosis. *Am J Physiol* 1980;239:G382–G386.

59. Read NW. Speculations on the role of motility in the pathogenesis and treatment of diarrhea. *Scand J Gastroenterol* 1983;87:45–63 (suppl).

60. Sjogren RW, Sherman PM, Boedeker EC. Altered intestinal motility precedes diarrhea during *Escherichia coli* enteric infection. *Am J Physiol* 1989;257:G725–G731.

61. Fernandez A, Sninsky CA, O'Brien AD, et al. Purified *Shigella* enterotoxin does not alter intestinal motility. *Infect Immunol* 1984;43:477–481.

62. Sninsky CA, Ramphal R, Gaskins DJ, et al. Alteration of myoelectrical activity associated with *Campylobacter jejuni* and cell-free filtrate in the small intestine of rabbits. *Gastroenterology* 1985;89:337–344.

63. Sjogren RW, Wardlow M, Charles LG. Stimulation of action potential complexes by fluid distension of rabbit small intestine—Evidence that migrating action potential complexes are a non-specific myoelectrical response. In: Roman C, ed. *Gastrointestinal Motility*. Boston, MA: MTP Press; 1983:311–318.

64. Coremans G, Janssens J, Vantrappen G, et al. Migrating action potential complexes in a patient with secretory diarrhea. *Dig Dis Sci* 1987;32:1201–1206.

65. Roussel AJ, Woode GN, Waldron RC, et al. Myoelectrical activity of the small intestine in enterotoxin-induced diarrhea of calves. *Am J Vet Res* 1992;53:1145–1148.

66. Burrows CF, Merritt AM. Influence of coronavirus (transmissible gastroenteritis) infection on jejunal myoelectrical activity of the neonatal pig. *Gastroenterology* 1984;87:386–391.

67. Berry CR, Merritt AM, Burrows CF, et al. Evaluation of the myoelectrical activity of the equine ileum infected with *Strongylus vulgaris* larvae. *Am J Vet Res* 1986;47:27–30.

68. Fleckenstein P, Krough F, Oigaard A. The interdigestive myoelectrical complex and other migrating electrical phenomena in the human small intestine. In: Duthie HL, ed. *Gastrointestinal Motility in Health and Disease*. Baltimore, MD: University Park Press; 1978:19–28.

69. Bueno L, Frexinos J, Fioramonti J. Role of motility in pathogenesis of constipation and diarrhea. *Pharmacology* 1988;36:15–22(suppl 1).

70. Fleckenstein P, Bueno L, Fioramonti J, et al. Minute rhythm of electrical spike bursts of the small intestine in different species. *Am J Physiol* 1982;242:G654–G659.

71. Daniel EE, Woskowska CHZ, Cipris S, et al. Role of nitric oxide-related inhibition in intestinal function: Relation to vasoactive intestinal polypeptide. *Am J Physiol* 1994;266:G31–G39.

72. Burleigh DE. N⁶-nitro-L-arginine reduces nonadrenergic, noncholinergic relaxations of human gut. *Gastroenterology* 1992;102:679–683.

73. Mearin F, Mourelle M, Guarner F, et al. Patients with achalasia lack nitric oxide synthase in the gastroesophageal junction. *Eur J Clin Invest* 1993;23:724–728.

74. Mascolo N, Izzo AA, Autore G, et al. Nitric oxide and castor oil-induced diarrhea. *J Pharm Exper Ther* 1994;268:291–295.

75. Quigley EMM, Phillips SF, Dent J. Distinctive patterns of interdigestive motility at the canine ileocolonic junction. *Gastroenterology* 1984;87:836–844.

76. Kruis W, Azpiroz F, Phillips SF. Contractile patterns and transit of fluid in canine terminal ileum. *Am J Physiol* 1985;249:G264–G270.

77. Cowles VE, Sarna SK. Effect of cholera toxin on small intestinal motor activity in the fed state. *Dig Dis Sci* 1990;35:353–359.

78. Bueno L, Fioramonti J, Frexinos J, et al. Colonic myoelectrical activity in diarrhea and constipation. *Hepatogastroenterology* 1980;27:381–389.

79. Karaus M, Sarna SK, Ammon HV, et al. Effects of oral laxatives on colonic motor complexes in dogs. *Gut* 1987;28:1112–1119.

80. Spiller RC, Brown ML, Phillips SF. Decreased fluid tolerance, accelerated transit, and abnormal motility of the human colon induced by oleic acid. *Gastroenterology* 1986;91:100–107.

81. Snape WJ, Matarazzo SA, Cohen S. Abnormal gastrocolonic response in patients with ulcerative colitis. *Gut* 1980;21:392–396.

82. Rao SSC, Read NW. Gastrointestinal motility in patients with ulcerative colitis. *Scand J Gastroenterol* 1990;25:22–28(suppl 172).

83. Sethi AK, Sarna SK. Colonic motor activity in acute colitis in conscious dogs. *Gastroenterology* 1991;100:954–963.

84. Sarna SK. Physiology and pathophysiology of colonic motor activity: Part two of two. *Dig Dis Sci* 1991;36:998–1018.

85. Burakoff R, Nastos E, Won S. Effects of PGF₂α and of indomethacin on rabbit small and large intestinal motility in vivo. *Am J Physiol* 1990;258:G231–G237.

86. Van Miert ASJPAM, Van Duin CTM. The effect of flurbiprofen upon fever and ruminal stasis induced by *Escherichia coli* endotoxin, poly I: Poly C and sodium nucleinate from yeast in conscious goats. *J Vet Pharm Ther* 1979;2:69–79.

87. De Saedeleer V, Wechsung E, Houvenhaghe A. Endotoxin in the conscious piglet: Its effects on some general and gastrointestinal myoelectrical parameters. *Vet Res Commun* 1991;15:227–238.

88. Pons L, Droy-Lefaix MT, Braquet P, et al. Role of free radicals and platelet-activating factor in the genesis of intestinal motor disturbances induced by *Escherichia coli* endotoxins in rats. *Gastroenterology* 1991;100:946–953.

89. Pons L, Droy-Lefaix MT, Braquet P, et al. Involvement of platelet-activating factor (PAF) in endotoxin-induced intestinal motor disturbances in rats. *Life Sci* 1989;45:533–541.

90. Durantou A, Bueno L. Central opiate mechanism involved in gastro-intestinal motor disturbance induced by *E. coli* endotoxin in sheep. *Life Sci* 1984;34:1795–1799.

91. King JN, Gerring EL. Antagonism of endotoxin-induced disruption of equine gastrointestinal motility with the platelet-activating factor antagonist WEB 2086. *J Vet Pharmacol Ther* 1990;13:333–339.

92. King JN, Gerring EL. The action of low dose endotoxin on equine bowel motility. *Equine Vet J* 1991;23:11–17.

93. Eades SC, Moore JN. Blockade of endotoxin-induced cecal hypoperfusion and ileus with an α₂ antagonist in horses. *Am J Vet Res* 1993;54:586–590.

94. Wright CE, Rees DD, Moncada S. Protective and pathological roles nitric oxide in endotoxin shock. *Cardiovasc Res* 1992;26:48–57.
95. Tracey KJ, Reutler B, Lowry SF, et al. Shock and tissue injury induced by recombinant human cachectin. *Science* 1986;234:470–474.
96. Sun XM, Hsueh W. Bowel necrosis induced by tumor necrosis factor in rats is mediated by platelet-activating factor. *J Clin Invest* 1988;81:1328–1331.
97. Schanbacher LM, Nations JK, Weisbrodt NW, et al. Intestinal myoelectric activity in parasitized dogs. *Am J Physiol* 1978;234:R188–R195.
98. Cowles VE, Sarna SK. Effect of *T. spiralis* infection on intestinal motor activity in the fasted state. *Am J Physiol* 1990;259:G693–G701.
99. Palmer JM, Weisbrodt NW, Castro GA. *Trichinella spiralis*: Intestinal myoelectric activity during enteric infection in the rat. *Exp Parasitol* 1984;57:132–141.
100. Weisbrodt NW, Castro GA. Intestinal myoelectric activity of the dog during hookworm infection. *Federation Proc* 1977;36:595(abstr).
101. Bueno L, Dakkak A, Fioramonti J. Gastro-duodenal motor and transit disturbances associated with *Haemonchus contortus* infection in sheep. *Parasitology* 1982;84:367–374.
102. Bueno L, Ruckebusch Y, Dorchies P. Disturbances of digestive motility in horses associated with strongyle infection. *Vet Parasitol* 1979;5:253–260.
103. Fioramonti J, Sorraing JM, Licois D, et al. Intestinal motor and transit disturbances associated with experimental coccidiosis (*Eimeria magna*) in the rabbit. *Ann Rech Vet* 1981;12:413–420.
104. Cowles VE, Sarna SK. *Trichinella spiralis* infection alters small bowel activity in the fed state. *Gastroenterology* 1991;101:664–669.
105. Castro GA, Badial-Aceves F, Smith JW, et al. Altered small bowel propulsion associated with parasitism. *Gastroenterology* 1976;71:620–625.
106. Lester GD, Bolton JR, Cambridge H, et al. The effect of *Strongylus vulgaris* larvae on equine intestinal myoelectrical activity. *Equine Vet J* 1989;7:8–13(suppl).
107. Yates DJ, Hunt E. Disorders of calcium metabolism. In: Smith BP, ed. *Large Animal Internal Medicine*. St Louis, MO: Mosby; 1990:1315–1322.
108. Hull BL, Wass WM. Abomasal displacement–2: Hypocalcemia as a contributing causative factor. *Vet Med Small Anim Clin* 1973;68:412–417.
109. Massey CD, Wang C, Donovan GA, Beede DK. Hypocalcemia at parturition as a risk factor for left displacement of the abomasum in dairy cows. *J Am Vet Med Assoc* 1993;203:852–853.
110. Huber TL, Wilson RC, Stattelmann AJ, et al. Effect of hypocalcemia on motility of the ruminant stomach. *Am J Vet Res* 1981;42:1488–1490.
111. Daniel RCW. Motility of the rumen and abomasum during hypocalcaemia. *Can J Comp Med* 1983;47:276–280.
112. Madison JB, Trout HF. Effects of hypocalcaemia on abomasal motility. *Res Vet Sci* 1988;44:264–266.
113. Biggs JSG, Vesey EJ. Treatment of gastrointestinal disorders of pregnancy. *Drugs* 1980;19:70–76.
114. Garry FB. Indigestion in ruminants. In: Smith BP, ed. *Large Animal Internal Medicine*. St. Louis, MO: Mosby; 1990:747–782.
115. Lawson M, Kern F, Everson GT. Gastrointestinal transit time in human pregnancy: Prolongation in the second and third trimesters followed by postpartum normalization. *Gastroenterology* 1985;89:996–999.
116. Ryan JP, Bhojwani A, Wang MB. Effect of pregnancy on gastric motility in vivo and in vitro in the guinea pig. *Gastroenterology* 1987;93:29–34.
117. Ryan JP. Effect of pregnancy on intestinal transit: Comparison of results using radioactive and non-radioactive test meals. *Life Sci* 1982;31:2635–2640.
118. Ryan JP, Bhojwani A. Colonic transit in rats: Effect of ovariectomy, sex steroid hormones, and pregnancy. *Am J Physiol* 1986;251:G46–46(abstr).
119. Scott LD, Lester R, Van Thiel DH, et al. Pregnancy-related changes in small intestinal myoelectrical activity in the rat. *Gastroenterology* 1983;84:301–305.