

## OPEN

# Evaluation of the Safety and Efficacy of a Low-Temperature Plasma Surgical System for Pterygium

Haixiang Huang, MD,\* Saiqun Li, MD, PhD,\* Jing Zhong, MD, PhD,\* Bowen Wang, MD,\* Lulu Peng, MD,\* Yuqing Deng, MD,\* Mingwu Wang, MD, PhD,† and Jin Yuan, MD, PhD\*

**Purpose:** Surgical excision is the standard treatment for pterygium. This study was conducted to evaluate the safety and efficacy of a novel technique using low-temperature plasma (LTP) for excision and hemostasis in pterygium surgery.

**Methods:** A prospective, comparative, and randomized clinical trial was conducted on 60 patients (60 eyes) undergoing pterygium excision with conjunctival autografts using fibrin glue. Patients were equally divided into the following 2 groups: a control group and a LTP group. Postoperative follow-up visits were scheduled on day 1, week 1, and months 1 and 3, and recurrence was evaluated at 1 year. Patients were examined for operative time, best corrected visual acuity, conjunctival autograft inflammation (CAI), graft stability (GS), pain, recurrence, and final appearance. Factors related to pterygium recurrence and final appearance were analyzed.

**Results:** Mean operative times were shorter in the LTP group ( $16.7 \pm 3.4$  min) than those in the control group ( $20.1 \pm 4.7$  min,  $P = 0.002$ ). LTP eyes had milder CAI than control eyes at postoperative day 1 ( $P = 0.000$ ) and week 1 ( $P = 0.000$ ). Patients in the LTP group exhibited better GS ( $P = 0.01$ ) and milder pain ( $P = 0.04$ ) than those in the control group on day 1. Two control patients (6.7%) and no (0%) LTP patients experienced recurrence ( $P = 0.08$ ). GS and CAI were the significant factors contributing to recurrence (GS:  $R = 0.425$ ,  $P = 0.001$ ; CAI:  $R = 0.309$ ,  $P = 0.016$ ).

**Conclusions:** LTP to replace surgical blades and disposable cautery for ablation and hemostasis is safe and efficient for pterygium surgery, resulting in shorter operative time, milder inflammation, and better graft stability without increasing complication risk.

**Key Words:** pterygium, low-temperature plasma, graft stability, recurrence

(*Cornea* 2020;39:1581–1587)

Pterygium is a common degenerative and proliferative external eye disease characterized by excessive fibrovascular growth arising from the conjunctiva and extending into the cornea. Surgical excision is the standard treatment, and many techniques, including beta-irradiation, mitomycin-C, amniotic membrane transplantation, conjunctival autografts (CAGs), and limbal-conjunctival autografting, have been developed to improve the surgical outcomes.<sup>1,2</sup> In recent years, the use of fibrin tissue adhesives or autologous serum to facilitate graft attachment has been shown to shorten the operating time, reduce patients' postoperative discomfort, and avoid suture-related problems.<sup>3,4</sup> Traditionally, electrocautery pens or disposable cautery are the most frequently used devices for hemostasis in pterygium surgery. However, cautery generates a direct current to heat a wire loop at the end of the device up to 350°C to 400°C, leading to acute tissue damage<sup>5</sup> and wound ischemia<sup>6</sup> and even delayed wound healing and inflammatory reactions.<sup>7</sup> Possibly because of the excessive burn damage and related inflammation, these adjunctive devices may be associated with complications such as conjunctival granulomas, scleral dissolution, anterior segment ischemia, and even higher recurrence rates.<sup>5–7</sup>

Recently, low-temperature plasma (LTP) has been distinguished as a new energy device used in surgeries.<sup>8–10</sup> LTP is composed of a variety of active particles (electrons, photons, and positive ionization). It is generated at a relatively low temperature (<40°C) to avoid thermal effects on living structures.<sup>11</sup> LTP has been used for a variety of applications, such as wound healing<sup>12</sup> and anticancer therapy.<sup>10</sup> Moreover, LTP has several advantages when it is applied in surgeries, including clear visualization of the surgical field, thorough removal of tissue, minimal bleeding, and less postoperative inflammation.<sup>9,13</sup> Plasma energy ablates the bonds of biological macromolecules, breaking them into small molecular fragments. Therefore, LTP can function as an excimer laser for cutting tissues.<sup>14</sup> An LTP blade, also known as the Fugo blade, has been approved by the Food and Drug Administration for cataract<sup>15</sup> and glaucoma surgery.<sup>16</sup> Moreover, the Fugo blade has been shown to safely and quickly create resistance-free cuts in corneal tissues.<sup>17</sup> Another well-established application of LTP is for hemostasis in surgery.

Received for publication March 13, 2020; revision received June 20, 2020; accepted June 23, 2020. Published online ahead of print August 26, 2020. From the \*State Key Laboratory of Ophthalmology, Zhongshan Ophthalmic Center, Sun Yat-Sen University, Guangzhou, China; and †Department of Ophthalmology, University of Arizona College of Medicine, Tucson, AZ. Supported by Grants from the Natural Science Foundation of China (81870633 and 81670826).

The authors have no conflicts of interest to disclose.

H. Huang and S. Li contributed equally to this study.

Correspondence: Jin Yuan, MD, PhD, State Key Laboratory of Ophthalmology, Zhongshan Ophthalmic Center, Zhongshan School of Medicine, Sun Yat-sen University, 54S Xian Lie Rd, Guangzhou 510060, China (e-mail: yuanjin@cornea@126.com).

Copyright © 2020 The Author(s). Published by Wolters Kluwer Health, Inc. This is an open-access article distributed under the terms of the Creative Commons Attribution-Non Commercial-No Derivatives License 4.0 (CCBY-NC-ND), where it is permissible to download and share the work, provided it is properly cited. The work cannot be changed in any way or used commercially without permission from the journal.

The LTP stops blood flow by forming blood clots because of the coagulation of platelets and clotting proteins, as well as other serum proteins, such as albumin, fetuin, and immunoglobulin. This procedure is very gentle and does not lead to thermal injury at the wound site.<sup>12</sup> Here, we describe our attempt to use LTP for pterygium excision and hemostasis and compare it with conventional surgical modalities, such as blades and disposable cautery, for safety and efficacy.

## MATERIALS AND METHODS

### Study Design and Participants

This was a prospective, randomized, and control study conducted at the Zhongshan Ophthalmic Center, Sun Yat-sen University. Sixty patients (male and female patients) aged 30 to 70 years were included in the study. Patients who underwent primary nasal pterygium excision combined with sutureless CAGs were recruited between September 2016 and March 2018. Patients with systemic or ocular immune-related disease, narrow occludable angles, ocular hypertension, physiologic or glaucomatous optic disc cupping, family history of glaucoma, history of an earlier ocular surgery or trauma, pseudopterygium, or recurrent pterygium were excluded from the study. The study adhered to the tenets of the Declaration of Helsinki and the Association for Research in Vision and the Ophthalmology statement on human subjects and was approved by the hospital ethics committee and registered at ClinicalTrials.gov (ID: NCT03204084). Informed consent was obtained from all subjects.

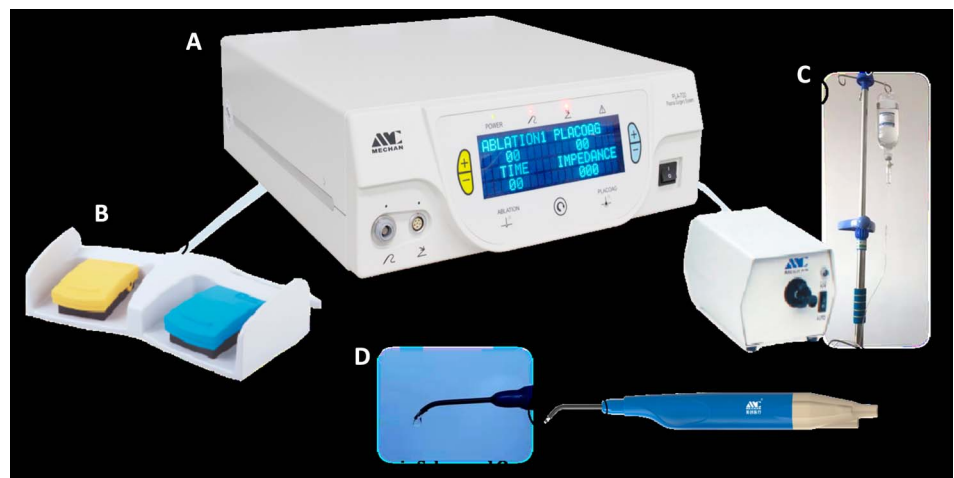### Surgical Technique

All surgeries were performed by a single experienced surgeon (J.Y.). In the control group, a surgical blade was used for pterygium excision and wound polishing. Disposable cautery (BDD-YD-1; Cbd Shunye Medical Co, Ltd power: 1.5 V, China) was used to achieve hemostasis. In the LTP group, an LTP surgical system (PLA-700; Chengdu Mechan Electronic Technology Co, Ltd, China) (Fig. 1) was used for ablation, hemostasis, and polishing the corneal stromal

surface. According to the manufacturer's instructions, 2 different device modules were used for ablation and hemostasis, respectively. To ensure that the LTP head temperature was stable at 40°C, it was operated underwater with an internal saline cooling system. In both groups, the free conjunctival autograft was harvested following the standard technique described previously.<sup>18</sup> Grafts were attached onto the bare sclera using a fibrin tissue adhesive [Fibrin Sealant (Human); FIBINGLUEAAS Shanghai RAAS Blood Products Co, Ltd, China]. Bandage contact lenses were placed in all eyes, and a pressure patch was applied for 24 hours. Topical 0.3% tobramycin/0.1% dexamethasone ophthalmic solution (S.A. Alcon Couvreur N.V. Belgium) was applied 4 times daily for 2 weeks after the surgery. In addition, 0.3% sodium hyaluronate (Cravit; Santen, Osaka, Japan) and pranoprofen (Senju Pharmaceutical Ltd, Osaka, Japan) were prescribed 4 times daily for 3 months.

### Main Outcome Measures

Patients were followed on postoperative day 1, week 1, and months 1 and 3, and recurrence was evaluated at 1 year postoperatively. All patients underwent complete ophthalmic examinations, including best corrected visual acuity (BCVA and LogMAR) measurement, noncontact tonometry for intraocular pressure (IOP), and a slit-lamp examination. Pterygium was graded according to its relative translucency (T1, atrophic; T2, intermediate; and T3, fleshy)<sup>19</sup> and the position of the advancing edge of pterygium regarding the corneal diameter (G1, one-third of the corneal diameter; G2, between one-third of the corneal diameter and the pupil; and G3, within the pupillary area).<sup>20</sup> Operative time was measured starting from the placement of the lid retractors to the removal at the end of surgery. Slit-lamp examination was performed to observe the scleral defects. Conjunctival autograft inflammation (CAI) was used to represent the conjunctival inflammation of the surgical wound. CAI and graft stability (GS) were evaluated and graded using the grading system developed by Srinivasan et al.<sup>21</sup> The scoring scale of CAI was based on the number of bright red, dilated corkscrew vessels crossing the graft-bed margin: grade 0,



**FIGURE 1.** PLA-700 plasma surgery system. A, The main body of the PLA-700 plasma surgery system. B, Two functional pedals for ablation and platelet coagulation. C, The saline circulation system for maintaining the low temperature of plasma. D, LTP scalpel inside a pen-like device and the handpiece in submerged operation. (The full color version of this figure is available at [www.corneajrnl.com](http://www.corneajrnl.com).)

**TABLE 1.** Patient Demographics

Parameter	LTP Group (30 Eyes)	Control Group (30 Eyes)	P
Age (yrs), mean ± SD	59.5 ± 9.4	57.9 ± 9.9	0.51
PA (mm <sup>2</sup> ), mean ± SD	7.4 ± 3.7	7.6 ± 4.2	0.88
Sex, male/female	8/22	11/19	0.09
Eye laterality, right/left	18/12	13/17	0.25
Pterygium grade G (%)			0.75
G1	6 (20)	8 (26.7)	
G2	11 (36.7)	10 (33.3)	
G3	13 (43.3)	12 (40)	
Pterygium grade T (%)			0.76
T1	4 (13.4)	1 (3.3)	
T2	13 (43.3)	20 (66.7)	
T3	13 (43.3)	9 (30)	

G1, one-third of the corneal diameter; G2, between one-third of the corneal diameter and the pupil; G3, within the pupillary area; T1, atrophy; T2, intermediate; T3, fleshy.

none; grade 1, 1 vessel; grade 2, 2 vessels; grade 3, 3 vessels; and grade 4, >3 vessels. The scoring scale of GS was based on the number of sides displaying gaping/displacement in the graft-bed junction: grade 0, none; grade 1, 1 side; grade 2, 2 sides; grade 3, 3 sides; and grade 4, completely displaced. Postoperative pain was scored on a 10-point scale where one end represents no pain and 10 represents the most severe pain the patient has ever experienced,<sup>22</sup> which was recorded at each visit using the visual analog scale (VAS). The final appearance (FA) was graded according to the following system used by Prabhasawat et al<sup>23</sup>: grade 1, normal appearance; grade 2, some fine episcleral vessels in the excised area extending up to but not beyond the limbus and without any fibrous tissue; grade 3, additional fibrous tissues in the excised area that did not invade the cornea; and grade 4, true recurrence with fibrovascular tissue invading the cornea. The measures, including pterygium severity, postoperative inflammation, GS, complications, FA, and pain, were evaluated and graded by an independent investigator without the knowledge of which surgical tools were used.

### Statistical Analysis

The statistical analysis was conducted using SPSS software version 23.0 (SPSS Inc, Chicago, IL). The Mann-Whitney *U* test, Student *t* test, paired *t* test, and ANOVA test were used to compare qualitative and continuous quantitative variables between the 2 groups. Pearson correlation analysis was used for correlation analysis of the parameters. *P* values of 0.05 or less were considered statistically significant.

## RESULTS

### Patient Demographics

The demographics and clinical characteristics of the study population are summarized in Table 1. There were no significant differences in age, sex, eye laterality, and IOP between the 2 groups (*P* > 0.05). In addition, the differences

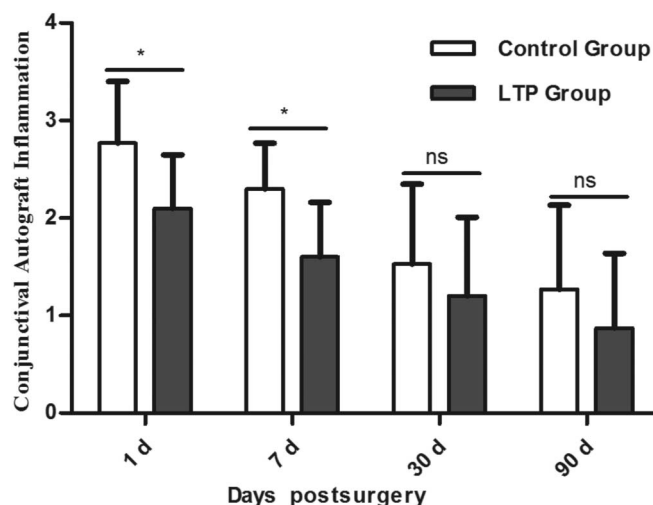
regarding pterygium area (PA, LTP, 7.4 ± 3.7 mm<sup>2</sup>, control, 7.6 ± 4.2 mm<sup>2</sup>, *P* = 0.88) and grade were not significant. Before surgery, the mean BCVA was 0.42 ± 0.24 LogMAR in the LTP group and 0.41 ± 0.25 LogMAR in the control group. It then increased to 0.21 ± 0.12 LogMAR (*P* = 0.002) and 0.24 ± 0.16 LogMAR (*P* = 0.001) at postoperative 3 months, respectively. No significant differences in preoperative (*P* = 0.83) and postoperative (*P* = 0.15) BCVA were found between the 2 groups, and there was also no difference in improvement between the 2 groups. The operative time in the LTP group was 16.7 ± 3.4 minutes, which was significantly shorter than that in the control group, which was 20.1 ± 4.7 minutes (*P* = 0.002).

### Postoperative Inflammation

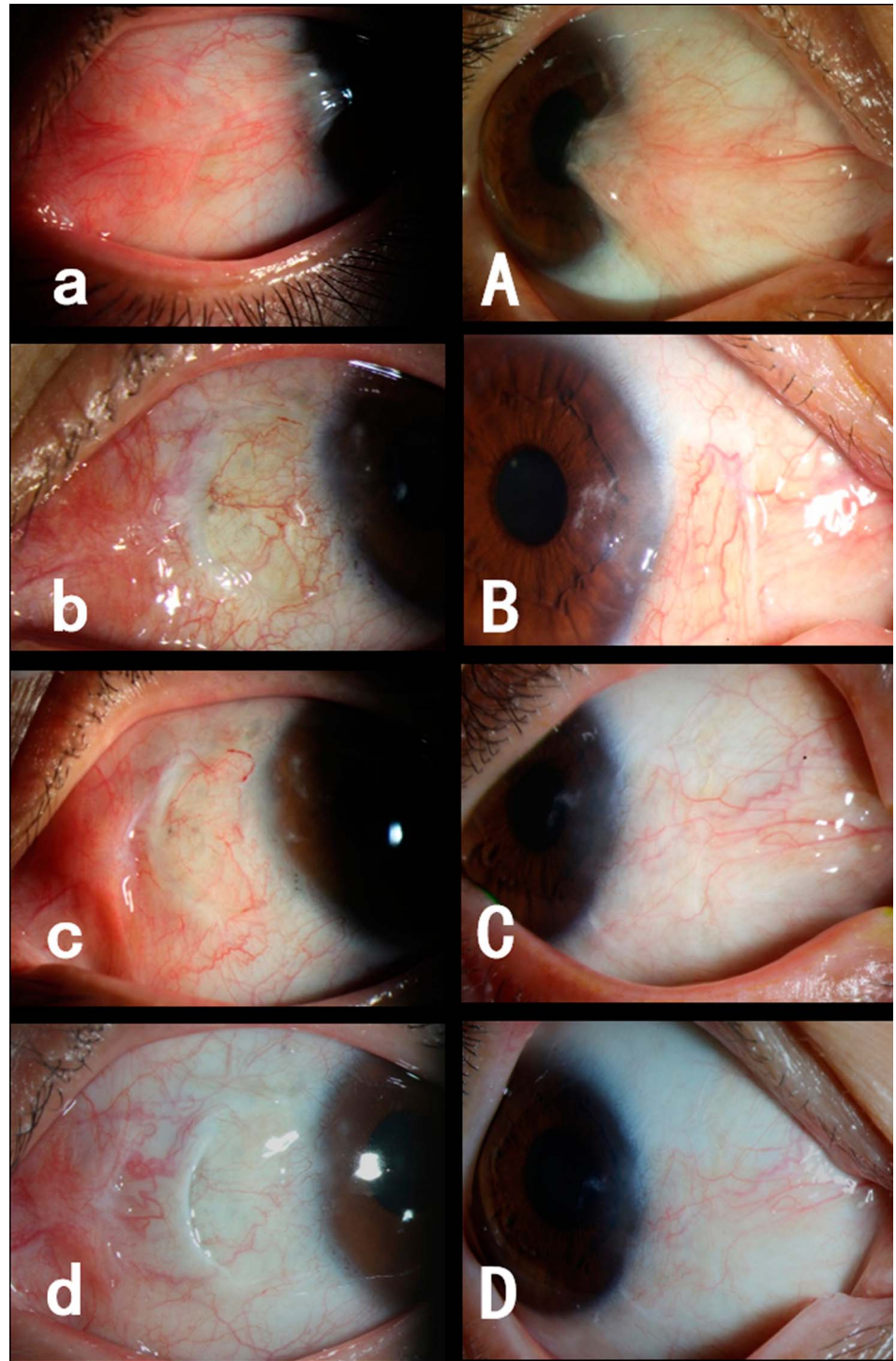
The CAI was significantly lower in the LTP group than that in the control group at postoperative day 1 (2.1 ± 0.55 vs. 2.77 ± 0.63, *P* = 0.000) and week 1 (1.6 ± 0.56 vs. 2.3 ± 0.47, *P* = 0.000), but no difference was observed at postoperative month 1 (LTP, 1.2 ± 0.81 vs. control, 1.53 ± 0.82, *P* = 0.21) and month 3 (LTP, 0.87 ± 0.77 vs. control, 1.27 ± 0.86, *P* = 0.07) (Fig. 2).

### Graft Stability and Complications

Corneal epithelium healed completely after the contact lens was removed at week 1 in all patients. Two conjunctival grafts (6.7%) were lost in the control group at day 1, but none (0%) in the LTP group were lost, demonstrating better GS in the LTP group (*P* = 0.01). Four cases (13.3%) of scleral fluorescein staining in the LTP group and 8 (26.7%) in the control group were observed at an early postoperative time (week 1) (*P* = 0.12), but all healed without additional intervention 1 month later (Fig. 3). Pterygium recurrence



**FIGURE 2.** Postoperative inflammation evaluated by CAI. CAI was significantly reduced in the LTP group on both day 1 (*P* = 0.000) and day 7 (*P* = 0.000), although no significant differences were observed on day 30 (*P* = 0.21) and day 90 (*P* = 0.07). \*Indicates a significant difference (*P* < 0.05); ns, none statistically significant, *P* > 0.05.



**FIGURE 3.** Slit-lamp photographs after pterygium surgery with a conjunctival autograft. a-d, Images of the conjunctival appearance in the control group captured before surgery and at month 1, month 3, and year 1 after surgery, respectively. A-D, Images of the conjunctival appearance in the LTP group captured before surgery and at month 1, month 3, and year 1 after surgery, respectively. (The full color version of this figure is available at [www.corneajrnl.com](http://www.corneajrnl.com).)

was found in 2 patients (6.7%) in the control group but in none (0%) in the LTP group at the 1-year follow-up ( $P = 0.08$ ). One patient experiencing recurrence of pterygium at postoperative month 3 had grade 4 graft instability, whereas the other patient who had a late pterygium recurrence (7 months after surgery) had grade 3 graft instability. No complications such as elevated IOP, symblepharon, giant

papillary conjunctivitis, corneal defects, and infection were observed. We analyzed the FA in those patients who did not show frank recurrence. After excluding grade 4 (ie, recurrence), 93.3% (28/30) of LTP patients and 83.3% (25/30) of control subjects were determined to have grades 1 and 2 (ie, with appearances generally acceptable to both patients and physicians). However, the difference in FA between LTP and

**TABLE 2.** Results of Complications and Recurrence

Parameter	LTP Group (30 Eyes)	Control Group (30 Eyes)	P
GS (%)			0.01*
G0	6 (20)	2 (6.7)	
G1	19 (63.4)	14 (46.6)	
G2	4 (13.3)	10 (33.3)	
G3	1 (3.3)	2 (6.7)	
G4	0 (0)	2 (6.7)	
FA (%)			0.26
G1	15 (50)	12 (40)	
G2	13 (43.3)	13 (43.3)	
G3	2 (6.7)	3 (10)	
G4	0 (0)	2 (6.7)	
Scleral fluorescein staining (%)	4 (13.3)	8 (26.7)	0.52
Recurrence (%)	0 (0)	2 (6.7)	0.08

\*Statistically significant ( $P < 0.05$ ).

GS: G0, all 4 sides of the graft margin are well apposed; G1: gaping/displacement of one side of the graft-bed junction; G2, gaping/displacement of 2 sides of the graft-bed junction; G3, gaping/displacement of 3 sides of the graft-bed junction; G4, graft completely displaced from the bed. FA: G1, normal appearance; G2, some fine episcleral vessels in the excised area extending up to but not beyond the limbus and without any fibrous tissue; G3, additional fibrous tissues in the excised area that did not invade the cornea; G4, true recurrence with fibrovascular tissue invading the cornea.

control groups did not achieve statistical significance ( $P = 0.26$ ) (Table 2).

### Postoperative Pain

The VAS indicated the degree of pain the patient experienced, which was not significantly different between the 2 groups at postoperative week 1, months 1 and 3 ( $P > 0.05$ ) but was significantly lower in the LTP group at day 1 ( $P = 0.04$ ) (Fig. 4).

### Correlation Analysis

Correlation analysis showed that relevant factors for recurrence were GS ( $R = 0.425$ ,  $P = 0.001$ ) and CAI ( $R = 0.309$ ,  $P = 0.016$ ). Moreover, GS was related to PA ( $R = 0.398$ ,  $P = 0.002$ ) and CAI ( $R = 0.333$ ,  $P = 0.009$ ). FA was correlated with pterygium grade ( $R = 0.347$ ,  $P = 0.007$ ), PA ( $R = 0.082$ ,  $P < 0.001$ ), and GS ( $R = 0.558$ ,  $P < 0.001$ ).

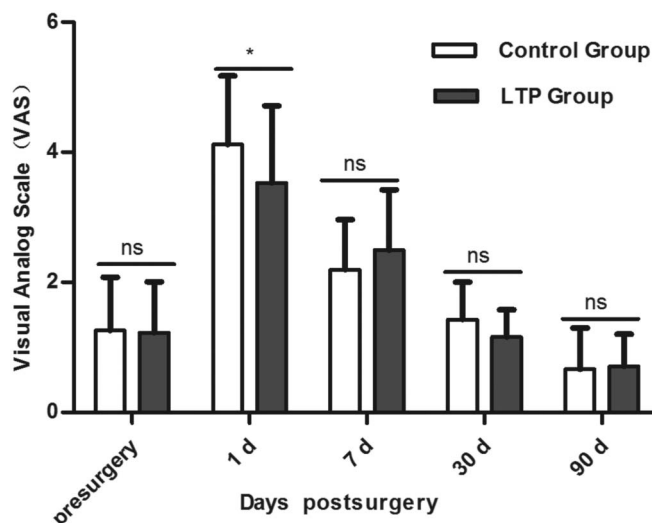
## DISCUSSION

Recurrence is the most undesired complication after pterygium surgery. There has been an evolution of multiple surgical techniques to achieve low recurrence, such as using CAGs for exposed sclera<sup>2</sup> and using fibrin glue adhesives to replace sutures,<sup>3</sup> as well as using antifibrotic,<sup>1</sup> anti-vascular endothelial growth factor,<sup>24</sup> and even robotic-assisted pterygium surgery.<sup>25</sup> CAG has been considered an effective procedure for reducing recurrence. In our study, in conjunction with the fibrin glue adhesive used for attaching the CAG, we used LTP for tissue ablation and wound hemostasis in pterygium surgery, which proved to be more precise, gentle, and easy to control. With this novel technique, we obtained

satisfactory efficacy and safety in pterygium removal and hemostasis, good GS, a short operative time, and a low recurrence rate.

Pterygium excision combined with autografting using either fibrin glue or autologous blood have recurrence rates ranging from 3.4% to 10.6%.<sup>26,27</sup> In the present study, the introduction of LTP into pterygium surgery further reduced the risk of recurrence in comparison to published rates. Subepithelial fibrovascular tissue, inflammation, and GS have been reported as risk factors for recurrence.<sup>28</sup> The unexcised abnormal fibrovascular tissue may continue to proliferate after pterygium surgery<sup>3</sup>; therefore, inadequate pterygium sectioning is a risk factor for recurrence. Traditionally, surgical blades have been used for pterygium tissue removal, whereas blades were replaced by LTP in our study. Although tissue removal was performed in the same fashion by the same surgeon in all participants, we found that LTP was more thorough in tissue polishing. More thorough ablation of subepithelial fibrovascular tissue after pterygium excision may have contributed to the lower recurrence rate and better cosmetic appearance in the LTP group.

Some studies have revealed that fibroblasts cultured from pterygium body overexpress the matrix-degrading enzymes matrix metalloproteinase (MMP)-1 and 3 in response to proinflammatory cytokines, such as interleukin-1 $\beta$  or tumor necrosis factor- $\alpha$ .<sup>29</sup> This finding supports the fact that inflammation of the ocular surface may activate the transformation of remaining pterygia body fibroblasts into an invasive phenotype.<sup>30</sup> Furthermore, a recent study showed that ocular demodicosis is a risk factor for pterygium recurrence, presumably by perpetuating chronic inflammation mediated by T-helper-17 lymphocytes.<sup>31</sup> This finding also



**FIGURE 4.** Postoperative pain was evaluated by a VAS. Significant differences in pre-VAS ( $P = 0.77$ ) were not observed between the 2 groups. The degree of VAS was significantly decreased in the LTP group on day 1 ( $P = 0.04$ ), although no significant differences were observed on day 7 ( $P = 0.18$ ), day 30 ( $P = 0.06$ ), and day 90 ( $P = 0.54$ ). \*Indicates a significant difference ( $P < 0.05$ ); ns, none statistically significant,  $P > 0.05$ .



explains why CAI was associated with recurrence in our study. Consistent with the results from these studies, we observed lower CAI in the LTP group at day 1 and week 1, indicating that LTP produces less burning and is more gentle than cautery to reduce inflammation. Moreover, the expression of tumor necrosis factor- $\alpha$  and MMP-9 was recently shown to be significantly suppressed in plasma-treated fungal keratitis in rabbits, indicating that plasma exerts an anti-inflammatory effect on the cornea.<sup>32</sup>

Graft dehiscence is the main issue causing the recurrence of pterygium. Bare scleral excision is known to be associated with a high recurrence rate of up to 61%.<sup>19</sup> After combination with amniotic membrane transplantation or CAGs, the recurrence rate is substantially reduced from 5.3% to 39%.<sup>1,2</sup> Our correlation analysis data also showed a positive relationship between GS and recurrence. In this study, there were 2 cases (6.7%) of graft dislocation in the control group but none (0%) in the LTP group, but probably because of a relatively small sample size, the difference in recurrence rates between the 2 groups did not achieve statistical significance. It has been suggested that immediate adherence of the graft may inhibit fibroblast ingrowth and reduce recurrence.<sup>33</sup> Based on our study, we found that mild graft retraction and dehiscence, such as GS of grade 1 or 2, do not affect recurrence but are essential for wound healing. However, serious dehiscence (grade 3) and even dislocation (grade 4) may directly lead to recurrence, which necessitates repeated surgery to attach the graft as soon as possible.

Studies have reported rates of graft loss in surgeries performed with fibrin glue ranging from 1.14% to 6%,<sup>34,35</sup> and rates of partial dislodgement ranging from 1.7% to 16%.<sup>26,35</sup> In the present study, fibrin glue was used for graft attachment in both groups. Two cases experienced graft loss in the control group (6.7%), which is within the acceptable range, whereas no patients in the LTP group experienced graft loss, indicating that the LTP group exhibited better GS than the control group. Although the adequacy of the fibrin glue used, such as the amount and ratio of components, plays an important role in determining GS; the smoothness of the exposed scleral surface may also influence the GS. LTP is effective at achieving hemostasis, but it is more gentle and produces less damage. In the present study, the exposed scleral surface in the LTP group was smoother than that in the control group and the surgical wound surface did not contain pits. The smooth surface may be one of the factors contributing to lower graft loss rates in the LTP group than those in the control group.

Some studies have reported that plasma could stimulate cell proliferation and consequently promote tissue regeneration in skin and blood vessels. The plasma induces changes in the gene expression of key molecules involved in the wound healing machinery, such as transforming growth factor- $\beta$ 1 and - $\beta$ 2, and promotes wound healing in vitro and in vivo.<sup>36</sup> In addition, the plasma-induced skin regeneration is a novel method of resurfacing that serves as a natural biological dressing and promotes wound healing and rapid recovery.<sup>37</sup> Furthermore, low-dose nonthermal plasma enhances endothelial cell proliferation due to reactive oxygen species-

mediated fibroblast growth factor 2 release.<sup>38</sup> These processes may help explain our findings of fewer scleral defects in the LTP group.

The safety of the LTP technique was further evaluated in our study. The LTP only affects the contact site with a depth of penetration of approximately 20 to 50  $\mu$ m.<sup>32</sup> Hence, with appropriate energy, the affected depth and width can be controlled, making the LTP relatively safe for surrounding tissues such as the lens, iris, and retina. Our study used the VAS to quantify patient pain. We found that LTP also provided good postoperative comfort, especially on postoperative day 1. In addition, some studies have indicated that autologous blood is an effective and safe method for attaching CAGs, similar to fibrin glue.<sup>4</sup> Our results showed better GS in the LTP group than that in the control group. Therefore, we speculate that effective and gentle hemostasis may improve the stability of the graft.

## CONCLUSIONS

Our study has provided insights into the surgical outcomes of the LTP-assisted pterygium surgery technique, which is safe and feasible, and has some obvious advantages, including a shorter operation time, milder inflammation, and better graft stability, which were significant factors correlated with recurrence. There were no unacceptable complications from this technique, and all patients experienced clinical improvement during an adequate length of follow-up. We acknowledge some limitations to the present study. In the present study, we did not fully confirm the optimal LTP energy strengths for pterygium surgery and the underlying mechanisms for surgical outcomes using LTP. In addition, a larger number of clinical trials may be necessary to validate the specific biological effects of LTP and personalized LTP parameters in the future.

## REFERENCES

1. Kaufman SC, Jacobs DS, Lee WB, et al. Options and adjuvants in surgery for pterygium: a report by the American Academy of Ophthalmology. *Ophthalmology*. 2013;120:201–208.
2. Clearfield E, Hawkins BS, Kuo IC. Conjunctival autograft versus amniotic membrane transplantation for treatment of pterygium: findings from a systematic review. *Am J Ophthalmol*. 2017;182:8–17.
3. Cha DM, Kim KH, Choi HJ, et al. A comparative study of the effect of fibrin glue versus sutures on clinical outcome in patients undergoing pterygium excision and conjunctival autografts. *Korean J Ophthalmol*. 2012;26:407–413.
4. Zeng W, Dai H, Luo H. Evaluation of autologous blood in pterygium surgery with conjunctival autograft. *Cornea*. 2019;38:210–216.
5. Gunduz K, Gunalp I, Ozden RG. Anterior segment ischemia following pterygium surgery. *Jpn J Ophthalmol*. 1997;41:192–195.
6. Naftali M, Jabaly-Habib H, Mukari A. Burn during a routine pterygium excision operation. *Eur J Ophthalmol*. 2008;18:639–640.
7. Garcia-Medina JJ, Del-Rio-Vellosillo M, Zanon-Moreno V, et al. Severe scleral dellen as an early complication of pterygium excision with simple conjunctival closure and review of the literature. *Arq Bras Oftalmol*. 2014;77:182–184.
8. Gan L, Zhang S, Poorun D, et al. Medical applications of nonthermal atmospheric pressure plasma in dermatology. *J Dtsch Dermatol Ges*. 2018;16:7–13.
9. Akhmedov IN, Isaev VM, Svistushkin VM, et al. Endolaryngeal cold-plasma microsurgery for the treatment of benign neoplasms in the larynx and the objective assessment of its functional results. *Vestn Otorinolaringol*. 2011;57–60.

10. Zhang Y, Wang B, Sun G, et al. Carbon dioxide laser microsurgery versus low-temperature plasma radiofrequency ablation for T1a glottic cancer: a single-blind randomized clinical trial. *Biomed Res Int*. 2018;2018:4295960.
11. Weltmann KD, Metelmann HR, Von Woedtke T. Low temperature plasma applications in medicine. *Europhysics News*. 2016;47:39–42.
12. Adachi T. Introduction to serial reviews: biomedical application of non-thermal atmospheric pressure plasma and its usefulness. *J Clin Biochem Nutr*. 2017;60:1–2.
13. Wang Z, Zhang Y, Cui H, et al. Endoscopic low-temperature plasma radiofrequency ablation for laryngeal plexiform neurofibromatosis-1 in an infant: case report and review of the literature. *Technol Health Care*. 2016;24:775–780.
14. Fugo RJ. Fugo blade to enlarge phimotic capsulorhexis. *J Cataract Refract Surg*. 2006;32:1900.
15. Singh D. Use of the Fugo blade in complicated cases. *J Cataract Refract Surg*. 2002;28:573–574.
16. Singh D, Bundela R, Agarwal A, et al. Goniotomy ab interno “a glaucoma filtering surgery” using the Fugo Plasma Blade. *Ann Ophthalmol (Skokie)*. 2006;38:213–217.
17. Peponis V, Rosenberg P, Reddy SV, et al. The use of the Fugo Blade in corneal surgery: a preliminary animal study. *Cornea*. 2006;25:206–208.
18. Ma DH, See LC, Liao SB, et al. Amniotic membrane graft for primary pterygium: comparison with conjunctival autograft and topical mitomycin C treatment. *Br J Ophthalmol*. 2000;84:973–978.
19. Tan DT, Chee SP, Dear KB, et al. Effect of pterygium morphology on pterygium recurrence in a controlled trial comparing conjunctival autografting with bare sclera excision. *Arch Ophthalmol*. 1997;115:1235–1240.
20. Nejima R, Masuda A, Minami K, et al. Topographic changes after excision surgery of primary pterygia and the effect of pterygium size on topographic restoration. *Eye Contact Lens*. 2015;41:58–63.
21. Srinivasan S, Dollin M, McAllum P, et al. Fibrin glue versus sutures for attaching the conjunctival autograft in pterygium surgery: a prospective observer masked clinical trial. *Br J Ophthalmol*. 2009;93:215–218.
22. McCormack HM, Horne DJ, Sheather S. Clinical applications of visual analogue scales: a critical review. *Psychol Med*. 1988;18:1007–1019.
23. Prabhawat P, Barton K, Burkett G, et al. Comparison of conjunctival autografts, amniotic membrane grafts, and primary closure for pterygium excision. *Ophthalmology*. 1997;104:974–985.
24. Nava-Castaneda A, Olvera-Morales O, Ramos-Castellon C, et al. Randomized, controlled trial of conjunctival autografting combined with subconjunctival bevacizumab for primary pterygium treatment: 1-year follow-up. *Clin Exp Ophthalmol*. 2014;42:235–241.
25. Bourcier T, Chammas J, Becmeur PH, et al. Robotically assisted pterygium surgery: first human case. *Cornea*. 2015;34:1329–1330.
26. Nadarajah G, Ratnalingam VH, Mohd IH. Autologous blood versus fibrin glue in pterygium excision with conjunctival autograft surgery. *Cornea*. 2017;36:452–456.
27. Kurian A, Reghunadhan I, Nair KG. Autologous blood versus fibrin glue for conjunctival autograft adherence in sutureless pterygium surgery: a randomised controlled trial. *Br J Ophthalmol*. 2015;99:464–470.
28. Kwon SH, Kim HK. Analysis of recurrence patterns following pterygium surgery with conjunctival autografts. *Medicine (Baltimore)*. 2015;94:e518.
29. Lee SB, Li DQ, Tan DT, et al. Suppression of TGF-beta signaling in both normal conjunctival fibroblasts and pterygial body fibroblasts by amniotic membrane. *Curr Eye Res*. 2000;20:325–334.
30. Ti SE, Tseng SC. Management of primary and recurrent pterygium using amniotic membrane transplantation. *Curr Opin Ophthalmol*. 2002;13:204–212.
31. Huang Y, He H, Sheha H, et al. Ocular demodicosis as a risk factor of pterygium recurrence. *Ophthalmology*. 2013;120:1341–1347.
32. Park HJ, Kim SH, Ju HW, et al. Microplasma jet arrays as a choice for fungal keratitis. *Sci Rep*. 2018;8: 2422.
33. Maiti R, Mukherjee S, Hota D. Recurrence rate and graft stability with fibrin glue compared with suture and autologous blood coagulum for conjunctival autograft adherence in pterygium surgery: a meta-analysis. *Cornea*. 2017;36:1285–1294.
34. Kodavoor SK, Ramamurthy D, Solomon R. Outcomes of pterygium surgery-glue versus autologous blood versus sutures for graft fixation-an analysis. *Oman J Ophthalmol*. 2018;11:227–231.
35. Huang X, Zhu B, Lin L, et al. Clinical results for combination of fibrin glue and nasal margin suture fixation for attaching conjunctival autografts after pterygium excision in Chinese pterygium patients. *Medicine (Baltimore)*. 2018;97:e13050.
36. Arndt S, Unger P, Wacker E, et al. Cold atmospheric plasma (CAP) changes gene expression of key molecules of the wound healing machinery and improves wound healing in vitro and in vivo. *PLoS One*. 2013;8:e79325.
37. Foster KW, Moy RL, Fincher EF. Advances in plasma skin regeneration. *J Cosmet Dermatol*. 2008;7:169–179.
38. Kalghatgi S, Friedman G, Fridman A, et al. Endothelial cell proliferation is enhanced by low dose non-thermal plasma through fibroblast growth factor-2 release. *Ann Biomed Eng*. 2010;38:748–757.