



Contents lists available at ScienceDirect

## International Journal of Surgery Case Reports

journal homepage: [www.casereports.com](http://www.casereports.com)

## Survived COVID-19 patient presented with death on arrival: A case report

Aryan A. Hama Amin<sup>a,b</sup>, Ahmed H. Awakhti<sup>a,c</sup>, Lana A. Hama Hussein<sup>a</sup>,  
Fattah H. Fattah<sup>b,d</sup>, Hiwa O. Baba<sup>b,e</sup>, Fahmi H. Kakamad<sup>b,d,e,\*</sup>, Abdulwahid M. salih<sup>b,d</sup>,  
Hiwa O. Abdullah<sup>b,e</sup>, Berwn A. Abdulla<sup>b,e</sup>, Karokh H. Salih<sup>e</sup>

<sup>a</sup> Sulaymaniyah Directorate of Health, Sulaimani, Iraq<sup>b</sup> Smart Health Tower, Madam Mittarand Street, Sulaimani, Iraq<sup>c</sup> Zhyan Private Hospital, Goran Street, Sulaimani, Iraq<sup>d</sup> College of Medicine University of Sulaimani, Sulaimani, Iraq<sup>e</sup> Kscien Organization, Hamdi Street, Azadi Mall, Sulaimani, Iraq

## ARTICLE INFO

## Article history:

Received 26 February 2021

Received in revised form 21 March 2021

Accepted 21 March 2021

Available online 23 March 2021

## Keywords:

DOA

COVID-19

CPR

Infection

## ABSTRACT

**INTRODUCTION AND IMPORTANCE:** Although Corona virus primarily infects respiratory system, several complications have been reported. The aim of this paper is to report a strange case of corona virus disease presented with death on arrival and survived after rigorous cardiopulmonary resuscitation.

**CASE PRESENTATION:** A 35-year-old male present as a sudden loss of consciousness 10 min before admission. The patient was unconscious, pulseless, there was no sign of breathing, the pupils fixed, did not react to light. Blood sugar was 112 mg/dl. Cardiopulmonary resuscitation (CPR) commenced with insertion of two wide bore cannulas. The patient developed ventricular fibrillation. Later, he reverted to pulseless ventricular tachycardia. After several minutes of CPR, the patient returned back to sinus rhythm. He underwent percutaneous coronary intervention and became healthy one month after the intervention.

**CLINICAL DISCUSSION:** Cardiac involvement in case of COVID-19 might be explained by the presence of the angiotensin-converting enzyme 2 (ACE2) receptor which is a transmembrane soluble protein regulating the local actions of the renin-angiotensin apparatus in cardio-vascular system.

**CONCLUSION:** death on arrival could be the first presentation of COVID-19. Aggressive CPR is necessary to revive the victim.

© 2021 The Author(s). Published by Elsevier Ltd on behalf of IJS Publishing Group Ltd. This is an open access article under the CC BY-NC-ND license (<http://creativecommons.org/licenses/by-nc-nd/4.0/>).

### 1. Introduction

The coronavirus disease 19 (COVID-19) is a pathogenic viral infection with a high transmission rate which is caused by severe acute respiratory syndrome coronavirus 2 (SARS-CoV-2), which emerged at the end of 2019 in Wuhan, China and spread around the world [1].

Corona viruse is a member of the Coronaviridae family which has a crown-like spikes on the outer surface of the virus and a size around (65–125 nm in diameter) which has a single stranded non segmented positive sense RNA genetic material. Corona viruses classified into alpha (a), beta (b), gamma (c) and delta (d) coronavirus [2].

The new corona virus was named by the Chinese researchers as Wuhan coronavirus or 2019 novel coronavirus (2019-nCov) and

named as a SARS-CoV-2 and the disease as COVID-19 by The International Committee on Taxonomy of Viruses (ICTV) and reported to be a substitute of B group of coronaviruses family [2].

The World Health Organization (WHO) has declared the SARS-CoV2 (COVID-19) outbreak a global pandemic on March 11, 2020, the total number of reported cases to WHO till 19th Jan. 2021 was more than 93 million infected cases with more than 2 million deaths [3].

SARS-CoV-2 transmission according to current evidences is primarily through droplets (particles 5–10 μm in size) and inter-personal transmission occurs by coughing, sneezing, and talking with infected individuals within the distance of 6 feet (1.8 m) and on stationary or movable objects and can also be transferred to another person when come in contact with these fomites [4].

The high transmission rate of SARS-CoV2 is thought to be due to genetic recombination event at S protein in the RBD region of SARS-CoV-2 [2].

Although it primarily infects respiratory system, several complications have been reported including strokes, renal failure and peripheral arterial diseases [1]. The aim of this paper is to report a

\* Corresponding author at: Doctor City, Building 11, Apartment 50, Sulaimani, 0064, Iraq.

E-mail address: [fahmi.husseini@uniuvslu.edu.iq](mailto:fahmi.husseini@uniuvslu.edu.iq) (F.H. Kakamad).

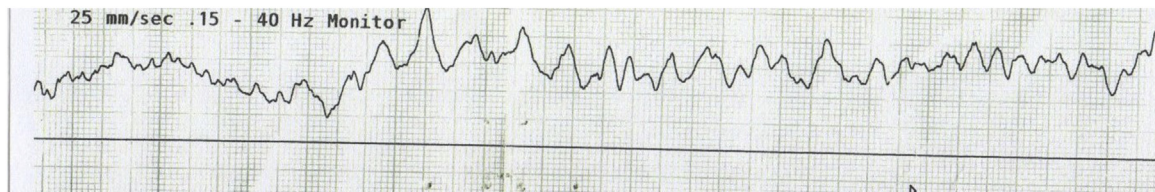

Fig. 1. ECG showing ventricular fibrillation.

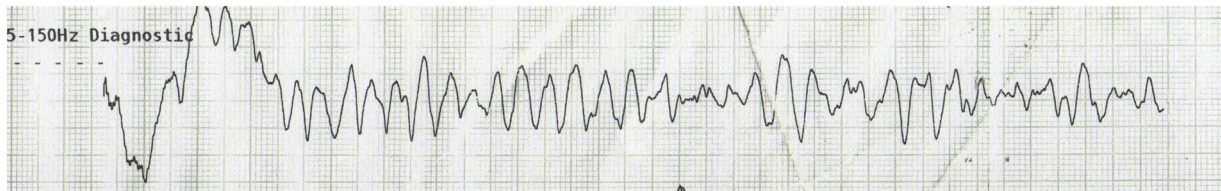


Fig. 2. Ventricular tachycardia.

strange case of COVID-19 presented with death on arrival and survived after rigorous cardiopulmonary resuscitation. The report has been arranged in line with SCARE 2020 guidelines [5].

### 1.1. Patient information

A 35-year-old male present to Emergency Department as a sudden loss of consciousness 10 min before admission. His family reported chest pain and sweating few minutes before fainting. He was smoker (20 packs-year), ex-drinker and known case of neglected type 1 diabetes mellitus without regular medication.

### 1.2. Clinical findings

The patient was unconscious, pulseless, there was no sign of breathing, the pupils fixed, did not react to light, he had a normal body weight (22.32 kg/m<sup>2</sup>).

### 1.3. Diagnostic assessment

There was no enough time to investigate apart from checking blood sugar (112 mg/dl).

### 1.4. Therapeutic intervention

Cardiopulmonary resuscitation (CPR, 30 chest compression followed by 2 rescue breathes for five times continuously) commenced with insertion of two wide bore cannulas. The resuscitation was monitored by DC machine (Monitor mode). The patient developed ventricular fibrillation (VF, Fig. 1). After three cycles of CPR, one ampule of adrenaline 1 mg IV and 1 DC shock 150 J, the strip changed to torsade de pointes, after another three cycles of CPR, an ampule of adrenaline 1 mg IV, an ampule of amiodarone 150 mg IV and 1 DC shock 170 J, the patient reverted to pulseless ventricular tachycardia (VT, Fig. 2). CPR was ongoing (another seven cycles), two ampules of adrenaline 1 mg IV, two ampules of amiodarone 150 mg IV and 2 DC shocks 200 J. After several minutes of CPR, the patient returned back to sinus rhythm with ECG evidence of ST elevation myocardial infarction (STEMI).

After 90 min of resuscitation; pulse rate:82 beats per minute, SpO<sub>2</sub>:88–94% with 10 L O<sub>2</sub> by face mask, pupils react to light with slight delay in response but unconscious. After intubation, the patient referred to cardiac care unit (CCU) for primary percutaneous coronary intervention (PCI, angioplasty with ballooning was performed for left anterior descending artery). On the 4th day of CCU admission, the patient was extubated and discharged home

on the 5th day of admission. Most of the medical procedures and interventions were performed by the first three authors.

### 1.5. Follow up

The patient was healthy 30 days after discharge.

## 2. Discussion

Patients with COVID-19 disease usually present with pyrexia as a most common presentation. Cough in the early presentation is also common which, at the beginning is dry then becomes productive with other respiratory symptoms like sore throat, nasal congestion, and dyspnea. Constitutional symptoms present as a muscle cramps, bone pain, chills and head ache. Gastrointestinal symptoms like nausea, vomiting and diarrhea are the main presenting symptoms in a few cases [6].

Severe infection and more involvement of lung tissue can cause acute respiratory distress syndrome (ARDS) and septic shock. The current patient had dizziness for two days before arrival [7].

COVID-19 has a wide range of atypical presentation includes limb ischemia, acute cardiac injury, arrhythmias, myocarditis which caused by damage of cardiac cells by direct effect of the virus, acute coronary syndrome and pulmonary embolism by an imbalance between pro-coagulative and anti-coagulant mechanisms of the body [7,8]. Another rare presentation of the virus is pericardial involvement and cardiac tamponade due to large hemorrhagic pericardial effusion without cardiac injury and myocardial involvement [7]. Hons and associates investigated the causes behind reduction of in-hospital mortalities of cardiac patients during COVID-19 era. They study 29635 patients and found that most of the cardiac patients develop arrest before admission [9].

Cardiac involvement in case of COVID-19 might be explained by the presence of the angiotensin-converting enzyme 2 (ACE2) receptor which is a transmembrane soluble protein regulating the local actions of the renin-angiotensin apparatus in cardio-vascular system [10].

The present case had cardiac arrest on presentation that might be due to direct insult the myocardium.

Dermatological manifestations have also been reported such as urticaria, vesicle formation and rash. The exact mechanism still to be understood [7]. We did not observe skin signs in this case.

Central nervous system manifestation such as loss of taste and smell through cribriform plate of ethmoid, confusion, headache, ataxia cerebrovascular disease and seizure are other rare presentations [7].

Encephalitis is another rare manifestation of the virus, CSF analysis by RT-PCR was positive for SARS-CoV2 [11].

Rhabdomyolysis as a complication of myositis has been reported in few cases. It is recognized by a more intense pain than myalgia which is often self-limited and last for 3 days [12].

The most common chest-X-ray finding in COVID-19 cases is consolidation followed by reticular interstitial thickening and ground glass opacity, less frequent finding are pleural effusion and pulmonary nodule [13].

Chest CT-scan shows a variety of findings include ground glass opacity, crazy-paving patterns, interstitial infiltration, multiple patchy consolidation, interlobar septal thickening and vessel enlargement [7].

High resolution chest CT-scan in this case showed bilateral pleural effusion and ground glass opacity.

In conclusion, death on arrival could be the first presentation of COVID-19. Aggressive CPR is necessary to revive the victim. One should not be distracted by non-responding in the first few minutes.

#### Declaration of Competing Interest

There is no conflict to be declared.

#### Funding

No source to be stated.

#### Ethical approval

Approval is not necessary for case report in our locality.

#### Consent

Consent has been taken from the patient and the family of the patient.

#### Author contribution

Aryan A. Hama amin, Ahmed H. Awakhti, Lana A. Hama Hussein: Rotators managing the case, follow up the patient, writing the manuscript and final approval of the manuscript.

Fahmi H. Kakamad, Hiwa O. Abdullah, Berwn A. Abdulla: literature review, writing the manuscript, final approval of the manuscript.

Fattah H. Fattah, Hiwa O. Baba, Abdulwahid M. salih<sup>2,4</sup>, Karokh H. salih: major contribution to the idea, revision and final revision of the manuscript.

#### Registration of research studies

Not Applicable.

#### Guarantor

Fahmi Hussein Kakamad is the Guarantor of submission.

#### Provenance and peer review

Not commissioned, externally peer-reviewed.

#### References

- [1] H.M. Abdullah, H.H. Hama-Ali, S.N. Ahmed, K.M. Ali, K.A. Karadakhly, S.O. Mahmood, et al., Severe refractory COVID-19 patients responding to convalescent plasma; A case series, *Ann. Med. Surg.* 56 (1) (2020) 125–127.
- [2] M.A. Shereen, S. Khan, A. Kazmi, N. Bashir, R. Siddique, COVID-19 infection: origin, transmission, and characteristics of human coronaviruses, *J. Adv. Res.* 24 (1) (2020) 91–98.
- [3] World Health Organization. <https://covid19.who.int/>. Accepted on 19 January 2021.
- [4] S.B. Omer, P. Malani, C. Del Rio, The COVID-19 pandemic in the US: a clinical update, *JAMA* 323 (18) (2020) 1767–1768.
- [5] R.A. Agha, T. Franchi, C. Sohrabi, G. Mathew, for the SCARE Group, The SCARE 2020 guideline: updating consensus Surgical CAse REport (SCARE) guidelines, *Int. J. Surg.* 84 (2020) 226–230.
- [6] P. Kakodkar, N. Kaka, M.N. Baig, A comprehensive literature review on the clinical presentation, and management of the pandemic coronavirus disease 2019 (COVID-19), *Cureus* 12 (4) (2020).
- [7] M. Macera, G. De Angelis, C. Sagnelli, N. Coppola, V. COVID, Clinical presentation of COVID-19: case series and review of the literature, *Int. J. Environ. Res. Public Health* 17 (14) (2020) 5062.
- [8] A. Baram, Fh Kakamad, Hm Abdullah, Dh Mohammed-Saeed, Da Hussein, Sh Mohammed, et al., Large vessel thrombosis in patient with COVID-19, a case series, *Ann. Med. Surg.* 60 (1) (2020) 526–530.
- [9] M. Glg Rashid, C.P. Gale, N. Curzen, P. Ludman, M. De Belder, A. Timmis, et al., Impact of coronavirus disease 2019 pandemic on the incidence and management of out-of-hospital cardiac arrest in patients presenting with acute myocardial infarction in England, *J. Am. Heart Assoc.* 9 (22) (2020), e018379.
- [10] A. García-Escobar, S. Jiménez-Valero, G. Galeote, A. Jurado-Román, J. García-Rodríguez, R. Moreno, The soluble catalytic ectodomain of ACE2 a biomarker of cardiac remodelling: new insights for heart failure and COVID19, *Heart Fail. Rev.* 26 (1) (2021), -1.
- [11] D.G. Placantonakis, M. Aguero-Rosenfeld, A. Flaifel, J. Colavito, K. Inglima, D. Zagzag, et al., SARS-CoV-2 is not detected in the cerebrospinal fluid of encephalopathic COVID-19 patients, *Front. Neurol.* 11 (1) (2020).
- [12] Q. Zhang, K.S. Shan, A. Minalyan, C. O'Sullivan, T. Nace, A rare presentation of coronavirus disease 2019 (COVID-19) induced viral myositis with subsequent rhabdomyolysis, *Cureus* 12 (5) (2020).
- [13] R. Yasin, W. Gouda, Chest X-ray findings monitoring COVID-19 disease course and severity, *Egypt. J. Radiol. Nucl. Med.* 51 (1) (2020) 1–8.

#### Open Access

This article is published Open Access at [sciencedirect.com](https://www.sciencedirect.com). It is distributed under the [IJSCR Supplemental terms and conditions](#), which permits unrestricted non commercial use, distribution, and reproduction in any medium, provided the original authors and source are credited.