

Mapping of low-voltage bridges with a high-density multipolar catheter in a child with atrioventricular nodal reentry tachycardia



Fabrizio Drago, MD,* Camilla Calvieri, MD, PhD,* Greta Allegretti, BioMedEng,[†] Massimo Stefano Silvetti, MD*

From the *Paediatric Cardiology and Cardiac Arrhythmias/Syncope Unit, Bambino Gesù Children's Hospital and Research Institute, Rome, Italy, and [†]Abbott, St Jude, Abbott Medical Italia S.p.A., Agrate Brianza, Italy.

Introduction

The new Advisor HD Grid Sensor Enabled mapping catheter (Abbott Medical Italia S.p.A., Agrate Brianza, Italy) has been recently used in different clinical settings.

This new multipolar catheter with small electrodes and very short inter-electrode space has been proved to be effective and safe in left atrial mapping for atrial fibrillation ablation procedures,¹ as well as for right ventricle premature ventricular contraction mapping² and for left ventricle epicardial mapping.³

In the last years, different authors have described 3D voltage mapping of the Koch triangle in order to find low-voltage bridges as targets for a successful transcatheter ablation (TCA) of the slow pathway in children.⁴ Although this new strategy seems to be very promising, mapping can be difficult, operator-dependent, and time-consuming.

Case report

A case of successful TCA of typical atrioventricular nodal reentry tachycardia (AVNRT) in a child using this new multi-electrode mapping catheter and the “low-voltage bridge strategy”⁴ is described below.

Owing to its specific technical characteristics, this new catheter allows very fast electroanatomical mapping regardless of the direction of the signal's front propagation.

A 12-year-old boy was scheduled for TCA using the EnSite Precision Navigation System and the Advisor HD Grid Sensor Enabled mapping catheter (Abbott Medical Italia S.p.A.) for symptomatic AVNRT previously documented by electrocardiogram prior in the emergency room.

KEYWORDS Advisor HD Grid catheter; AVNRT; Children; 3D mapping; Transcatheter ablation
(Heart Rhythm Case Reports 2020;6:8–10)

Address reprint requests and correspondence: Dr Camilla Calvieri, Paediatric Cardiology and Cardiac Arrhythmias/Syncope Unit, Bambino Gesù Children's Hospital and Research Institute, Piazza Sant'Onofrio 4, 00165 Rome, Italy. E-mail address: camilla.calvieri@opbg.net.

KEY TEACHING POINTS

- The HD Grid multipolar catheter (Abbott Medical Italia S.p.A., Agrate Brianza, Italy), with its handle flexibility and smooth shape, allows a safe and not arrhythmogenic HD 3D mapping of the Koch triangle.
- High-density mapping by HD grid multipolar mapping catheter is useful in ablation of atrioventricular nodal reentry tachycardia in children by using the low-voltage bridge strategy.
- The Advisor HD Grid mapping catheter allows a very safe, fast, and accurate Koch triangle mapping in order to obtain a successful ablation of the slow pathway.

The endocavitary electrophysiological study was performed in basal condition and during infusion of isoproterenol, showing only the presence of the St-R>RR phenomenon during overdrive atrial pacing and a reproducible inducibility of single typical atrioventricular nodal reentry.

By mapping in the right atrium 1576 points in only 238 seconds (Figure 1A), 2 small and very close low-voltage bridges were found in the Koch triangle, in the so-called P1,⁴ just in front of the coronary sinus ostium (Supplementary Video). Figure 1B shows the bridges and the typical “hump and spike” signal recorded by the HD Grid catheter on its C2-C3 bipole at this site. This specific signal was more evident compared to its correspondent orthogonal bipole B2-C2 and compared to the one recorded by a standard quadripolar catheter (Figure 1B).

Four cryoablations (cryo-mapping at -30°C to -50°C for 30 seconds, cryoablation at -77°C to -80°C for 480 seconds) were performed using a 6-mm-tip cryo-catheter. The entire area of the bridges was covered and the slow pathways were successfully eliminated without complications and

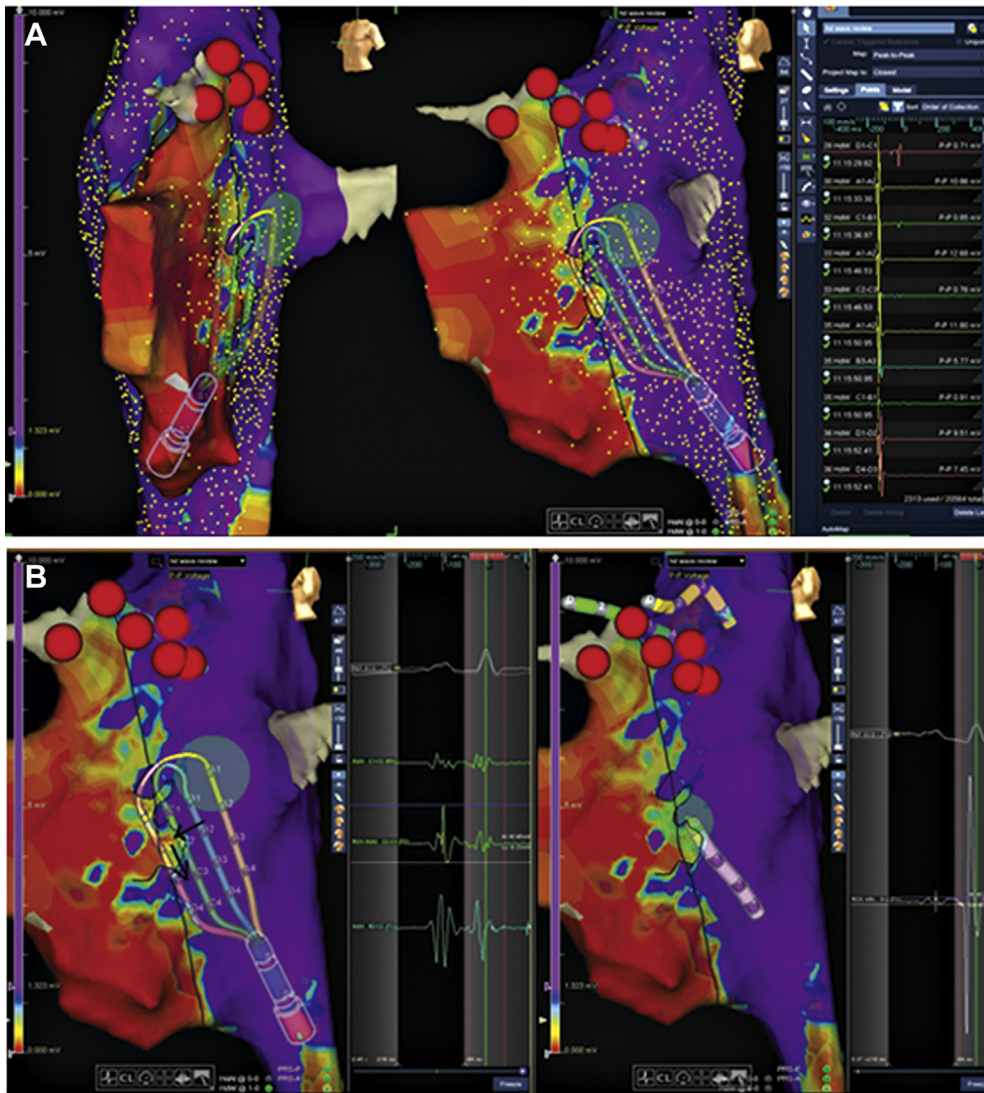


Figure 1 A: 3D mapping by Advisor HD Grid (Abbott Medical Italia S.p.A, Agrate Brianza, Italy). B: The bridges and the typical “hump and spike” signal recorded by the HD Grid catheter on its C2-C3 bipole at this site.

with a radiological exposure of only 1.1 mGy. At the end of the procedure, no reproducible inducibility of single typical atrioventricular nodal reentry and St-R>RR phenomenon during overdrive atrial pacing was observed in baseline condition and during isoproterenol infusion.

During the follow-up period (7 months), no spontaneous recurrences were reported, and a transesophageal electrophysiological study did not show any sign of presence of slow pathway conduction.

Discussion

To the best of our knowledge, this is the first procedure with the HD Grid multipolar catheter in mapping and ablation of AVNRT with “low-voltage bridge strategy” in children.

The design of this catheter with 16 electrodes of 1 mm of thickness, 3 mm equidistant electrode spacing (Abbott, St Paul, MN) allows bi-dimensional bipolar recording along and across the splines. This allows greater mapping sensitivity regardless of signals’ direction of activation, unlike

traditional mapping catheters, which only allow bipolar recording in 1 direction.

Moreover, its flexibility and smooth shape make this HD catheter particularly atraumatic, maneuverable, and, above all, not arrhythmogenic, as are other HD catheters.

These technological features allowed us to elicit a more accurate definition of anatomical substrate^{1,2} and a safe and faster 3D mapping of the Koch triangle than those obtained with conventional bipolar catheters (mean time 14 ± 3 minutes, in our experience), as shown in the [Supplementary Video](#).

Conclusions

This case report seems to indicate the Advisor HD Grid mapping catheter as the ideal catheter for a very safe, fast, and accurate Koch triangle mapping in order to obtain a successful ablation of the slow pathway using the low-voltage bridge strategy in pediatric patients.

Acknowledgments

The authors would like to thank Dr Elisa Del Vecchio for her valuable collaboration in the editorial revision.

Appendix

Supplementary data

Supplementary data associated with this article can be found in the online version at <https://doi.org/10.1016/j.hrcr.2019.09.009>.

References

1. Yeo C, Tan VH, Wong KCK. Pulmonary vein reconnection mapping with Advisor HD Grid demonstrating local EGM which were not visible on Tactiath ablation catheter. *J Arrhythm* 2019;35:152–154.
2. Cauti FM, Rossi P, Allegretti G, Iaia L, Bianchi S. Increasing pace mapping properties in parahissian premature ventricular contraction. Novel insight from HD grid multipolar catheter. *J Arrhythm* 2019;35:149–151.
3. Bellmann B, Luker J, Steven D, Sultan A. First epicardial mapping of the left ventricle using the Advisor HD Grid catheter. *J Interv Card Electrophysiol* 2018; 53:103–104.
4. Drago F, Battipaglia I, Russo MS, et al. Voltage gradient mapping and electrophysiologically guided cryoablation in children with AVNRT. *Europace* 2018;20:665–672.