

Case Report

Entrapment of the urinary bladder: A rare mechanism of bladder injury in pelvic trauma

Derek S. Stenquist^{a,*}, Tyler J. Chavez^b, Michael J. Weaver^{c,d}

^aHarvard Combined Orthopedic Residency Program, Brigham and Women's Hospital, United States of America

^bHarvard Medical School, 25 Shattuck Street, Boston, MA 02115, United States of America

^cHarvard Medical School, Brigham and Women's Hospital, United States of America

^dOrthopaedic Trauma, Brigham and Women's Hospital, United States of America

ARTICLE INFO

Keywords:

Trauma surgery
Pelvic fracture
Bladder entrapment
Pelvic trauma
Genitourinary trauma

ABSTRACT

A pelvic fracture with entrapment of the urinary bladder in the fracture site is a rare pattern of injury. As the “team captains” in the trauma bay and in the care of polytraumatized patients, trauma surgeons must be aware of this entity and its implications. We report a case of acute bladder entrapment in the fracture site of a lateral compression pelvic fracture. A review of the English literature yielded four previous reports, including two patients with delayed diagnosis (Ghuman et al., 2014; Kumar et al., 1980; Wright and Taitsman, 1996; Min et al., 2010 [1–4]).

Kumar and colleagues first documented bladder entrapment by a pelvic fracture in 1980 (Kumar et al., 1980 [2]). Ghuman et al. described a similar case treated with fixation of the pelvic fracture (Ghuman et al., 2014 [1]). Wright and colleagues treated a patient with bladder perforation due to entrapment diagnosed two weeks after a pelvic ring fracture (Wright and Taitsman, 1996 [3]). In this case the bladder injury was repaired, but internal fixation of the pelvis fracture was avoided due to fear of contamination. Finally, Min et al. documented a case of bladder entrapment and perforation presenting six months after non-operative management of a pelvic ring fracture. The female patient developed recurrent UTIs and dyspareunia, and imaging revealed fracture malunion with the bladder entrapped in the fracture site (Min et al., 2010 [4]).

This collection of case reports demonstrates the potential for acute or delayed bladder injury even in seemingly benign pelvic fractures. A high index of suspicion is required to intervene and prevent morbidity from bladder injuries in pelvic trauma. Entrapment of the bladder may require surgical intervention even when the injury pattern would not normally dictate surgery for the pelvis or bladder alone (Bryk and Zhao, 2016 [5]). We describe the diagnosis and surgical management of bladder entrapment and present a brief review of bladder injuries associated with pelvic fractures.

Case report

A 37-year-old male carpenter presented after a 20-foot fall from a ladder at work. His GCS was 15 in the Trauma Bay and FAST exam was negative. Physical exam demonstrated a scalp laceration and pain with pelvic compression. There was no blood at the urethral meatus and no scrotal hematoma but Foley catheter placement yielded gross blood. Pelvis x-ray showed a pelvic ring fracture and CT scan confirmed a crescent fracture of the left ilium with left superior and inferior pubic rami fractures. A CT cystogram

* Corresponding author at: Brigham and Women's Hospital, 75 Francis Street, Boston, MA 02115, United States of America.

E-mail address: DSTENQUIST@mg.harvard.edu (D.S. Stenquist).

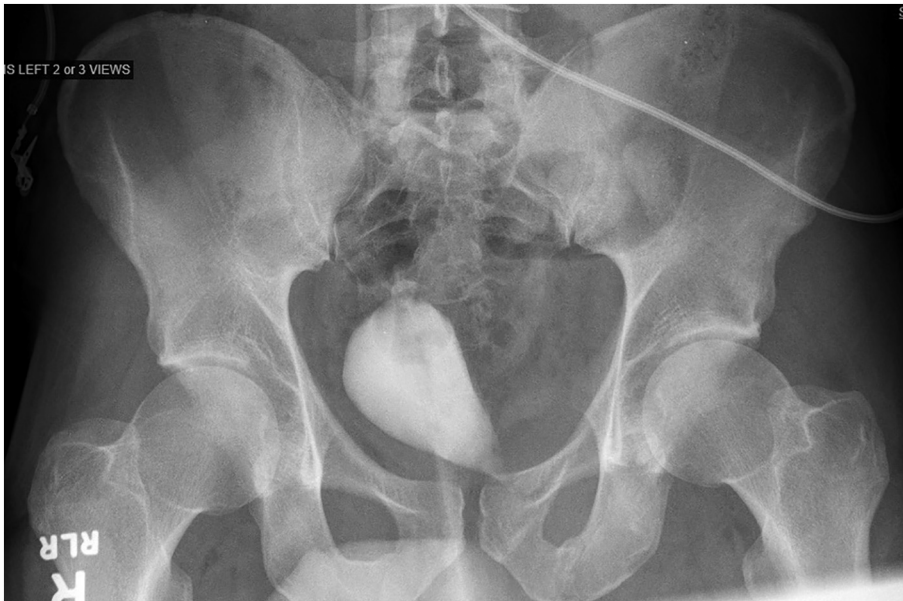

Fig. 1. Residual contrast in the bladder shows bladder entrapment by the left superior pubic ramus fracture on this AP pelvis X-ray.

demonstrated entrapment of the bladder in the left superior pubic ramus fracture with no contrast extravasation, and residual contrast in the bladder showed the entrapment on plain film (Fig. 1).

The patient was taken to the operating room the next day for open reduction and internal fixation of his pelvis fracture with release of the entrapped bladder (Fig. 2). After careful dissection, a Cobb elevator was used to pry the left superior pubic ramus fracture apart, and the bladder was teased free from the fracture site. A tear in the bladder wall extending into the muscularis layer but not through the mucosa was repaired with absorbable sutures in a mattress pattern. The fracture site was irrigated and fixed with a small fragment reconstruction plate. Percutaneous fixation of the posterior pelvic ring injury was performed with a sacroiliac screw (Fig. 3). The patient was given peri-operative antibiotics per routine and discharged with the Foley in place for two weeks, toe-touch weightbearing on the affected extremity. Two weeks after surgery, repeat cystogram demonstrated no active extravasation from the

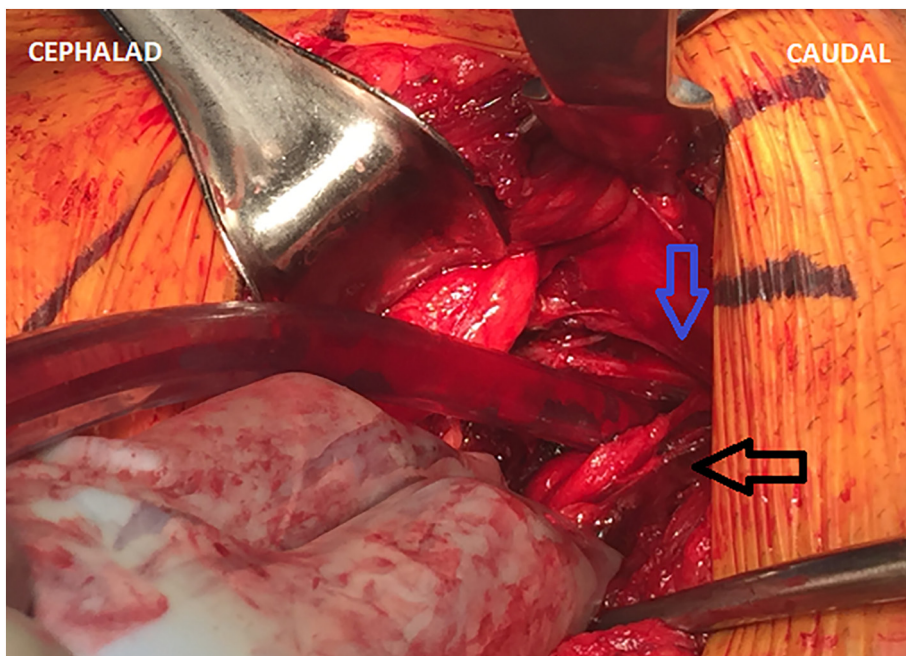

Fig. 2. Intra-operative photograph showing the bladder trapped in the fracture site of the left superior pubic ramus. (Blue arrow = fracture. Black arrow = bladder.) (For interpretation of the references to colour in this figure legend, the reader is referred to the web version of this article.)

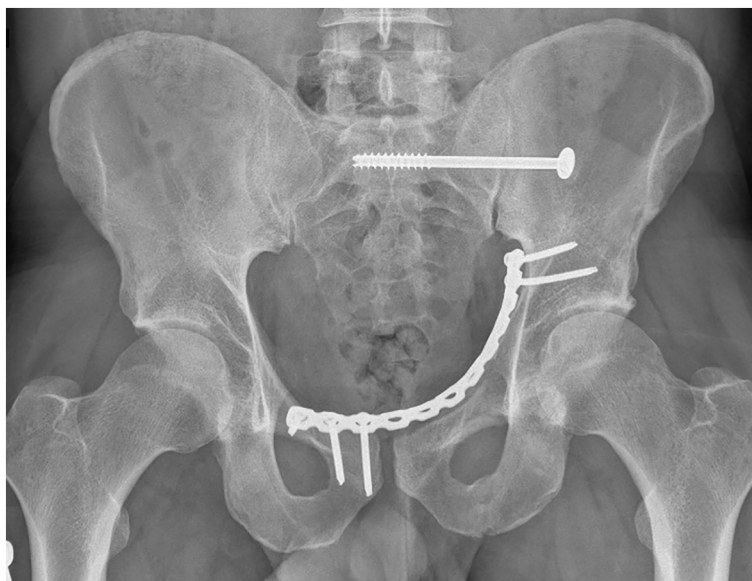


Fig. 3. AP pelvis X-ray 3 months status post open reduction, internal fixation.

bladder. The Foley was removed and the patient passed a voiding trial. At 6-week follow up his fractures were healing well and he had no urinary symptoms. By 4 months after surgery, he had returned to work and has experienced no complications, now 18 months after injury.

Discussion

Pelvic fractures make up approximately 10% of fractures in blunt trauma patients [6,7]. They are particularly important to trauma and orthopaedic surgeons because they indicate major force and have a high rate of associated injuries [6,7]. More than 16% of patients with severe pelvic fractures have intra-abdominal or urogenital injuries, and the bladder and urethra are among the most commonly injured organs [7]. Both pelvic fractures and urogenital injuries are a source of significant healthcare costs and morbidity [6–8]. In the USA, the cost of pelvic fractures is nearly \$1.5 billion annually, and non-renal genitourinary injuries account for an additional \$1 billion [6,8].

Injuries to the bladder range in severity from contusion to bladder rupture (Table 1) [5]. Mechanisms of bladder injury in pelvic trauma include direct penetration by bony fragments, compression, or shearing forces transmitted through ligamentous attachments. Injuries to the bladder neck and urethra as well as combined extra- and intraperitoneal perforation can occur [6]. This case report and those previously identified demonstrate that bladder entrapment in the fracture site is an additional mechanism of injury that must be appreciated. Bladder herniation and entrapment at the pubic symphysis after reduction of a traumatic diastasis has also been reported several times [9].

Trauma surgeons may be the first to recognize genitourinary injury associated with a pelvic fracture during the secondary survey in the trauma bay. Blood at the urethral meatus indicates possible urethral injury and Foley catheter placement is deferred. A retrograde urethrogram is performed to evaluate for urethral injury and a urology consultation should be obtained. In the absence of blood at the urethral meatus, a Foley catheter may be placed. If clear urine is obtained, no further work-up for a urinary tract injury is required. However, gross hematuria warrants further evaluation [5].

Hematuria is a hallmark sign of injury to the bladder and may result from contusion, direct laceration, or rupture [10]. This series of case reports demonstrates that bladder entrapment can present with gross or microscopic hematuria [1–4]. Brewer et al. found that the presence of gross hematuria in blunt trauma patients demonstrated 100% sensitivity and 98.5% specificity for bladder injury [10]. Cystography of the bladder (traditional or CT) is recommended for hemodynamically stable patients with gross hematuria and

Table 1
AAST organ injury severity scale for bladder trauma [5].

Grade	Description of Injury
1	Hematoma + Contusion, partial thickness laceration
2	Extraperitoneal bladder wall laceration < 2 cm
3	Extraperitoneal bladder (> 2 cm) or intraperitoneal (< 2 cm) bladder laceration
4	Intraperitoneal bladder wall laceration > 2 cm
5	Intraperitoneal or extraperitoneal bladder wall laceration extending into the bladder neck or ureteric orifice

either a pelvic ring fracture or a mechanism of injury concerning for bladder injury [5]. More complex injuries to the bladder may require co-management by trauma surgeons, orthopaedic surgeons, and urologic surgeons.

Our patient underwent CT cystogram for gross hematuria which demonstrated bladder entrapment but no perforation. According to the American Association for the Surgery of Trauma (AAST) classification, hematuria without perforation represents a Grade I bladder injury and should be treated non-operatively [5,6]. However, all previously documented cases of bladder entrapment have been managed surgically due to the interaction between the fracture and the bladder [1–4]. Therefore, bladder entrapment is a unique injury because it represents a Grade I bladder injury (typically non-operative) which may benefit from operative management.

Although rare, bladder entrapment by a pelvic ring fracture has now been documented several times. Bladder entrapment is an AAST Grade I injury but trauma surgeons should be aware that these injuries will likely require operative management due to the potential for perforation, delayed perforation, or symptoms of urinary and sexual dysfunction. These injuries represent a unique intersection of orthopaedic and urologic trauma requiring interdisciplinary collaboration and individualized management. Clinicians must maintain a high index of suspicion for urogenital injury in patients with pelvic fractures, and trauma surgeons should be aware of this unique mechanism of bladder injury after blunt trauma.

Conflicts of interest

None.

References

- [1] M.S. Ghuman, S. Kaur, K. Saggar, Urinary bladder herniation into pubic ramus fracture, *Urol. J.* 11 (4) (2014) 1852 <http://www.ncbi.nlm.nih.gov/pubmed/25194091>.
- [2] R. Kumar, D.C. Schaff, E.S. Ostrowski, Entrapped urinary bladder: complication of pelvic trauma, *Urology* 16 (1) (1980) 82–83 <http://www.ncbi.nlm.nih.gov/pubmed/7395017>.
- [3] D.G. Wright, L.L.R. Taitzman, Case report: pelvic and bladder trauma: a case report and subject review, *J. Orthop. Trauma* 10 (5) (1996) 351–354.
- [4] W. Min, R.J. Gaines, H.C. Sagi, Delayed presentation of bladder entrapment secondary to nonoperative treatment of a lateral compression pelvic fracture, *J. Orthop. Trauma* 24 (5) (2010) e44–e48, <https://doi.org/10.1097/BOT.0b013e3181a9ee1d>.
- [5] D.J. Bryk, L.C. Zhao, Guideline of guidelines: a review of urological trauma guidelines, *BJU Int.* 117 (2) (2016) 226–234, <https://doi.org/10.1111/bju.13040>.
- [6] B. Figler, C. Edward Hoffer, W. Reisman, et al., Multi-disciplinary update on pelvic fracture associated bladder and urethral injuries, *Injury* 43 (8) (2012) 1242–1249, <https://doi.org/10.1016/j.injury.2012.03.031>.
- [7] D. Demetriades, M. Karaiskakis, K. Toutouzas, K. Alo, G. Velmahos, L. Chan, Pelvic fractures: epidemiology and predictors of associated abdominal injuries and outcomes, *J. Am. Coll. Surg.* 195 (1) (2002) 1–10 <http://www.ncbi.nlm.nih.gov/pubmed/12113532>.
- [8] E. Zaloshnja, T. Miller, E. Romano, R. Spicer, Crash costs by body part injured, fracture involvement, and threat-to-life severity, United States, 2000, *Accid Anal Prev* 36 (3) (2004) 415–427, [https://doi.org/10.1016/S0001-4575\(03\)00035-6](https://doi.org/10.1016/S0001-4575(03)00035-6).
- [9] R.P. Finnan, M.A. Herbenick, M.J. Prayson, M.C. McCarthy, Bladder incarceration following anterior external fixation of a traumatic pubic symphysis diastasis treated with immediate open reduction and internal fixation, *Patient Saf Surg* 2 (1) (2008) 26, <https://doi.org/10.1186/1754-9493-2-26>.
- [10] M.E. Brewer, R.J. Wilmoth, B.L. Anderson, B.J. Daley, Prospective comparison of microscopic and gross hematuria as predictors of bladder injury in blunt trauma, *Urology* 69 (6) (2007) 1086–1089, <https://doi.org/10.1016/j.urology.2007.02.056>.