



Since January 2020 Elsevier has created a COVID-19 resource centre with free information in English and Mandarin on the novel coronavirus COVID-19. The COVID-19 resource centre is hosted on Elsevier Connect, the company's public news and information website.

Elsevier hereby grants permission to make all its COVID-19-related research that is available on the COVID-19 resource centre - including this research content - immediately available in PubMed Central and other publicly funded repositories, such as the WHO COVID database with rights for unrestricted research re-use and analyses in any form or by any means with acknowledgement of the original source. These permissions are granted for free by Elsevier for as long as the COVID-19 resource centre remains active.



## Case Report

## Serial serum SARS-CoV-2 RNA results in two COVID-19 cases with severe respiratory failure



Tatsuya Kodama <sup>a,\*</sup>, Yuji Kouzaki <sup>b</sup>, Shuichi Kawano <sup>a</sup>, Hirofumi Obinata <sup>c</sup>, Hiroaki Taniguchi <sup>d</sup>, Hisashi Sasaki <sup>a</sup>, Shinichiro Ota <sup>e</sup>, Akihiko Kawana <sup>b</sup>, Kaku Tamura <sup>f</sup>

<sup>a</sup> Division of Pulmonary Medicine, Department of Internal Medicine, Self-Defense Forces Central Hospital, 1-2-24 Ikejiri, Setagaya, Tokyo 154-8532, Japan

<sup>b</sup> Division of Infectious Diseases and Pulmonary Medicine, Department of Internal Medicine, National Defense Medical College, 3-2 Namiki, Tokorozawa, Saitama 359-8513, Japan

<sup>c</sup> Department of Anesthesiology, Self-Defense Forces Central Hospital, 1-2-24 Ikejiri, Setagaya, Tokyo 154-8532, Japan

<sup>d</sup> Department of Emergency, Japan Self Defense Force Sapporo Hospital, 17 Makomanai, Minami, Sapporo 005-8543, Japan

<sup>e</sup> Department of Internal Medicine, Japan Self Defense Forces Hospital, 1776-1 Tauraminatomachi, Yokosuka, Kanagawa 237-0071, Japan

<sup>f</sup> Division of Infectious Disease, Department of Internal Medicine, Self-Defense Forces Central Hospital, 1-2-24 Ikejiri, Setagaya, Tokyo 154-8532, Japan

## ARTICLE INFO

## Article history:

Received 6 April 2020

Received in revised form

6 July 2020

Accepted 13 July 2020

Available online 17 July 2020

## Keywords:

COVID-19

Severe respiratory failure

Serum SARS-CoV-2 RNA

## ABSTRACT

Coronavirus disease 2019 (COVID-19) is spreading worldwide and poses an imminent threat to public health. We encountered 2 cases of COVID-19 with progression resulting in severe respiratory failure and improvement without any specific treatment.

To examine the course of infection, we performed reverse-transcription (RT) polymerase chain reaction assay with serum specimens, and serum SARS-CoV-2 RNA was detected in both cases when body temperature increased and respiratory status deteriorated. We, then examined, retrospectively and prospectively, the clinical course during hospitalization by performing serial examinations of serum SARS-CoV-2 RNA status. The findings from our cases suggest that not only is detection of viremia useful as a predictive marker of severity, but also serial serum SARS-CoV-2 RNA results can be helpful for predicting the clinical course.

© 2020 Japanese Society of Chemotherapy and The Japanese Association for Infectious Diseases. Published by Elsevier Ltd. All rights reserved.

## 1. Introduction

Although about 80% of cases of the novel coronavirus disease 2019 (COVID-19) are thought to be mild, the remaining 20% of cases can progress to severe disease [1]. Possible risk factors for severe COVID-19 are reported to be the presence of underlying comorbidities, older age, high Sequential Organ Failure Assessment (SOFA) score, and laboratory findings including lymphopenia, elevated d-dimer and lactate dehydrogenase [2,3] (see Tables 1 and 2).

According to Huang et al., around 15% of hospitalized COVID-19 patients had RNAemia in Wuhan [1] and detection of SARS-CoV-2 RNA in blood was reported to have a possible correlation with disease severity [4,5]. However, no reports on viremia in COVID-19 which showed the serial serum SARS-CoV-2 RNA results and

clinical courses in COVID-19 have described the serial measurement of serum SARS-CoV-2 RNA result by polymerase chain reaction (PCR) over the clinical course to date. Here we describe the clinical course in 2 critical cases of COVID-19 with severe respiratory failure together with the results of serial PCR measurements of serum SARS-CoV-2 RNA.

## 2. Case report

Storage and use of serum taken from patients was granted by the Research Ethics Office of the Self Defense Forces Central Hospital (approval number: 01–011, approval date: March 5th, 2020). Consent was obtained from patients.

Case 1: A 42-year-old man with no underlying medical conditions was admitted to our hospital after being diagnosed with COVID-19 by RT-PCR assay of an oropharyngeal swab sample performed 2 days earlier. Five days before admission, he had noticed fever, dry cough and arthralgia (Fig. 1-A). On admission

\* Corresponding author.

E-mail address: [kodaaman1986@gmail.com](mailto:kodaaman1986@gmail.com) (T. Kodama).

**Table 1**  
Laboratory results during hospitalization, Case 1 patient, 42-year-old male.

	On admission (day 6 of illness)	Day 11 of illness	Day 13 of illness
Leukocytes, cell/mm <sup>3</sup>	4400	5370	4840
Neutrophils, %	71	75.5	62.4
Lymphocytes, %	23	18	28.5
Erythrocytes, × 10 <sup>4</sup> /μL	533	456	453
Hemoglobin, g/dL	15.1	14.2	13.9
Hematocrit, %	46.9	41.1	41
Platelets, × 10 <sup>4</sup> /μL	17.9	23.2	28.4
Total bilirubin, mg/dL	0.26	0.31	0.35
AST, IU/L <sup>a</sup>	44	67	37
ALT, IU/L <sup>b</sup>	43	50	40
LDH, IU/L <sup>c</sup>	249	419	352
Blood urea nitrogen, mg/dL	18	16	12
Creatinine, mg/dL	1.07	1.06	0.93
C-reactive protein, mg/dL	2.34	7.29	5.1
PT-INR	1.04	1.07	1.07
APTT, sec	38.5	40.6	34.3
D-dimer, μg/mL	<0.5	0.8	0.8
Administered oxygen	None	High flow nasal, 40L, 40%, oxygen	Nasal, 3L, oxygen
Arterial blood gas levels			
PaCO <sub>2</sub> , mmHg <sup>d</sup>	31.9	34.5	35.2
PaO <sub>2</sub> , mmHg <sup>e</sup>	67.2	65.1	96.5
pH	7.48	7.45	7.45
Bicarbonate, mmol/L	23.2	23.2	24
Base excess, mmol/L	-0.2	-1.6	-1.2

<sup>a</sup> Aspartate aminotransferase.<sup>b</sup> Alanine aminotransferase.<sup>c</sup> Lactate dehydrogenase.<sup>d</sup> Arterial carbon dioxide partial pressure.<sup>e</sup> Arterial oxygen partial pressure.

(day 6 of illness), he was febrile (37.6 °C), blood pressure was 130/68 mmHg, and respiratory rate was 20 breaths/min. Oxygen saturation was 94% on room air. Computed tomography (CT) revealed consolidation and ground glass opacity in both lower lobes (Fig. 2).

Respiratory status gradually deteriorated and his body temperature increased to 39 °C on day 8 of his illness. Given that a previous report on viremia in cases of influenza A H1N1/09 described deteriorating respiratory symptoms and/or high fever coinciding with the detection of influenza A H1N1RNA in blood [6], we suspected a correlation with viremia in COVID-19 also. The positive test result was found on examination of serum samples for SARS-CoV-2 RNA by RT-PCR performed in accordance with recommendation by Japan's National Institute of Infectious Disease [7]. We then retrospectively performed RT-PCR of a serum sample that had been collected on admission (day 6 of illness) and stored at -80 °C. The result was negative.

On day 9 of his illness, oxygen saturation could not be maintained under nasal oxygen therapy, so high-flow nasal oxygen therapy was started at 40L/min and 40%, (Fig. 1-A). The RT-PCR result became negative on day 13 (Fig. 1-A), after which respiratory status improved and fever decreased. He was discharged on day 20 after confirming 2 consecutive negative RT-PCR results from oropharyngeal swab samples (Fig. 1-A), in line with the criteria for discharge in Japan. Chest CT findings gradually improved following the seroconversion of viral RNA to negative and improvement of general condition (Fig. 2). During hospitalization, we did not administer any antiviral or steroid therapy but provided only conservative and supportive care such as administering antipyretics and implementing measures to deep vein

**Table 2**  
Laboratory results during hospitalization, Case 2 patient, 78-year-old male.

	On admission (day 3 of illness)	Day 7 of illness	Day 11 of illness
Leukocytes, cell/mm <sup>3</sup>	6670	8140	5960
Neutrophils, %	81.3	85	76.5
Lymphocytes, %	14.5	9	14.5
Erythrocyte × 10 <sup>4</sup> /μL	438	437	417
Hemoglobin, g/dL	14.5	14.2	14.2
Hematocrit, %	42	41	39.5
Platelets, × 10 <sup>4</sup> /μL	17.7	11.5	21.4
Total bilirubin, mg/dL	1.15	1.18	0.64
AST, IU/L <sup>a</sup>	35	49	46
ALT, IU/L <sup>b</sup>	40	50	51
LDH, IU/L <sup>c</sup>	266	342	333
Blood urea nitrogen, mg/dL	20	22	10
Creatinine, mg/dL	1.09	1.09	0.75
C-reactive protein, mg/dL	4.84	8.64	3.41
PT-INR	1.01	1.05	0.98
APTT, sec	37.5	33.2	29.9
D-dimer, μg/mL	2	2	2.3
Administered oxygen	Room air (day 4 of illness)	High flow nasal, 45L, 45%, oxygen	Nasal, 2L, oxygen
Arterial blood gas levels			
PaCO <sub>2</sub> , mm Hg <sup>d</sup>	29.2	28.6	35.2
PaO <sub>2</sub> , mmHg <sup>e</sup>	49.5	79.5	86.9
pH	7.48	7.41	7.45
Bicarbonate, mmol/L	21	17.8	24
Base excess, mmol/L	-1.3	-5.4	-1.6

<sup>a</sup> Aspartate aminotransferase.<sup>b</sup> Alanine aminotransferase.<sup>c</sup> Lactate dehydrogenase.<sup>d</sup> Arterial carbon dioxide partial pressure.<sup>e</sup> Arterial oxygen partial pressure.

thrombosis. No symptoms suspect for recurrence of COVID-19 have been detected since discharge.

Case 2: A 78-year-old man with chronic heart failure by old myocardial infarction and hypertension was admitted to our hospital after being diagnosed with COVID-19. Two days before admission, he had noticed fatigue. On admission (day 3 of his illness), he was febrile (38.0 °C) and had a dry cough (Fig. 1-B). Blood pressure was 120/70 mmHg, respiratory rate was 24 breaths/min and oxygen saturation level was around 93% on room air. Chest CT showed ground glass opacity in both lower lung lobes (Fig. 3). Respiratory condition deteriorated and his body temperature increased to 38.8 °C on day 6 of his illness. RT-PCR for SARS-CoV-2 RNA was performed using a serum sample and the result was found to be positive. We then retrospectively performed RT-PCR of a serum sample that had been collected on admission (day 3 of illness) from the patient and found PCR assay was positive. Subsequently, RT-PCR of serum SARS-CoV-2 RNA was performed prospectively.

On day 7 of illness, respiratory failure progressed and oxygen saturation concentration could not be maintained on nasal oxygen therapy, so we started high-flow nasal oxygen therapy at 40 L and 40%. The RT-PCR result became negative on day 9 (Fig. 1-B), following which respiratory status improved and fever decreased.

We found that the RT-PCR result became negative on day 9 in Case 2 (Fig. 1-B). Chest CT findings also gradually improved (Fig. 3). After we confirmed 2 consecutive negative RT-PCR results from oropharyngeal swab samples, he was discharged on day 22 (Fig. 1-B). During hospitalization, we did not administer any antiviral or steroid therapy. He has had no symptoms suspect for recurrence of COVID-19 after discharge.

## A

Date from onset	1	2	3	4	5	6	7	8	9	10	11	12	13	14	15	16	17	18	19	20
Hospital day						1	2	3	4	5	6	7	8	9	10	11	12	13	14	15 (discharge)
Fever (°C)	unknown	unknown	unknown	unknown	unknown	37.6	37.6	39	40.2	40.1	39.3	40	39.3	36.8	37	37.2	36.8	36.6	36.5	
Fatigue																				
Arthralgia																				
Dry cough																				
Medication								AC	AC	AC	AC	AC	AC							
P/F (PaO <sub>2</sub> /FiO <sub>2</sub> )						320			170			162		301						390
Oxygen therapy	None	None	None	None	None	None	Nasal	Nasal	High flow nasal	High flow nasal	High flow nasal	Mask	Nasal	Nasal	None	None	None	None	None	None
RT-PCR (serum)						-		+				+								
RT-PCR (oro)				+															-	-

## B

Date from onset	1	2	3	5	6	7	8	9	10	11	12	13	14	15	20	21	22
Hospital day			1	2	3	5	6	7	8	9	10	11	12	13	18	19	20 (discharge)
Fever (°C)	unknown	unknown	38	37.8	38.8	39.2	39.6	39.3	37.6	36.8	36.8	36.7		36.5	36.2	36.4	
Fatigue																	
Dry cough																	
Medication					AC	AC	AC	AC									
P/F (PaO <sub>2</sub> /FiO <sub>2</sub> )				235		176				310		305		395			
Oxygen therapy	None	None	None	Nasal	Nasal	High flow nasal	High flow nasal	High flow nasal	Nasal	Nasal	Nasal	Nasal	None	None	None	None	None
RT-PCR (serum)			+		+			-		-							
RT-PCR (oro)		+													-	-	

**Fig. 1.** Clinical courses of 2 case-patients with COVID-19. (A) Case 1 patient, 42-year-old male. (B) Case 2 patient, 78-year-old male. Body temperature is maximum body temperature in a day; AC, Acetaminophen; Oro, oropharyngeal swabs; RT-PCR, reverse transcription PCR.

### 3. Discussion

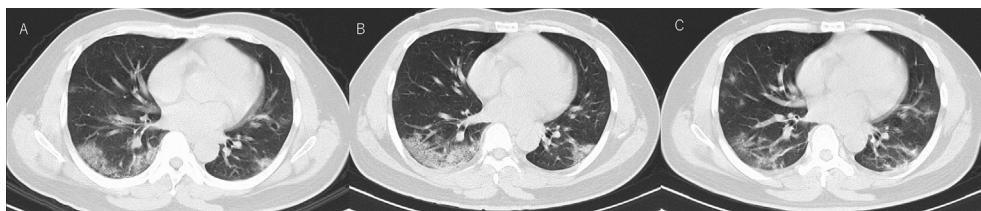
In these 2 cases of COVID-19 with severe respiratory failure, we have described the relationship between serial serum SARS-CoV-2 RNA results and clinical course. In Case 1, PCR-positive serum samples corresponded to worsening of both respiratory condition and laboratory findings, but his general condition improved dramatically (including respiratory status, laboratory findings, and fever) after seroconversion to negative. Similarly, in Case 2, PCR-positive serum samples corresponded to worsening of respiratory status and general condition improved dramatically after seroconversion to negative.

The correlation between COVID-19 infection and elevated cytokine levels, including IL-6, has recently gained attention [8]. IL-6 is thought to be one of the main pro-inflammatory factors in cytokine storm, and cytokine storm is a cause of organ dysfunction [9]. Also, Chen, et al. recently showed a close correlation of markedly elevated IL-6 level with the incidence of RNAemia in COVID-19 patients [5]. In line with this, our cases suggest increased cytokine level caused high fever and deterioration of respiratory condition as evidence of organ dysfunction during the period of seroconversion and/or when there were PCR-positive serum results. The seroconversion to negative would suggest that cytokine level decreased and fever and organ dysfunction also improved with reduction in viral load. Accordingly, physicians should consider the correlation with viremia due to COVID-19 as respiratory condition progressively worsens and fever rises above 38 °C, a status that qualifies as systemic inflammatory response syndrome

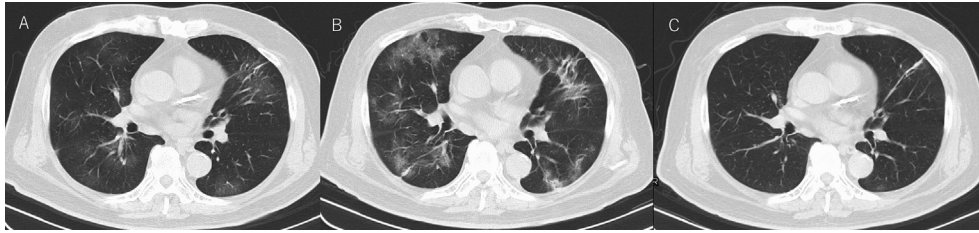
[10]. When progression to respiratory failure without viremia is seen, it is vital to exclude the possibility of a combination of pneumonia caused by other pathogens, cardiac failure, and pulmonary embolism [5,11–13].

We observed a difference in the window period for detection of serum SARS-CoV-2 RNA in our 2 cases, on day 8 of illness in Case 1 and day 3 of illness in Case 2. A recent study of COVID-19 in elderly patients showed that rapid progress of disease was found in the dead patients with median survival time of 5 days after admission and patients with dyspnea, cardiovascular disease and COPD on admission were predictive markers for fatal outcome [14]. It is probable that Case 2 progressed to viremia rapidly as he had a history of old myocardial infarction. However, he recovered with supportive care and conservative care.

Going forward, it is important for clinicians to consider the practical use of serum RT-PCR assay in COVID-19. According to a previous report related to viremia in influenza virus infection, viremia was detected in severe cases only [15]. A recent study of COVID-19 showed that RNAemia cases were seen in the critically ill group which meets at least one of the following conditions, respiratory failure requiring mechanical ventilation, shock and multiple organ failure requiring transfer to the intensive care unit [5]. Considering these factors, serum PCR should be performed for patients with severe disease. In addition, our findings suggest that serum PCR assay may be more useful during high fever and progression of organ dysfunction including respiratory deterioration, which meets the criteria for systemic inflammatory response syndrome during the course of infection [10].



**Fig. 2.** Chest CT images of Case 1 patient during hospitalization: A) Day 8 of his illness, peripheral ground-glass opacity and consolidation on both lower lobes. B) Day 11 of his illness, consolidation on the dorsal side increased in extent. C) Day 17 of his illness, consolidation on dorsal side tend to disappear, however new ground glass opacity appeared on right middle lobe and left S<sup>8</sup>.



**Fig. 3.** Chest CT images of Case 2 patient during hospitalization: A) Day 3 of his illness, ground-glass opacity on both lower lobes and right middle lobe and lingual. B) Day 7 of his illness, ground-glass opacity extended and new consolidation appeared. C) Day 13 of his illness. ground glass opacity and consolidation almost diminished.

Although it remains unclear whether viremia is an indicator of mortality, our 2 cases showed progression to severe acute respiratory failure and critical condition, which supports Chen et al.'s findings that the presence of viremia in COVID-19 is a prognostic indicator of clinical severity [4]. We suggest that detection of viremia in addition to serial serum SARS-CoV-2 RNA measurements can be useful predictive markers for severity and may also be helpful in predicting the clinical course. However, further accumulation of COVID-19 cases with serum SARS-CoV-2 RNA measurements is required to confirm this.

#### Authorship statement

All authors meet the ICMJE authorship criteria. TK reviewed the clinical literature and drafted the initial draft of the manuscript. YK and SK edited the manuscript. HO, HT and HS designed the figure in the manuscript. SO edited the table in the manuscript., AK and KT edited the manuscript and provided intellectual inputs. All authors approved the final version of the manuscript.

#### Declaration of Competing Interest

None.

#### Acknowledgements

We thank Dr. Kazuo Imai and laboratory staff for their contribution to perform RT-PCR.

#### References

- [1] Huang C, Wang Y, Li X, Ren L, Zhao J, Hu Y, et al. Clinical features of patients infected with 2019 novel coronavirus in Wuhan, China. *Lancet* 2020;395:497–506. [https://doi.org/10.1016/S0140-6736\(20\)30183-5](https://doi.org/10.1016/S0140-6736(20)30183-5).
- [2] Wan D, Hu B, Hu C, Zhu F, Liu X, Zhang J, et al. Clinical characteristics of 138 hospitalized patients with 2019 novel coronavirus-infected pneumonia in Wuhan, China. *J Am Med Assoc* 2020;323:1061–9. <https://jamanetwork.com/journals/jama/fullarticle/2761044>.
- [3] Zhou F, Yu T, Du R, Fan G, Liu Y, Liu Z, et al. Clinical course and risk factors for mortality of adult in patients with COVID-19 in Wuhan, China: a retrospective cohort study. *Lancet* 2020;395:1054–62. [https://doi.org/10.1016/S0140-6736\(20\)30566-3](https://doi.org/10.1016/S0140-6736(20)30566-3).
- [4] Chen W, Lan Y, Yuan X, Deng X, Li Y, Cai X, et al. Detectable 2019-nCoV viral RNA in blood is a strong indicator for the further clinical severity. *Emerg Microb Infect* 2020;9:469–73. <https://doi.org/10.1080/22221751.2020.1732837>.
- [5] Chen X, Zhao B, Qu Y, Chen Y, Xiong J, Fen Y, et al. Detectable serum SARS-CoV-2 viral load (RNAemia) is closely correlated with drastically elevated interleukin 6 (IL-6) level in critically ill COVID-19 patients. *Clin Infect Dis* 2020:ciaa449. <https://doi.org/10.1093/cid/ciaa449>.
- [6] Matthew O, Andre D, Denny L, Hugues C, Marc A, Marc M, et al. Evidence of viremia in 2 cases of severe pandemic influenza A H1N1/09. *Diagn Microbiol Infect Dis* 2011;70:213–7. <https://doi.org/10.1016/j.diagmicrobio.2010.12.013>.
- [7] Nagamori N, Shirato K, Katano H, Matsuyama S, Makoto T. Detection of second case of 2019-nCoV infection in Japan. National Institute of Infectious Diseases. [https://www.niid.go.jp/niid/images/vir3/nCoV/method-20200123-2\\_erratum.pdf](https://www.niid.go.jp/niid/images/vir3/nCoV/method-20200123-2_erratum.pdf). [Accessed 1 March 2020].
- [8] John BM, Carl HJ. Cytokine release syndrome in severe COVID-19. *Science* 2020;368:473–4. <http://science.sciencemag.org/content/368/6490/473>.
- [9] Tanaka T, Narazaki M, Kishimoto T. IL-6 in inflammation, immunity, and disease. *Cold Spring Harb Perspect Biol* 2014;6:a016295. <https://cshperspectives.cshlp.org/content/6/10/a016295.full>.
- [10] Bone R, Balk R, Cerra F, Dellinger R, Fein A, Knaus W, et al. Definitions for sepsis and organ failure and guidelines for the use of innovative therapies in sepsis. The ACCP/SCCM consensus conference committee. American college of chest physicians/society of critical care medicine. *Chest* 1992;101:1644–55. <https://doi.org/10.1378/chest.101.6.1644>.
- [11] Philipp K, Oliver C, Bernd B, Fabian D, Dennis A, Frieder F, et al. COVID-19 associated pulmonary aspergillosis. *Mycoses* 2020;63:528–34. <https://doi.org/10.1111/myc.13096>.
- [12] Robert B, Gregg F, Patric O, Clyde Y. Association of coronavirus disease 2019 (COVID-19) with myocardial injury and mortality. *JAMA Cardiol* 2020. <https://doi.org/10.1001/jamacardio.2020.1105>.
- [13] Klok F, Kruip M, van der Meer N, Arbous M, Gommers D, Kant K, et al. Incidence of thrombotic complications in critically ill ICU patients with COVID-19. *Thromb Res* 2020;191:145–7. <https://doi.org/10.1016/j.thromres.2020.04.013>.
- [14] Wang L, He W, Yu X, Hu D, Bao M, Liu H, et al. Coronavirus disease 2019 in elderly patients: characteristics and prognostic factors based on 4-week follow-up. *J Infect* 2020;80:639–45. <https://doi.org/10.1016/j.jinf.2020.03.019>.
- [15] To K, Hung I, Li I, Lee K, Koo C, Yan W, et al. Delayed clearance of viral load and marked cytokine activation in severe cases of pandemic H1N1 2009 influenza virus infection. *Clin Infect Dis* 2010;50:850–9. <https://doi.org/10.1086/650581>.