

A Phase II Trial of Pazopanib in Patients with Metastatic Alveolar Soft Part Sarcoma

MISO KIM,^a TAE MIN KIM,^a BHUMSUK KEAM,^a YU JUNG KIM,^b JIN CHUL PAENG,^c KYUNG CHUL MOON,^d DONG-WAN KIM,^a DAE SEOG HEO^a

^aDepartment of Internal Medicine, Seoul National University Hospital, Seoul National University Cancer Research Institute, Seoul National University College of Medicine, Seoul, Korea; ^bDepartment of Internal Medicine, Seoul National University Bundang Hospital, Seoul National University College of Medicine, Seongnam, Korea; Departments of ^cNuclear Medicine and ^dPathology, Seoul National University Hospital, Seoul National University College of Medicine, Seoul, Korea

TRIAL INFORMATION

- **ClinicalTrials.gov Identifier:** NCT02113826
- **Sponsor(s):** Tae Min Kim
- **Principal Investigator:** Tae Min Kim
- **IRB Approved:** Yes

LESSONS LEARNED

- Pazopanib shows a modest efficacy in metastatic alveolar soft part sarcoma.
- Clinical outcomes were comparable to those in previous studies using antiangiogenic drugs.
- Further prospective studies evaluating the benefit of pazopanib in alveolar soft part sarcoma with a larger sample are warranted to validate results.

ABSTRACT

Background. Alveolar soft part sarcoma (ASPS) is a rare mesenchymal malignant tumor characterized by an unbalanced translocation, t(X;17)(p11.2;q25), which leads to the fusion of *ASPC1* to the *TFE3* transcription factor. Because this results in the upregulation of angiogenesis-related transcripts, antiangiogenic drugs have been used in ASPS patients.

Methods. This open-label, single-arm, multicenter, investigator-initiated phase II trial was designed to evaluate efficacy and safety of pazopanib 800 mg once daily in patients with metastatic ASPS. The primary endpoint was investigator-assessed overall response rate (ORR), and secondary endpoints were toxicity, progression-free survival (PFS), and overall survival (OS). ⁶⁸Ga-RGD (Arg-Gly-Asp) positron emission tomography (PET) scan and gene

expression profiling using NanoString platform were performed for biomarker analysis.

Results. Six patients with histologically confirmed metastatic ASPS were enrolled between December 2013 and November 2014. Among six patients, one achieved a partial response (PR) (ORR 16.7%) and five patients showed stable disease (SD). With a median follow-up of 33 months (range 18.7–39.3 months), median PFS was 5.5 months (95% confidence interval [CI] 3.4–7.6 months), and median OS was not reached. There were no severe toxicities except one patient with grade 3 diarrhea.

Conclusion. Pazopanib showed modest antitumor activity with manageable toxicities for patients with metastatic ASPS. *The Oncologist* 2019;24:20–e29

DISCUSSION

ASPS is a rare histological subtype of soft-tissue sarcomas (STS). It shows a poor prognosis in the metastatic setting, and the standard chemotherapy regimens do not improve treatment outcomes. Several antiangiogenic drugs have been studied in metastatic ASPS patients.

We performed an open-label, single-arm, phase II study to evaluate the efficacy and safety of pazopanib in patients with metastatic ASPS. We included patients who met the

following key eligibility criteria: age ≥18 years; histologically confirmed diagnosis of metastatic or unresectable ASPS confirmed by positive immunostaining for TFE3; treatment-naïve or received prior chemotherapy except vascular endothelial growth factor (VEGF) inhibitors. Six patients were enrolled into this trial. The median number of cycles administered was 7.5 (range 6–21), with a median follow-up duration of 33 months (range 18.7–39.3 months). The

Correspondence: Tae Min Kim, M.D., Ph.D., Department of Internal Medicine, Seoul National University Hospital, Seoul National University Cancer Research Institute, Seoul National University College of Medicine, 101 Daehak-ro, Jongno-gu, 03080, Seoul, Korea. Telephone:82-2-2072-3559; e-mail: gabriel9@snu.ac.kr Received June 2, 2018; accepted for publication July 24, 2018; published Online First on September 25, 2018. © AlphaMed Press; the data published online to support this summary is the property of the authors. <http://dx.doi.org/10.1634/theoncologist.2018-0464>

Table 1. Patients' characteristics and treatment outcomes

Characteristics	Patient 1	Patient 2	Patient 3	Patient 4	Patient 5	Patient 6
Age/Sex	33/Male	28/Male	36/Male	31/Female	23/Female	28/Female
ECOG PS	1	1	1	0	1	0
Location of primary tumor	Lower extremity	Lung	Lower extremity	Pelvis	Lower extremity	Upper extremity
Metastatic sites	Lung, bone, brain	Lung	Lung	Liver, lymph nodes	Lung, bone	Lung
Previous surgery	yes	yes	yes	yes	yes	yes
Number of prior chemotherapy regimens	0	1	2	0	0	0
Best response to pazopanib	SD	SD	SD	PR	SD	SD
PFS, months	8.0	5.5	20.3	5.5	22.2	5.4
OS, months	17.1	37.8	36.2	32.0	33.9	31.1

Abbreviations: ECOG PS, Eastern Cooperative Oncology Group performance status; PFS, progression-free survival; PR, partial response; OS, overall survival; SD, stable disease.

baseline characteristics are presented in Table 1. One patient (16.7%) achieved PR after two cycles of pazopanib treatment. The remaining five (83.3%) showed SD during the treatment (tumor reduction, mean \pm standard deviation, $9.4 \pm 13.1\%$). The median PFS was 5.5 months (95% CI 3.4–7.6 months), and the 6-month PFS rate was 50%. Among four patients with SD, there was one patient (patient 3) who showed disease stabilization over the long period of time. She was 23 years of age and diagnosed with ASPS with metastases to the lung and bone. As shown in Figure 1, computed tomography (CT) scan during pazopanib treatment showed clinical improvement, and the value of maximal standardized uptake value measured on ^{68}Ga -RGD PET/CT was also slightly decreased. The period of disease stabilization lasted 22 months. Treatment was

discontinued for all six patients due to disease progression, and two patients died of disease progression.

The most common treatment-related toxicities were diarrhea (100%) and abdominal pain (50%; Adverse events table). There were no severe toxicities except one patient with grade 3 diarrhea.

To our knowledge, clinical outcomes in our study were comparable to those in previous studies in metastatic ASPS using antiangiogenic TKIs. However, our study was closed early because of the low accrual rate that was attributable to the rarity of the subtype (<1% of STS). In addition, a wait-and-see policy was adopted in ASPS patients who showed stable or slow-growing metastases. Further large-scale, prospective studies evaluating the efficacy of pazopanib in ASPS are warranted.

TRIAL INFORMATION

Disease	Sarcomas – Adult
Stage of Disease/Treatment	Metastatic/advanced
Prior Therapy	No designated number of regimens
Type of Study - 1	Phase II
Type of Study - 2	Single arm
Primary Endpoint	Overall response rate
Secondary Endpoint	Progression-free survival
Secondary Endpoint	Progression-free survival at 6 months
Secondary Endpoint	Overall survival
Secondary Endpoint	Toxicity
Additional Details of Endpoints or Study Design	Simon's two-stage minimax design was used to evaluate a null hypothesis of an ORR <15% versus an alternative hypothesis of $\geq 40\%$ ORR, with a significance level of 0.05 and a power of 0.80. The target accrual was nine patients in the first stage. If ≥ 2 responders were observed, then an additional 10 patients would be enrolled in the second stage.
Investigator's Analysis	Active but results overtaken by other developments

DRUG INFORMATION

Drug 1	
Generic/Working Name	Pazopanib

Trade Name	Votrient
Company Name	Novartis
Drug Type	Small molecule
Drug Class	VEGF receptor
Dose	800 mg per flat dose
Route	p.o.
Schedule of Administration	800 mg once daily administered continuously in 4-week interval per cycle

PATIENT CHARACTERISTICS

Number of Patients, Male	3
Number of Patients, Female	3
Stage	Metastatic
Age	Median (range): 29.5 (23–36)
Number of Prior Systemic Therapies	Median (range): 0 (0–2)
Performance Status: ECOG	0 – 2 1 – 4 2 – 0 3 – 0 Unknown –
Other	Previous surgery: 6
Cancer Types or Histologic Subtypes	Alveolar soft part sarcoma: 6

PRIMARY ASSESSMENT METHOD

Number of Patients Screened	7
Number of Patients Enrolled	6
Number of Patients Evaluable for Toxicity	6
Number of Patients Evaluated for Efficacy	6
Evaluation Method	RECIST 1.1
Response Assessment CR	<i>n</i> = 0 (0%)
Response Assessment PR	<i>n</i> = 1 (16.7%)
Response Assessment SD	<i>n</i> = 5 (83.3%)
Response Assessment PD	<i>n</i> = 0 (0%)
(Median) Duration Assessments PFS	5.5 months, CI: 3.4–7.6
Outcome Notes	Median OS was not reached.

ADVERSE EVENTS

All Dose Levels, All Cycles							
Name	NC/NA	1	2	3	4	5	All grades
Fatigue	67%	33%	0%	0%	0%	0%	33%
Anorexia	83%	17%	0%	0%	0%	0%	17%
Nausea	83%	17%	0%	0%	0%	0%	17%
Vomiting	83%	17%	0%	0%	0%	0%	17%
Abdominal pain	50%	50%	0%	0%	0%	0%	50%
Diarrhea	0%	67%	17%	17%	0%	0%	100%
Mucositis oral	83%	17%	0%	0%	0%	0%	17%
Palmar-plantar erythrodysesthesia syndrome	83%	17%	0%	0%	0%	0%	17%

Neutrophil count decreased	83%	0%	17%	0%	0%	0%	17%
Hypertension	67%	0%	33%	0%	0%	0%	33%
Proteinuria	83%	0%	17%	0%	0%	0%	17%
Headache	83%	17%	0%	0%	0%	0%	17%

Adverse events observed in any patient during any cycle.

Abbreviation: NC/NA, no change from baseline/no adverse event.

ASSESSMENT, ANALYSIS, AND DISCUSSION

Completion	Study terminated before completion
Terminated Reason	Did not fully accrue
Investigator's Assessment	Active but results overtaken by other developments

Alveolar soft part sarcoma (ASPS) is a very rare and distinct histologic soft-tissue sarcoma (STS), mainly arising in adolescents and young adults [1]. Despite its relatively slow progression, ASPS exhibits a very high propensity for metastases to other organs, typically the lung and the brain [2]. Conventional cytotoxic chemotherapy has not proved effective for the treatment of ASPS. Instead, surgical therapy is still the mainstay of treatment and ensures chance for long-term survival [3, 4]. Microarray gene expression analysis and in vitro preclinical studies reported the markedly elevated expression of several genes involved in angiogenesis, including vascular endothelial growth factor (*VEGF*), *ANGPTL2*, *HIF-1 α* , *MDK*, *c-MET*, and *TIMP-2*, in ASPS tumors [5, 6]. The lack of therapeutic alternatives in metastatic ASPS, its highly vascular property, and the abnormal expression of genes related to angiogenesis prompted us to test the possible therapeutic activity of antiangiogenic drugs.

Pazopanib, a small molecule tyrosine kinase inhibitor, exhibits selective activity against VEGF receptors [7]. In a recent phase III study in metastatic STS (PALETTE), the median progression-free survival (PFS) in patients receiving pazopanib was improved to 4.6 months compared with 1.6 months in patients receiving placebo [8]. However, the number of ASPS patients included in this trial was too small to evaluate its efficacy in this tumor type. Therefore, we designed this phase II study to assess the clinical efficacy and safety of pazopanib in patients with metastatic ASPS.

In the present study, we observed modest clinical benefit with pazopanib—with one (16.7%) and five patients (83%) with metastatic ASPS having partial response and stable disease (SD), respectively. The tumors of patients with SD remained stable for at least 4 months. Among four patients with SD, there was one patient who experienced disease stabilization for 22 months. The efficacy achieved in our study was comparable to that reported in previous phase II and III studies with pazopanib in patients with metastatic ASPS [8, 9]. Other drugs targeting the angiogenic pathways have also been investigated in ASPS. These include sunitinib, cediranib, dasatinib, and bevacizumab. The clinical benefit of sunitinib has been encouraging, based on a series of retrospective studies with median PFS ranging from 17 to 41 months, and the median OS ranging from 19 to 56 months [10–12]. Cediranib has also demonstrated encouraging efficacy in a phase II trial with an objective

response rate of 35% and a disease control rate of 84% at 24 weeks [13]. Also, >10% of the ASPS patients treated with dasatinib showed disease stabilization for >1 year [14]. Finally, Azizi et al. reported that bevacizumab, a monoclonal antibody blocking VEGF- α , induced tumor regression in a patient with metastatic ASPS [15]. To date, sunitinib seems to provide the most promising results for the treatment of metastatic ASPS compared with other antiangiogenic drugs (Table 2). However, it needs to be further validated by a prospective study on a larger scale before being recommended as the standard treatment for metastatic ASPS.

It is of note that stabilization of the disease was the most frequent response observed between 53% and 83% for patients treated with TKIs, including those receiving pazopanib in our study [10, 11, 13]. This is not surprising in that antiangiogenic TKIs target the angiogenesis signaling pathways on the endothelial cells rather than tumor itself. In this aspect, one could speculate that TKIs might have some limited benefit in their clinical efficacy due to their indirect mode of action. However, Stacchiotti et al. demonstrated the direct antitumor effect of sunitinib in short-term ASPS cultures [11]. Pazopanib also has antitumor activity in tumor xenografts derived from non-ASPS tumor cells [16]. Therefore, it is likely that the spectrum for activity of these multitargeted TKIs might be so broad as to inhibit both angiogenesis and tumor cell growth. Although the action mechanism of pazopanib is mediated via VEGF pathway, the underlying biological processes need to be addressed. In an effort to identify these key mediators, we analyzed the transcriptome of ASPS following the treatment with pazopanib. We analyzed the pretreatment and postprogression paired samples from three patients using the NanoString gene expression array. Using a *p* value <.05, we selected the top 41 differentially expressed genes (DEGs) between pretreatment and postprogression samples. DEGs with the greatest differential expression were the components of signaling pathways such as mitogen-activated protein kinase, phosphoinositide 3-kinase, and wingless-type MMTV integration site family (Fig. 2). We also identified 10 up- or down-regulated DEGs related to angiogenesis. Our result indicates that pazopanib might modulate multiple signaling pathways in a simultaneous manner.

In conclusion, this study demonstrates that pazopanib has modest efficacy with tolerable toxicity in metastatic

ASPS. However, our study had several limitations due to the rarity of the disease inherent to ASPS. First, this was a small population size of six patients due to an early closure. Second, our result on the efficacy of pazopanib should be interpreted with caution given that the spontaneous stabilization could occur in ASPS due to its indolent biology. Therefore, a larger, future study will be necessary to accrue a significant number of patients to validate the clinical benefit of pazopanib in patients with metastatic ASPS.

REFERENCES

- Zarrin-Khameh N, Kaye KS. Alveolar soft part sarcoma. *Arch Pathol Lab Med* 2007;131:488–491.
- Jaber OI, Kirby PA. Alveolar soft part sarcoma. *Arch Pathol Lab Med* 2015;139:1459–1462.
- Pappo AS, Parham DM, Cain A et al. Alveolar soft part sarcoma in children and adolescents: Clinical features and outcome of 11 patients. *Med Pediatr Oncol* 1996;26:81–84.
- van Ruth S, van Coevorden F, Peterse JL et al. Alveolar soft part sarcoma. A report of 15 cases. *Eur J Cancer* 2002;38:1324–1328.
- Kenney S, Vistica DT, Stockwin LH et al. ASPS-1, a novel cell line manifesting key features of alveolar soft part sarcoma. *J Pediatr Hematol Oncol* 2011;33:360–368.
- Stockwin LH, Vistica DT, Kenney S et al. Gene expression profiling of alveolar soft-part sarcoma (ASPS). *BMC Cancer* 2009;9:22.
- Schutz FA, Choueiri TK, Sternberg CN. Pazopanib: Clinical development of a potent anti-angiogenic drug. *Crit Rev Oncol Hematol* 2011;77:163–171.
- van der Graaf WT, Blay JY, Chawla SP et al. Pazopanib for metastatic soft-tissue sarcoma (PALETTE): A randomised, double-blind, placebo-controlled phase 3 trial. *Lancet* 2012;379:1879–1886.
- Sleijfer S, Ray-Coquard I, Papai Z et al. Pazopanib, a multikinase angiogenesis inhibitor, in patients with relapsed or refractory advanced soft tissue sarcoma: A phase II study from the European Organisation for Research and Treatment of Cancer-soft tissue and bone sarcoma group (EORTC study 62043). *J Clin Oncol* 2009;27:3126–3132.
- Jagodzinska-Mucha P, Switaj T, Kozak K et al. Long-term results of therapy with sunitinib in metastatic alveolar soft part sarcoma. *Tumori* 2017;103:231–235.
- Stacchiotti S, Negri T, Zaffaroni N et al. Sunitinib in advanced alveolar soft part sarcoma: Evidence of a direct antitumor effect. *Ann Oncol* 2011;22:1682–1690.
- Li T, Wang L, Wang H et al. A retrospective analysis of 14 consecutive Chinese patients with unresectable or metastatic alveolar soft part sarcoma treated with sunitinib. *Invest New Drugs* 2016;34:701–706.
- Kummar S, Allen D, Monks A et al. Cediranib for metastatic alveolar soft part sarcoma. *J Clin Oncol* 2013;31:2296–2302.
- Schuetze SM, Bolejack V, Choy E et al. Phase 2 study of dasatinib in patients with alveolar soft part sarcoma, chondrosarcoma, chordoma, epithelioid sarcoma, or solitary fibrous tumor. *Cancer* 2017;123:90–97.
- Azizi AA, Haberler C, Czech T et al. Vascular-endothelial-growth-factor (VEGF) expression and possible response to angiogenesis inhibitor bevacizumab in metastatic alveolar soft part sarcoma. *Lancet Oncol* 2006;7:521–523.
- Kumar R, Knick VB, Rudolph SK et al. Pharmacokinetic-pharmacodynamic correlation from mouse to human with pazopanib, a multikinase angiogenesis inhibitor with potent antitumor and antiangiogenic activity. *Mol Cancer Ther* 2007;6:2012–2021.

ACKNOWLEDGMENTS

This study was supported by GlaxoSmithKline and Novartis Pharmaceuticals Corporation. Pazopanib is an asset of Novartis AG as of March 2, 2015. Medical writing assistance was provided by Seonah Ha, Ph.D.

DISCLOSURES

Dong-Wan Kim: Pfizer, Merck Sharp & Dohme (C/A). The other authors indicated no financial relationships.

(C/A) Consulting/advisory relationship; (RF) Research funding; (E) Employment; (ET) Expert testimony; (H) Honoraria received; (OI) Ownership interests; (IP) Intellectual property rights/inventor/patent holder; (SAB) Scientific advisory board

FIGURES AND TABLES

Table 2. Comparison of published studies of tyrosine kinase inhibitors for advanced ASPS

	Present study	Jagodzińska-Mucha et al. [10]	Kummar et al. [13]	Schuetze et al. [14]
Regimen	Pazopanib 800 mg once daily	Sunitinib 37.5 mg once daily	Cediranib 30 mg once daily	Dasatinib 100 mg twice daily
Number of ASPS patients	6	15	43	12
Study nature	Prospective phase II	Retrospective	Prospective phase II	Prospective phase II
Response rate, %	16.7	40	35	8
Median OS, months	Not reached	56	—	—
Median PFS, months	5.5 (6-month PFS rate 50%)	19	—	11 (6-month PFS rate 62%)

Abbreviations: —, no data; ASPS, alveolar soft part sarcoma; OS, overall survival; PFS, progression-free survival.

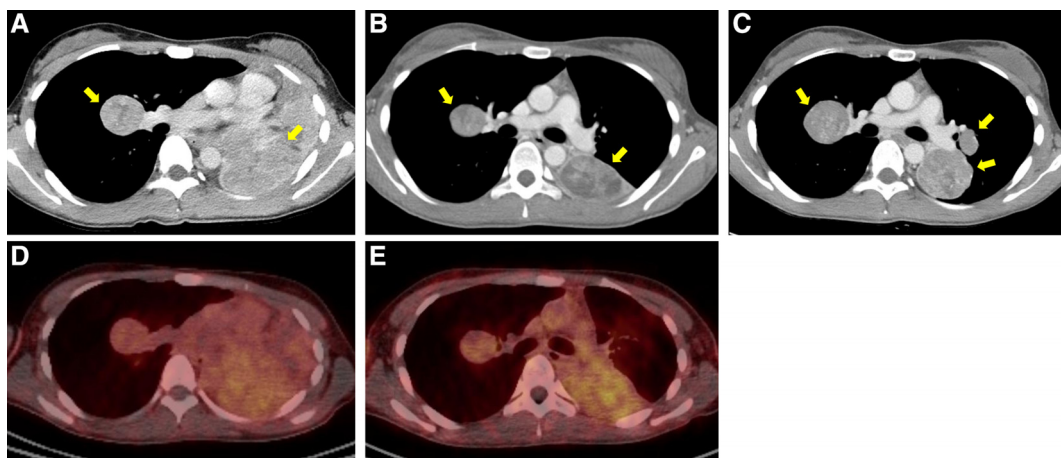


Figure 1. Computed tomography (CT) scan and ^{68}Ga -RGD positron emission tomography-CT scan of patient 3. CT scan before treatment (A), after 2 months of pazopanib treatment (B), and at disease progression (C). ^{68}Ga -RGD PET/CT before treatment (D) and after 14 days of pazopanib treatment (E).

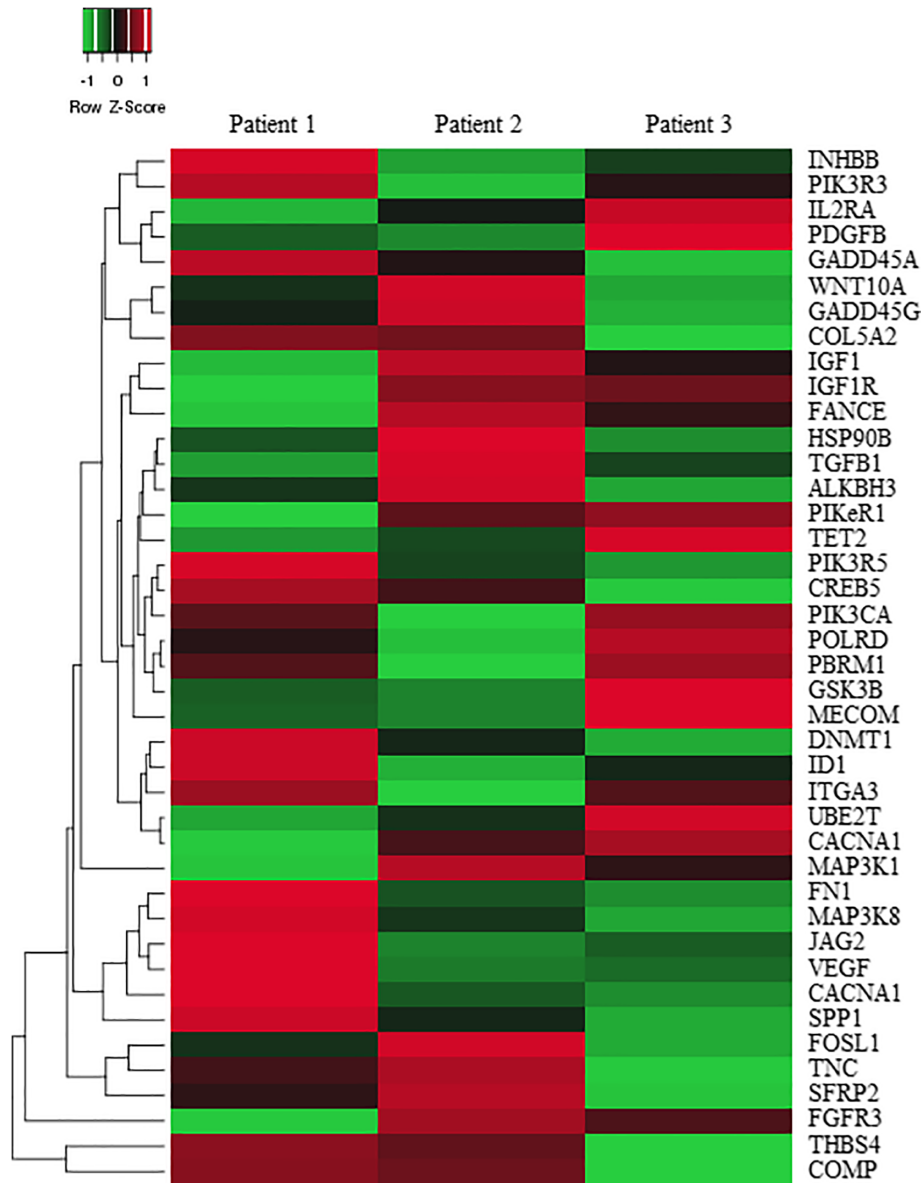


Figure 2. Heatmap illustrating the differential expression of 41 genes.

[Click here to access other published clinical trials.](#)