

Innominate artery pseudoaneurysm from a Salter-Harris fracture of the sternoclavicular joint

Emily Y. Fan, MD,^a Santiago Abrill Zegarra, BS,^b Jennifer Walker, MD,^c Errol Mortimer, MD,^d and Jessica P. Simons, MD, MPH,^a *Worcester and Amherst, MA*

ABSTRACT

Fractures and dislocations of the sternoclavicular joint (SCJ) are uncommon, accounting for <5% of all shoulder girdle injuries. They are relatively more common in the pediatric population than in the adult population and can often present concurrently as a posteriorly displaced medial clavicular dislocation with a fracture through the unfused physis. It is especially important to recognize this injury, because its management and potential sequelae are very different from those for fractures of the clavicle shaft. This type of injury frequently requires closed or open operative management because fracture-dislocation of the SCJ can be associated with potentially serious complications such as pneumothorax, brachial plexus injury, vagus nerve injury, tracheal injury, and vascular compromise. Few case reports describe fracture-dislocation of the SCJ resulting in vascular injuries. We describe the case of a 17-year-old boy who sustained a blunt hockey injury resulting in a right physeal fracture-dislocation of the SCJ causing an innominate artery pseudoaneurysm. This was treated with excision of the pseudoaneurysm, bovine pericardial patch angioplasty repair of the innominate artery, and open reduction and internal fixation of the medial clavicular physeal fracture. (J Vasc Surg Cases Innov Tech 2024;10:101405.)

Keywords: Bovine pericardial patch; Innominate artery; Pseudoaneurysm; Salter-Harris fracture; Sternoclavicular joint

Injuries to the sternoclavicular joint (SCJ) are rare among orthopedic injuries but are most commonly seen in young adults.¹ They often occur due to high-energy forces to the shoulder, such as blunt trauma or sports-related activities. SCJ injuries typically present as an isolated dislocation of the joint without associated fracture of the clavicle or manubrium. However, in patients with an unfused medial clavicle physis, SCJ injuries can present as a fracture-dislocation through the unfused physis,² with a Salter-Harris type fracture. Posterior displacement of the clavicle is far less common than anterior displacement with this injury.³ These fractures as a whole are often difficult to diagnose. They can be occult on radiography and computed tomography (CT), because the medial clavicle epiphysis does not usually begin to ossify until ~16 to 19 years of age.⁴ However, an accurate diagnosis is crucial because (1) closed reductions are often insufficient to treat the physeal fracture; and (2) posterior displacement, when it does occur,

requires investigation of potential concomitant injuries to mediastinal structures such as the great vessels, brachial plexus, and trachea.⁵

Vascular complications from SCJ injuries are rare but have been reported.^{6,7} The proximity of the great vessels to a posteriorly displaced clavicle can lead to vascular injuries, such as bleeding, aneurysm or pseudoaneurysm formation, compression, transection, or thrombosis. We describe a case of an innominate artery pseudoaneurysm with thrombus and distal embolization due to a posteriorly displaced sternoclavicular Salter-Harris fracture-dislocation. The patient's parent provided written informed consent for the report of his case details and imaging studies.

CASE REPORT

A 17-year-old boy presented to our emergency department with acute onset left upper extremity weakness and left-sided facial droop that occurred at hockey practice with no immediately preceding trauma. Two weeks prior, however, he was body-checked to the right shoulder during a hockey game. The findings from a chest radiograph at an urgent care center were reportedly negative, and he returned to playing hockey after 2 days with no notable symptoms until the day of presentation to the emergency department. On examination, his temperature was 36.7°C, pulse rate, 114 bpm, and blood pressure, 124/64 mm Hg. His neurologic examination was notable for a mild persistent left facial droop with forehead sparing, and his strength was 5 of 5 for all four extremities. The laboratory blood test results demonstrated a white blood cell count of 17,500/ μ L; all other values were within normal limits. CT angiography demonstrated a 1.8-cm maximum diameter amorphous hyperdensity abutting the anterior aspect of the innominate artery, suggesting a pseudoaneurysm or contained rupture (Fig 1).

From the Division of Vascular and Endovascular Surgery, University of Massachusetts Chan Medical School, Worcester^a; the University of Massachusetts Amherst, Amherst^b; the Division of Cardiac Surgery,^c and Department of Orthopedic Surgery,^d University of Massachusetts Chan Medical School, Worcester.

Correspondence: Jessica P. Simons, MD, MPH, Division of Vascular and Endovascular Surgery, University of Massachusetts Chan Medical School, 55 Lake Ave N, Worcester, MA 01655 (e-mail: jessica.simons@umassmemorial.org).

The editors and reviewers of this article have no relevant financial relationships to disclose per the Journal policy that requires reviewers to decline review of any manuscript for which they may have a conflict of interest.

2468-4287

© 2024 The Authors. Published by Elsevier Inc. on behalf of Society for Vascular Surgery. This is an open access article under the CC BY-NC-ND license (<http://creativecommons.org/licenses/by-nc-nd/4.0/>).

<https://doi.org/10.1016/j.jvscit.2023.101405>

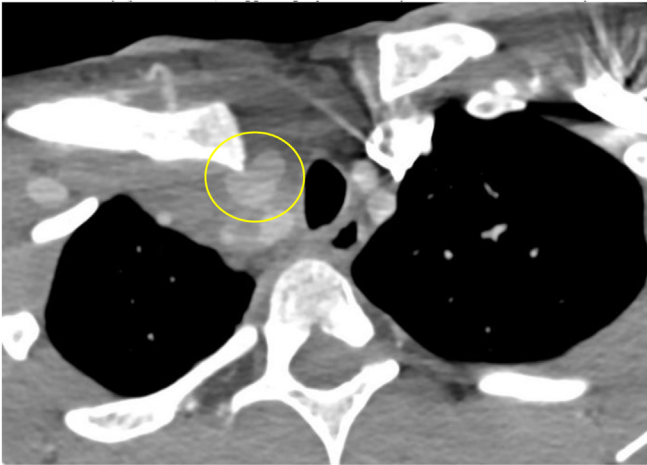


Fig 1. Computed tomography angiogram showing a 1.8-cm maximum diameter amorphous hyperdensity abutting the anterior aspect of the innominate artery (yellow circle), suggesting a pseudoaneurysm of the innominate artery.

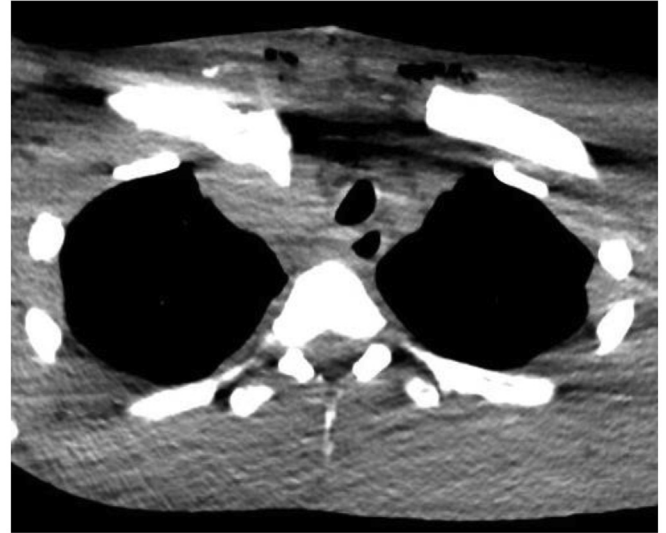


Fig 3. Computed tomography angiogram showing a Salter-Harris I fracture of the right clavicular head with 1.5 cm of posterior dislocation and evidence of bone resorption and healing and surrounding contusion/hematoma.

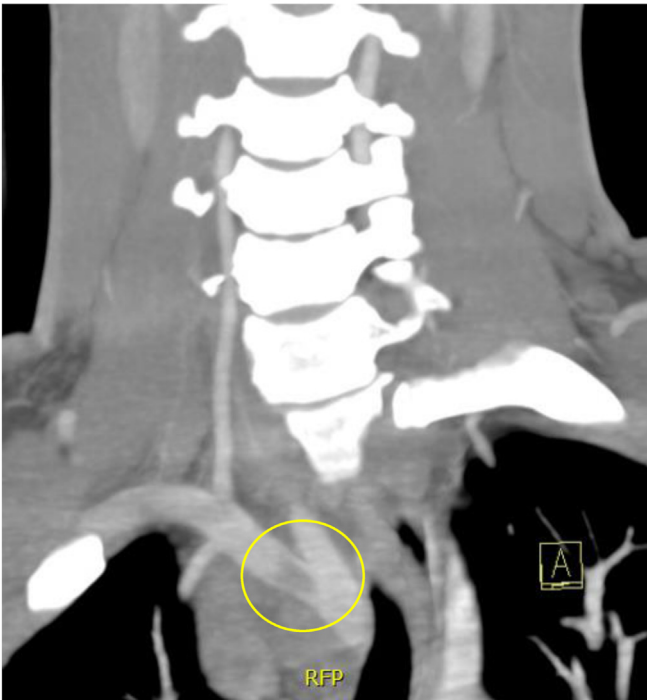


Fig 2. Computed tomography angiogram showing thrombus (yellow circle) within the right subclavian artery distal to the pseudoaneurysm.

Additionally, there was thrombus noted at the bifurcation of the subclavian artery and right common carotid artery (Fig 2). Finally, there was a Salter-Harris I fracture of the right clavicular head with 1.5 cm of posterior dislocation and evidence of bone resorption and healing and surrounding contusion/hematoma (Fig 3).

The patient was taken for multidisciplinary operative repair of his innominate artery pseudoaneurysm with vascular and

cardiac surgery. This was performed via a median sternotomy. The proximal innominate artery was identified and encircled with a vessel loop. The dissection was difficult due to both the extensive inflammation and the distortion of the anatomy from the posteriorly displaced clavicular head. Considerable effort was required to anteriorly retract the clavicle off the pseudoaneurysm; this maneuver disrupted the hemostasis of the injury. Manual hemostasis with a finger on the injury was required to continue careful dissection and, ultimately, control the right common carotid artery and subclavian artery distal to the injury. It was not possible to identify and control the vertebral artery. The site of injury was focal, measuring 3 mm × 2 mm, just proximal to the bifurcation on the anterior surface of the innominate artery. A Fogarty embolectomy catheter was passed into the subclavian artery without return of thrombus. The radial pulse was confirmed to be palpable at the right wrist. The innominate artery wall was resected to healthy tissue and repaired with a small bovine pericardial patch. Orthopedic surgery was consulted intraoperatively to evaluate the Salter-Harris fracture-dislocation of the SCJ and opted for delayed surgical management. Three chest tubes were placed, and the sternum was closed. The patient was extubated in the operating room and was neurologically intact with a palpable right radial pulse. Postoperatively, he recovered well with no complications. He was instructed to take aspirin 81 mg daily. By postoperative day 3, the chest tubes were removed, and he was discharged home. His 1-month CT scan demonstrated an intact repair.

Approximately 6 weeks postoperatively, the patient returned for definitive surgical management of his Salter-Harris fracture-dislocation of the SCJ. He underwent open reduction and internal fixation surgery of the SCJ with orthopedic surgery. The medial clavicle, which was found to be posteriorly and superiorly

dislocated, was suture anchored to the articular surface. The entire SCJ was then reapproximated and reinforced with a tendon allograft. The patient recovered well and was discharged on postoperative day 1. After a 6-week period of immobilization, the patient began a course of physical therapy and ultimately returned to a normal level of activity, including playing hockey, by 6 months postoperatively. He will continue taking aspirin 81 mg daily for 1 year, and no further imaging surveillance is planned.

DISCUSSION

The present case describes an innominate artery injury associated with a Salter-Harris I fracture-dislocation of the SCJ joint in a 17-year-old boy. This patient developed an innominate artery pseudoaneurysm, which was treated by excision of the pseudoaneurysm, bovine pericardial patch angioplasty repair of the innominate artery, and open reduction and internal fixation of the medial physeal fracture and dislocation.

SCJ injuries are rare, comprising <1% of all fractures or dislocations.^{2,4} These injuries are caused by blunt trauma to the shoulder from motor vehicle accidents, sports activities, and falls.^{2,8} With ligament disruption, the medial end of the clavicle can dislocate in the posterior or anterior direction. Posterior dislocations are less common but are more serious due to potential compression and injury to mediastinal structures such as the subclavian artery, innominate artery, internal jugular vein, and trachea.⁵ Approximately 30% of patients with posterior SCJ injuries could have injuries to these mediastinal structures.^{9,10} Patients with posterior SCJ injuries often present with pain in the affected shoulder, with radiation to the neck,¹¹ swelling, paresthesia, neurologic deficits, and hoarseness or dyspnea if tracheal compression occurs.^{9,12}

The identification and diagnosis of posterior SCJ injuries often require a high index of suspicion. The epiphysis at the medial portion of the clavicle is the last to complete its ossification, fusing with the shaft of the clavicle at 23 to 25 years.⁵ Consequently, younger patients are, overall, more susceptible to epiphyseal Salter-Harris I or II fracture-dislocations rather than a true dislocation.^{5,13} In fact, the Salter-Harris classification is specifically a method used to grade fractures in children that involve the growth plate, with five grades describing the exact involvement of the physis, metaphysis, and epiphysis.¹⁴ The clinical presentation can often mimic a ligamentous injury. Identifying the degree of injury on imaging studies can also be difficult. Epiphyseal fractures can be obscure on CT scans and radiographs, because the medial clavicle epiphysis typically begins to ossify at 16 to 19 years.¹⁵ Additionally, the exact degree of displacement of the medial end of the clavicle in the sagittal plane, relative to the sternal articulation, is difficult to determine on standard radiographs because standard views of the SCJ only demonstrate the frontal plane and do not

demonstrate an adequate three-dimensional (3D) representation. Therefore, 3D reconstruction using CT or magnetic resonance imaging of the SCJ could help identify the true degree of clavicle displacement and assess the integrity of the great vessels and other mediastinal structures.^{2,12,13}

No consensus has been reached in the literature regarding the optimal treatment of physeal fracture-dislocation injuries. The treatment options include both closed reduction and open reduction with internal fixation, with closed reduction widely favored if there are no injuries to mediastinal structures. However, closed reduction can be an ineffective method to realign the physis because free fragments might not be adequately managed.¹³ This is particularly true if definitive treatment is delayed. Thus, early management to stabilize the SCJ is recommended, followed by a period of immobilization in a sling.

Several methods for SCJ reconstruction are described in the literature, including soft tissue reconstruction with a tendon graft, plate fixation, and the use of suture anchors.^{4,5} The use of Kirschner wires or Steinman pins for stabilization is not recommended due to the risk of migration to vital structures.⁴ Many repair techniques require anterior to posterior drilling at the clavicle and manubrium, posing the risk of injury to posterior vascular structures.¹¹ After achieving reduction, joint immobilization should occur with the use of a "figure-of-eight" splint or a shoulder sling for a length of 4 to 8 weeks, depending on the method of repair.¹⁶

Surgical treatment is indicated for patients with evidence of vascular injury. Midline sternotomy is the most common exposure technique reported in the literature,¹⁷ although a mini-sternotomy can also provide the needed exposure.¹⁸ Approaches for repair of the innominate artery described in the literature include primary repair and bypass grafting.^{19,20} In the present case, the pseudoaneurysm left a sizable defect, which was adequately treated with a bovine pericardial patch. To the best of our knowledge, this is the first report describing the use of a bovine pericardial patch for artery repair in the case of a SCJ fracture-dislocation. Our reasoning for using a bovine pericardial patch as opposed to a vein patch were twofold: (1) the injury was a closed fracture with no concern for infection; and (2) the patient was nearly a full-grown adult. Therefore, we had less concern for future stenosis. Thus, although some evidence has shown that vein grafts accommodate growth better over time in young children requiring vascular procedures, no long-term data are available supporting the superiority of a vein patch over a bovine pericardial patch in an older age group.²¹⁻²³

CONCLUSIONS

Fracture-dislocations of the SCJ are rare among shoulder girdle injuries and are often misdiagnosed as

ligamentous sprains or other relatively minor posteriorly dislocated SCJ injuries. They can be associated with serious complications as a result of mediastinal compression, including vascular injury. Thus, the index of suspicion should be high when the mechanism of injury is appropriate. Advanced imaging such as 3D CT or magnetic resonance imaging could lead to a more accurate diagnosis. In the present case, a 17-year-old boy developed an innominate artery pseudoaneurysm as a result of a posterior SCJ fracture-dislocation, which was successfully repaired using a bovine pericardial patch with delayed fixation of the displaced SCJ fracture-dislocation.

DISCLOSURES

None.

REFERENCES

1. Waters PM, Bae DS, Kadiyala R, Kumar MD. Short-term Outcomes after surgical treatment of traumatic posterior sternoclavicular fracture-dislocations in children and adolescents. *J Pediatr Orthop.* 2003;23:464–469.
2. Beckmann N, Crawford L. Posterior sternoclavicular salter-harris fracture-dislocation in a patient with unossified medial clavicle epiphysis. *Skeletal Radiol.* 2016;45:1123–1127.
3. Nettles JL, Linscheid RL. Sternoclavicular dislocations. *J Trauma.* 1968;8:158–164.
4. Bennett AN, Edwards E, Kiss Z, Brukner P. Posterior sternoclavicular joint dislocation with brachiocephalic vein compression in an elite hockey player. *Inj Extra.* 2006;37:422–424.
5. Pimenta R, Alegrete N, Vidinha V, Lima S, Pinto I. Medial epiphyseal fracture-detachment of the sternoclavicular joint with posterior displacement in a Judo athlete – equivalent of posterior sternoclavicular dislocation. *Rev Bras Ortop.* 2013;48:196–199.
6. Borrero E. Traumatic posterior displacement of the left clavicular head causing chronic extrinsic compression of the subclavian artery. *Phys Sports Med.* 1987;15:87–89.
7. Khalil H, Bourchier R, Walsh S. Case report – vascular injury in association with posteriorly displaced medial clavicle fracture. *Trauma Case Rep.* 2021;33:100483.
8. Deren ME, Behrens SB, Vopat BG, Blaine TA. Posterior sternoclavicular dislocations: a brief review and technique for closed management of a rare but serious injury. *Orthop Rev.* 2014;6:5245.
9. Carmichael KD, Longo A, Lick S, Swischuk L. Posterior sternoclavicular epiphyseal fracture-dislocation with delayed diagnosis. *Skeletal Radiol.* 2006;35:608–612.
10. Kim WG, Laor T, Jarrett DY. Physeal injuries of the clavicle: pediatric counterparts to adult acromioclavicular and sternoclavicular joint separations. *Pediatr Radiol.* 2023;53:1513–1525.
11. Perdreau A, Bingen B, Gossing L, Lejeune É, Beugnies A. Posterior sternoclavicular epiphyseal fracture-dislocation: case report and review of literature. *Inj Extra.* 2014;45:1–5.
12. Groh GI, Wirth MA. Management of traumatic sternoclavicular joint injuries. *J Am Acad Orthop Surg.* 2011;19:1–7.
13. Lampasi M, Bochicchio V, Bettuzzi C, Donzelli O. Sternoclavicular physeal fracture associated with adjacent clavicle fracture in a 14-year-old boy: a case report and literature review. *Knee Surg Sports Traumatol Arthr.* 2008;16:699–702.
14. Cepela DJ, Tartaglione JP, Dooley TP, Patel PN. Classifications in brief: salter-harris classification of pediatric physeal fractures. *Clin Orthop Relat Res.* 2016;474:2531–2537.
15. Owings-Webb PA, Suchey JM. Epiphyseal union of the anterior iliac crest and medial clavicle in a modern multiracial sample of American males and females. *Am J Phys Anthropol.* 1985;68:457–466.
16. Calderazzi F, Menozzi M, Valenti P, et al. A rare case of complicated pure posterior sternoclavicular dislocation in a young athlete. *Acta Biomed.* 2020;91(14-S):e2020015.
17. Wang XL, Guan XL, Jiang WJ, Liu O, Zhang HJ. Innominate artery aneurysm, how to solve it? *J Int Med Res.* 2017;45:1359–1368.
18. Sakopoulos AG, Ballard JL, Gundry SR. Minimally invasive approach for aortic arch branch vessel reconstruction. *J Vasc Surg.* 2000;31(1 Pt 1):200–202.
19. Darko ND, Danner OK, Wilson KL, Matthews LR, Patel V. Pseudoaneurysm of the proximal innominate artery after blunt trauma. *Am Surg.* 2012;78:E139–E140.
20. Kieffer E, Chiche L, Koskas F, Bahnini A. Aneurysms of the innominate artery: surgical treatment of 27 patients. *J Vasc Surg.* 2001;34:222–228.
21. Morell VO, Wearden PA. Experience with bovine pericardium for the reconstruction of the aortic arch in patients undergoing a Norwood procedure. *Ann Thorac Surg.* 2007;84:1312–1315.
22. Ebert N, McGinnis M, Johnson W, et al. Comparison of patch materials for pulmonary artery reconstruction. *Semin Thorac Cardiovasc Surg.* 2021;33:459–465.
23. van Beynum IM, Kurul S, Krasemann T, et al. Reconstruction of the aortic arch in neonates and infants: the importance of patch material. *World J Pediatr Congenit Heart Surg.* 2021;12:487–491.

Submitted Nov 17, 2023; accepted Dec 7, 2023.